

Penile Inflammatory Skin Disorders and the Preventive Role of Circumcision

Abstract

Penile inflammatory skin conditions such as balanitis and posthitis are common, especially in uncircumcised males, and feature prominently in medical consultations. We conducted a systematic review of the medical literature on PubMed, EMBASE, and Cochrane databases using keywords “balanitis,” “posthitis,” “balanoposthitis,” “lichen sclerosus,” “penile inflammation,” and “inflammation penis,” along with “circumcision,” “circumcised,” and “uncircumcised.” Balanitis is the most common inflammatory disease of the penis. The accumulation of yeasts and other microorganisms under the foreskin contributes to inflammation of the surrounding penile tissue. The clinical presentation of inflammatory penile conditions includes itching, tenderness, and pain. Penile inflammation is responsible for significant morbidity, including acquired phimosis, balanoposthitis, and lichen sclerosus. Medical treatment can be challenging and a cost burden to the health system. Reducing prevalence is therefore important. While topical antifungal creams can be used, usually accompanied by advice on hygiene, the definitive treatment is circumcision. Data from meta-analyses showed that circumcised males have a 68% lower prevalence of balanitis than uncircumcised males and that balanitis is accompanied by a 3.8-fold increase in risk of penile cancer. Because of the high prevalence and morbidity of penile inflammation, especially in immunocompromised and diabetic patients, circumcision should be more widely adopted globally and is best performed early in infancy.

Keywords: Balanitis, circumcision male, foreskin, infection, inflammation, lichen sclerosus

Introduction

Inflammatory lesions of the glans penis (balanitis), of the foreskin (posthitis), or both (balanoposthitis) are common.^[1,2] They are painful and can be associated with penile bleeding, lichen sclerosus (LS), and complications such as phimosis and paraphimosis. Fungal infections are usually responsible, most commonly involving the yeast, *Candida albicans*, potentially associated with polymicrobial flora.^[3] Genital yeast infection (termed “candidiasis” or “thrush”) is uncommon in healthy individuals, but in immunocompromised individuals, such as those with HIV infection, in diabetic and cancer patients *C. albicans* can also cause bloodstream infection with serious consequences.^[4] Globally, the annual incidence of *C. albicans* infection is approximately 400,000, most cases occurring in economically developed regions.^[4] The attributable (27%) mortality rates are very high.^[4] Infected individuals are less able to mount a cytokine response to

limit the damage caused by the *C. albicans* peptide toxin candidalysin, responsible for the epithelial damage caused when hyphae (filamentous structures of yeast) breach the epidermal barrier of the host cell.^[5] A strong direct link of *C. albicans* antibodies with schizophrenia in men, independent of potential confounders, has been reported.^[6]

Penile inflammatory conditions can occur at any age, being more common in males with primary phimosis, and can also cause secondary phimosis. Recent evidence-based policy statements recognize that circumcision can protect against penile inflammation.^[7-10]

The present review discusses the various penile inflammatory skin conditions and the protective role of circumcision.

Methods

The PubMed, EMBASE, and Cochrane databases were searched on May 15, 2016, for “balanitis,” “posthitis,” “balanoposthitis,” “lichen sclerosus,” “penile inflammation,” and “inflammation penis.” We then searched for publications

How to cite this article: Morris BJ, Krieger JN. Penile inflammatory skin disorders and the preventive role of circumcision. *Int J Prev Med* 2017;8:32.

**Brian J. Morris,
John N. Krieger¹**

*Department of Physiology,
School of Medical Sciences
and Bosch Institute, University
of Sydney, New South Wales
2006, Australia, ¹Department
of Medicine, University of
Washington School of Medicine,
VA Puget Sound Health Care
System, Section of Urology,
Seattle, Washington 98108, USA*

Address for correspondence:
Professor Emrt. Brian J. Morris,
School of Medical Sciences and
Bosch Institute, Building F13,
University of Sydney,
New South Wales 2006,
Australia.
E-mail: brian.morris@sydney.
edu.au

Access this article online

Website:
www.ijpvmjournal.net/www.ijpm.ir

DOI:
10.4103/ijpvm.IJPVM_377_16

Quick Response Code:



This is an open access article distributed under the terms of the Creative Commons Attribution-NonCommercial-ShareAlike 3.0 License, which allows others to remix, tweak, and build upon the work non-commercially, as long as the author is credited and the new creations are licensed under the identical terms.

For reprints contact: reprints@medknow.com

matching one or more of the keywords “circumcision,” “circumcised,” or “uncircumcised” plus one or more of the keywords above. EMBASE and Cochrane database searches did not identify additional articles. The title and abstract of each article retrieved was used to judge whether it was of sufficient quality to merit detailed review. Inclusion criteria included either nonduplicated original data or a meta-analysis of original data, and peer-reviewed journal publication. Reference lists were searched for additional articles. Major reviews were used for presenting clinical background.

Results and Discussion

Articles included

Figure 1 shows the results of the search strategy we used.

Balanitis

Clinical presentation and causes

Balanitis presents with mild burning, pruritis, itching, swelling, erythematous patches, and plaques or bullae involving the glans penis, satellite eroded pustules and moist curd-like accumulations^[1] [Figure 2]. In uncircumcised men, the foreskin is often involved (balanoposthitis).^[1] Balanitis has worse clinical presentation in diabetic and immunocompromised patients, with fulminating edema or ulcers in severe cases.^[1]

Poor hygiene is the most common cause. Irritant balanitis can result from exposure to medications, such as some common antibiotics, and to allergens, including latex condoms, propylene glycol in lubricants, some spermicides, and corticosteroids. Ammonia, released from urine by bacterial hydrolysis of urea, can induce inflammation of the glans and foreskin. Another common irritant responsible for contact dermatitis is frequent washing with soaps containing topical allergens or irritants.

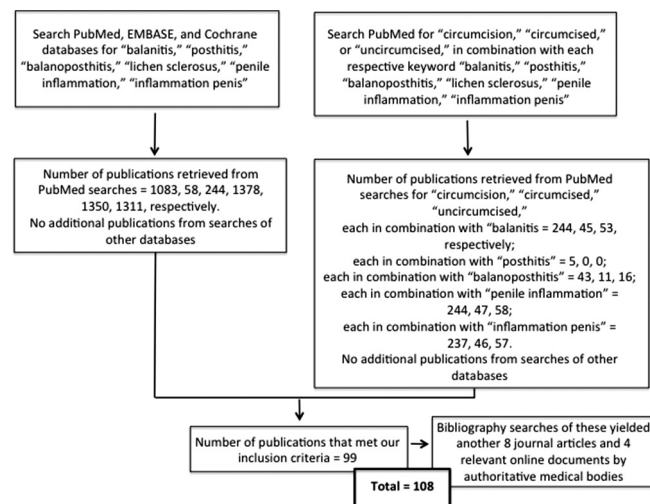


Figure 1: Search strategy and results

Microbiology of balanitis

Various bacterial species and yeasts under the foreskin have the potential to cause penile inflammatory conditions. *C. albicans* is the most frequent fungal isolate from the penis.^[11] Fungi are normal flora, but overgrowth can occur in certain conditions, especially in diabetic patients with phimosis. *Candida* colonization was seen in 16% of men visiting a sexually transmitted infection (STI) clinic in Coventry, the UK.^[12] Symptomatic infection due to *C. albicans* is more common in uncircumcised males.^[3] Bacterial superinfection with Streptococci or Staphylococci increases pain.

Bacteria, especially *Streptococcus* spp., by themselves are the second most common cause of infectious balanitis. Less common are *Haemophilus parainfluenzae*, *Klebsiella* spp., *Staphylococcus epidermidis*, *Enterococcus*, *Proteus* spp., *Morganella* spp., and *Escherichia coli*.^[1]

Chlamydia trachomatis, genital mycoplasmas, and bacterial STIs such as *Neisseria gonorrhoeae*, *Haemophilus ducreyi*, and others can be associated with balanitis and balanoposthitis.^[1] *N. gonorrhoeae* produces an endotoxin likely responsible for edema and erythema of the foreskin.^[13] *Gardnerella vaginalis* is responsible for symptomatic anaerobic-related balanitis in men; presentation includes a subpreputial “fishy”-smelling discharge similar to the odor from bacterial vaginosis in women.^[1] The prevalence of *G. vaginalis* was 15% and 25% among heterosexual attendees at STI clinics in London^[14] and Alabama,^[15] respectively. Other causes of balanitis and balanoposthitis include viral STIs, such as high-risk human papillomavirus (HPV) types, and parasitic infections such as *Trichomonas vaginalis* and protozoa, all more common in uncircumcised men.^[1]

Balanitis in boys

Approximately 4% of boys get balanitis, most commonly during the preschool years.^[16] Balanitis is especially

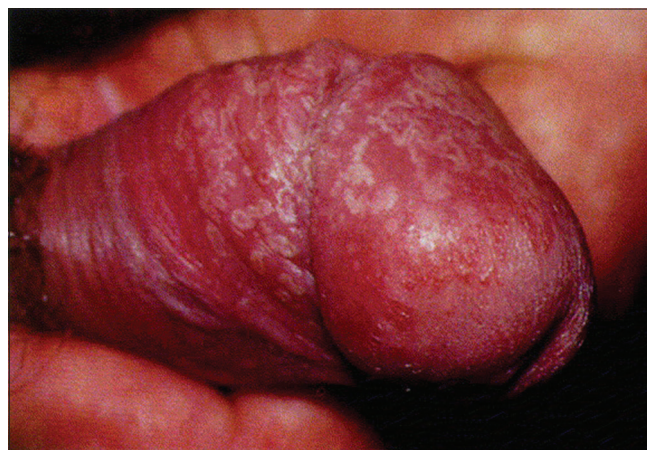

Figure 2: Clinical presentation of balanitis. Reprinted from English et al.^[1]

common in uncircumcised boys aged under 5 years with phimosis (25%) compared with those without phimosis (6%).^[17] For males over 5 years of age, these figures are 24% versus 12%, respectively.^[17] Ballooning was also more common in uncircumcised boys suffering from phimosis (34% vs. 2% and 20% vs. 4% for the respective age groups).^[17] Overgrowth of yeasts as well as other microorganisms that favor development of balanitis can follow antibiotic treatment. Any factor that increases microorganisms substantially has the potential to contribute to balanitis in boys.

A major predisposing factor in boys is lack of circumcision, especially in those whose foreskin is partly or completely nonretractable.^[16] An obvious medical reason for circumcision of boys is protection against balanitis and posthitis.^[3] The incidence of balanitis in boys is over 2-fold higher in the uncircumcised.^[18-21] Cases of balanitis caused by group A or B hemolytic *Streptococcus* spp. have been reported in prepubertal^[22] and postpubertal^[23] uncircumcised boys, respectively. Newer pyrosequencing methods (see subsection below) are needed to confirm and expand on findings in boys.

A study in India of 124 boys aged 6 weeks to 8 years swabbed before circumcision found that *E. coli*, *Proteus* spp., and *Klebsiella* spp., were the most common bacteria.^[24] After circumcision, bacterial cultures were negative in 66%. Swabs of smegma from 52 uncircumcised Nigerian boys aged 1 week to 11 years identified 50 bacterial isolates, 58% being Gram-positive, and 42% Gram-negative; *E. coli* was the most common Gram-negative bacterium.^[25] A Turkish study of 100 prepubertal boys swabbed before circumcision identified 72 organisms, 75% being Gram-positive bacteria, 24% Gram-negative bacteria, and 1% *Candida* spp.^[26] Nine percent of boys had high-risk HPV genotypes. Most bacteria were multidrug resistant and included species capable of causing urinary tract infections. Another Turkish study, involving 78 boys aged 1 month to 14 years (mean 3.9 years), found bacterial growth in 72% before circumcision, but in only 10% after circumcision.^[27] Bacterial growth was seen in all boys with phimosis; growth decreased progressively to approximately 50% for greater exposure of the glans. The most common organisms were *Enterococcus* (33%), *Staphylococcus* spp. (15%), *E. coli* (13%), *Proteus* spp. (7%), and *Klebsiella* spp. (3%).

C. albicans, but no other fungi, was found in 3.5% of 200 Iranian infants before circumcision.^[28] In boys aged 8 months to 18 years (mean 6.4 years), fungus incidence was 44% in uncircumcised boys, compared to 18% in circumcised boys.^[29] The fungal species were as follows: *Malassezia globosa*, *Malassezia furfur*, *Malassezia slooffiae*, *C. albicans*, *Candida tropicalis*, and *Candida parapsilosis*. All were present in uncircumcised infants, but none in circumcised infants. A gradual accumulation with age occurred to 37.5% by the age of 18 years in

circumcised boys compared to the prevalence of 62.5% in uncircumcised boys.

Balanitis in adult males

Lack of circumcision has been consistently associated with balanitis in men.^[30] Other causes include exposure to certain medications, allergens, and chemical irritants. Balanitis was reported in 11%–13% of uncircumcised men, but in only 2% of circumcised men.^[20,21] A 3-year prospective review of men aged 16–95 years (mean age 47 years) at a multi-specialty penile dermatology clinic in Edinburgh, UK, diagnosed nonspecific balanitis in 22% of patients.^[31] When circumcision status was documented, 53% were uncircumcised and 18% were circumcised. An STI clinic in Portugal found that the prevalence of balanitis in men (all uncircumcised) was 11%.^[32] A large randomized controlled trial (RCT) involving young men found balanitis in 0.7% of the uncircumcised men over the 18 months of follow-up, but in none of the men who received circumcision.^[33]

Diabetic uncircumcised men have a high (35%) prevalence of symptomatic balanitis.^[20,21] Among men with acquired phimosis, 26% had a history of diabetes.^[34] Phimosis increases the risk of infection of the foreskin and glans. During the period of 1942–1945 in World War II, there were 146,000 hospitalizations of US troops for balanitis, balanoposthitis, phimosis, and paraphimosis.^[35] It was remarked that “the man-hours lost as a result of circumcisions and adjuvant therapy were expensive to the war effort and exasperated the commanding officers”.^[35] “Time and money could have been saved had prophylactic circumcision been performed before the men were shipped overseas.”^[35]

A study of 350 Indian men found that the uncircumcised men were more likely to harbor bacterial pathogens in the coronal sulcus; Gram-positive, Gram-negative, and any pathogen were 1.9, 2.4 and 2.8 times higher, respectively.^[36]

Smegma, produced under the foreskin, consists of 27% fat and 13% protein, and contributes to the higher occurrence of *Malassezia* spp. in uncircumcised versus circumcised men (49% vs. 7%).^[37] The frequency of yeast colonization was reduced from 11% to 1.3% ($P < 0.008$) by circumcision.^[38]

The uncircumcised penis is an important niche for genital anaerobes associated with bacterial vaginosis in female partners.^[39] Bacterial vaginosis risk to female partners is reduced by male circumcision.^[40] The causative anaerobic genera significantly decreased by circumcision include *Anaerococcus*, *Fingoldia*, *Peptoniphilus*, and *Prevotella*.^[41] These bacteria are exchanged between partners during sexual intercourse.^[39]

Complete microbiome determined by pyrosequencing

Sophisticated 16S rRNA gene-based quantitative polymerase chain reaction (qPCR) and pyrosequencing,

log response ratio, Bayesian classification, nonmetric multidimensional scaling, and permutational multivariate analysis have been used in recent years to provide a much more complete picture of the penile microbiome than traditional clinical microbiological approaches.

A study in Rakai, Uganda, using this technology found a greater microbial diversity on coronary sulcus swabs of uncircumcised men before circumcision than 12 months after circumcision.^[41] Anaerobic bacterial families decreased from 72 to 4.8 ($P < 0.014$) and facultative anaerobic families increased from 23 to 79 ($P = 0.006$), while abundance of aerobic bacteria did not differ significantly before and after circumcision (236 vs. 467). An RCT found significant reduction in prevalence, composition, and load of 12 anaerobic bacterial taxa 1 year after circumcision.^[42] The prevalence and absolute abundance of 12 anaerobic bacterial taxa decreased significantly in the men who were circumcised. It was suggested that reduction in anaerobes might account in part for the ability of circumcision to reduce human immunodeficiency virus infection. An increase in the prevalence of two types of aerobic bacteria (*Corynebacterium* spp. and *Staphylococcus* spp.), which are skin commensals, was seen after circumcision.

A US study involving qPCR and pyrosequencing detected bacterial vaginosis-associated taxa (including *Atopobium*, *Megasphaera*, *Mobiluncus*, *Prevotella*, and *Gemella*) in coronal sulcus specimens of both sexually experienced and inexperienced males aged 14–17 years.^[43] *Porphyromonas* was higher in uncircumcised men (6.4% vs. 0.3%) and *Prevotella* spp. were found in abundance only in uncircumcised males. In contrast, *Staphylococcus* spp. were enriched in circumcised participants (27% vs. 5.5%).^[39]

Pyrosequencing data are consistent with conventional clinical microbiology results, so adding to the reliability of conclusions drawn based only on the latter.

Meta-analysis of balanitis and circumcision status

Figure 3 shows a Forest plot from a meta-analysis of 8 relevant studies.^[18-20,30,33,44-46] This found that prevalence of balanitis was 68% lower in circumcised versus uncircumcised males (odds ratio = 0.32; 95% CI 0.20–0.52)^[47] i.e., was 3.1 times (95% CI 1.9–5.0) higher in uncircumcised males.

Treatment of balanitis

Topical antifungals, if applied consistently until symptoms disappear, may be effective in treatment of sexually acquired balanitis.^[48] Recurrence is frequent, however, especially in patients with risk factors such as phimosis or diabetes. Treatment of the partner is important to reduce the risk of relapse. Prevention entails good hygiene and circumcision during childhood.

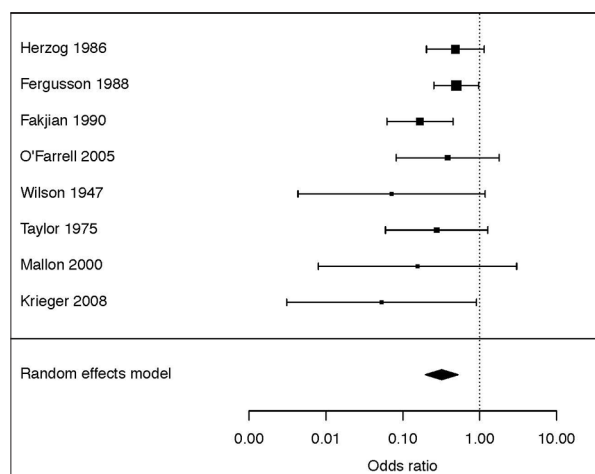


Figure 3: Meta-analysis of association of lack of circumcision with penile inflammation. Reprinted from Morris et al.^[47]

Balanoposthitis

Overview

This condition only occurs in uncircumcised males. The prevalence is lower than balanitis.^[16] The entire distal penis (foreskin and glans) presents as red, painful, and swollen, often accompanied by a foul-smelling, purulent discharge.^[49] Balanoposthitis can involve a vicious cycle. After each infection, the foreskin will heal by fibrosis, in which there is thickening and scarring of connective tissue, and this will further shrink the tight foreskin. Balanoposthitis represents a strong medical indication for circumcision.

Balanoposthitis in boys

In childhood, balanoposthitis presents most commonly between ages 2 and 5 years,^[16] which contradicts claims of soiled diapers, etc., as a major cause of penile inflammation. In young boys, balanoposthitis is often associated with phimosis and inability to clean under the foreskin because the foreskin is still lightly attached to the underlying penis.^[49]

Balanoposthitis in men

This condition was found in 20% of 194 consecutive unselected UK men, all uncircumcised.^[50] A Brazilian study of men presenting for prostate cancer screening identified balanoposthitis in 12%.^[51] The prevalence was 58% higher in those with a history of nonspecific urethritis.^[51] Balanoposthitis is especially common in uncircumcised diabetic men,^[20,51,52] a dysfunctional, shrunken penis likely a contributing factor.^[20] Not surprisingly, balanoposthitis in diabetic men adds to their frequent diabetic neuropathy and peripheral vascular disease, so contributing to their sexual dysfunction. Diabetes is common, inherited, and rising in incidence. Thus, in the opinion of the authors, family history of diabetes may add to considerations for circumcising a newborn infant.

Treatment of balanoposthitis

Local hygienic measures have been suggested for the treatment of nonspecific balanoposthitis.^[53] If the condition is recalcitrant, antifungal and antibiotic creams can be used.^[53] Circumcision is the definitive treatment for the prevention of future occurrence.^[48,53] A study of 476 boys who were circumcised beyond the neonatal period found that balanoposthitis was the reason for performing the surgery in 23% of them.^[54]

Other inflammatory conditions of penile skin

Other penile skin disorders include psoriasis, penile infections, LS, lichen planus, seborrheic dermatitis, and Zoon (plasma cell) balanitis, as described in extensive reviews.^[1,21,55] These conditions are either much more common in, or totally confined to, uncircumcised males. A total of 34 different conditions, most commonly lichenoid conditions (24%), followed by nonspecific balanitis (22%), eczema and psoriasis (11%), Zoon/plasma cell balanitis (10%), malignancy/premalignant change (10%), and infective conditions (9%), were diagnosed over a 3-year period in 226 men in a clinic in Edinburgh.^[31] Penile dermatoses in general have been reported in 20,^[56] 5,^[57] 3,^[31] and 2^[30] times as many uncircumcised as circumcised men. Data on several of the most prominent conditions follow.

A large series has shown that all patients with Zoon balanitis, Bowenoid papulosis, and nonspecific balanoposthitis were uncircumcised.^[30] Bowenoid papulosis occurs mainly in young sexually active men.^[55] One Zoon balanitis case has been reported in a circumcised man.^[58] Typical symptoms of Zoon balanitis are erythema (always), swelling (in 91%), discharge (in 73%), dysuria (in 13%), bleeding (in 2%), and ulceration (in 1%).^[21] *Mycobacterium smegmatis* has been implicated in Zoon balanitis.^[1] Zoon balanitis in 112 uncircumcised men aged 24–70 years involved lesions on the foreskin and glans of 59%, foreskin only in 23%, and glans only in 18%.^[59] Lesions associated with Zoon balanitis improved after treatment with 0.1% tacrolimus ointment.^[60] Erosive lichen planus is associated with increased mast cells, foreskin scarring, and phimosis in uncircumcised men.^[61]

Lichen sclerosis

Overview

LS (previously termed either LS et atrophicus or balanitis xerotica obliterans) is a chronic, progressive, sclerosing inflammatory anogenital skin disease of uncertain etiology.^[1] Figure 4 shows typical clinical appearance.^[62] It is mostly anogenital. Only about 10% of patients have extragenital involvement. Because LS is among the most serious penile inflammatory condition, it has generated numerous publications.

Clinical presentation of lichen sclerosis

LS represents a challenge to urologists.^[63] It presents as single or multiple erythematous papules, macules, or

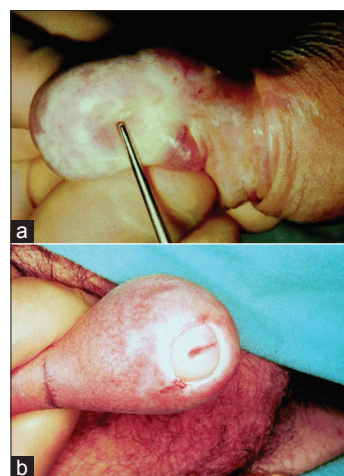


Figure 4: Lichen sclerosis. (a) Appearance of foreskin and glans. (b) Meatal stricture which can result. Reprinted from Depasquale et al.^[62]

plaques that progress to sclerotic or atrophic white, ivory, or blue-white coalescent flat-topped papules and plaques.^[1] Lesions commonly involve the glans and foreskin, although the frenulum, urethral meatus, and fossa navicularis may be involved as well. A sclerotic white ring at the tip of the foreskin is diagnostic of LS. Shaft and perianal involvement is rare. Serosus and hemorrhagic bullae, erosions, fissures, telangiectasia, and petechiae of the glans can occur. The foreskin may be adherent to the glans. As the disease progresses, the coronal sulcus and frenulum may be obliterated and the meatus gradually narrows. Progression of the disease through the entire urethra takes over 10 years,^[64] resulting in significant urinary retention, followed by retrograde damage to the posterior urethra, bladder, and kidneys.^[1] Eventual sloughing of the distal 0.5 cm of the urethra can occur.

LS can present at any age^[65] and estimated prevalence is 1 in 300 to 1 in 1,000.^[66] In prepubertal German boys, the prevalence was 0.1%–0.4%^[67] and in Danish boys aged 1–17 years was 0.37%.^[68]

LS is a common cause of phimosis in boys.^[69,70] Early in its course, LS is often asymptomatic. Men may complain of phimosis, pruritus, burning, hypoesthesia of the glans, dysuria, urethritis with or without discharge, painful erections, and sexual dysfunction.^[1] In a Swedish study, 56% of LS patients complained of an adverse effect on their sex lives.^[71]

Figure 5 shows the penile sites affected by LS in a study of 66 men at a genitourinary clinic in Oxford, the UK.^[65] Frequency was 64% for meatus (37% of these having meatal narrowing), 55% foreskin, 20% shaft, and 20% glans.^[65] At the time of diagnosis, 30% of patients did not complain of symptoms related to LS. Nine percent had had a circumcision. A 2014 review of 40 reports found that LS affected the foreskin and glans in 57%–100% of cases, the meatus in 4%–37%, and urethra in 20%.^[72] These studies found that disease progression may lead to phimosis and

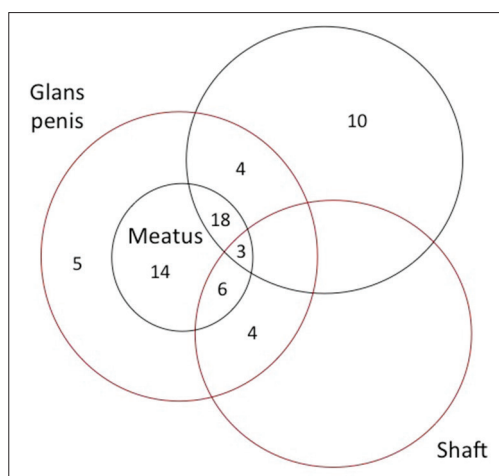


Figure 5: The penile sites affected by lichen sclerosus and the frequency of each in a study of 66 cases in the UK. Redrawn and slightly modified from Riddell *et al.*^[66]

severe urethral stricture disease.^[72] LS prevalence has generally been thought to peak in the fourth decade of life,^[73] although a peak in the third decade has also been reported.^[74] Foreskin biopsy after circumcision diagnosed LS histologically in 4%–19% of cases.^[1,21] Because of the narrow foreskin opening, partial or complete urinary obstruction occurs. Both urethral stenosis and meatal stenosis is seen, so making LS a significant medical problem.^[75,76]

Etiology of lichen sclerosus

LS may have an autoimmune origin, exacerbated by the warm and moist subpreputial environment,^[67] but genetic and hormonal factors^[77] and the isomorphic response^[1] probably contribute. Lack of circumcision applies to 98% of LS patients.^[30] Postpubertal circumcision has also been invoked.^[78]

Lichen sclerosus in boys

Rather than being rare, and a disorder presenting in adulthood, LS is now regarded as common in boys.^[75,79,80] In boys, average age of diagnosis is 9–11 years.^[81] Atopic skin diathesis, seen in 25% of juvenile cases, may predispose to LS.^[82] In contrast to a reported rate of 1%,^[83] two UK studies found LS prevalence of 5% and 6% in uncircumcised boys under 18 and 15 years of age, respectively.^[84,85] Histological examination of foreskins removed for various reasons revealed LS in 3.6%–19%.^[86-91] A study in Plymouth, UK, of 422 boys aged 3 months to 16 years (mean 6 years) referred to a pediatric general surgical outpatient department with foreskin problems found 55.9% were normal, with the remainder (44.1%) undergoing surgery: 35% circumcision, 8% preputial adhesiolysis, and 0.1% frenuloplasty.^[75] Histological abnormalities were seen in 85% of the foreskins removed by circumcision; chronic inflammation was seen in 47%, LS in 35%, fibrosis in 3%, and 13% were histologically normal.^[75]

Global LS prevalence from 13 studies was 35% in foreskins from boys circumcised for any reason.^[92] A prospective study in Budapest involving 1,178 boys who presented consecutively over the decade 1991–2001 and who underwent circumcision, identified LS in 40% of histological specimens, with peak prevalence of 76% at ages 9–11 years.^[93] In this study, 19% had an early, 60% had an intermediate, and 21% had a late form of LS.

LS prevalence in acquired phimosis cases ranges from 10%^[94] to 80%–90%^[67] in more recent studies. LS can cause pathological phimosis as a result of secondary cicatrization of the foreskin orifice. In one study, LS was regarded as responsible for secondary phimosis in all pediatric patients requiring circumcision.^[93] In another study, 37% of pediatric patients with severe phimosis had LS.^[95] A further study found LS in 60% of boys with acquired phimosis and in 30% of those with congenital phimosis.^[96] Foreskin inflammation was seen in 88% and 82%, respectively. The study also examined boys with congenital hypospadias, with 61% showing symptoms of inflammation and 15% having features consistent with LS. In a case series from Boston, of 41 pediatric patients with LS, 52% had been referred for phimosis, 13% for balanitis, and 10% for buried penis.^[97]

Lichen sclerosus in adult males

An Italian study of men of mean age 46 years found LS in 85% of biopsies, LS of the foreskin being documented by histology in 93% of cases, of the meatus in 92% of cases, of the fossa navicularis in 84% and of the penile urethra in 71%.^[64] A Hungarian study of men circumcised for phimosis found LS in 62%.^[98]

In older patients, progressive LS or other inflammatory changes can lead to phimosis.^[99] LS with phimosis can also cause lower urinary tract symptoms in elderly men.^[100] Phimosis in older men is associated with 44%–85% of cases of penile cancer.^[72,101] In men not circumcised in childhood, phimosis was strongly associated with invasive penile cancer, as was high-risk HPV.^[102] Oncogenic HPV was seen in 23% of 92 Italian men aged on average 68 years who had LS, compared to 15% of men aged on average 58 years without LS, suggesting that LS causes slower clearance of HPV.^[103] Among 226 males aged 16–95 years attending a penile dermatology clinic in Edinburgh, penile intraepithelial neoplasia was diagnosed in 6% and invasive penile cancer in 2%.^[31] Penile cancer was seen in 1% of 771 Swedish men aged 48.6 years (range 22–92) diagnosed with LS during 1997–2007.^[71] Another study found penile cancer in 4%–8% of men with LS.^[104]

A random-effects meta-analysis of 8 studies found an association of phimosis with a 12-fold (95% CI 5.6–26) increase in penile cancer risk.^[105] Lifetime prevalence of penile cancer is approximately 1 in 1000.^[7,8,105] Among patients diagnosed with LS, penile cancer occurred in

2.3%–8.4% and mean time between diagnosis of LS and development of penile cancer is 12 years.^[62,72,106]

LS represents an important, potentially preventable risk factor for this devastating cancer.

Treatment of lichen sclerosus in boys

The treatment of choice for LS in boys is circumcision.^[62,93,94] Conservative treatment with topical steroids is considered “controversial.”^[67,82] Because of significant side effects, steroid use should be avoided in children.^[72] Preputioplasty is regarded by some as effective, although 13% of patients developed recurrent symptoms.^[107] Preputioplasty or frenuloplasty are never a first choice. They are only an option when parents do not agree to circumcise. A Boston study found 46% of pediatric LS patients underwent curative circumcision.^[97] In 27%, LS involved the meatus, so besides circumcision these patients had meatotomy or meatoplasty. In all, 22% required extensive plastic surgery of the penis, including buccal mucosa grafts, demonstrating a more severe and morbid clinical course. A study in Liverpool, UK, of 300 boys (mean age 9 years; range 4–16 years) circumcised after clinical diagnosis of LS, confirmed LS by histology in 80% and 1 in 5 required subsequent meatal dilatation or meatotomy for meatal pathology.^[108]

Treatment of lichen sclerosus in men

Circumcision is curative in “nearly 100%” of LS cases.^[109] Another study reported a cure rate of over 75%^[73] and when confined to the foreskin, circumcision resulted in a long-term cure in 92% of LS patients.^[62]

Steroid creams can limit disease progression but do not cure many LS cases.^[73,110] Steroids lead to an improvement in 41%–76%, but a cure in only 50%–60% of cases in men.^[73] In the second author’s experience, steroids are less effective than this. Recurrence of LS after steroid treatment may occur after 5 years.^[109] In a Swedish study, 30% of men reported that outcome of local steroid treatment was “good,” while 37% said it was “medium” and 16% “poor” (17% failed to answer).^[71] An Indian study of men aged 20–45 years with LS reported a preference by all for circumcision rather than use of steroid creams.^[111] In another Indian study, 77% received circumcision for treatment.^[63]

Progression to urethral involvement makes treatment much more difficult.^[72] Treatment may include meatotomy or meatoplasty for meatal stenosis and urethroplasty for urethral involvement. Extensive disease affecting the full length of the urethra may require perineal urethrostomy.^[72] In an Italian study of men of mean age 46 years, treatment included circumcision, meatotomy, navicularis uroplasty, extensive grafting procedures, and perineal urethrostomy.^[64]

Conclusions

Balanitis and balanoposthitis are common. Not only do they lead to frequent medical consultations, but if not treated, the consequences can include acquired phimosis and LS, the treatment of which can often be challenging. While topical antifungal creams can be used to treat each of these, usually accompanied by advice on hygiene, the definitive treatment is circumcision. Based on the evidence, circumcision of males, particularly early in life, substantially reduced the risk of penile inflammatory conditions. The clinical and personal burden of penile inflammatory conditions in males can be ameliorated by preventive measures, most notably circumcision.

Financial support and sponsorship

Nil.

Conflicts of interest

There are no conflicts of interest.

Received: 19 Nov 16 **Accepted:** 07 Feb 17

Published: 04 May 17

References

- English JC 3rd, Laws RA, Keough GC, Wilde JL, Foley JP, Elston DM. Dermatoses of the glans penis and prepuce. *J Am Acad Dermatol* 1997;37:1-24.
- West DS, Papalas JA, Selim MA, Vollmer RT. Dermatopathology of the foreskin: An institutional experience of over 400 cases. *J Cutan Pathol* 2013;40:11-8.
- Edwards S. Balanitis and balanoposthitis: A review. *Genitourin Med* 1996;72:155-9.
- Brown GD, Denning DW, Gow NA, Levitz SM, Netea MG, White TC. Hidden killers: Human fungal infections. *Sci Transl Med* 2012;4:165rv13.
- Moyes DL, Wilson D, Richardson JP, Mogavero S, Tang SX, Wernecke J, *et al.* Candidalysin is a fungal peptide toxin critical for mucosal infection. *Nature* 2016;532:64-8.
- Severance EG, Gressitt KL, Stallings CR, Katsafanas E, Schweinfurth LA, Savage CL, *et al.* *Candida albicans* exposures, sex specificity and cognitive deficits in schizophrenia and bipolar disorder. *NPJ Schizophr* 2016;2:16018.
- American Academy of Pediatrics Task Force on Circumcision. Male circumcision. *Pediatrics* 2012;130:e756-85.
- Centers for Disease Control and Prevention. [Docket No. CDC-2014-0012-0002] Recommendations for Providers Counseling Male Patients and Parents Regarding Male Circumcision and the Prevention of HIV Infection, STIs, and Other Health Outcomes; 2014. Available from: <http://www.regulations.gov/-!documentDetail;D=CDC-2014-0012-0002>. [Last accessed on 2016 Sep 14].
- American Urological Association. Circumcision. Available from: <http://www.auanet.org/about/policy-statements/circumcision.cfm>. [Last accessed on 2016 Sep 14].
- Morris BJ, Wodak AD, Mindel A, Schrieber L, Duggan KA, Dilly A, *et al.* Infant male circumcision: An evidence-based policy statement. *Open J Prevent Med* 2012;2:79-92.
- Aridogan IA, Izol V, Ilkit M. Superficial fungal infections of the male genitalia: A review. *Crit Rev Microbiol* 2011;37:237-44.

12. David LM, Walzman M, Rajamanoharan S. Genital colonisation and infection with *Candida* in heterosexual and homosexual males. *Genitourin Med* 1997;73:394-6.
13. Fiumara NJ, Kahn S. Contact dermatitis from a gonococcal discharge: A case report. *Sex Transm Dis* 1982;9:41-2.
14. Dawson SG, Ison CA, Csonka G, Easmon CS. Male carriage of *Gardnerella vaginalis*. *Br J Vener Dis* 1982;58:243-5.
15. Schwebke JR, Rivers C, Lee J. Prevalence of *Gardnerella vaginalis* in male sexual partners of women with and without bacterial vaginosis. *Sex Transm Dis* 2009;36:92-4.
16. Escala JM, Rickwood AM. Balanitis. *Br J Urol* 1989;63:196-7.
17. Ladenhauf HN, Ardelean MA, Schimke C, Yankovic F, Schimpl G. Reduced bacterial colonisation of the glans penis after male circumcision in children – A prospective study. *J Pediatr Urol* 2013;9(6 Pt B):1137-44.
18. Herzog LW, Alvarez SR. The frequency of foreskin problems in uncircumcised children. *Am J Dis Child* 1986;140:254-6.
19. Fergusson DM, Lawton JM, Shannon FT. Neonatal circumcision and penile problems: An 8-year longitudinal study. *Pediatrics* 1988;81:537-41.
20. Fakjian N, Hunter S, Cole GW, Miller J. An argument for circumcision. Prevention of balanitis in the adult. *Arch Dermatol* 1990;126:1046-7.
21. Köhn FM, Pflieger-Bruss S, Schill WB. Penile skin diseases. *Andrologia* 1999;31 Suppl 1:3-11.
22. Orden B, Martin R, Franco A, Ibañez G, Mendez E. Balanitis caused by group A beta-hemolytic streptococci. *Pediatr Infect Dis J* 1996;15:920-1.
23. Lucks DA, Venezia FR, Lakin CM. Balanitis caused by group B streptococcus. *J Urol* 1986;135:1015.
24. Laway MA, Wani ML, Patnaik R, Kakru D, Ismail S, Shera AH, *et al.* Does circumcision alter the periurethral uropathogenic bacterial flora. *Afr J Paediatr Surg* 2012;9:109-12.
25. Anyanwu LJ, Kashibu E, Edwin CP, Mohammad AM. Microbiology of smegma in boys in Kano, Nigeria. *J Surg Res* 2012;173:21-5.
26. Balci M, Tuncel A, Baran I, Guzel O, Keten T, Aksu N, *et al.* High-risk oncogenic human papilloma virus infection of the foreskin and microbiology of smegma in prepubertal boys. *Urology* 2015;86:368-72.
27. Tarhan H, Akarken I, Koca O, Ozgü I, Zorlu F. Effect of preputial type on bacterial colonization and wound healing in boys undergoing circumcision. *Korean J Urol* 2012;53:431-4.
28. Mousavi SA, Shokohi T, Hedayati MT, Mosayebi E, Abdollahi A, Didehdar M. Prevalence of yeast colonization on prepuce of uncircumcised children. *J Mazandaran Univ Med Sci* 2015;25:118-22.
29. Iskit S, Ilkit M, Turç-Biçer A, Demirhindi H, Türker M. Effect of circumcision on genital colonization of *Malassezia* spp. in a pediatric population. *Med Mycol* 2006;44:113-7.
30. Mallon E, Hawkins D, Dinneen M, Francis N, Fearfield L, Newson R, *et al.* Circumcision and genital dermatoses. *Arch Dermatol* 2000;136:350-4.
31. Pearce J, Fernando I. The value of a multi-specialty service, including genitourinary medicine, dermatology and urology input, in the management of male genital dermatoses. *Int J STD AIDS* 2015;26:716-22.
32. Lisboa C, Ferreira A, Resende C, Rodrigues AG. Infectious balanoposthitis: Management, clinical and laboratory features. *Int J Dermatol* 2009;48:121-4.
33. Krieger JN, Mehta SD, Bailey RC, Agot K, Ndinya-Achola JO, Parker C, *et al.* Adult male circumcision: Effects on sexual function and sexual satisfaction in Kisumu, Kenya. *J Sex Med* 2008;5:2610-22.
34. Bromage SJ, Crump A, Pearce I. Phimosi as a presenting feature of diabetes. *BJU Int* 2008;101:338-40.
35. Patton JF. Urology. In United States Army Surgery in World War II. Office of the Surgeon General and Center of Military History; 1987. p. 45-88, 52, 64, 100, 120, 121, 145, 146, 183, 488.
36. Schneider JA, Vadivelu S, Liao C, Kandukuri SR, Trikarnji BV, Chang E, *et al.* Increased likelihood of bacterial pathogens in the coronal sulcus and urethra of uncircumcised men in a diverse group of HIV infected and uninfected patients in India. *J Glob Infect Dis* 2012;4:6-9.
37. Mayser P, Schütz M, Schuppe HC, Jung A, Schill WB. Frequency and spectrum of *Malassezia* yeasts in the area of the prepuce and glans penis. *BJU Int* 2001;88:554-8.
38. Aridogan IA, Ilkit M, Izol V, Ates A, Demirhindi H. Glans penis and prepuce colonisation of yeast fungi in a paediatric population: Pre- and postcircumcision results. *Mycoses* 2009;52:49-52.
39. Liu CM, Hungate BA, Tobian AA, Ravel J, Prodder JL, Serwadda D, *et al.* Penile microbiota and female partner bacterial vaginosis in Rakai, Uganda. *MBio* 2015;6:e00589.
40. Gray RH, Kigozi G, Serwadda D, Makumbi F, Nalugoda F, Watya S, *et al.* The effects of male circumcision on female partners' genital tract symptoms and vaginal infections in a randomized trial in Rakai, Uganda. *Am J Obstet Gynecol* 2009;200:42.e1-7.
41. Price LB, Liu CM, Johnson KE, Aziz M, Lau MK, Bowers J, *et al.* The effects of circumcision on the penis microbiome. *PLoS One* 2010;5:e8422.
42. Liu CM, Hungate BA, Tobian AA, Serwadda D, Ravel J, Lester R, *et al.* Male circumcision significantly reduces prevalence and load of genital anaerobic bacteria. *MBio* 2013;4:e00076.
43. Nelson DE, Dong Q, Van der Pol B, Toh E, Fan B, Katz BP, *et al.* Bacterial communities of the coronal sulcus and distal urethra of adolescent males. *PLoS One* 2012;7:e36298.
44. O'Farrell N, Quigley M, Fox P. Association between the intact foreskin and inferior standards of male genital hygiene behaviour: A cross-sectional study. *Int J STD AIDS* 2005;16:556-9.
45. Wilson RA. Circumcision and venereal disease. *Can Med Assoc J* 1947;56:54-6.
46. Taylor PK, Rodin P. Herpes genitalis and circumcision. *Br J Vener Dis* 1975;51:274-7.
47. Morris BJ, Waskett JH, Banerjee J, Wamai RG, Tobian AA, Gray RH, *et al.* A 'snip' in time: What is the best age to circumcise? *BMC Pediatr* 2012;12:20.
48. Edwards SK, Bunker CB, Ziller F, van der Meijden WI 2013 European guideline for the management of balanoposthitis. *Int J STD AIDS* 2014;25:615-26.
49. Schoen EJ. Circumcision as a lifetime vaccination with many benefits. *J Mens Health Gend* 2007;382:306-11.
50. Kinghorn GR, Jones BM, Chowdhury FH, Geary I. Balanoposthitis associated with *Gardnerella vaginalis* infection in men. *Br J Vener Dis* 1982;58:127-9.
51. Romero FR, Romero AW, Almeida RM, Oliveira FC Jr., Filho RT Jr. Prevalence and risk factors for penile lesions/anomalies in a cohort of Brazilian men ≥ 40 years of age. *Int Braz J Urol* 2013;39:55-62.
52. Verma SB, Wollina U. Looking through the cracks of diabetic candidal balanoposthitis! *Int J Gen Med* 2011;4:511-3.
53. Schwartz RH, Rushton HG. Acute balanoposthitis in young boys. *Pediatr Infect Dis J* 1996;15:176-7.
54. Wiswell TE, Tencer HL, Welch CA, Chamberlain JL.

- Circumcision in children beyond the neonatal period. *Pediatrics* 1993;92:791-3.
55. Singh S, Bunker C. Male genital dermatoses in old age. *Age Ageing* 2008;37:500-4.
 56. Samuel M, Brady M, Tenant-Flowers M, Taylor C. Role of penile biopsy in the diagnosis of penile dermatoses. *Int J STD AIDS* 2010;21:371-2.
 57. David N, Tang A. Efficacy and safety of penile biopsy in a GUM clinic setting. *Int J STD AIDS* 2002;13:573-6.
 58. Toker SC, Baskan EB, Tunali S, Yilmaz M, Karadogan SK. Zoon's balanitis in a circumcised man. *J Am Acad Dermatol* 2007;57 2 Suppl: S6-7.
 59. Kumar B, Narang T, Dass Radotra B, Gupta S. Plasma cell balanitis: Clinicopathologic study of 112 cases and treatment modalities. *J Cutan Med Surg* 2006;10:11-5.
 60. Moreno-Arias GA, Camps-Fresneda A, Llaberia C, Palou-Almerich J. Plasma cell balanitis treated with tacrolimus 0.1%. *Br J Dermatol* 2005;153:1204-6.
 61. Regauer S, Beham-Schmid C. Benign mast cell hyperplasia and atypical mast cell infiltrates in penile lichen planus in adult men. *Histol Histopathol* 2014;29:1017-25.
 62. Depasquale I, Park AJ, Bracka A. The treatment of balanitis xerotica obliterans. *BJU Int* 2000;86:459-65.
 63. Singh JP, Priyadarshi V, Goel HK, Vijay MK, Pal DK, Chakraborty S, *et al.* Penile lichen sclerosis: An urologist's nightmare! – A single center experience. *Urol Ann* 2015;7:303-8.
 64. Barbagli G, Mirri F, Gallucci M, Sansalone S, Romano G, Lazzeri M. Histological evidence of urethral involvement in male patients with genital lichen sclerosis: A preliminary report. *J Urol* 2011;185:2171-6.
 65. Riddell L, Edwards A, Sherrard J. Clinical features of lichen sclerosis in men attending a department of genitourinary medicine. *Sex Transm Infect* 2000;76:311-3.
 66. Wallace HJ. Lichen sclerosis et atrophicus. *Trans St Johns Hosp Dermatol Soc* 1971;57:9-30.
 67. Becker K. Lichen sclerosis in boys. *Dtsch Arztebl Int* 2011;108:53-8.
 68. Sneppen I, Thorup J. Foreskin morbidity in uncircumcised males. *Pediatrics* 2016;137. pii: e20154340.
 69. Rickwood AM, Hemalatha V, Batcup G, Spitz L. Phimosis in boys. *Br J Urol* 1980;52:147-50.
 70. Garat JM, Chéchile G, Algaba F, Santaularia JM. Balanitis xerotica obliterans in children. *J Urol* 1986;136:436-7.
 71. Kantere D, Löwhagen GB, Alvingren G, Månesköld A, Gillstedt M, Tunbäck P. The clinical spectrum of lichen sclerosis in male patients – A retrospective study. *Acta Derm Venereol* 2014;94:542-6.
 72. Stewart L, McCammon K, Metro M, Virasoro R. SIU/ICUD Consultation on Urethral Strictures: Anterior urethra-lichen sclerosis. *Urology* 2014;83 Suppl: S27-30.
 73. Edmonds EV, Hunt S, Hawkins D, Dinneen M, Francis N, Bunker CB. Clinical parameters in male genital lichen sclerosis: A case series of 329 patients. *J Eur Acad Dermatol Venereol* 2012;26:730-7.
 74. Kizer WS, Prarie T, Morey AF. Balanitis xerotica obliterans: Epidemiologic distribution in an equal access health care system. *South Med J* 2003;96:9-11.
 75. Yardley IE, Cosgrove C, Lambert AW. Paediatric preputial pathology: Are we circumcising enough? *Ann R Coll Surg Engl* 2007;89:62-5.
 76. Belsante MJ, Selph JP, Peterson AC. The contemporary management of urethral strictures in men resulting from lichen sclerosis. *Transl Androl Urol* 2015;4:22-8.
 77. Meffert JJ, Davis BM, Grimwood RE. Lichen sclerosis. *J Am Acad Dermatol* 1995;32:393-416.
 78. Weigand DA. Lichen sclerosis et atrophicus, multiple dysplastic keratoses, and squamous-cell carcinoma of the glans penis. *J Dermatol Surg Oncol* 1980;6:45-50.
 79. Jayakumar S, Antao B, Bevington O, Furness P, Ninan GK. Balanitis xerotica obliterans in children and its incidence under the age of 5 years. *J Pediatr Urol* 2012;8:272-5.
 80. Kuehhas FE, Miernik A, Weibl P, Schoenthaler M, Sevcenco S, Schauer I, *et al.* Incidence of balanitis xerotica obliterans in boys younger than 10 years presenting with phimosis. *Urol Int* 2013;90:439-42.
 81. Fistarol SK, Itin PH. Diagnosis and treatment of lichen sclerosis: An update. *Am J Clin Dermatol* 2013;14:27-47.
 82. Becker K, Meissner V, Farwick W, Bauer R, Gaiser MR. Lichen sclerosis and atopy in boys: Coincidence or correlation? *Br J Dermatol* 2013;168:362-6.
 83. Rickwood AM, Kenny SE, Donnell SC. Towards evidence based circumcision of English boys: Survey of trends in practice. *BMJ* 2000;321:792-3.
 84. Griffiths D, Frank JD. Inappropriate circumcision referrals by GPs. *J R Soc Med* 1992;85:324-5.
 85. Huntley JS, Bourne MC, Munro FD, Wilson-Storey D. Troubles with the foreskin: One hundred consecutive referrals to paediatric surgeons. *J R Soc Med* 2003;96:449-51.
 86. Bainbridge DR, Whitaker RH, Shepherd BG. Balanitis xerotica obliterans and urinary obstruction. *Br J Urol* 1971;43:487-91.
 87. Schinella RA, Miranda D. Posthitis xerotica obliterans in circumcision specimens. *Urology* 1974;3:348-51.
 88. Ridley CM. Genital lichen sclerosis (lichen sclerosis et atrophicus) in childhood and adolescence. *J R Soc Med* 1993;86:69-75.
 89. Chalmers RJ, Burton PA, Bennett RF, Goring CC, Smith PJ. Lichen sclerosis et atrophicus. A common and distinctive cause of phimosis in boys. *Arch Dermatol* 1984;120:1025-7.
 90. Bale PM, Lochhead A, Martin HC, Gollow I. Balanitis xerotica obliterans in children. *Pediatr Pathol* 1987;7:617-27.
 91. Clemmensen OJ, Krogh J, Petri M. The histologic spectrum of prepuces from patients with phimosis. *Am J Dermatopathol* 1988;10:104-8.
 92. Celis S, Reed F, Murphy F, Adams S, Gillick J, Abdelhafeez AH, *et al.* Balanitis xerotica obliterans in children and adolescents: A literature review and clinical series. *J Pediatr Urol* 2014;10:34-9.
 93. Kiss A, Király L, Kutasy B, Merksz M. High incidence of balanitis xerotica obliterans in boys with phimosis: Prospective 10-year study. *Pediatr Dermatol* 2005;22:305-8.
 94. Meuli M, Briner J, Hanimann B, Sacher P. Lichen sclerosis et atrophicus causing phimosis in boys: A prospective study with 5-year followup after complete circumcision. *J Urol* 1994;152:987-9.
 95. Rossi E, Pavanello P, Franchella A. Lichen sclerosis in children with phimosis. *Minerva Pediatr* 2007;59:761-5.
 96. Mattioli G, Repetto P, Carlini C, Granata C, Gambini C, Jasonni V. Lichen sclerosis et atrophicus in children with phimosis and hypospadias. *Pediatr Surg Int* 2002;18:273-5.
 97. Gargollo PC, Kozakewich HP, Bauer SB, Borer JG, Peters CA, Retik AB, *et al.* Balanitis xerotica obliterans in boys. *J Urol* 2005;174(4 Pt 1):1409-12.
 98. Nyirády P, Borka K, Bánfi G, Kelemen Z. Lichen sclerosis in urological practice. *Orv Hetil* 2006;147:2125-9.
 99. Aynaud O, Piron D, Casanova JM. Incidence of preputial lichen sclerosis in adults: Histologic study of circumcision specimens. *J Am Acad Dermatol* 1999;41:923-6.

100. Nemoto K, Ishidate T. Balanitis xerotica obliterans with phimosis in elderly patients presenting with difficulty in urination. *Hinyokika Kyo* 2013;59:341-6.
101. Micali G, Nasca MR, Innocenzi D, Schwartz RA. Penile cancer. *J Am Acad Dermatol* 2006;54:369-91.
102. Daling JR, Madeleine MM, Johnson LG, Schwartz SM, Shera KA, Wurscher MA, *et al*. Penile cancer: Importance of circumcision, human papillomavirus and smoking in *in situ* and invasive disease. *Int J Cancer* 2005;116:606-16.
103. Nasca MR, Lacarrubba F, Paravizzini G, Micali G. Oncogenic human papillomavirus detection in penile lichen sclerosis: An update. *Int STD Res Rev* 2014;2:29-37.
104. Clouston D, Hall A, Lawrentschuk N. Penile lichen sclerosis (balanitis xerotica obliterans). *BJU Int* 2011;108 Suppl 2:14-9.
105. Morris BJ, Gray RH, Castellsague X, Bosch FX, Halperin DT, Waskett JH, *et al*. The strong protective effect of circumcision against cancer of the penis. *Adv Urol* 2011;2011:812368.
106. Barbagli G, Palminteri E, Mirri F, Guazzoni G, Turini D, Lazzeri M. Penile carcinoma in patients with genital lichen sclerosis: A multicenter survey. *J Urol* 2006;175:1359-63.
107. Wilkinson DJ, Lansdale N, Everitt LH, Marven SS, Walker J, Shawis RN, *et al*. Foreskin preputioplasty and intralesional triamcinolone: A valid alternative to circumcision for balanitis xerotica obliterans. *J Pediatr Surg* 2012;47:756-9.
108. Homer L, Buchanan KJ, Nasr B, Losty PD, Corbett HJ. Meatal stenosis in boys following circumcision for lichen sclerosis (balanitis xerotica obliterans). *J Urol* 2014;192:1784-8.
109. Kirtschig G, Becker K, Günthert A, Jasaitiene D, Cooper S, Chi CC, *et al*. Evidence-based (S3) guideline on (anogenital) lichen sclerosis. *J Eur Acad Dermatol Venereol* 2015;29:e1-43.
110. Hartley A, Ramanathan C, Siddiqui H. The surgical treatment of Balanitis Xerotica Obliterans. *Indian J Plast Surg* 2011;44:91-7.
111. Singh Thakur R, Pinjala P, Babu M. Balanitis xerotica obliterans Bxo-mimicking vitiligo. *IOSR J Dent Med Sci* 2015;14:29-31.