



Review Article

Fronto-orbito-ethmoidal intradiploic meningiomas: A case study with systematic review

Antonio Crea¹, Gianluca Grimod¹, Gianluca Scalia², Mariarosaria Verlotta¹, Lucio Mazzeo¹, Giorgio Rossi³, Davide Mattavelli⁴, Vittorio Rampinelli⁴, Sabino Luzzi⁵, Giannantonio Spena¹

¹Department of Neuroscience, Neurosurgery Unit, Alessandro Manzoni Hospital, Lecco, ²Department of Neurosurgery, Highly Specialized Hospital of National Importance "Garibaldi", Catania, ³Department of Oncology, Pathological Anatomy and Histology Unit, Alessandro Manzoni Hospital, Lecco, ⁴Department of Surgical Specialties, Radiological Sciences and Public Health, Unit of Otorhinolaryngology – Head and neck Surgery, Piazza del Mercato, Brescia, ⁵Department of Neurosurgery, IRCCS Fondazione Policlinico San Matteo, University of Pavia, Pavia, Italy.

E-mail: *Antonio Crea - antonio_crea89@virgilio.it; Gianluca Grimod - g.grimod@gmail.com; Gianluca Scalia - gianluca.scalia@outlook.it; Mariarosaria Verlotta - mari.verlotta@gmail.com; Lucio Mazzeo - umazzeo@yahoo.it; Giorgio Rossi - gi.rossi@asst-lecco.it; Davide Mattavelli - davide.mattavelli@unibs.it; Vittorio Rampinelli - vittorio.rampinelli@gmail.com; Sabino Luzzi - sabino.luzzi@gmail.com, Giannantonio Spena - giannantonios@gmail.com



***Corresponding author:**

Antonio Crea,
Department of Neuroscience,
Neurosurgery Unit, Alessandro
Manzoni Hospital, Lecco, Italy.

antonio_crea89@virgilio.it

Received : 19 April 2021
Accepted : 08 September 2021
Published : 30 September 2021

DOI
10.25259/SNI_386_2021

Quick Response Code:



ABSTRACT

Background: Primary intradiploic meningiomas, extra-axial tumors arising primarily in the skull, are rare. The authors reported a complex case of intradiploic intraosseous metaplastic meningioma of the left medial wall and orbital roof with the left frontal sinus invasion and left ethmoidal body bone substitution. The authors also conducted a systematic review concerning diagnosis and management of patients affected by purely calvarial intradiploic meningiomas along with a focus on fronto-orbito-ethmoidal ones.

Methods: A literature search was conducted using PubMed and Scopus databases according to preferred reporting items for systematic reviews and meta-analysis statement and with the following Mesh terms: Intradiploic, intraosseous, calvarial, and meningioma. Eligibility criteria were limited by the nature of existing literature on intradiploic meningiomas, consisting of only case series, and case reports.

Results: A total of 128 published studies were identified through our search. 41 studies were included in this systematic review, 59 patients with a female/male ratio of 1.2/1. The mean age of the patients is of 47.69 years (range 3–84 years). Only seven out of 59 patients (11.9%) presented a complex intradiploic meningioma located in fronto-orbito-ethmoidal region like our case. In almost all patients, a gross-total resection was performed (96.6%) and only in two patients (3.4%) a subtotal resection was achieved.

Conclusion: The authors shared this successfully treated case to add to the overall clinical experience in the management of this rare subtype tumor, with the hope that more studies are conducted to further address the mechanism of intradiploic meningiomas development.

Keywords: Anterior skull base, Calvarial, Intradiploic, Intraosseous, Meningioma

INTRODUCTION

Meningiomas are one of the most common benign brain/intracranial tumors with an incidence rate of 15–20%.^[1,2] Parasagittal and convexity location are the most frequent accounting all together for almost 45% of the cases. The most common extradural localizations are the paranasal sinuses, nasal cavity, skin, neck, glands, and intraosseous space.^[3] Primary intraosseous lesions

This is an open-access article distributed under the terms of the Creative Commons Attribution-Non Commercial-Share Alike 4.0 License, which allows others to remix, tweak, and build upon the work non-commercially, as long as the author is credited and the new creations are licensed under the identical terms.

©2021 Published by Scientific Scholar on behalf of Surgical Neurology International

are rare accounting for <1% of intracranial meningiomas.^[39] Intradiploic meningioma is an extremely rare type of extradural meningioma and is generally localized in the frontoparietal and orbital regions. Due to their low incidence and lack of adequate preoperative diagnostic imaging, intradiploic meningiomas are generally mistaken for primary calvarial bone tumors, en plaque meningiomas, and fibrous dysplasia. It is postulated that they could arise from arachnoid cell remnants captured at inappropriate sites during embryonic development or implantation of these cells by some mechanical insult such as trauma or dural tear.^[23] Their origin can also be attributed to cellular dedifferentiation within the diploic space or cranial nerve sheath cells during their course through diploe.^[37] These tumors are observed mostly within the first two decades of life and histologically are usually of psammomatous type. From a surgical perspective, when located onto the convexity surgical excision is feasible. Often, the complex reconstruction of the anterior skull base can represent a limit in the case of gross total resection (GTR) of large meningiomas involving also ethmoid and sphenoid bones.

MATERIALS AND METHODS

The authors collected clinical, radiological, intraoperative, postoperative, and histological features of a patient harboring a rare case of left intradiploic fronto-orbito-ethmoidal meningioma. We also performed a systematic review in accordance with preferred reporting items for systematic reviews and meta-analysis guidelines [Figure 1]. A literature search was conducted using PubMed and Scopus databases from 1955 (first reported paper) to 2021. References of the included studies were searched for additional relevant studies. This search was limited to studies in English language. MeSH terms utilized were as follows: (intradiploic OR intraosseous OR calvarial) AND meningioma. Eligibility criteria were limited by the nature of existing literature on intradiploic meningiomas, consisting of only case series and case reports. Data items collected included the following: authors and year of the study, number of patients, sex, signs and/or symptoms, intradiploic meningioma location, treatment modality, histological examination, and clinical outcome. In brief, 128 articles were found after database searching and removal of duplicates. After full-text review, 87 articles were excluded, leaving 41 included studies.

CASE DESCRIPTION

History

A 47-year-old female patient was admitted to our department, following the progressive onset of left eye proptosis lasting for 4 years associated with occasional mild to moderate headache. She did not complain visual acuity decrease nor diplopia in any gaze direction. At the time of her first medical consultation (at another Institution), she

was advised to perform an endoscopic trans-nasal biopsy; this procedure was then performed but the histology was not helpful (no more information about this surgical procedure is available). After this, she decided to have a second opinion with the aim of definitively cure her illness.

Physical examination

On physical examination, there was axial proptosis on the left side, diplopia, with a restriction of the extraocular movements in the superior and medial side. The patient also presented hyposmia. She suffered from an amblyopia dating back to the adolescence in the contralateral eye (visual acuity: 7/10); in the left eye acuity was 8/10. No visual fields defect was detected, and the fundus oculi examination was normal. Rest of the neurological examination was normal. Routine hematological and biochemical tests were normal.

Preoperative imaging

A brain computerized tomography (CT) scan with thin cuts of the orbit and 3D-reconstruction showed a roughly ovoidal lesion centered at the left medial wall and roof of the orbit and invading the left frontal sinus and left ethmoidal body bone. The lesion's maximal diameter was about 5 cm, and it was surrounded by a heterogeneous bone shell filled internally by hypodense tissue with multiple septations [Figure 2]. This lesion compressed and elevated the frontal lobe while, inferolaterally, the ocular bulb was dislocation with evident proptosis. Magnetic resonance imaging (MRI) showed that the mass was T1-weighted iso-intense and T2-weighted heterogeneously hyperintense with an intense postgadolinium enhancement. Medial and superior rectus and superior oblique muscles were compressed and dislocated [Figure 3]. A total body CT scan was negative for other neoplastic localization.

Surgical procedures

Neuronavigation was installed. A sterile surgical field was prepared at the level of the fascia lata to harvest a graft. A bicoronal skin incision with subcutaneous two-layer dissection (to save a vascularized pericranial flap) was performed. A bilateral fronto-basal transfrontal sinus craniotomy was done to expose the tumor. Tumor was found to be completely extra-axial destroying the orbital roof and the orbital medial wall and eroding the ethmoid. Bilateral frontal sinus was invaded by the lesion (especially in the left side). The dura of the left anterior skull base was massively elevated together with the frontal lobe and totally substituted by a thin layer of fibrous tissue. The lesion presented a hard consistence due to an external hyperostotic bone shell. At the inside there was a cavity filled with numerous septations and blood clots. The prior orbita was intact during the microsurgical

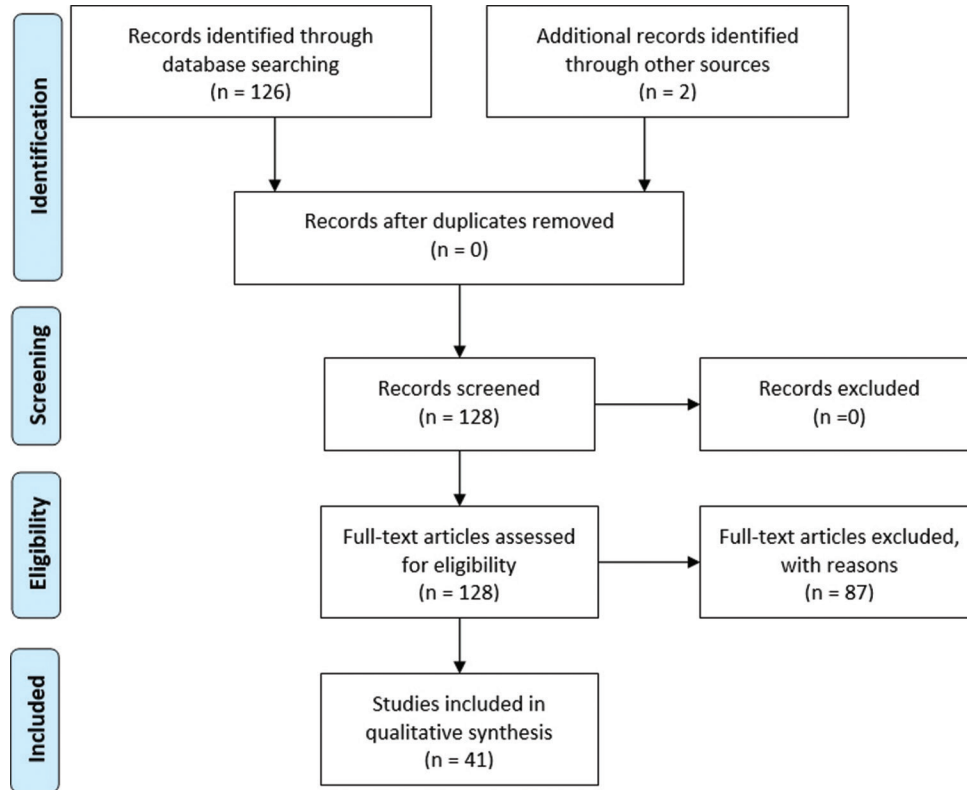


Figure 1: Preferred reporting items for systematic reviews and meta-analysis flow diagram summarizing our searches and selection of studies included in the systematic review of intradiploic meningioma.

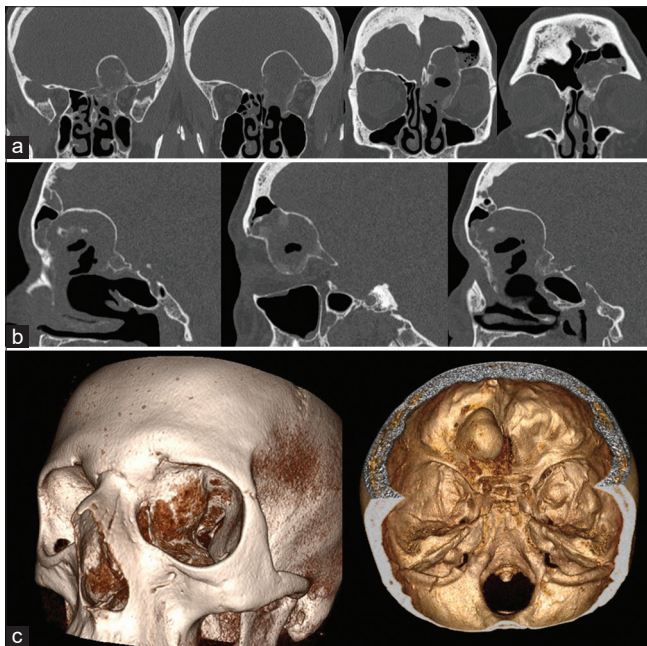


Figure 2: Preoperative coronal (a) and sagittal (b) head computed tomography scan images with bone algorithm and 3D-reconstruction (c) in series showing a left fronto-orbito-ethmoidal intradiploic lesion, with frontal sinus involvement.

dissection with a good cleavage plan. The tumor was removed through a piecemeal technique. Peripheral hyperostotic bone was drilled away to obtain a good control of the bleeding and an efficient removal. Frontal skull base dura was removed and reconstructed with watertight technique with a synthetic patch. Left olfactory nerve was encased in the mass and was not possible to be spared. The tumor was completely removed obtaining a Simpson I resection. Frontal and ethmoidal sinus was closed by free temporal muscle fragments, gel foam, and fibrin glue. Then, orbital roof, medial orbital wall, and ethmoid were reconstructed using the split internal cortical bone of the frontal flaps, to avoid any postoperative pulsatile proptosis. This reconstruction was then covered with fascia lata and fibrin glue. Finally, the whole anterior skull-base until the planum sphenoidale was covered and sealed up with a vascularized pericranial layer. The bony defects of the frontal craniotomy were corrected using a methyl-methacrylate paste. A lumbar drain was placed to prevent any cerebrospinal fluid (CSF) leak (for a total of 8 days).

Histological examination

The histological analysis reported a metaplastic meningioma (the World Health Organization [WHO] Grade I) with

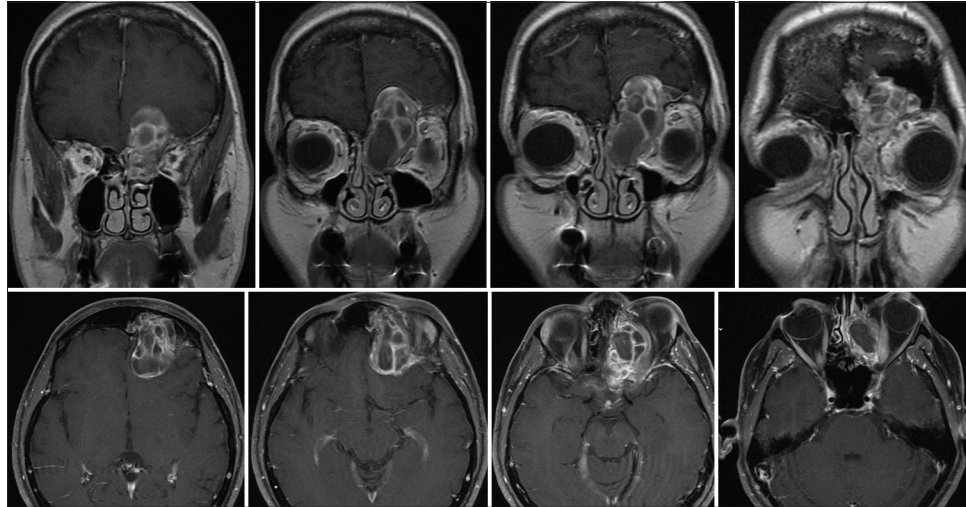


Figure 3: Preoperative coronal (up) and axial (down) brain T1-weighted Magnetic resonance imaging images after Gadolinium administration showing a left inhomogeneous multilobulated intradiploic fronto-orbito-ethmoidal lesion.

extensive ossification with a bone angioectasia infiltration (immunostaining showed Epithelial Membrane Antigen +, Vimentine +, S100-, CKpool -, CD4-, Progesterone -) [Figure 4].

Postoperative course and postoperative imaging

At the recovery from the general anesthesia, the patient was drowsy and strongly apathetic. CT scan demonstrated a contusion and reactive edema at the basal frontal lobe. Intensive care stay was prolonged, and patient gradually recovered to a satisfying state of consciousness after eight days. Postoperative CT scan showed a total removal of the lesion, with an optimal reconstruction of the medial wall and the roof of the left orbit, in the absence of complications [Figure 5]. At the discharge, patient was neurologically intact and after 3 months got back to her job. Cosmetic outcome was particularly good, and the proptosis showed an evident reduction.

Late rhinoliquorrhea management

About 3 months from the previous CT scan control, the patient presented to the local emergency room for acute recurrence of rhinoliquorrhea. According to the COVID-19 re-organization model adopted by the Lombardy region, the patient was transferred to the neurosurgical reference hub in the area. When she arrived at the Neurosurgical department of the “Spedali Civili” Hospital in Brescia, the patient underwent a brain CT and MRI that showed the presence of pneumocephalus with a small defect in the posterior ethmoidal plane close to the sphenoparietal suture with pneumocephalus [Figure 6]. After examining the radiological images, we decided to perform a combined transcranial and transsphenoidal approach. Such approach,

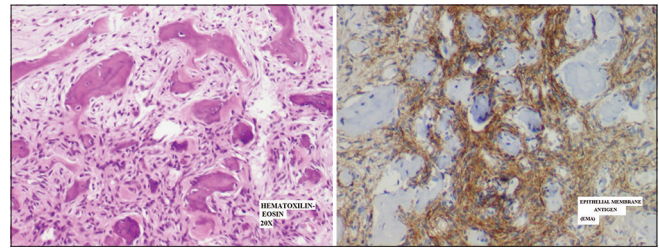


Figure 4: Routine histology showing neoplastic proliferation of medium-sized spindle tumor cells with no atypia, forming fascicles in metaplastic bone tissue and spreading in normal trabecular bone (up); neoplastic cells with epithelial membrane antigen immunoreactivity (Epithelial Membrane Antigen) (down).

in our experience, yields to a higher successful rate. Under balanced general anesthesia, the previous bicoronal surgical incision was opened. After removing the bone flaps, no evident extradural CSF collection was found. The bone flaps and all the reconstruction materials (i.e., methyl methacrylate and orbital roof titanium mash) were removed and after meticulous exploration a defect at the margin of the duroplasty with the dura mater was found. The synthetic patch was completely removed, and the underlying subdural space was filled with a graft of abdominal fat tissue (para-umbilical incision). The dura was reconstructed with a free pericranium (taken from the calvarium posterior to the craniotomy) with a watertight technique and reinforced with fibrin glue. The reconstruction of the anterior skull base appeared intact except in its posterior ethmoidal portion. A 5 mm gap/defect was found at the level of the left ethmoidoparietal suture. The adjacent pericranium was detached to adequately expose the defect and the surrounding bone. The posterior ethmoidal space, after thorough cleaning, was filled with free fatty tissue (till the intact periorbital plane)

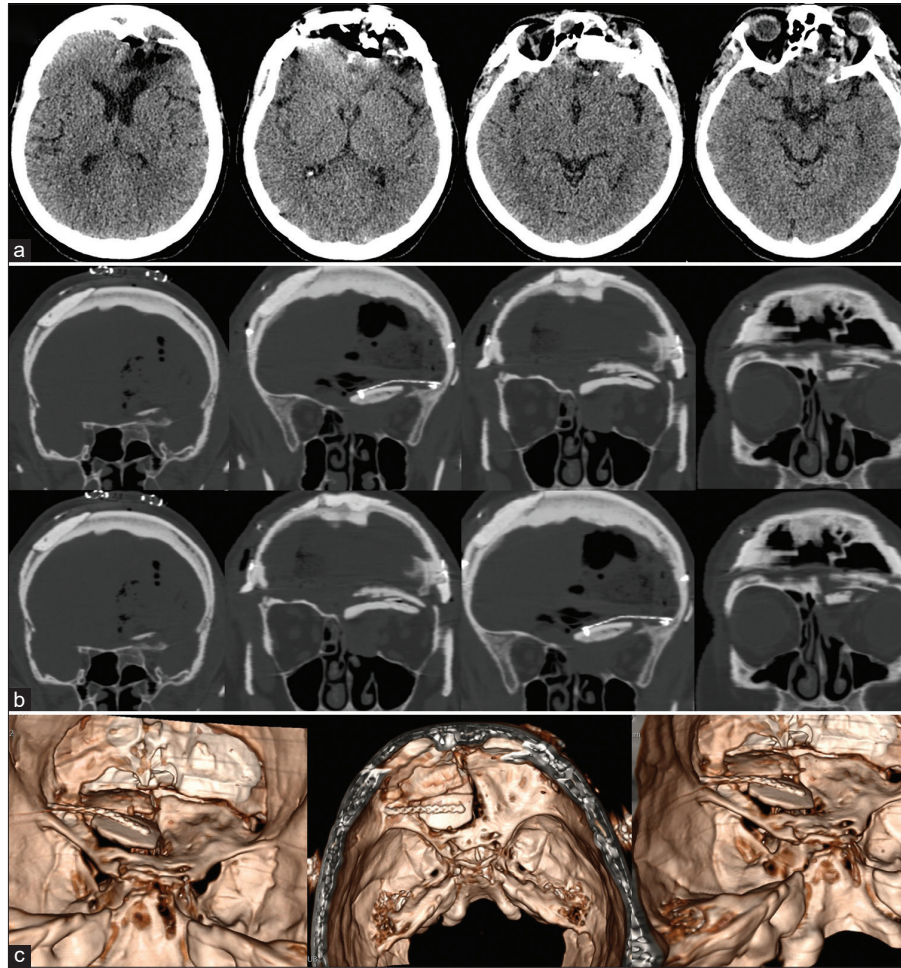


Figure 5: Postoperative axial head computed tomography scan images in series (a), with bone algorithm (b) and with 3D-reconstruction (c) showing a proper reconstruction of the left orbital roof and the medial orbital wall with split calvarial bone graft and bone defect reconstruction with methyl-methacrylate paste, obtaining good cosmetic and functional results.

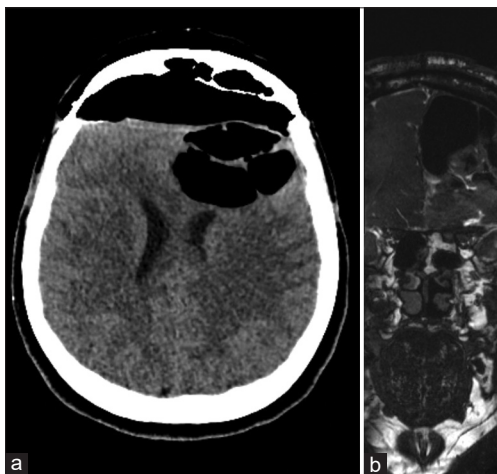


Figure 6: Axial head computed tomography scan (a) and coronal T2-CISS 3D magnetic resonance imaging (b) showing the presence of pneumocephalus with a small defect in the posterior ethmoidal plane close to the sphenoidal suture with pneumocephalus.

laterally and medially to the mucosal graft and sealed with one layer of free pericranium. The margins of pericranial layer (positioned in the previous intervention) dehiscent have been incised and removed. The margins were slightly detached from the bone plane for about 3 mm; a first patch of free pericranium was placed, in contact with the free bone margin and to cover the fat layer. The pedicled pericranium was then repositioned to cover the whole floor of the left anterior cranial fossa and a second patch of free pericranium was applied to it by superimposing it on the vital pericranium (with multilayer wafer technique). The whole construct was then sealed with fibrin glue. The epidural space was filled with free fatty abdominal tissue. Through an endoscopic transnasal approach the free abdominal flap fat in the sphenoidal suture is easily identified. The nasal mucosa bordering the defect was removed and vital bone tissue exposed. A pedicled naso-septal flap, previously harvested, was then used to further seal and support the reconstruction.

Silicone coated pads were positioned to make the flap adhere better to hold the construct (the endonasal swabs will then be removed 4 days after surgery). The frontal bone operculum was positioned and fixed with plates and screw (Synthes Matrix). Postoperative course was uneventful. A control head CT scan showed good surgical results and resolution of the pneumocephalus. An endoscopic exploration showed good vitality and adhesion of the mucosal flap. After prophylactic therapy (vancomycin + cephalosporin for 10 days), the patient was discharged at home neurologically intact. The 3-month postoperative MRI showed no residual or recurrent disease [Figure 7].

RESULTS

A total of 128 published studies were identified through our detailed searches from 1955 to 2021. After a detailed examination of the titles, abstracts, and contents of these studies, 87 were rejected from our systematic review because they were not in English language, not purely intradiploic calvarial meningiomas, or did not include accurate data. Our case was not included in this systematic review. A summary of patients' characteristics in selected papers are reported in [Table 1].^[2-43] A total of 41 studies were selected, including 59 patients, 32 females (54.2%), 26 males (44%), and one patient of unknown sex, with a female/male ratio of 1.2/1. The mean age of the patients is of 47.69 years, ranging from 3 to 84 years. Signs and/or neurological symptoms of onset include exophthalmos in 15 out of 59 patients (25.4%), headache in 13 out of 59 patients (22%), diplopia in four out of 59 patients (6.7%), ptosis in three out of 59 patients (5%), motor deficits in 2/59 patients (3.4%), and behavior disturbances in only one patient (1.7%), while 23 out of 59 patients were asymptomatic (38.9%). The most frequent localization is in the frontal bone in 20 out of 59 patients (33.9%), parietal in 16/59 patients (27.1%), orbital in 14/59 patients (23.7%), sphenoid in 7/59 patients (11.9%), temporal in 6/59 patients (10.2%), and occipital in 3/59 patients (5%). Only seven out of 59 patients (11.9%) presented a complex intradiploic meningioma located in fronto-orbito-ethmoidal region like our case. In almost all patients (57 out of 59) a GTR was performed (96.6%) and only in two patients (3.4%) a subtotal resection was achieved. Histological examination showed a meningothelial subtype in 18 out of 59 patients (30.5%), transitional in ten out of 59 patients (16.9%), microcystic in nine out of 59 patients (15.2%), psammomatous in six out of 59 patients (10.2%), fibroblastic in 1/59 patients (1.7%), chordoid in 1/59 patients (1.7%), atypical meningioma in two out of 59 patients (3.4%), anaplastic meningioma in 1/59 patients (1.7%), and malignant meningioma without specifying the subtype in 1/59 patients (1.7%), while in ten out of 59 patients (16.9%) the subtype was not specified. A total of 48 out of 59 patients

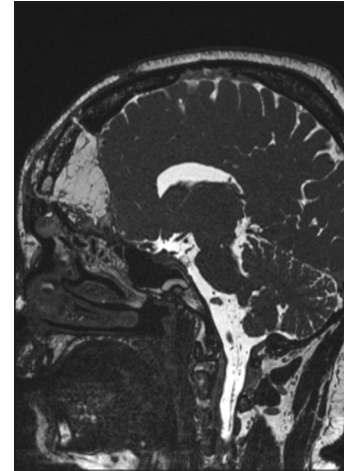


Figure 7: Three-month postoperative sagittal T2-CISS 3D magnetic resonance imaging showing the posterior ethmoidal space, filled with free fatty tissue and no residual or recurrent disease.

presented a good recovery after surgery (81.3%), one patient showed only persistent exophthalmos, one patient developed a wound infection with CSF leak, one patient underwent reoperation due to meningioma recurrence, and another one patient presented a persisting gait disturbance, with an overall postoperative complication rate of 1.7%.

DISCUSSION

A localization of meningiomatous tissue at the level of the orbita, it is most often due to secondary invasion of the orbit or of the orbital walls by a tumor starting from the meninges enveloping the brain, especially at the level of the anterior cranial fossa or of the sphenoid lesser wing.^[31] Winkler in 1904 first described a meningioma originating from extradural location and extradural meningioma arising in the skull is usually referred as calvarial, intraosseous, or intradiploic location. Intraosseous meningioma denotes a subset of extradural meningioma arising in bone and accounts for about two-third of extradural meningioma. According to the literature, frontoparietal and orbital regions are the most common intraosseous meningioma locations.^[37] Lang *et al.*^[21] classified primary extradural meningioma (PEM) into three types: Type 1 (purely extracalvarial), Type 2 (purely calvarial), and Type 3 (calvarial with extracalvarial extension). Types 2 and 3 can be subclassified as B (convexity) and C (skull base). According to the above-mentioned classification, our case can be classified as Type 2 C. Cirac *et al.*^[7] reported that psammomatous variety is the most common histological subtype, but the results of our systematic review showed that the most frequent histology is the meningothelial subtype. At our knowledge, the current is the first case of intradiploic metaplastic meningioma. There are different theories as to the origin of intradiploic meningiomas. On the one

Table 1: Schematic summary of the characteristics of 59 patients affected by intradiploic meningioma, in the context of our systematic review.

Authors and year	Age (Years)	Sex	Signs and/or symptoms	Location	Treatment	Histopathological evaluation	Outcome
Reale <i>et al.</i> 1978 ^[31]	19	Male	Exophthalmos	Medial and superior wall right orbit	GTR (right frontal flap)	Endotheliomatous and psammomatous meningioma	Good recovery
Pompili <i>et al.</i> 1983 ^[29]	40	Male	Exophthalmos	Upper part left orbita	GTR (extradural subfrontal approach)	Psammomatous meningioma	Good recovery
Oka <i>et al.</i> 1989 ^[28]	79	Female	Asymptomatic	vertex	GTR (skin flap over the vertex)	Transitional meningioma	Good recovery
	73	Female	Asymptomatic	Vertex	GTR (bilateral parietal craniotomy)	Transitional meningioma	Good recovery
Van Tassel <i>et al.</i> 1991 ^[35]	41	Female	Asymptomatic	Right sphenoid bone	GTR	Meningothelial meningioma	Not reported
	not reported	Female	Not reported	Left lateral orbit	GTR	Meningothelial meningioma	Not reported
Kulali <i>et al.</i> 1991 ^[19]	50	Male	Asymptomatic	Right occipital	GTR	Transitional meningioma	Good recovery
	29	Male	Asymptomatic	Right parietal	GTR	Meningothelial meningioma	Good recovery
	30	Male	Asymptomatic	Left frontal	GTR	Meningothelial meningioma	Good recovery
Nakao <i>et al.</i> 1991 ^[27]	68	Female	Mild motor weakness right lower extremity	Left parietal	GTR	Meningothelial meningioma	Good recovery
Halpin <i>et al.</i> 1991 ^[14]	19	Male	Exophthalmos	Body and wings of the sphenoid bone	GTR (bicoronal scalp flap)	Transitional meningioma	Good recovery
	9	Female	Exophthalmos	Wall right orbit	GTR (bicoronal scalp flap)	Transitional meningioma	Good recovery
Ghobashy <i>et al.</i> 1994 ^[13]	65	Female	Generalized dull headaches	Right frontal	GTR (right frontal craniotomy)	Transitional meningioma	Good recovery
Prado <i>et al.</i> 1994 ^[30]	not reported	Male	Asymptomatic	Frontal	GTR	Intraosseous meningioma	Good recovery
Monteiro <i>et al.</i> 1996 ^[23]	30	Male	lump slightly painful	Left parietal	GTR (left parietal skin flap)	Psammomatous meningioma	Good recovery
Muthukumar <i>et al.</i> 1997 ^[25]	55	Male	Asymptomatic	Right parietal	GTR	Meningothelial meningioma	Good recovery
	50	Male	Generalized Dull headaches	Left temporo-parietal	GTR	Meningothelial meningioma	Not reported
	65	Male	Asymptomatic	Left frontal	GTR	Meningothelial meningioma	Not reported
	15	Female	Vague headache	Right temporal	GTR (right temporal scalp flap)	Psammomatous meningioma	Not reported
Anegawa <i>et al.</i> 1999 ^[2]	77	Female	Transient episodes of left-sided weakness, vomiting, left-sided ptosis, lethargy	Bilateral parietal	GTR (external decompressive craniectomy)	Meningothelial meningioma	Good recovery

(Contd...)

Table 1: (Continued).

Authors and year	Age (Years)	Sex	Signs and/or symptoms	Location	Treatment	Histopathological evaluation	Outcome
Cirak <i>et al.</i> 2000 ^[7]	12	Female	Exophthalmos, occasional diplopia	Fronto-orbitonasal	GTR (bicoronal skin incision)	Psammomatous meningioma	Only exophthalmos
Lang <i>et al.</i> 2000 ^[21]	41	Female	Headache	Right greater sphenoid wing	GTR	Purely calvarial meningioma	Good recovery
	49	Female	Asymptomatic	Left frontal bone; superior & lat orbital wall; left greater sphenoid wing	GTR	Purely calvarial meningioma	Good recovery
Muzumdar <i>et al.</i> 2001 ^[26]	63	Female	Headache and exophthalmos, chemosis left eye	Both frontoparietal convexity and superolateral aspect of the left orbit	GTR (left frontoparietal craniotomy)	Meningothelial meningioma	Good recovery
Desai <i>et al.</i> 2004 ^[10]	12	Male	Exophthalmos	Left orbital roof	GTR (basal subfrontal craniotomy)	Psammomatous meningioma	Good recovery
Al-khawaja <i>et al.</i> 2007 ^[11]	50	Male	Headache	Left parasagittal	GTR	Meningothelial meningioma	Good recovery
Bou-Assaly <i>et al.</i> 2007 ^[5]	not reported	Not reported	Progressive vision loss and significant Exophthalmus	Frontal, zygomatic, sphenoid and temporal	GTR (left fronto-temporal craniectomy)	Intraosseous meningioma	Good recovery
Borkar <i>et al.</i> 2008 ^[4]	40	Male	Exophthalmos	Left frontal and left orbital roof	GTR (bifrontal craniotomy)	Transitional meningioma	Good recovery
Iannelli <i>et al.</i> 2008 ^[16]	3	Female	Asymptomatic	Left pterional	GTR	Transitional meningioma	Good recovery
Sujit Kumar <i>et al.</i> 2009 ^[20]	46	Female	Not reported	Left parietal Parasagittal	STR	Malignant meningioma	Wound infection with CSF leak
Yener <i>et al.</i> 2009 ^[40]	78	Male	Asymptomatic	Right parietal	GTR	Meningothelial meningioma	Good recovery
Sambasivan <i>et al.</i> 2010 ^[32]	13	Male	Asymptomatic	Right temporal	GTR	Intradiploic meningioma	Good recovery
Mukherjee <i>et al.</i> 2010 ^[24]	55	Male	Headache, exophthalmos	Large calvarial mass crossing the midline and with extension To the right orbit	GTR (bicoronal skin incision)	Atypical meningioma	Reoperated Twice for small recurrences at bony edges.
Hong <i>et al.</i> 2010 ^[15]	52	Male	Asymptomatic	Parietal	GTR	Intraosseous meningioma	Good recovery
	73	Male	Asymptomatic	Occipital	GTR	Anaplastic meningioma	Good recovery
Yilmaz <i>et al.</i> 2010 ^[41]	41	Male	Headache	Frontal	GTR (right frontal craniectomy)	Meningothelial meningioma	Not reported
Eras <i>et al.</i> 2011 ^[11]	16	Female	Asymptomatic	Right parietal and posterior frontal	GTR (right frontoparietal craniectomy)	Transitional meningioma	Good recovery
Khalatbari <i>et al.</i> 2011 ^[18]	14	Female	Exophthalmos, diplopia	Right orbital Roof	GTR (bicoronal skin incision)	Transitional meningioma	Good recovery

(Contd...)

Table 1: (Continued).

Authors and year	Age (Years)	Sex	Signs and/or symptoms	Location	Treatment	Histopathological evaluation	Outcome
Cruz et al. 2013 ^[9]	43	Female	ptosis	Right orbital roof and lateral Portion of the frontal	Gtr (coronal approach)	Meningothelial meningioma	Not reported
Kariyattil et al. 2014 ^[17]	40	Female	Hedeache and frontal swelling	Left frontal	GTR (left frontal craniotomy)	Meningothelial meningioma	Good recovery
Yun et al. 2014 ^[4]	65	Female	Asymptomatic	Right frontal	GTR	Atypical meningioma	Good recovery
Velazquez Vega et al. 2015 ^[36]	60	Male	Asymptomatic	Right frontal	GTR	Microcystic meningioma	Good recovery
	62	Male	Asymptomatic	Left frontal	GTR	Microcystic meningioma	Good recovery
	56	Female	Previous right optic Nerve meningioma and Radiation	Right frontal	GTR	Microcystic meningioma	Good recovery
	68	Female	Asymptomatic	Right parietal	GTR	Microcystic meningioma	Good recovery
	71	Female	Asymptomatic	Right frontal	GTR	Microcystic meningioma	Good recovery
	71	Female	Diplopia	Left parietal	GTR	Microcystic meningioma	Good recovery
	79	Female	Asymptomatic	Left parietal	GTR	Microcystic meningioma	Good recovery
	79	Female	Diplopia, exophthalmos, intermittent Ptosis and visual field Defects	Right sphenoid bone	GTR	Microcystic meningioma	Good recovery
	84	Female	Asymptomatic	Left frontal	GTR	Microcystic meningioma	Good recovery
Vital et al. 2015 ^[38]	62	Female	Headache	Right parietal	GTR (right parietal incision and craniotomy)	Meningothelial meningioma	Good recovery
Asil et al. 2015 ^[3]	64	Male	Pain And swelling on the right side of head	Right frontotemporal	GTR	Intradiploic meningioma	Good recovery
Verma et al. 2015 ^[37]	16	Female	Exophthalmos, headache	Right orbital roof	GTR (right fronto-temporal craniotomy with orbitotomy)	Intradiploic meningioma	Good recovery
Vlychou et al. 2016 ^[39]	63	Female	Pain in the right eye	Right frontal	STR	Fibroblastic meningioma	Good recovery
Caruso et al. 2017 ^[6]	62	Male	Exophthalmos	Lateral wall of the orbit and the greater wing of the sphenoid	GTR (left frontopterional approach)	Meningothelial meningioma	Good recovery

(Contd...)

Table 1: (Continued).

Authors and year	Age (Years)	Sex	Signs and/or symptoms	Location	Treatment	Histopathological evaluation	Outcome
Zhang <i>et al.</i> 2017 ^[43]	48	Male	Headache	Frontal	GTR (bilateral frontal craniotomy)	Intraosseus meningioma	Good recovery
Sundblom <i>et al.</i> 2018 ^[34]	39	Female	Headache, bilateral anosmia, bilateral papilledema, diminished visual fields bilaterally	Frontal, Parietal, and temporal bones on both sides	GTR (bifrontal and right-sided tumor resection via a combined approach)	Chordoid meningioma	Good recovery
Mankotia <i>et al.</i> 2018 ^[22]	27	Female	headache, exophthalmos, visual blurring in her left eye	left temporal	GTR (left frontotemporal orbitozygomatic craniotomy)	Intradiploic meningioma	Good recovery
Satyarthee 2018 ^[32]	40	Male	headache, gait imbalance, bilateral papilledema	occipital	GTR (midline suboccipital craniectomy)	Meningothelial meningioma	Persisting minimal gait disturbance
Present Case	47	Female	exophthalmos, diplopia, headache, hyposmia	left fronto-orbital and left ethmoidal	GTR (bicoronal skin incision and bilateral fronto-basal craniotomy with orbital roof and medial wall orbital reconstruction)	Metaplastic	Good recovery

GTR: Gross Total Resection, STR: Sub-total resection

hand, it is thought that they arise from arachnoid cell rests inappropriately laid down during embryonal life or deposited in unusual sites by trauma and dural tears. On the the other hand, they may arise from the sheath cell of cranial nerves as they course through the diploic space or their origin may be due to cellular dedifferentiation within the diploe; a similar mechanism is proposed for the equally uncommon cutaneous meningioma.^[7] The common age of presentation was in the early second decade of life and although intraosseous meningiomas commonly involve the calvarial bone, they rarely occur in the orbital roof and sphenoid bone.^[1,10]

Intradiploic meningiomas of the orbital roof are more frequent in males and in young people.^[29] These tumors may be considered as a subgroup of intraosseous meningiomas and it does not fit any of the intraorbital meningiomas described by Craig and Gogela.^[8] PEM grows slowly over time and produces signs and symptoms due to compression of adjacent neural structures, especially exophthalmos is the predominant symptom.^[22] In addition, intraosseous PEMs appear on tomography scans

as expansile masses or provoking osteolytic lesions that mimic metastatic disease.^[9]

X-ray, head CT, and brain MRI are methods of radiological screening in diagnosing intradiploic meningioma. Radiologically intradiploic meningiomas are typically either osteoplastic or osteolytic, and although the majority are osteoblastic, extremely rarely are osteolytic or very extremely have a mixed pattern. These can present with opacity of the orbital roof on X-ray skull study. The osteolytic subtype of intradiploic meningiomas is more likely to be malignant than the osteoblastic subtype. Intradiploic meningiomas should be considered in the differential diagnosis of patients presenting with osteoblastic or osteolytic skull lesions.^[37] The differential diagnosis of the osteoclastic lesion should include chondroma, chondrosarcoma, hemangioma, epidermal cyst, eosinophilic granuloma, metastasis, and fibrous dysplasia, whereas the radiological differential diagnosis of osteoblastic lesions should include metabolic diseases including osteoma, hyperparathyroidism, metastasis and A and D hypervitaminosis. Head CT scan can be used

to best define the margins of meningiomas in the bone algorithm and brain MRI can be used to identify adherent tissue involvement.^[3] Particularly, MRI is helpful to evaluate the extraosseous extension and the soft tissue component. It is like the primary intradural meningiomas except for the dural tail sign, which could not be seen in intradiploic meningiomas.^[43] Furthermore, scintigraphy and positron emission tomography CT (PET-CT) can be used for the differential diagnosis, with bone scintigraphy that shows an increased metabolic activity of the specific bone region when positive.^[3]

Tumor excision with wide surgical resection and meticulous bony reconstruction is the primary choice for treatment in symptomatic patients^[22] and in this kind of tumor surgery, if the shell of the tumor facing the dura mater is not intact, the most important rule is to prevent postoperative CSF leakage.^[7] This holds especially true for our case, given that the large dimension and the infiltration of multiple compartments (namely the roof and medial wall of the orbit, the ethmoid, and the frontal sinus) set a particularly high risk of CSF fistula. More, the absence of a dura sheet between the tumor and the basal frontal brain provoked a superficial damage to fronto-basal cortex. Nevertheless, these factors did not prevent us to accomplish a Simpson I resection and avoid CSF leak. Although most intradiploic meningiomas are benign, they could present malignant growth, which might lead to erosion of the skull. Therefore, in most cases, total resection of lesions seems to be impossible, and the residual tumor should be treated with radiation therapy and chemotherapy, especially for the patients who had malignant or atypical features on histological examination. The present chemotherapeutic agents mainly include molecule-targeted drugs (imatinib, sunitinib, and vatalanib), cytotoxic chemotherapeutics (hydroxyurea, irinotecan, and temozolomide), hormonal inhibitors (targeting estrogen and progesterone), and other drugs. Hence, postoperative imaging will become vital for monitoring tumor recurrence or progress and prolonged follow-up of patients will be necessary.^[43]

CONCLUSION

Primary intradiploic meningiomas are rare tumors, which are used to describe the subset of extradural meningiomas that arise in the skull. To the best of our knowledge, only seven cases of complex intradiploic fronto-orbito-ethmoidal meningioma were reported in the literature. Regular monitoring is essential in the management of intradiploic meningioma and surgical treatment with wide incision of the lesion is the goal of the primary therapy. We share this successfully treated case to add to the overall clinical experience in the management of this rare subtype tumor, with the hope that more studies are conducted to further

address the mechanism of intradiploic meningiomas development.

Acknowledgments

The authors thank Professor Francesco Doglietto for the surgical management and supervision of the clinical case.

Ethical approval

All procedures in studies involving human participants were in accordance with the ethical standards of the institutional and/or national research committee and with the 1964 Helsinki declaration and its later amendments or comparable ethical standards.

Declaration of patient consent

The authors certify that they have obtained all appropriate patient consent.

Financial support and sponsorship

Nil.

Conflicts of interest

There are no conflicts of interest.

REFERENCES

1. Al-khawaja D, Murali R, Sindler P. Primary calvarial meningioma. Case reports. *J Clin Neurosci* 2007;14:1235-9.
2. Anegawa S, Hayashi T, Torigoe R. Diffuse calvarial meningioma. *J Neurosurg* 1999;90:970-3.
3. Asil K, Aksoy YE, Yaldiz C. Primary intraosseous meningioma mimicking osteosarcoma: Case report. *Turk Neurosurg* 2015;25:174-6.
4. Borkar SA, Tripathi AK, Satyarthee GD. Fronto-orbital intradiploic transitional meningioma. *Neurol India* 2008;56:205-6.
5. Bou-Assaly W, Illner A, Mosier KM. Intra-osseous meningioma of the orbit: An unusual presentation. *Eur Radiol* 2007;17:2192-4.
6. Caruso R, Fini G, Pesce A. A primary intraosseous cystic meningioma: Case report. *Int J Surg Case Rep* 2017;37:189-92.
7. Cirak B, Guven MB, Ugras S. Fronto-Orbitonasal intradiploic meningioma in a child. *Pediatr Neurosurg* 2000;32:48-51.
8. Craig WM, Gogela LJ. Meningioma of the optic foramen as a cause of slowly progressive blindness: Report of three cases. *J Neurosurg* 1950;7:44-8.
9. Cruz AA, Rota LM, Trevenzol FP. Hyperplastic intradiploic meningiothelial tissue in the orbital roof mimicking metastatic disease. *Ophthal Plast Reconstr Surg* 2013;29:1.
10. Desai KI, Nadkarni TD, Bhayani RD. Intradiploic meningioma of the orbit: A case report. *Neurol India* 2004;52:380-2.
11. Eras MA, Tari R, Ozturk G. Intraosseous meningioma

- mimicking osteosarcoma in an adolescent: A case report. *Turk Neurosurg* 2011;21:663-5.
12. Germano IM, Edwards MS, Davis RL. Intracranial meningiomas of the first two decades of life. *J Neurosurg* 1994;80:447-53.
 13. Ghobashy A, Tobler W. Intraosseous calvarial meningioma of the skull presenting as a solitary osteolytic skull lesion: Case report and review of the literature. *Acta Neurochir (Wien)* 1994;129:105-8.
 14. Halpin SF, Britton J, Wilkins P. Intradiploic meningiomas. A radiological study of two cases confirmed histologically. *Neuroradiology* 1991;33:247-50.
 15. Hong B, Hermann EJ, Klein R. Surgical resection of osteolytic calvarial lesions: clinicopathological features. *Clin Neurol Neurosurg* 2010;112:865-9.
 16. Iannelli A, Pieracci N, Bianchi MC. Primary intra-diploic meningioma in a child. *Childs Nerv Syst* 2008;24:7-11.
 17. Kariyattil R, Govindaraju V, Hamid RS. Primary extradural meningioma presenting as frontal sinusitis with extensive bony changes: Case report. *SQU Med J* 2014;14:e566-70.
 18. Khalatbari MR, Borghai-Razavi H, Moharamzad Y. Intradiploic orbital roof meningioma with pneumosinus dilatans in a child: A case report and review of the literature. *Pediatr Neurosurg* 2011;47:66-71.
 19. Kulali A, İlçayto R, Rahmanli O. Primary calvarial ectopic meningiomas. *Neurochirurgica (Stuttg)* 1991;34:174-7.
 20. Kumar GS, Chacko G, Chacko AG. Multiple extracranial metastases from intradiploic meningioma. *Neurol India* 2009;57:96-7.
 21. Lang FF, Kenneth Macdonald O, Fuller GN. Primary extradural meningiomas: A report on nine cases and review of the literature from the era of computerized tomography scanning. *J Neurosurg* 2000;93:940-50.
 22. Mankotia DS, Singh SK, Borkar SA. Primary giant sphenoidal intradiploic meningioma. *Asian J Neurosurg* 2018;13:157-60.
 23. Monteiro JT, Baptista AE, Trabulo AS. Intradiploic meningioma of the skull: Case report and review of the literature. *Neurocirugia* 1996;7:129-32.
 24. Mukherjee KK, Salunke P, Chhabra R. Temporary bilateral external carotid artery clamping to reduce blood loss during removal of calvarial meningioma: A technical note. *Br J Neurosurg* 2011;25:127-9.
 25. Muthukumar N. Primary calvarial meningiomas. *Br J Neurosurg* 1997;11:388-92.
 26. Muzumdar DP, Vengsarkar US, Bhatjiwale MG. Diffuse calvarial meningioma: A case report. *J Postgrad Med* 2001;47:116-8.
 27. Nakao N, Kubo K, Moriwaki H. Multiple growths of primary calvarial meningiomas. *Neurosurgery* 1991;29:3.
 28. Oka K, Hirakawa K, Yoshida S. Primary calvarial meningiomas. *Surg Neurol* 1989;32:304-10.
 29. Pompili A, Caroli F, Cattani F. Intradiploic meningioma of the orbital roof. *Neurosurgery* 1983;12:5.
 30. Prado JA, Sener RN, Jinkins JR. Primary intraosseous calvarial meningioma. *Comput Med Imaging Graphics* 1994;18:467-8.
 31. Reale F, Delfini R, Cintonio M. An intradiploic meningioma of the orbital roof: Case report. *Ophtalmologica* 1978;177:82-7.
 32. Sambasivan M, Kumar PS, Mahesh S. Primary intradiploic meningioma in the pediatric age-group. *J Pediatr Neurosci* 2010;5:76-8.
 33. Satyarthee GD. Primary extradural meningioma of posterior fossa associated with acquired chiari malformation: A short review. *Asian J Neurosurg* 2018;13:421-4.
 34. Sundblom J, Nowinski D, Casar-Borota O. Removal of giant intraosseous meningioma followed by cranioplasty using a custom-made bioceramic implant: Case report. *J Neurosurg* 2018;131:735-9.
 35. Van Tassel P, Lee YY, Ayala A. Case report 680. *Skeletal Radiol* 1991;20:383-6.
 36. Vega JE, Rosenberg A. Microcystic meningioma of the calvarium: A series of 9 cases and review of the literature. *Am J Surg Pathol* 2015;39:4.
 37. Verma SK, Satyarthee G, Borkar SA. Orbital roof intradiploic meningioma in a 16-year-old girl. *J Pediatr Neurosci* 2015;10:51-4.
 38. Vital RB, Filho PT, Lapate RL. Calvarial ectopic meningotheelial meningioma. *Int J Surg Case Rep* 2015;10:69-72.
 39. Vlychou M, Inagaki Y, Stacey R. Primary intraosseous meningioma: An osteosclerotic bone tumour mimicking malignancy. *Clin Sarcoma Res* 2016;6:14.
 40. Yener U, Bayrakli F, Vardere E. Intradiploic meningioma mimicking calvarial metastasis: Case report. *Turk Neurosurg* 2009;19:297-301.
 41. Yilmaz A, Musluman M, Aydin Y. Primary osteolytic intraosseous meningioma of the frontal bone. *Neurol I Neurochirurg Polska* 2010;44:415-8.
 42. Yun JH, Lee SK. Primary osteolytic intraosseous atypical meningioma with soft tissue and dural invasion: Report of a case and review of literatures. *J Korean Neurosurg Soc* 2014;56:509-12.
 43. Zhang S, Zhang J, Chen J. Frontal intradiploic meningioma with progressive intracranial invasion. *Medicine* 2017;96:34.

How to cite this article: Crea A, Grimod G, Scalia G, Verlotta M, Mazzeo L, Rossi G, *et al.* Fronto-orbito-ethmoidal intradiploic meningiomas: A case study with systematic review. *Surg Neurol Int* 2021;12:485.