

# CASE REPORT

Nagoya J. Med. Sci. **81**. 711–716, 2019  
doi:10.18999/nagjms.81.4.711

## Successful management of extensive bowel resection without intestinal continuity: a case report

Koichi Mohri, Eiji Takeuchi, Hideo Miyake, Hidemasa Nagai, Yuichiro Yoshioka, Masataka Okuno, and Norihiro Yuasa

*Department of Gastrointestinal Surgery, Japanese Red Cross Nagoya First Hospital, Nagoya, Japan*

### ABSTRACT

Patients with intestinal ischemia associated with acute aortic dissection often require emergent bowel resection, which results in serious complications. We present a case of successful surgical management of extensive bowel necrosis caused by acute aortic dissection. A 42-year-old man underwent emergent subtotal resection of the small intestine, right colectomy, tube gastrostomy, and transverse colostomy; however, intestinal continuity was not restored. He developed two major postoperative complications: unconsciousness due to metabolic alkalosis caused by massive discharge from the gastrostomy and jaundice due to bile salt depletion caused by disruption of the enterohepatic circulation. His serum bilirubin levels decreased after the infusion of gastric discharge through gastrostomy into the transverse colon through the colostomy; thereafter, a second operation was performed to restore gastrointestinal continuity. Overall, patients undergoing massive bowel resection without intestinal continuity require careful management of electrolytes and bile salt.

Keywords: bowel necrosis, short bowel syndrome, aortic dissection, bile salt depletion, intestinal continuity

#### Abbreviations:

ICU: intensive care unit

POD: postoperative day

This is an Open Access article distributed under the Creative Commons Attribution-NonCommercial-NoDerivatives 4.0 International License. To view the details of this license, please visit (<http://creativecommons.org/licenses/by-nc-nd/4.0/>).

### INTRODUCTION

Patients presenting with acute aortic dissection without serious complications can usually be managed with conservative treatment focused on the use of antihypertensives. On the contrary, patients with ischemic organ injury require surgical treatment. The mortality rate of patients with intestinal ischemia associated with acute aortic dissection has been reported to be 36–90%.<sup>1,2</sup> Extensive intestinal resection often results in short bowel syndrome. The severity of functional outcomes and complications associated with short bowel syndrome depend on the length of the

---

Received: February 12, 2019; accepted: April 3, 2019

Corresponding Author: Norihiro Yuasa, MD, PhD

Department of Surgery, Japanese Red cross Nagoya First Hospital, 3-35 Michishita-cho, Nakamura-ku, Nagoya 453-8511, Japan

Tel: +81-52-481-5111, Fax: +81-52-482-7733, E-mail: m\_ri619@yahoo.co.jp

residual intestine, the anatomical component involved, and intestinal continuity. Surgical procedures without intestinal continuity can frequently cause several complications including impaired consciousness and hyperbilirubinemia. We report the case of a patient who underwent successful surgical management of acute extensive bowel necrosis associated with acute aortic dissection.

## CASE PRESENTATION

A 42-year-old man was admitted to a local hospital for sudden-onset back pain. Contrast-enhanced computed tomography showed an aortic dissection (Stanford type B). Following 10 days of conservative therapy, he was transferred to our hospital and presented with shock and abdominal pain. He was unconscious, and showed marked abdominal distention and tenderness with blood pressure of 81/45 mmHg and a pulse rate of 84/min. Blood tests showed elevated inflammatory biomarkers and liver damage (white blood cell count, 16200/ $\mu$ l; hemoglobin, 11.0 g/dL; C-reactive protein, 28.5 mg/dL; serum albumin, 2.3 g/dL; lactate dehydrogenase, 3112 IU/L; aspartate aminotransferase, 1742 IU/L; and alanine aminotransferase, 1263 IU/L). Arterial blood gas analysis revealed severe acidosis (pH, 7.16; partial pressure of oxygen, 105 mmHg; partial pressure of carbon dioxide, 22.5 mmHg; bicarbonate, 7.7 mmol/L; base excess, -20.0 mmol/L; and lactate level, 2.5 mmol/L). The computed tomography scan showed aortic dissection extending between the chest and common iliac artery, a compressed superior mesenteric artery orifice secondary to the development of a false aortic lumen (Fig. 1), pneumatosis intestinalis involving the entire small intestine and right-sided colon with decreased contrast enhancement (Fig. 2), and hepatic portal venous gas.

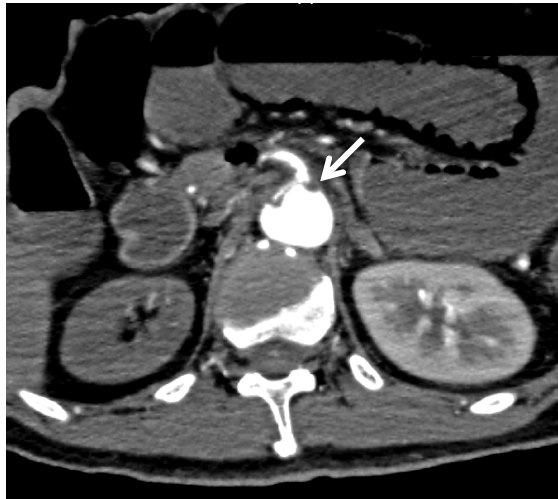An emergency operation was performed. Laparotomy revealed necrosis of the entire small intestine and right-sided colon and the non-pulsatile superior mesenteric artery. Subtotal resection of the small intestine and right colectomy were performed (Fig. 3[a]). The duodenal stump was closed using a liner stapler, a gastrostomy tube was placed, and a transverse colostomy was performed (Fig. 3[b]). The operating time was 93 minutes, and total blood loss was 30 g. The resected specimen had a speckled appearance, indicating bowel necrosis.

The patient required a 7-day stay in the intensive care unit (ICU) for cardiopulmonary support. On the 16th postoperative day (POD), he developed impaired consciousness, bradypnea due to metabolic alkalosis, and CO<sub>2</sub> narcosis secondary to massive gastrostomy discharge (>3000 mL/day). He was transferred back to the ICU where intravenous electrolyte fluid resuscitation (3000–4000 mL/day) and non-invasive positive pressure ventilation were performed. Furthermore, a proton-pump inhibitor and octreotide acetate were administered to reduce the gastrostomy discharge.

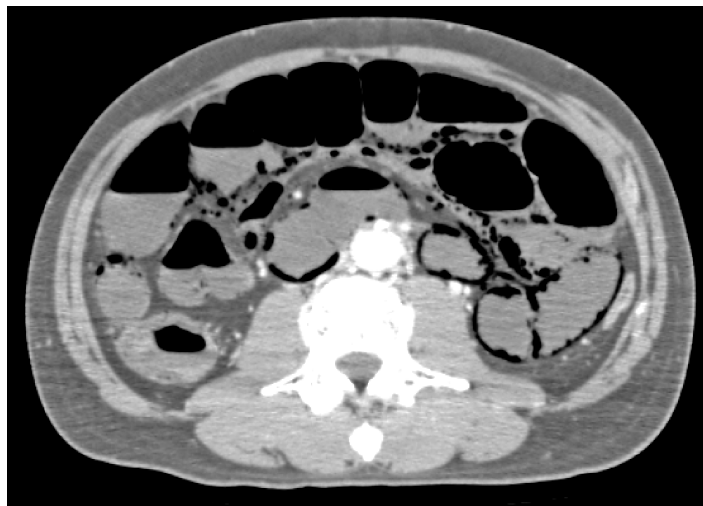
Following a 12-day ICU stay, his general condition gradually improved; however, it took over 2 months to plan the second surgery for restoring intestinal continuity. Since the 70th POD, his serum total bilirubin level gradually increased and reached 6.4 mg/dl on the 113th POD. Laboratory tests did not indicate viral infection, autoantibody formation, or obstructive jaundice. Computed tomography scan revealed a fatty liver without intrahepatic biliary dilatation. We suspected bile salt depletion secondary to a disruption of the enterohepatic circulation; thus, a small amount of the gastrostomy discharge (approximately 200 mL/day) was infused into the transverse colon through the colostomy. This management strategy resulted in a decrease of serum bilirubin to 4.6 mg/dL on the 153rd POD. Consequently, the second operation (a side-to-side anastomosis of the duodenum and transverse colon) was performed on the 155th POD (Fig. 3[c]). The operating time was 125 minutes, and total blood loss was 150 g.

Following this second operation, he was able to begin an oral diet. His blood pressure was

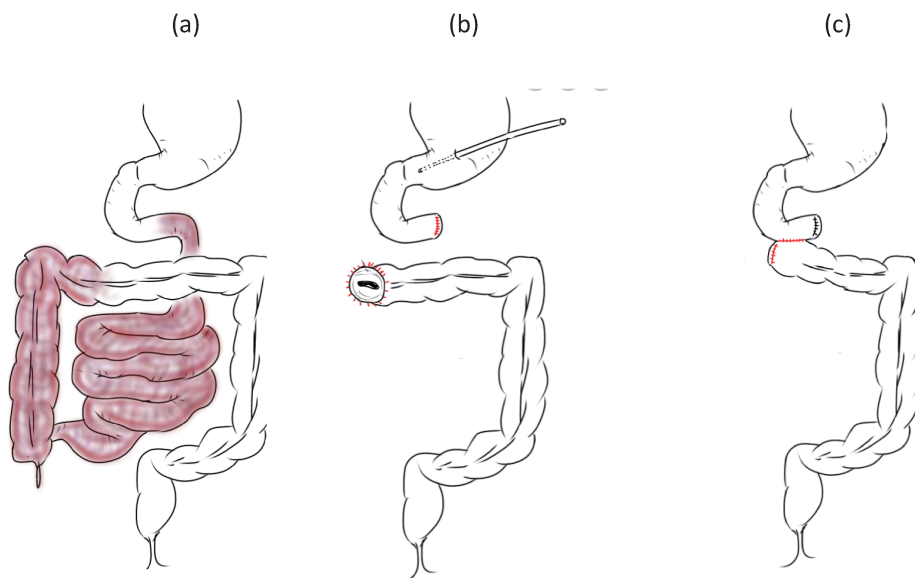
controlled with oral antihypertensives. After a central venous port was placed, he was discharged. The clinical course is schematically represented in Fig. 4. Despite frequent diarrhea, he has been well-nourished for 18 months with oral food intake and home-based intravenous hyperalimentation (3000 mL at 1640 kcal/day).



**Fig. 1** Computed tomography showing a narrowed superior mesenteric artery orifice (arrow) compressed by a false aortic lumen



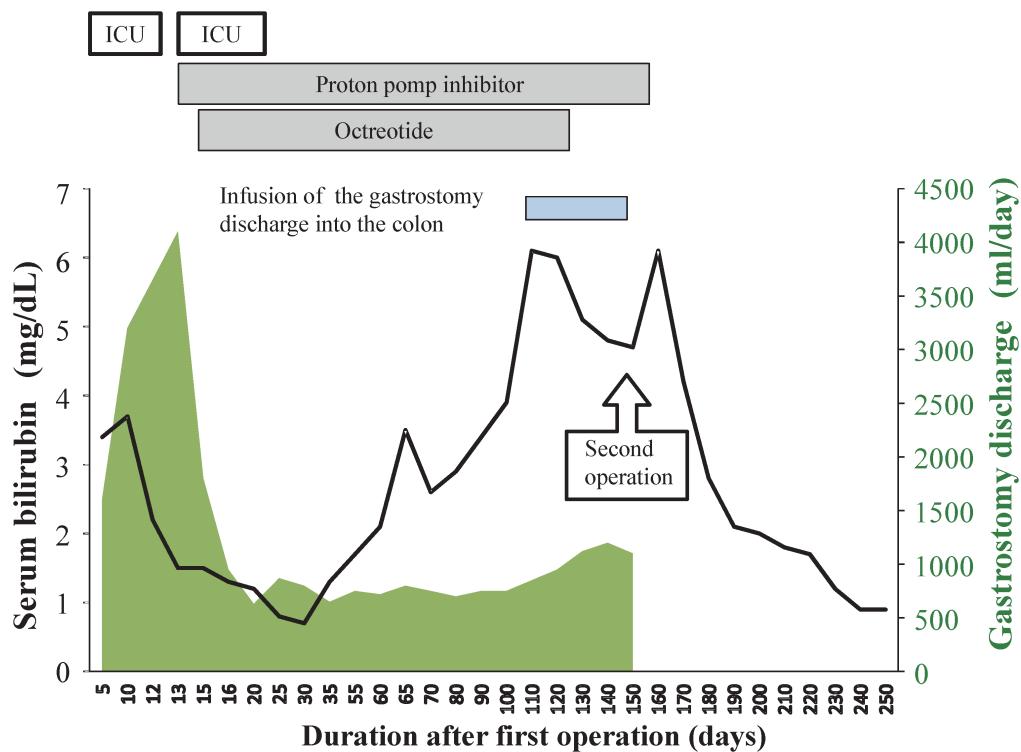
**Fig. 2** Computed tomography showing pneumatosis intestinalis and decreased contrast enhancement of the small bowel.



**Fig. 3** Shema of the operations

**Fig. 3a and 3b:** Schema representing the first operation: subtotal resection of the small intestine and right colectomy, tube gastrostomy, and transverse colostomy.

**Fig. 3c:** Schema representing the second operation: side-to-side anastomosis of the duodenum and transverse colon.



**Fig. 4** Schematic representation of the clinical course.

Gastrostomy discharge was reduced by administration of a proton-pump inhibitor and octreotide. The elevated serum bilirubin level during the 70–113th postoperative days was decreased after the infusion of gastrostomy discharge into the colon.

## DISCUSSION

Acute aortic dissection occasionally requires extensive intestinal resection. We reported such a case, where intestinal continuity was not able to be restored in the first operation. Two major postoperative complications were developed; impaired consciousness and jaundice. They were successfully managed, the second operation for restoring intestinal continuity was performed, and the patient was able to go back home.

Extensive resection of the small intestine can trigger gastric hypergastrinemia and hypersecretion, particularly in patients who undergo duodenal and proximal jejunal resection.<sup>3</sup> Massive discharge from the gastrostomy causes concomitant loss of electrolytes and gastric acid, and it can lead to hypokalemic hypochloremic metabolic alkalosis, which is usually compensated by CO<sub>2</sub> retention, resulting in impaired consciousness. This complication was treated with intravenous electrolyte fluid resuscitation, non-invasive positive pressure ventilation, and administration of proton pump inhibitor and octreotide acetate.

The cause of hyperbilirubinemia developed after the first surgery (subtotal resection of the small intestine and right colectomy) with full external drainage of gastric and duodenal contents through the gastrostomy is unclear. We hypothesized that bile salt depletion secondary to a disruption of the enterohepatic circulation might be associated with hyperbilirubinemia. Bile acid synthesis from cholesterol is required to maintain the bile acid pool in the enterohepatic circulation. However, a disruption of bile acid circulation leads to compensatory increase in hepatic bile acid production, which can be associated with hepatocyte injury and increased bile acid-dependent bile, resulting in progressive intrahepatic cholestasis<sup>4,5</sup> Saiki et al reported that compared to external drainage, internal biliary drainage restored the bile acid pool and increased bile secretion and bilirubin discharge in patients with obstructive jaundice in 1999.<sup>6</sup> In our case, the elevated serum bilirubin level was decreased after the infusion of gastric discharge through gastrostomy into the transverse colon through the colostomy; thereafter, the second surgery was performed. Administration of the hydrophobic bile acids (cholic acid or chenodeoxycholic acid) into the colon could have been an alternative treatment option because these acids suppress the synthesis of cytotoxic bile acid precursors and restore the input of primary bile acids into the enterohepatic circulation.<sup>7</sup>

The second operation (anastomosis of the duodenum and transverse colon) was safely performed after effective management of these complications. Careful management of the patient's diarrhea, liver dysfunction, electrolytes, and nutrient balance was important to ensure a better long-term quality of life.

## CONCLUSION

Careful attention should be paid to electrolyte imbalance and bile salt depletion for patients who undergo extensive bowel resection without intestinal continuity.

## ACKNOWLEDGEMENTS

Not applicable.

## CONFLICTS OF INTERESTS AND SOURCE OF FUNDING

None.

## REFERENCES

- 1) Slonim SM, Miller DC, Mitchell RS, et al. Percutaneous balloon fenestration and stenting for life-threatening ischemic complications in patients with acute aortic dissection. *J Thorac Cardiovasc Surg.* 1999;117:1118–1126.
- 2) Fattori R, Cao P, De Rango P, et al. Interdisciplinary expert consensus document on management of type B aortic dissection. *J Am Coll Cardiol.* 2013;61:1661–1678.
- 3) William NS, Evans P, King RF. Gastric acid secretion and gastrin production in the short bowel syndrome. *Gut.* 1985;26:914.
- 4) Hofmann A. The continuing importance of bile acids in the liver and intestinal disease. *Arch Intern Med.* 1999;159:2647–2658.
- 5) Dawson PA: Bile Secretion and the Enterohepatic Circulation. In: Feldman M, ed. *Slisenger and Fordtran's Gastrointestinal and Liver Disease.* Saunders; 2015:chap 64.
- 6) Saiki S, Chijiwa K, Komura M, et al. Preoperative internal biliary drainage is superior to the external biliary drainage in liver regeneration and function after hepatectomy in obstructive jaundiced rats. *Ann Surg.* 1999;230:655–662.
- 7) Gonzales E, Gerhardt MF, Fabre M, et al: Oral cholic acid for hereditary defects of primary bile acid synthesis: a safe and effective long-term therapy. *Gastroenterology.* 2009;137:1310–1320.