



Arab Journal of Urology
(Official Journal of the Arab Association of Urology)

www.sciencedirect.com



PEDIATRIC UROLOGY

ORIGINAL ARTICLE

Closure of bladder exstrophy with a bilateral anterior pubic osteotomy: Revival of an old technique

**Ehab R. Elsayed^{a,*}, Mohamed N. Alam^a, Osama M. Sarhan^b, Diab Elsayed^a,
Ahmed M. Eliwa^a, Salem Khalil^a**

^a Urology Department, Faculty of Medicine, Zagazig University, Zagazig, Egypt

^b Urology and Nephrology Centre, Faculty of Medicine, Mansoura University, Mansoura, Egypt

Received 20 June 2011, Received in revised form 18 August 2011, Accepted 25 August 2011

Available online 15 November 2011

KEYWORDS

Bladder;
Exstrophy;
Osteotomy;
Anterior pelvic osteotomy;
Safety

Abstract Objective: To evaluate the results of simple closure using bilateral anterior pubic osteotomy to achieve a tension-free approximation of the pubis and abdominal wall in patients with bladder exstrophy.

Patients and methods: A prospective study carried out between 2006 and 2009 included 15 patients (13 boys and 2 girls; age range 3–47 months). Of these patients, three had recurrent exstrophy while 10 were operated primarily. An elective surgical technique was used for all patients, which included dissection of the exstrophic bladder from the abdominal wall, closure of the bladder and reconstruction of the urethra, then dissection of the rectus muscle and sheath lateral to the attachment of muscle to pubic bone, which makes osteotomy of the superior pubic ramus easy, thus facilitating closure.

Results: For closure of the bladder and anterior abdominal wall the results were excellent for all patients soon after surgery, but there was soft-tissue infection in two patients. Of all 15 patients, one had incomplete bladder dehiscence and another had a vesico-cutaneous fistula; both needed surgical intervention later.

Conclusions: Simple closure with anterior pubic osteotomy is a feasible and effective means to facilitate both bladder and abdominal closure for patients with bladder exstrophy. It is advantageous in being a rapid procedure, and can be completed by the paediatric urologist.

© 2011 Arab Association of Urology. Production and hosting by Elsevier B.V. All rights reserved.

Introduction

Classic bladder exstrophy is a birth defect mainly involving the musculoskeletal system and genitourinary tracts; it occurs at a

* Corresponding author. Tel.: +20 14 6044499.
E-mail address: Dr_ihabraafat@yahoo.com (E.R. Elsayed).



rate of 1 in 10 000–50 000 live births [1–4]. During the past two decades, the operative treatment of bladder exstrophy has advanced considerably, with various techniques and approaches described to achieve successful closure and the best functional outcomes [5–9]. The initial goal of exstrophy closure is a tension-free approximation of the pubic bones and soft tissue in the midline. Osteotomy provides closure of the bony ring and muscles of the pelvic floor to support the bladder and surround the urethra. Many types of osteotomy have been described to obtain a tension-free approximation of the pubic bones and soft tissues in the midline [10–17].

A successful osteotomy technique consisting of anterior pelvic osteotomy of the superior pubic ramus was first described by Frey and Cohen in 1989 [15]. This technique seems to be a safe and quick adjunct for pubic bone approximation, so that this approach would preclude the need for a paediatric orthopaedic surgeon [16,17]. The aim of the present study was to evaluate the feasibility and outcome of simple closure of exstrophy, using bilateral anterior pubic osteotomy to achieve a tension-free approximation of the pubis and abdominal wall in patients with bladder exstrophy.

Patients and methods

This prospective study, carried out between January 2006 and February 2010, included 15 patients (age range 3–47 months; 13 boys and 2 girls). Three patients had recurrent exstrophy while 12 were operated primarily; an elective surgical technique was used for all patients, of any age once osteotomy is indicated. After general anaesthesia was established, the ureteric orifices were cannulated (Fig. 1), the skin around the exstrophic bladder was incised and the exstrophic bladder was dissected from the abdominal wall extraperitoneally, with generous bladder dissection and any inter-symphyseal bands resected. The bladder was closed in two layers with insertion of a suprapubic catheter, and the epispadiac urethra reconstructed over 10 F urethral catheter using the Cantwell–Ransley technique [18]. In girls the bladder was separated from the anterior vaginal wall to help in female urethral reconstruction. Attention was directed after that to the pelvic osteotomy, in which both crura were dissected from their attachment to the

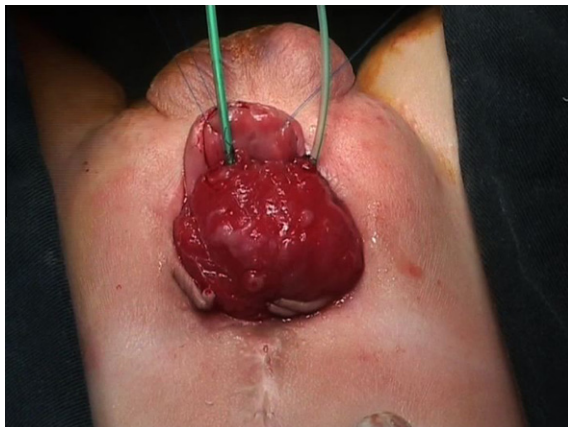


Figure 1 Preoperative view of a 7-month-old boy with failed exstrophy closure after fixation of two ureteric stents.

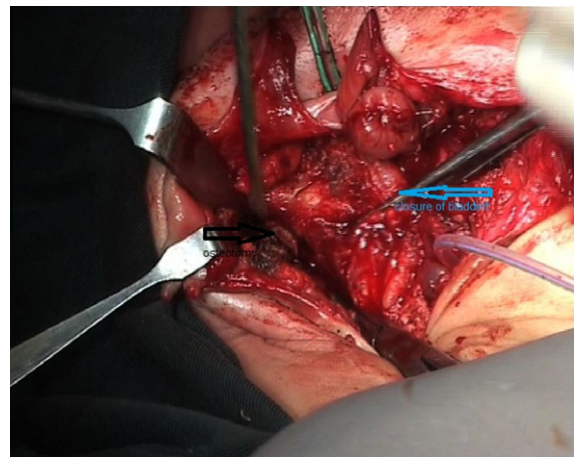


Figure 2 Anterior pelvic osteotomy lateral to the rectus muscle from the same incision on the left side.

inferior pubic wing. The technique of anterior pelvic osteotomy was the same as described by Frey and Cohen [15].

To begin anterior pubic osteotomy, both rectus muscles and sheath are identified and dissection is continued between the rectus sheath and the subcutaneous tissue laterally until the lateral boarder of the rectus abdominis muscle is reached. The rectus sheath is incised at this point and the superior pubic ramus is exposed. The periosteum of the superior pubic ramus is incised at the superior half of the pubic ramus medial to the insertion of the inguinal ligament. A bone retractor is inserted in the obturator foramen below the superior pubic ramus before starting the pubic osteotomy, to protect the obturator nerve and vessels. Pubic osteotomy is then performed using a chisel and mallet (diathermy was sometimes used), with particular care taken not to tear the inferior periosteum or injure the obturator nerve (Fig. 2). After completing the pubic osteotomy bilaterally, both pubic bones are tilted medially and approximated using one or two polyglactin-1 or -2 sutures (Fig. 3). The proposed bladder neck and urethra are positioned deep to the approximated pubic bones before securing the polyglactin sutures. Two drains are inserted at the site of both pubic

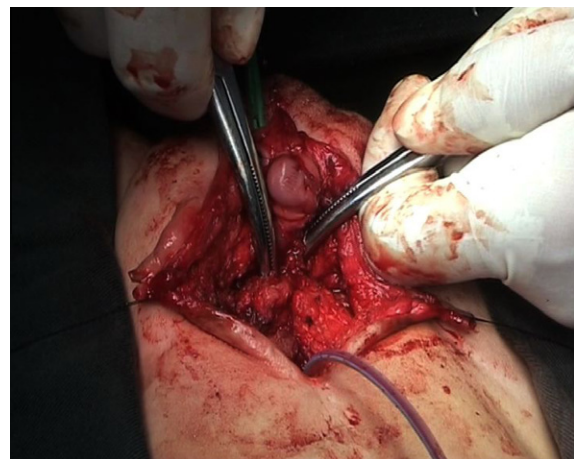


Figure 3 Easy approximation of the two recti in the midline after osteotomy.

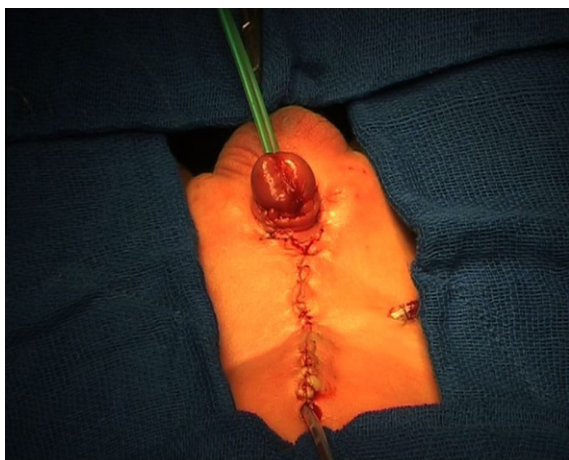


Figure 4 Final postoperative picture of the same case with a tube drain, suprapubic catheter and two ureteric stents passing through the neourethra.

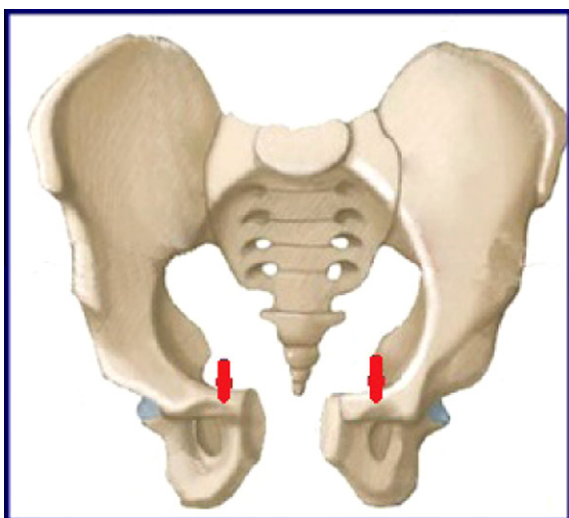


Figure 5 A drawing of the osteotomy procedure.

osteotomy and one more is inserted at the site of the reconstructed bladder. Wound closure is started by approximating both rectus muscles which, after completing the osteotomy, are easily approximated using interrupted absorbable sutures. Finally, the skin is closed, with reconstruction of the umbilicus (Fig. 4). Fig. 5 shows a diagram of the procedure. A hip spica cast was used as fixation in recurrent cases only for 2–3 weeks, while in the other cases simple closure was by a plaster and pressure bandage for 2 weeks. All patients were kept on bed rest during the period of hip spica, and movement was allowed thereafter.

Results

The mean (range) follow-up was 14 (6–36) months; we evaluated the anterior pubic osteotomy for closure of the bladder and anterior abdominal wall. The results were excellent for all patients in which a tension-free anterior abdominal wall and bladder reconstruction was used. Soon after surgery there

were soft-tissue infections in two patients; they were treated conservatively by frequent wound dressing and appropriate antibiotics. Of the 15 patients, one had complete wound dehiscence and another had a vesico-cutaneous fistula; both were treated by a later simple repair. The mean (range) operative duration was 165 (135–190) min and only one patient required a blood transfusion. No intraoperative repositioning was needed, and there was no need for orthopaedic surgeons.

Discussion

The main goal of initial exstrophy repair is to close the pubic bones and soft tissue of the anterior abdominal wall without tension, so it is apparent that any type of osteotomy seems to prevent dehiscence of the reconstructed bladder and abdominal wall. Pelvic osteotomies have been described by many authors, and there are many different techniques that can be chosen according to the surgeon's preference and experience [10–17]. In 1958, Schultz [10] described a bilateral posterior iliac osteotomy, which became a well-known technique for closure of cases with bladder exstrophy. However, it is a time-consuming major operation, usually performed by orthopaedic surgeons. Furthermore, this procedure requires repositioning the patient to complete the operation, which considerably increases the duration of the operation and of anaesthesia. In the late 1980s, Sponseller et al. [11] used the technique of anterior innominate osteotomy and approximated the pubic bones using an external fixator. It is an efficient procedure with none of the drawbacks of posterior osteotomy. However, it remains a major procedure and is usually done by orthopaedic surgeons. Other drawbacks of this type of osteotomy include increased blood loss and post-operative pain. Furthermore, in 1995 the combined anterior innominate with a posterior iliac osteotomy was used from an anterior approach [13]. Other approaches, including an oblique iliac wing osteotomy, have been described, and some promising clinical results reported [14].

Anterior pelvic osteotomy was first described by Frey and Cohen [15], when they used this type of osteotomy for children with bladder exstrophy. They documented complications in two of these patients; one had partial bladder prolapse while the other had a severe deep wound infection with complete breakdown of the repair. This type of osteotomy has many advantages; it is a versatile technique that could be used for both primary and re-do cases, regardless of patient age; the operative duration is reasonable, with no need to change the patient's position, and thus reduced anaesthetic exposure. Blood loss was minimized and blood transfusion was rarely needed. Anterior pubic osteotomy also has the advantage of being performed by the paediatric urologist, with no need for an orthopaedic surgeon. Two other reports on the same approach were published in early 1990s by Perovic et al. [17] and Schmidt et al. [12], which confirmed that there was no difference between bilateral iliac osteotomy and superior pubic ramotomy in terms of bladder exstrophy closure.

Following these reports, again Frey [16], who proposed this technique, documented further experience on 16 cases after exstrophy closure. He found that the abdominal wall closure was excellent in all patients except two, in whom major complications developed in the form of soft-tissue infection and bladder dehiscence in one, and transient obturator nerve palsy in the other. The latest experience of anterior pelvic osteotomy

was reported by Chiari et al. [19] in which all procedures were successful. Tension-free complete approximation of the symphysis and uncomplicated healing was achieved in all five cases, without palsy of the obturator nerve or postoperative haemorrhage. In our practice we used to use anterior innominate osteotomy to close bladder exstrophy. However, this procedure was lengthy (4–6 h), was only done by paediatric orthopaedic surgeons, and needed two separate incisions, with more blood loss. For these reasons we tried to use the anterior pubic osteotomy technique for a consecutive group of patients and compare the results with the previous group who underwent innominate osteotomy. We evaluated the feasibility of bilateral anterior osteotomy of the superior pubic ramus for closure of the abdominal wall, bladder and urethral reconstruction, operative time and technical difficulty. The operation was significantly quicker and the success rate was comparable with the other techniques. Anterior osteotomy of the superior pubic ramus allowed symphyseal approximation and abdominal wall closure in all patients in the present study, and there was no greater tension for pubic approximation than in the other technique. This is in accordance with the previously published reports about this type of osteotomy, which reported that it is an efficient procedure.

The importance of osteotomy for exstrophy repair is to achieve a tension-free closure of the bladder and abdominal wall [20]. A comparison of anterior pubic osteotomy with other types of osteotomy for continence and pelvic dimension has not yet been reported.

In conclusion, simple closure with anterior pubic osteotomy is a feasible and effective means to facilitate both bladder and abdominal closure for patients with bladder exstrophy. This technique has the advantage of being reproducible, quicker, with less blood loss and easily performed by the paediatric urologist.

References

- [1] Rickham PP. The incidence and treatment of ectopia vesicae. *Proc Roy Soc Med* 1961;**54**:389–92.
- [2] Lattimer JK, Smith MJ. Exstrophy closure. A followup on 70 cases. *J Urol* 1966;**95**:356–9.
- [3] Stec AA, Pannu HK, Tadros YE, Sponseller PD, Wakim A, Fishman EK, et al. Evaluation of the bony pelvis in classic bladder exstrophy by using 3D-CT. Further insights. *Urology* 2001;**58**:1030–5.
- [4] Stec AA, Pannu HK, Tadros YE, Sponseller PD, Fishman EK, Gearhart JP. Pelvic floor anatomy in classic bladder exstrophy using 3-dimensional computerized tomography: initial insights. *J Urol* 2001;**166**:1444–9.
- [5] Jeffs RD, Charrios R, Mnay M, Juransz AR. Primary closure of the exstrophied bladder. In: Scott R, editor. *Current controversies in urologic management*. Philadelphia: Saunders; 1972. p. 135–43.
- [6] Grady R, Mitchell ME. Complete primary repair of exstrophy. *J Urol* 1999;**162**:1415–20.
- [7] Baka-Jakubiack M. Combined bladder neck, urethral and penile reconstruction in boys with exstrophy-epispadias complex. *BJU Int* 2000;**86**:513–8.
- [8] Gearhart JP, Mathews RI, Taylor S, Jeffs RD. Combined bladder exstrophy closure and epispadias repair in the reconstruction of bladder exstrophy. *J Urol* 1998;**160**:1182–5.
- [9] Baird AD, Nelson CP, Gearhart JP. Modern staged repair of bladder exstrophy: a contemporary series. *J Pediatr Urol* 2007;**3**:311–5.
- [10] Shultz WG. Plastic repair of exstrophy of bladder combined with bilateral osteotomy of ilia. *J Urol* 1958;**79**:453–8.
- [11] Sponseller PD, Gearhart JP, Jeffs RD. Anterior innominate osteotomies for failure or late closure of bladder exstrophy. *J Urol* 1991;**146**:137–40.
- [12] Schmidt AH, Keenen TL, Tank ES, Bird CB, Beak RK. Pelvic osteotomy for bladder exstrophy. *J Ped Orthoped* 1993;**13**:214–9.
- [13] Gearhart JP, Forschner DC, Jeffs RD, Ben-Chaim J, Sponseller PD. A combined vertical and horizontal pelvic osteotomy approach for primary and secondary repair of bladder exstrophy. *J Urol* 1996;**155**:689–93.
- [14] Jones D, Parkinson S, Hosalkar HS. Oblique pelvic osteotomy in the exstrophy/epispadias complex. *J Bone Joint Surg Br* 2006;**88**:799–806.
- [15] Frey P, Cohen SJ. Anterior pelvic osteotomy: a new operative technique facilitating primary bladder exstrophy closure. *Br J Urol* 1989;**64**:641–3.
- [16] Frey P. Bilateral anterior pubic osteotomy in bladder exstrophy closure. *J Urol* 1996;**156**:812–5.
- [17] Perovic S, Brdar R, Scepanovic D. Bladder exstrophy and anterior pelvic osteotomy. *Br J Urol* 1992;**70**:678–82.
- [18] Ransley PG, Duffy PG, Wollin M. Bladder exstrophy closure and epispadias repair. In: *Operative surgery: paediatric surgery*. 4th ed. Edinburgh: Butterworths; 1989. p. 620.
- [19] Chiari G, Avolio L, Bragheri R. Bilateral anterior pubic osteotomy in bladder exstrophy repair. Report of increasing success. *Pediatr Surg Int* 2001;**17**:160–3.
- [20] Wild AT, Sponseller PD, Stec AA, Gearhart JP. The role of osteotomy in surgical repair of bladder exstrophy. *Semin Pediatric Surg* 2011;**20**:71–8.

Editorial comment

The authors of this article should be congratulated for reporting their experience of pubic osteotomy in children with exstrophy, which seems relatively straightforward and ‘orthopaedist-free’, although not adopted by many surgical teams. I wondered why, and the answer might be in the roles of pelvic osteotomy in the child with exstrophy. There is no doubt that the bilateral anterior pubic osteotomy, like several other techniques, is suitable for achieving a tension-free closure and filling the lower abdominal midline depression. Contrary to the anterior oblique iliac osteotomy, the reported technique does not change the depth of the pelvis, which is classically flattened in patients with exstrophy. This is an important point for relocating the bladder and bladder neck inside the pelvis, and possibly to restore some bladder function. Pubic osteotomy also fails to bring together the corpora cavernosa to reconstruct the epispadiac penis, except if it is combined with the Kelly soft-tissue mobilization. As far as I know, there is no report of a combination of these two procedures. It would be interesting to know if this type of osteotomy remains stable in the long term and avoids the progressive separation of the two hemi-pelves seen with other types of osteotomy.

The inward displacement of the nerves and vessels passing through the obturator foramen might be an issue when the gap between the two hemi-pelves is large. Transient paresis of the quadriceps is a common adverse effect of pelvic osteotomy, and is particularly symptomatic in older children. This aspect has not been contemplated in the present study, nor the place of this technique in the newborn, when many of these