

Original Article

Open Access

Pia Kokemohr*, Lars Haeder, Fabian Joachim Frömling, Peter Landwehr and Joachim Jähne

Surgical management of rectal foreign bodies: a 10-year single-center experience

DOI 10.1515/iss-2017-0021

Received March 30, 2017; accepted April 19, 2017; previously published online May 20, 2017

Abstract

Background: Patients with a rectal foreign body (RFB) are still a rare entity in general surgery departments but with an increasing incidence over the last years. This case is sometimes difficult to treat, and due to a lack of standardized treatment options, the aim of the study was to present our clinical experiences with the diagnostic and therapeutic approach to RFBs and a review of the currently available literature.

Materials and methods: Data were collected retrospectively from the patient's records of 20 patients who were treated due to an RFB between 2006 and 2016. Patient's demographics, circumstances of insertion, inserted objects, clinical presentation, laboratory and imaging results, as well as surgical treatment and duration of hospital stay were analyzed. Additionally, a review of the literature was performed with the search items "rectal foreign body" and "surgical therapy". Because many publications were just case reports, we did not perform a meta-analysis or a systematic review.

Results: Twenty-two cases in 20 patients (80% male) presented to the emergency room. The mean age was 38.5 ± 13.7 years. In 68.2% of the cases, the cause of RFB was due to sexual preferences. The following objects were inserted: six dildos, three vibrators, two bottles, one glass, one deodorant, one apple, one fever thermometer,

multiple glass fragments and razor blades in one patient and six unknown objects. For 18 RFBs, manual peranal removal without anesthesia was possible in the emergency room, but two patients required intravenous analgesia. Two patients were transferred to the operating room and the foreign body was removed via the anus under general anesthesia. Open surgery with a laparotomy was necessary for two complicated cases. One patient was in need of surgery due to a vacuum generated by the RFB, whereas the second patient suffered from a sigmoid perforation. In all cases, there was no morbidity or mortality.

Conclusion: In most cases, the removal of an RFB can be performed peranally in the emergency room without further complications, therefore representing the therapy of choice for RFB. Only in cases with perforation, acute abdomen, or failed peranal approaches, surgery is indicated to remove the foreign body.

Keywords: manual extraction; rectal foreign body; sexual preferences; surgical therapy.

Introduction

Patients with rectal foreign bodies (RFB) are still a rarity in the emergency room of general surgery departments [1], but their incidence is increasing [2, 3]. Patients are usually male and the motives are mostly sexual preferences [1, 4]. Until now, there is no standardized protocol for surgical treatment of these patients and many different strategies have been described over the last years [4, 5].

The aim of this study was to present our 10-year experiences with the surgical treatment of RFBs and the comparison to the data in the literature.

Materials and methods

Data collection

We retrospectively collected all data of patients who presented with an RFB to the emergency room of DIAKOVERE Henriettenstift

*Corresponding author: Pia Kokemohr, Clinic for General and Digestive Surgery, Center for Endocrine, Oncologic and Metabolic Surgery, DIAKOVERE Henriettenstift, Marienstraße 72-90, D-30171 Hannover, Germany, E-mail: Pia.Kokemohr@diakovere.de
Lars Haeder and Joachim Jähne: Clinic for General and Digestive Surgery, Center for Endocrine, Oncologic and Metabolic Surgery, DIAKOVERE Henriettenstift, Marienstraße 72-90, D-30171 Hannover, Germany

Fabian Joachim Frömling: Klinik für Hämatologie, Hämostaseologie, Onkologie und Stammzelltransplantation, Medizinische Hochschule Hannover, Hannover, Germany

Peter Landwehr: Klinik für Diagnostische und Interventionelle Radiologie, Hannover, Germany

(Hannover, Germany) from March 2006 to July 2016. Data retrieval was performed by the in-hospital digital information system ORBIS and GapIT, respectively. We identified 20 patients with 22 cases with an RFB, sharing the ICD-10 T18.5 code (anal foreign body and RFB). Collected data were related to patient's demographics, circumstances and objects of insertion, clinical presentation, laboratory results, surgical treatment, complications and duration of hospital stay. Due to the retrospective setting of this study, detailed information (e.g. inserted objects) was missed in some cases. The conducted research is not related to either human or animal use.

Statistical analysis

Data were collected into an Excel worksheet. Continuous variables were expressed as means \pm standard deviation. Categorical variables were expressed as absolute and relative frequencies. Due to the low number of patients, a detailed statistical analysis was not performed.

Diagnostic and therapeutic approach

After presenting to the emergency room, patient's history was taken followed by a complete medical and rectal examination. Depending on the manifestation of the symptoms and type of foreign body, blood samples were taken and X-rays were performed. In all cases, first efforts to remove the RFB from the patient were performed without anesthesia in the emergency room. If removal was not possible, more sophisticated therapeutic interventions were tried by applying analgesia and/or by endoscopy. Only in complicated cases, patients were taken to the operating room to undergo surgical exploration.

Results

Twenty-two cases in 20 patients were included into the study. The mean age was 38.5 ± 13.7 years (range 23–71 years). Sixteen (80%) of the 20 patients were male. Two male patients presented at two different times to the emergency room with an (recurrent) RFB. In 68.2% of the cases, the reason was anal sexual stimulation. The following objects were inserted into the rectum: six dildos, three vibrators, two bottles, one glass, one deodorant, one apple, one fever thermometer, multiple glass fragments and razor blades in one case (peranal and transvaginal) and six unknown objects. All patients came to the emergency room because they were not able to remove the objects by themselves and/or by their partners. Four of these patients presented with rectal bleeding, two patients presented with pain and one patient presented with constipation. Ten patients presented without any symptoms and for five patients, specific information was not available.

The patient who presented with perinally and transvaginally inserted multiple glass fragments and razor blades was a young woman from the psychiatric department. She presented several times before to the gynecology department with transvaginally inserted foreign bodies.

Abdominal X-rays were performed in only five patients and showed a perforation of the sigmoid by the RFB in one patient (Figure 1), whereas the others demonstrated the inserted RFB (Figures 2 and 3).

We took blood samples in three patients and the results showed leukocytosis in all three patients.

All rectal bodies were palpable by digital rectal examination or could be identified by proctoscopy. In all cases, the surgeon tried a manual retraction right in the emergency room on a proctoscopy chair in lithotomy position using hands, forceps, Kocher clamps, or other surgical instruments.

In 16 cases, this first attempt of removal was successful and the patients were discharged from the emergency room without further complications. In two cases, the removal of the foreign body was possible in the emergency room by applying analgesia. Two patients were transferred to the operating theater and the foreign body was removed under general anesthesia and full relaxation

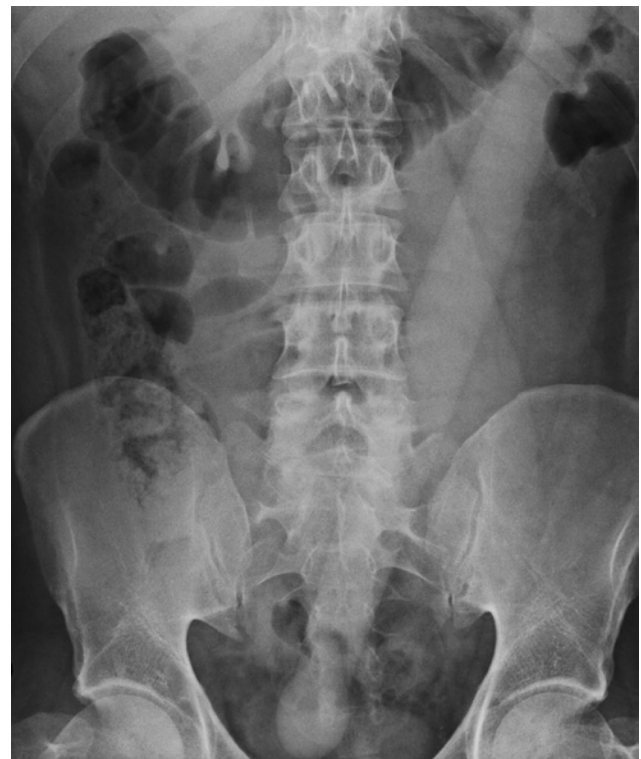

Figure 1: After rectal perforation, free-lying dildo in the abdomen.

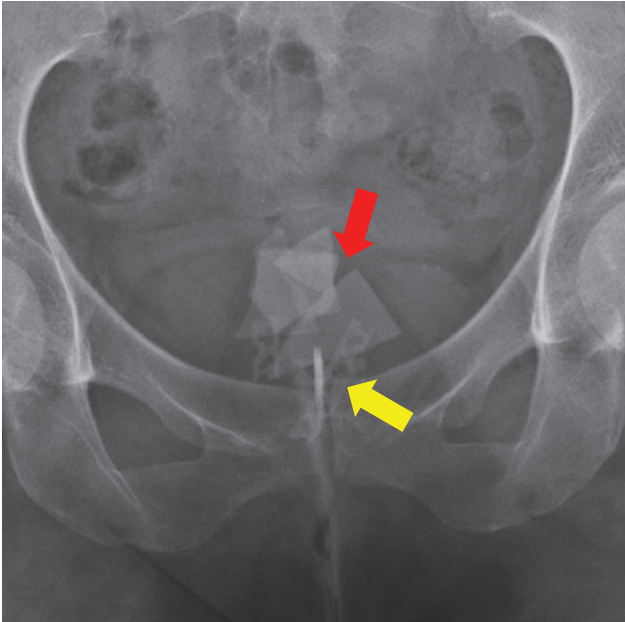


Figure 2: Perianally and transvaginally inserted glass fragments (red arrow) and razor blades (yellow arrow).

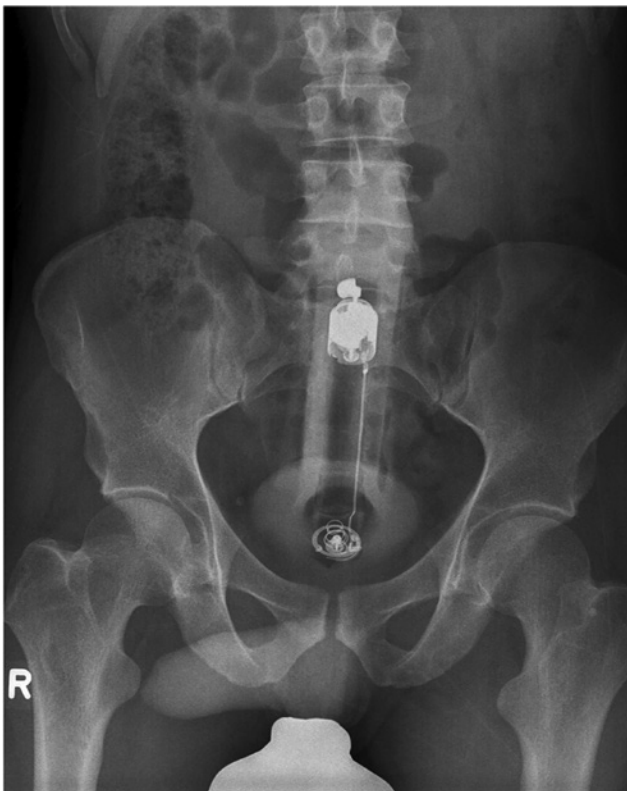

Figure 3: Complete perianally inserted vibrator.

of the sphincter muscle. The first case was a 26-year-old man with an inserted apple and the second one was a 27-year-old woman from the psychiatric department with

vaginally and rectally inserted glass fragments and razor blades. Both patients left hospital the next day without further complications.

In two cases, it was impossible to remove the foreign body without surgery. The first patient was a 31-year-old male who was in need of surgery because of a plug (dildo) in his proximal part of the rectum. Because of a resulting vacuum, it was impossible to retain the plug by hands or forceps or by endoscopy. Therefore, surgery with median laparotomy, transmural extraction and repair was necessary (Figure 4).

The second patient was a 39-year-old man suffering from dildo longer than 40 cm, which already perforated the sigmoid (Figure 5). In both cases, a primary repair without colostomy was possible. Both patients were discharged after 5 and 7 days, respectively, without further complications.

After removing the RFB, colonoscopy was made in five cases. Just in one case, there was a rectal injury with



Figure 4: This plug was removed by laparotomy. Because of the vacuum that was built by the RFB, all conservative efforts failed.

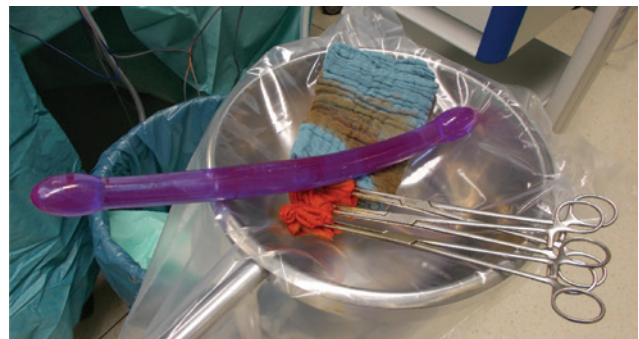

Figure 5: This 40-cm-long dildo perforated the sigmoid. This dildo was extracted by media laparotomy.

bleeding of the mucosa, whereas the others showed no significant injuries.

Discussion

RFBs are a rare entity in the emergency room of hospitals all over the world but with increasing incidence over the last decade [2, 3]. The reason for the rising incidence is unknown at the moment. It can be speculated, however, that the changing attitudes toward open-minded societies with the greater acceptance of individual lifestyles as well as sexual preferences may be one reason. Most studies dealing with RFB are case reports [6–10] or describe only a small number of cases [11–16]. With respect to the reviewed literature, our study on 20 patients with 22 cases is one of the bigger series. It is noteworthy, however, that the true incidence of RFB is most likely much higher, because it is completely unknown how often RFBs are removed by either the patient and/or other people at home.

Our data presented 22 cases over 10 years with a uniform distribution of frequency over the years. Other studies have shown an increasing number of patients who presented with an RFB to the emergency room over the last years [16].

Most reported cases dealt with the insertion of RFBs due to sexual preferences ranging from 78% to 100% of all cases [12, 17, 18]. In our study, 68.2% of the patients inserted a foreign body for sexual satisfaction. It may well be that this number does not reflect the true cause of rectal insertion because a patient bias due to individual shame cannot be excluded. Other reasons for RFB described in the literature are sexual abuse, to alleviate constipation, or accidental [13]. Body packing is also a common entity and is often used by drug traffickers [3]. Psychiatric diseases are also described in the literature [14, 19]. In our study, one 27-year-old woman from the psychiatric department presented with vaginally and rectally inserted foreign bodies. She presented several times before to the gynecological department with just vaginal foreign bodies.

Most patients tried to remove the RFB at home by their own or by their partners. Just when they failed to remove the object, they presented to the emergency room. Likewise, in some of our patients, constipation, rectal bleeding and abdominal pain are common complaints at the admission to the emergency room [20, 21].

A full patient's history and abdominal as well as rectal examination of the patient are necessary to figure out these patients who presented with signs of peritonitis as a result of perforation. Abdominal X-ray is indicated in all patients and can give useful information about the

type of object, the location of the object, or free air as a sign of perforation [1, 20, 22]. Despite these recommendations in the published articles, we performed only rarely an X-ray of the abdomen. This seems to be justified if the RFB can be palpated upon rectal examination and the patient shows no signs of an acute abdomen.

Like other studies have shown, there are many different types of objects that were inserted (e.g. vibrators, dildos, bottles, fruits, or vegetables). These different types of objects make it difficult to develop a standard treatment for this entity [14, 19]. Despite these limitations and based on our data, it can be recommended that peranal evacuation should always be performed at first side, acknowledging that, in particular, soft foreign bodies such as vegetables may be difficult to remove.

Many different techniques of extraction were described by the published studies [6, 23–26]. The chosen procedure depends on the type of object, location of the RFB, time from insertion to presenting to the emergency room, symptoms of the patients and the surgeon's skills.

In most cases, peranal extraction with or without analgesia is possible [2, 15, 17]. However, before all peranal interventions, acute abdomen due to bowel perforation and peritonitis should be excluded [1] and the approach to remove the RFB peranally should be made under direct vision [22]. In particular, when attempting to remove the RFB peranally, there is a risk of the RFB to migrate upward in the sigmoid. In our study, 81.8% of RFBs were removed just by hand or forceps, Kocher clamps, or other surgical instruments in the emergency room. Two patients were transferred to the operating theater and the foreign bodies were removed under general anesthesia. Other studies presented a similar number of removing the RFB peranally ranging from 66.7% to 100% [1, 11, 14–16]. Therefore, peranal extraction appears to be the treatment of choice.

The literature presents many case reports that are demonstrate ingenious and sophisticated techniques of removing RFBs [7–10, 23, 24]. Koornstra and Weersma presented a case report demonstrating an endoscopic technique using a pneumatic dilatation balloon normally used in achalasia. A 19-year-old male presented with a high-pressure container in his rectum. The sigmoidoscope could be passed to the proximal end of the foreign body. Via a guide wire, a 40 mm pneumatic dilatation balloon was inserted and inflated above the foreign body. The RFB was removed with traction on the balloon catheter under control [23].

Sayilir et al. presented a similar technique in a case report with a male patient who had inserted a mandarin in his rectum. They used a 14 Fr Foley catheter. The balloon of the catheter was inflated with 20 mL water and gently pulled out [24].

However, these two papers presented just case reports. To prove if techniques have an advantage to other conservative treatments, bigger studies with more patients are necessary. As mentioned above, the variety of different objects make it difficult to find a standard procedure and to choose a technique as the best one. The most important is to avoid injuries of the rectal and colon wall that can result in emergency laparotomy because of perforation.

Two studies reported a laparoscopic assistance of removing RFBs. Under general anesthesia, laparoscopy was used to push the RFB from above while it was removed perianally from below [25, 26].

Only if there is no opportunity to remove the RFB perianally by hands, surgical devices, endoscopically, or laparoscopically that invasive open surgery is indicated. Surgery is also more common with a foreign body retained in the sigmoid colon than in the rectum [1, 2].

In our study, two male patients were in need of surgery because conservative treatment was not possible. The first one was a 39-year-old man suffering from dildo longer than 40 cm, which already perforated the sigmoid. The dildo was extracted by median laparotomy and colotomy. The second case was a 31-year-old male with a plug in his proximal rectum. Because of the vacuum, an extraction by hands or endoscopy was not possible. Other series presented nearly the same number of patients in need for surgery [14, 27]. At the moment, the role of laparoscopic surgery remains unclear. Although gaining increasing relevance in elective abdominal surgery, our series as well as the literature reported only a few cases with a true laparoscopic approach for the surgical therapy of RFB. It can be assumed that the relevance of laparoscopic surgery will increase in the future.

Despite the overwhelming reports of “conservative” treatment of RFBs, Cawich et al. presented a high number of patients who need surgery to remove the RFB. Of the 10 patients, just in one case, it was possible to remove the RFB in the emergency room. One patient presented with acute abdomen and was directly brought to surgery for emergency laparotomy. The other eight patients also were transferred to the operating theater. In three cases, it was possible to remove the RFB perianally under anesthesia, one patient had perianal minimal invasive surgery (TAMIS), one patient underwent laparoscopic advancement and perianal retrieval and three other patients needed laparotomy and transmural extraction with repair in two patients and a colostomy in one patient [12].

Due to our experience, we suggest an algorithm for the management of RFBs in our department (Figure 6). All patients who present with an RFB to the emergency room get a complete physical and rectal examination. Due

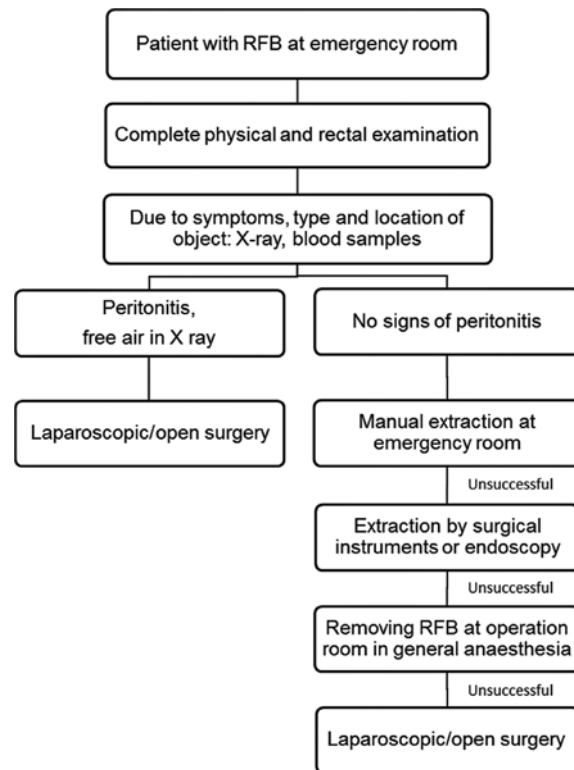


Figure 6: Algorithm for the management of RFB.

to the object and depending on the location of the object and the symptoms of the patient, we will take some blood samples or perform an X-ray. If the patients and the examination show no sign of acute abdomen or perforation, we always try to remove the RFB first in the emergency room by hands and when this is not possible, we remove the RFB by surgical instruments or endoscopy on a proctoscopy chair in lithotomy position. When the removal of the RFB is not successful, the next step is to try to remove the foreign body under general anesthesia with full relaxation of the sphincter muscle in the operating room. Only if all these steps are unsuccessful or the patient presents with acute abdomen as a sign of peritonitis and perforation that open and/or laparoscopic surgery may be necessary. Yildiz et al. also developed an algorithm very similar to our stepwise treatment of RFB [1]. Our experiences and our data show how important it is to try to standardize the treatment of the removal the RFB, although it is not easy due to the diverse types of objects. Because of the proposed stepwise treatment, it was possible to remove almost all RFBs by conservative management without further morbidity and without mortality.

Postretrieval colonoscopy and/or X-ray is compulsory in all cases to rule out colorectal injuries [1, 22]. In our study, postretrieval colonoscopy was made in just

five cases and showed an injury of the rectal mucosa in a 36-year-old man after removing a dildo by manual extraction in the emergency room.

Conclusion

There is still no gold standard for the treatment and removal of RFB. The therapeutic strategy depends on the surgeon's experience, the time from insertion to presenting to the emergency room, the kind and location of the foreign body and if the patient presents with any symptoms.

In our experience, it is important to work out a uniform treatment for all patients who present with an RFB to the emergency room, including physical examination, blood samples, ultrasound, X-ray and postextraction endoscopy.

Our data showed that a peranal extraction of the RFB is possible in most patients and could be done in the emergency room without further morbidity. Sometimes, anesthesia for the relaxation of the sphincter muscle is necessary. Laparotomy or laparoscopy is the last step when all conservative methods failed or the patient presented with symptoms of an acute abdomen or in the case of perforation.

Author Statement

Research funding: Authors state no funding involved. Conflict of interest: Authors state no conflict of interest. Informed consent: Informed consent has been obtained from all individuals. Ethical approval: Ethical approval was not applicable.

Author Contributions

Pia Kokemohr: Conceptualization, Data curation, Formal analysis, Writing original draft, Study design. Lars Haeder: Data curation, Supervision. Fabian Joachim Frömmling: Formal analysis, Supervision, Methodology. Peter Landwehr: Donation of figures. Joachim Jähne: Writing-review & editing, Project administration, Validation, Study design.

References

- [1] Yildiz SY, Kendirci M, Akbulut S, Ciftci A, Turgut HT, Hengirmen S. Colorectal emergencies associated with penetrating or retained foreign bodies. *World J Emerg Surg* 2013;8:25.
- [2] Lake JP, Essani R, Petrone P, Kaiser AM, Asensio J, Beart RW Jr. Management of retained colorectal foreign bodies: predictors of operative intervention. *Dis Colon Rectum* 2004;47:1694–1698.
- [3] Goldberg JE, Steele SR. Rectal foreign bodies. *Surg Clin North Am* 2010;90:173–184.
- [4] Kurer MA, Davey C, Khan S, Chintapatla S. Colorectal foreign bodies: a systematic review. *Colorectal Dis* 2010;12:851–861.
- [5] Anderson KL, Dean AJ. Foreign bodies in the gastrointestinal tract and anorectal emergencies. *Emerg Med Clin North Am* 2011;29:369–400.
- [6] Lim KJ, Kim JS, Kim BG, et al. Removal of rectal foreign bodies using tenaculum forceps under endoscopic assistance. *Intest Res* 2015;13:355–359.
- [7] Bak Y, Merriam M, Neff M, Berg DA. Novel approach to rectal foreign body extraction. *JLS* 2013;17:342–345.
- [8] Lin XD, Wu GY, Li SH, Wen ZQ, Zhang F, Yu SP. Removal of a large foreign body in the rectosigmoid colon by colonoscopy using gastrolith forceps. *World J Clin Cases* 2016;4:135–137.
- [9] Cawich SO, Mohammed F, Spence R, Albert M, Naraynsingh V. Colonic foreign body retrieval using a modified TAMIS technique with standard instruments and trocars. *Case Rep Emerg Med* 2015;2015:815616.
- [10] Andrabi SI, Johnson NA, Malik AH, Ahmed M. Extraction of a rectal foreign body – an alternative method. *Ulus Travma Acil Cerrahi Derg* 2009;15:403–405.
- [11] Huang WC, Jiang JK, Wang HS, et al. Retained rectal foreign bodies. *J Chin Med Assoc* 2003;66:607–612.
- [12] Cawich SO, Thomas DA, Mohammed F, Bobb NJ, Williams D, Naraynsingh V. A management algorithm for retained rectal foreign bodies. *Am J Mens Health* 2017;11:684–692.
- [13] Clarke DL, Buccimazza I, Anderson FA, Thomson SR. Colorectal foreign bodies. *Colorectal Dis* 2005;7:98–103.
- [14] Coskun A, Erkan N, Yakan S, Yildirim M, Cengiz F. Management of rectal foreign bodies. *World J Emerg Surg* 2013;8:11.
- [15] Ayantunde AA, Unluer Z. Increasing trend in retained rectal foreign bodies. *World J Gastrointest Surg* 2016;8:679–684.
- [16] Rodriguez-Hermosa JI, Codina-Cazador A, Ruiz B, Sirvent JM, Roig J, Farres R. Management of foreign bodies in the rectum. *Colorectal Dis* 2007;9:543–548.
- [17] Cohen JS, Sackier JM. Management of colorectal foreign bodies. *J R Coll Surg Edinb* 1996;41:312–315.
- [18] Odagiri H, Yasunaga H, Matsui H, Fushimi K, Iizuka T, Kaise M. Difference in outcomes of rectal foreign bodies between males and females: a retrospective analysis of a national inpatient database in Japan. *Digestion* 2015;92:165–170.
- [19] Cologne KG, Ault GT. Rectal foreign bodies: what is the current standard? *Clin Colon Rectal Surg* 2012;25:214–218.
- [20] Karateke F, Das K, Ozyazici S, Menekse E, Koseoglu Z, Karcioğlu O. Anorectal injuries due to foreign bodies: case reports and review of the management options. *Case Rep Surg* 2013;2013:809592.
- [21] Hellinger MD. Anal trauma and foreign bodies. *Surg Clin North Am* 2002;82:1253–1260.
- [22] Gajjar RA, Gupta PB. Foreign body in the rectum: a challenge for the emergency physician. *J Family Med Prim Care* 2016;5:495–497.
- [23] Koornstra JJ, Weersma RK. Management of rectal foreign bodies: description of a new technique and clinical practice guidelines. *World J Gastroenterol* 2008;14:4403–4406.
- [24] Sayilir A, Duzgun IN, Guvendi B. Treatment of unusual rectal foreign body using a Foley catheter. *Endoscopy* 2014;46:182–183.

- [25] Berghoff KR, Franklin ME Jr. Laparoscopic-assisted rectal foreign body removal: report of a case. *Dis Colon Rectum* 2005;48:1975–1977.
- [26] Rispoli G, Esposito C, Monachese TD, Armellino M. Removal of a foreign body from the distal colon using a combined laparoscopic and endoanal approach: report of a case. *Dis Colon Rectum* 2000;43:1632–1634.
- [27] Volpi A, Panebianco A, Ialongo P, et al. Colorectal retained foreign bodies per anum introduced. Three years retrospective study at emergency surgery unit. *G Chir* 2012;33:411–414.

Supplemental Material: The article (DOI: 10.1515/iss-2017-0021) offers reviewer assessments as supplementary material.

Reviewer Assessment

Open Access

Pia Kokemohr*, Lars Haeder, Fabian Joachim Frömling, Peter Landwehr and Joachim Jähne

Surgical management of rectal foreign bodies: a 10-year single-center experience

DOI 10.1515/iss-2017-0021

Received March 30, 2017; accepted April 19, 2017

*Corresponding author: Pia Kokemohr,

Clinic for General and Digestive Surgery, Center for Endocrine, Oncologic and Metabolic Surgery, DIAKOVERE Henriettenstift, Marienstraße 72-90, D-30171 Hannover, Germany, E-mail: Pia.Kokemohr@diakovere.de

Reviewers' Comments to Original Submission

Reviewer 1: Grzegorz Wallner

Apr 18, 2017

Reviewer Recommendation Term:	Accept
Overall Reviewer Manuscript Rating:	N/A
Custom Review Questions	Response
Is the subject area appropriate for you?	4
Does the title clearly reflect the paper's content?	5 - High/Yes
Does the abstract clearly reflect the paper's content?	5 - High/Yes
Do the keywords clearly reflect the paper's content?	5 - High/Yes
Does the introduction present the problem clearly?	4
Are the results/conclusions justified?	4
How comprehensive and up-to-date is the subject matter presented?	5 - High/Yes
How adequate is the data presentation?	4
Are units and terminology used correctly?	5 - High/Yes
Is the number of cases adequate?	4
Are the experimental methods/clinical studies adequate?	4
Is the length appropriate in relation to the content?	4
Does the reader get new insights from the article?	3
Please rate the practical significance.	3
Please rate the accuracy of methods.	4
Please rate the statistical evaluation and quality control.	4
Please rate the appropriateness of the figures and tables.	5 - High/Yes
Please rate the appropriateness of the references.	4
Please evaluate the writing style and use of language.	4
Please judge the overall scientific quality of the manuscript.	4
Are you willing to review the revision of this manuscript?	Yes

Comments to Authors:

The article concerns a potentially rare clinical problem, but with increasing tendency. The lack of scientific data, only retrospective evidence make that this paper is interesting only in terms as a case report. It is valuable only due to the number of analyzed cases, with good documentation. First of all - this paper is useful for residents and young surgeons. From the scientific point of view - nothing new in general knowledge, clinical practice or terms of originality novelty in diagnosis, therapy, surgical techniques etc. The paper is suitable for publication in chapter "Case reports".

Reviewer 2: Heinz-Jochen Gassel

Apr 19, 2017

Reviewer Recommendation Term:

Accept

Overall Reviewer Manuscript Rating:

N/A

Custom Review Questions**Response**

Is the subject area appropriate for you?	5 - High/Yes
Does the title clearly reflect the paper's content?	5 - High/Yes
Does the abstract clearly reflect the paper's content?	5 - High/Yes
Do the keywords clearly reflect the paper's content?	5 - High/Yes
Does the introduction present the problem clearly?	5 - High/Yes
Are the results/conclusions justified?	5 - High/Yes
How comprehensive and up-to-date is the subject matter presented?	5 - High/Yes
How adequate is the data presentation?	5 - High/Yes
Are units and terminology used correctly?	5 - High/Yes
Is the number of cases adequate?	4
Are the experimental methods/clinical studies adequate?	5 - High/Yes
Is the length appropriate in relation to the content?	4
Does the reader get new insights from the article?	4
Please rate the practical significance.	5 - High/Yes
Please rate the accuracy of methods.	5 - High/Yes
Please rate the statistical evaluation and quality control.	N/A
Please rate the appropriateness of the figures and tables.	4
Please rate the appropriateness of the references.	5 - High/Yes
Please evaluate the writing style and use of language.	5 - High/Yes
Please judge the overall scientific quality of the manuscript.	4
Are you willing to review the revision of this manuscript?	Yes

Comments to Authors:

-