

Intracranial solitary fibrous tumor

Report of two cases

Lian-Jie Sun, MM^a, Jun Dong, MM^a, Feng Gao, MM^a, Dong-Ming Chen, MM^a, Ke Li, MM^a, Jiang Liu, PhD^b, Cheng Zhang, MM^a, Maitiyiming Tohti, MM^a, Xiao-Peng Yang, MM^{a,*}

Abstract

Rationale: Intracranial solitary fibrous tumor (ISFT) is a rare spindle cell tumor derived from dendritic mesenchymal cells expressing CD34 antigens, which are widely distributed in human connective tissues.

Patient concerns: In two case reports, we describe a 61-year-old woman and a 42-year-old man who present with intracranial malignant SFTs. Computed tomography or magnetic resonance imaging of head revealed that the largest size is about 3.3 × 3.0 cm in left occipital part and 4.0 × 3.0 cm in right skull base.

Diagnosis: Postoperative pathological results demonstrated that all of two cases are SFT. Case one: Immunohistochemical examination demonstrated a strong immunoreaction for cluster of differentiation (CD)34, B-cell lymphoma 2 (Bcl-2) and Vimentin (Vim). Case two: The tumor was distinctively positive for Bcl-2, but not for CD34 and Vim.

Interventions: One of the two patients recurred 6 years after the first tumor resection. After the recurrence, two gamma knife treatments were given, and another operation was performed about five years later. In one case, only tumor resection was performed.

Outcomes: Case one: The postoperative neurological status was substantially improved and regular follow-up examinations for 6 months postsurgery have shown that the patient is currently disease-free. Case two: The patient achieved a good outcome, with no epilepsy or other neurological symptoms experienced on a regular 6-month follow-up. The patient is currently disease free.

Lessons: Imaging findings can be used to assist the diagnosis. The diagnostic method is pathology, and total surgical resection is the most effective treatment. The main treatment methods were total resection, supplemented by radiotherapy and chemotherapy if necessary.

Abbreviations: Bcl-2 = B-cell lymphoma 2, CD34 = cluster of differentiation 34, CT = computed tomography, DWI = diffusion weighted imaging, EMA = epithelial membrane antigen, GFAP = glial fibrillary acidic protein, GTR = gross total resection, ISFTs = intracranial solitary fibrous tumors, MRI = magnetic resonance imaging, PR = partial resection, STR = subtotal resection, T1WI = T1-weighted imaging, T2WI = T2-weighted imaging, Vim = vimentin, WHO = World Health Organization.

Keywords: intracranial, meningioma, solitary fibrous tumor, tumor

Editor: N/A.

L-JS and JD authors contributed equally to this work.

Ethical approval was given by the medical ethics committee of People's Hospital of Xinjiang Uygur Autonomous region, China. The certificate number is KY20180118100.

The datasets used during the present study are available from the corresponding author upon reasonable request.

The authors have no conflicts of interest to declare.

^a Department of Neurosurgery, People's Hospital of Xinjiang Uygur Autonomous Region, Urumqi, ^b Department of Neurosurgery, China-Japan Friendship Hospital, No. 2, Yinghua East St., ChaoYang District, Beijing, China.

* Correspondence: Xiao-Peng Yang, Department of Neurosurgery, People's Hospital of Xinjiang Uygur Autonomous Region, No. 91, Tianchi Road, TianShan District, Urumqi 830001, China (e-mail: yxp9972@sina.com).

Copyright © 2019 the Author(s). Published by Wolters Kluwer Health, Inc. This is an open access article distributed under the terms of the Creative Commons Attribution-Non Commercial-No Derivatives License 4.0 (CCBY-NC-ND), where it is permissible to download and share the work provided it is properly cited. The work cannot be changed in any way or used commercially without permission from the journal.

Medicine (2019) 98:17(e15327)

Received: 13 November 2018 / Received in final form: 17 March 2019 /

Accepted: 25 March 2019

<http://dx.doi.org/10.1097/MD.00000000000015327>

1. Introduction

Intracranial solitary fibrous tumor (ISFT) is a rare spindle cell tumor derived from dendritic mesenchymal cells expressing CD34 antigens, which are widely distributed in human connective tissues. Intracranial solitary fibrous tumor (ISFTs) is a rare tumor, Carneiro et al^[1] first described 7 cases of central nervous system SFT in 1996, ISFTs mostly originated from meninges. In 2007, World Health Organization (WHO) classified the tumors of the central nervous system into the mesenchymal tumors of meningeal tumors,^[2] which is a new pathological type. Because the tumor is easily misdiagnosed before operation, the present study provides the clinical data of 2 patients with SFT confirmed by postoperative clinicopathology, with a discussion of the possible differential diagnosis. The patients provided written informed consent.

2. Case report

2.1. Case one

A 61-year-old woman admitted to hospital on May 13, 2017, with left cerebellar meningioma 11 years after operation,

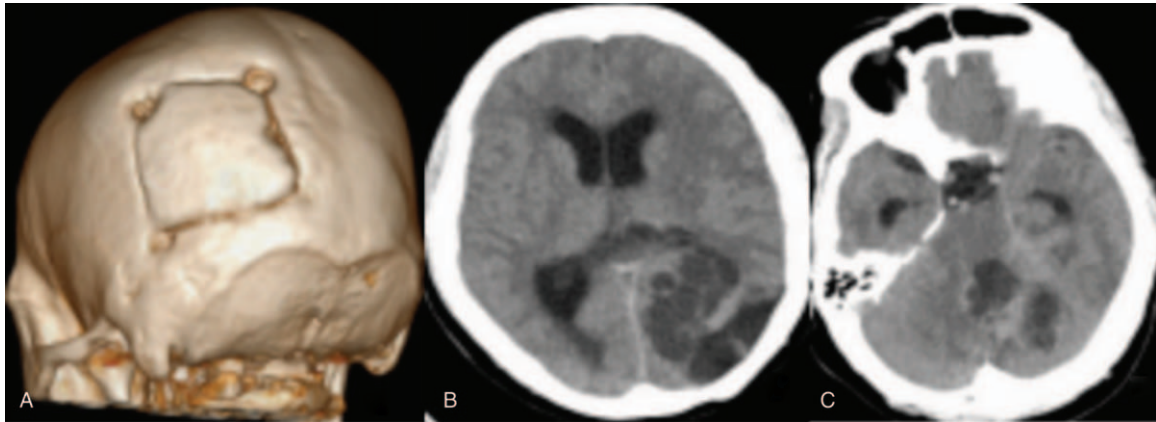


Figure 1. Cranial CT, 3D plain scan before admission. (A) Left occipital bone uncontinuous. (B and C) Multiple circular mixed density shadows are seen in the left cerebellar hemisphere and above and below the tentorium cerebelli, with the largest size being about 3.3×3.0 cm.

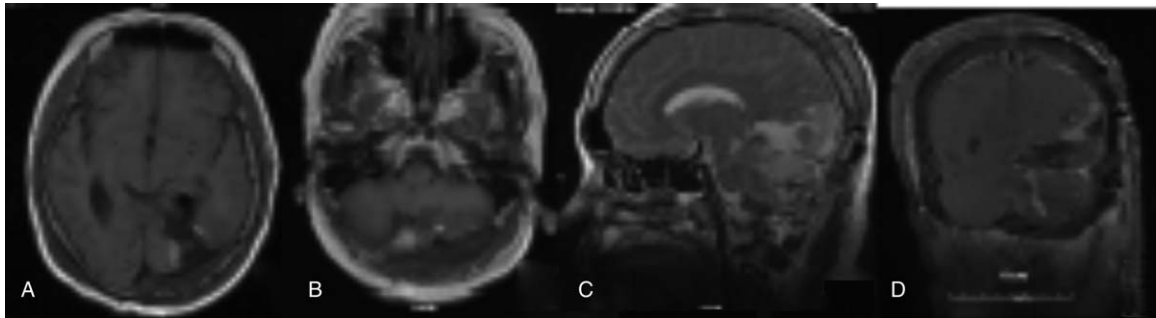


Figure 2. Postoperative cranial MRI after admission. (A+B) T1W1. (C) T2W1. (D) Coronal enhanced scanning.

headache and dizziness for 2 months. The patient had been diagnosed with a meningioma on the left parietal occipital lobe and was treated successfully by tumor resection 11 years earlier. The patient was treated with gamma knife twice because of the recurrence of intracranial tumor in August 28 and November 29, 2012. Cranial computed tomography (CT), 3D plain scan before admission (Fig. 1). MRI plain scan and enhancement after operation show that left parietal occipital lobe irregular slice long T1 and long T2 signal intensity, multiple patchy hyperintense

images were seen at the edge of T1 sequence. The side of the left lateral ventricle and bilateral cerebellar hemispheres showed long T1 and long T2 signal intensity, high signal intensity in FLAIR, DWI, and short T1 signal intensity in the lesion of cerebellum (Fig. 2). The largest size is about 3.3×3.0 cm. Microscopic immunohistochemical examination demonstrated a strong immunoreaction for CD34, Vim and Bcl-2, but a negative reaction for EMA and S-100 (Fig. 3). The frozen section analysis confirmed the presence of spindle cells and confirmed a diagnosis

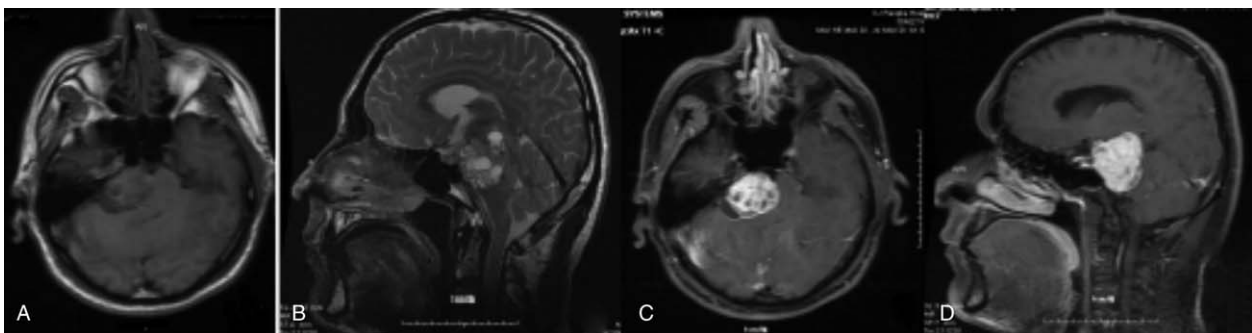


Figure 3. Cranial MRI. (A) T1W1. (B) T2W1. (C) Axial enhanced scanning. (D) Coronal enhanced scanning.




Figure 4. Postoperative pathological results after admission. WHOIII level, (left occipital) solitary fibrous tumor.

of an SFT. The postoperative neurological status was substantially improved and regular follow-up examinations for 6 months postsurgery have shown that the patient is currently disease-free.

2.2. Case two

A 42-year-old man admitted to hospital on September 21, 2015, with headache, dizziness, more than 2 months, weakness in limbs, poor speech, and unstable walking. No relevant past medical history. Preoperative MRI plain scan and enhanced display ring cistern, right cerebellopontine angle area irregular soft tissue mass, about the size of 40×31 mm, mixed T1 slightly longer T2 signal, multiple small cystic long T1 and long T2 signals were found in it (Fig. 4). Irregular soft tissue mass was seen in the right cerebellopontine angle area and cisterna ambiens, which was about 4.0×3.0 cm. The tumor was distinctively positive for Bcl-2, but not for S-100, CD34, Vim, and EMA (Fig. 5). The patient achieved a good outcome, with no epilepsy or other neurological symptoms experienced on a regular 6-month follow-up. The patient is currently disease-free.

3. Discussion

Usually, SFTs are slow-growing tumors with favorable prognosis, although there have been a small number of malignant cases. The specific manifestations vary according to the size and location of the tumor. Preoperative imaging is mainly used to determine the size, location, and peripheral structure of the tumor, make the operative plan and make the preliminary diagnosis. ISFT is usually shown as a benign process, and gross total resection (GTR) is the best way to treat it. ISFTs should be distinguished from the following types of intracranial tumors: meningiomas, hemangiopericytoma, and neurilemmoma.

3.1. Clinical characteristics

ISFT occurs mostly in the posterior cranial fossa, as well as in falx cerebri, facies convexa cerebri, and dura mater spinalis.^[3] Bai Yuzhen et al^[4] found that the focus of the cerebellopontine angle area was mainly located on the right side. This is consistent with the SFT location of the cerebellopontine angle area multiple articles case reports. ISFTs are common in adults with no

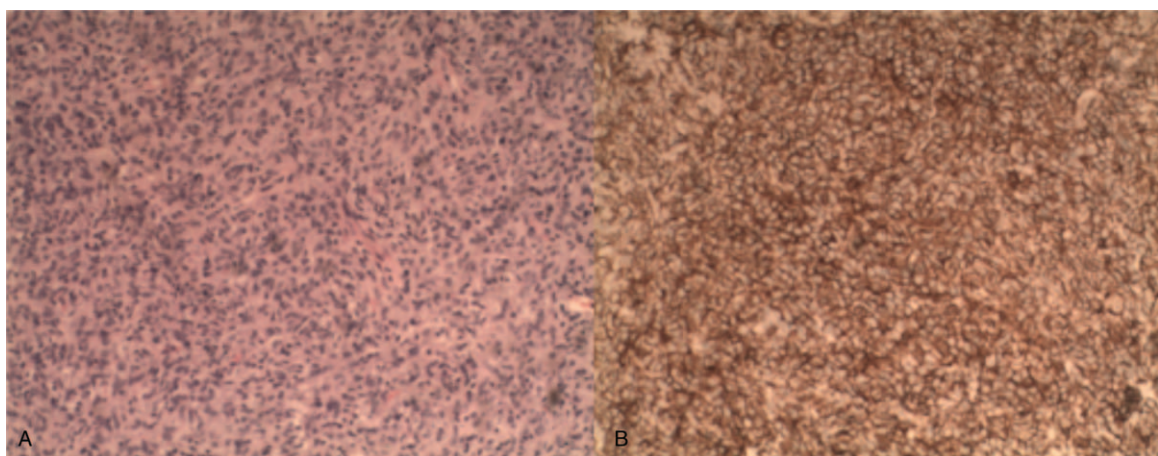


Figure 5. Postoperative pathological. (right skull base) solitary fibrous tumors.

significant gender difference. Most of ISFTs are benign tumors, which grow slowly, and the clinical symptoms are not obvious. The main manifestations are local compression and intracranial hypertension caused by tumor occupying.

3.2. Imaging features

CT plain scan showed round or circular lesions with clear boundary, with equal, slightly high and high density, which might be related to different tissue composition. Its equal density, slightly higher density may include some collagen fiber components, while high density may be related to the rich fusiform cells and its arrangement. The enhancement scan showed obvious homogeneous or uneven enhancement. YC Weon et al^[5] retrospectively reviewed CT, MRI, and angiographic findings in 6 cases of ISFTs, all 5 cases of cystic solid, and 5 cases of the tumors showed obvious uneven enhancement on CT plain scan. T1WI usually shows equal signal (compared with ectocinerea); T2WI showed more changes, its dense collagen fibers showed low signal intensity, tumor cell dense area showed slightly high signal intensity, tumor mucus degeneration, necrosis, and vascular interstitial area showed high signal intensity. Combined with this group of cases and related literature,^[6] the following five imaging findings can help in the diagnosis of ISFTs: First, tumor sites are often superficial. Second, high and low mixed signals on tumor T2WI. Third, the low signal intensity of T2WI is significantly enhanced after enhancement. Fourthly, peritumoral edema was not obvious. Last, DWI showed high signal. MRI is an important auxiliary examination for the diagnosis of ISFTs.

3.3. Pathological feature

In case two, the expression of Vim and CD34 was negative and the expression of Bcl-2 was positive, all of them were positive in case one. It was reported that when vimentin and CD34 was negative, the positive expression of bcl-2 was helpful to the diagnosis of ISFTs. Yokoi et al^[7] suggested that the expression of CD34 might be related to the nature of tumor. Research reports that malignant SFT tends to lack CD34 immune response, while overexpression of P53, S100 and Ki-67.^[8,9] In this study, CD34 (-), Ki-67 (20%), p53 (-), and S-100 (-) in case 2 were not consistent with the results reported in the literature. Some studies have found that compared with CD34, the specificity and sensitivity of ALDH1 immunohistochemical staining in the diagnosis of ISFTs are about 100%.^[10]

3.4. Therapeutical options and follow-up management

Surgery is the only current treatment for SFT of intracranial and intraspinal locations. The tumors are usually well circumscribed and often amenable to gross total resection. There is a 16-fold increase in the risk of recurrence in patients with subtotal resection (STR) or partial resection (PR) versus GTR.^[11] Radiotherapy and chemotherapy are mainly used for STR or PR, malignant or recurrent lesions. Wang et al^[12] found no recurrence report after GTR. If the central or peripheral nervous system is infiltrated, STR of tumor often leads to the recurrence of tumor; therefore, long term follow-up should be given to the patients of STR or PR. Because ISFTs have the pathological manifestation of angiopericytoma, angiogenesis antagonistic drugs have been used in the clinic, but the curative effect

remains to be observed.^[13] Follow-up for the usual SFT of the central nervous system completely resected may include annual imaging for 5 years and every 5 years thereafter.^[14] Close follow-up is mandatory with biannual MRI scans for cases in which tumor removal was incomplete and for those with atypical histological features or a high proliferation index.^[15] Extended follow-up is suggested in all cases, including for those completely removed and/or with usual histology.^[15]

3.5. Differential diagnosis with other intracranial tumors

ISFTs should be distinguished from the following types of intracranial tumors:

- (1) Meningiomas, especially fibrous meningiomas. In meningiomas, CD34 is negative, EMA and S-100 are positive; in ISFTs, the opposite is true.^[8] Meningiomas are common in middle-aged women, but no significant gender difference in SFT. Most meningiomas show homogenous isointense signals on T2WI, enhanced scanning with obvious homogeneous enhancement. Calcification, adjoining skull hyperplasia, and meningeal tail sign are more common.^[16] However, ISFTs were mostly attached to meninges, and adjacent skulls can be eroded, in which calcification, hyperplasia, and meningeal tail sign are rare.
- (2) Hemangiopericytoma^[17]: Most of CD34 were focal or flaky weakly positive. Most of T1WI showed low to isobaric signal, vascular emptiness could be seen in the tumor, and T2WI showed high signal intensity.
- (3) Neurilemmoma^[18]: Acoustic neurilemmoma that occurs mainly in the CPA area, with the internal auditory canal at the center of the growth, showing enlargement of the internal auditory canal on the affected side. T1WI showed low signal, slightly low signal, or low-equal mixed signal, and T2WI showed high signal or high signal mainly hybrid signal. S-100 protein was positive in immunohistochemistry, Leu-7 and myelin basic proteins were also positive.

4. Conclusions

ISFT is a rare intracranial tumor. It is easy to be misdiagnosed as meningioma or other tumors. The clinical manifestation of ISFTs mainly depends on the size and location of the tumor. Imaging findings can be used to assist the diagnosis. The diagnostic method is pathology, and total surgical resection is the most effective treatment. One of the two patients recurred 6 years after the first tumor resection. The recurrence was considered as not being completely resected for the first time. After the recurrence, two gamma knife treatments were given, and another operation was performed about five years later. It can be seen that gamma knife therapy can control the tumor growth rate to some extent, but because of the small number of cases, its therapeutic effect needs to be confirmed in more cases.

Author contributions

Conceptualization: Lian-Jie Sun, Dong-Ming Chen, Cheng Zhang, Xiao-Peng Yang.

Data curation: Lian-Jie Sun.

Formal analysis: Lian-Jie Sun.

Funding acquisition: Lian-Jie Sun.

Investigation: Lian-Jie Sun, Jiang Liu, Maitiyiming Tohti.

Methodology: Lian-Jie Sun, Jiang Liu, Feng Gao, Maitiyiming Tohti.

Project administration: Lian-Jie Sun, Jiang Liu, Feng Gao.

Resources: Lian-Jie Sun, Jiang Liu, Feng Gao, Dong-Ming Chen, Ke Li, Cheng Zhang.

Software: Feng Gao, Dong-Ming Chen, Ke Li, Cheng Zhang.

Supervision: Feng Gao, Ke Li, Jun Dong.

Validation: Dong-Ming Chen, Ke Li, Jun Dong.

Visualization: Dong-Ming Chen, Ke Li, Jun Dong, Cheng Zhang.

Writing – original draft: Jun Dong.

Writing – review & editing: Jun Dong, Xiao-Peng Yang.

References

- [1] Carneiro SS, Scheithauer BW, Nascimento AG, et al. Solitary fibrous tumor of the meninges: a lesion distinct from fibrous meningioma. A clinicopathologic and immunohistochemical study. *Am J Clin Pathol* 1996;106:217–24.
- [2] Jiang N, Xie YY, Chen W, et al. Solitary fibrous tumor of the central nervous system: a clinical and prognostic study of 24 cases. *World Neurosurg* 2016;99:584–92.
- [3] Moritani S, Ichihara S, Hasegawa M, et al. Dedifferentiation and progression of an intracranial solitary fibrous tumor: autopsy case of a Japanese woman with a history of radiation therapy of the head during infancy. *Pathol Int* 2015;61:143–9.
- [4] Yuzhen B, Guangming N, Yang G, et al. MRI features of solitary fibrous tumor in the central nervous system. *J Clin Radiol* 2016;35:1473–7.
- [5] Weon YC, Kim EY, H-J K, et al. Intracranial solitary fibrous tumors: imaging findings in 6 consecutive patients. *Am J Neuroradiol* 2007;28:1466–9.
- [6] Ginat DT, Aqiba B, Shweta B, et al. Imaging features of solitary fibrous tumors. *AJR Am J Roentgenol* 2011;196:487–95.
- [7] Yatabe Y. Solitary fibrous tumour: significance of p53 and CD34 immunoreactivity in its malignant transformation. *Histopathology* 2010;32:423–32.
- [8] Cummings TJ, Burchette JL, Mclendon RE. CD34 and dural fibroblasts: the relationship to solitary fibrous tumor and meningioma. *Acta Neuropathol* 2001;102:349–54.
- [9] Hanau CA, Miettinen M. Solitary fibrous tumor: histological and immunohistochemical spectrum of benign and malignant variants presenting at different sites. *Human Pathol* 1995;26:440.
- [10] Bouvier C, Bertucci F, Métellus P, et al. ALDH1 is an immunohistochemical diagnostic marker for solitary fibrous tumours and haemangiopericytomas of the meninges emerging from gene profiling study. *Acta Neuropathol Commun* 2013;1:10.
- [11] Pasquali S, Gronchi A, Strauss D, et al. Resectable extra-pleural and extra-meningeal solitary fibrous tumours: a multi-centre prognostic study. *Eur J Surg Oncol* 2016;42:1064–70.
- [12] Wang ZY, Qiu K, Ma YH, et al. Intracranial solitary fibrous tumors: a report of two cases and a review of the literature. *Oncol Lett* 2015;11:1057.
- [13] Claus E, Seynaeve P, Ceuppens J, et al. Intracranial solitary fibrous tumor. *Eur J Radiol* 2017;101:387–94.
- [14] Jallo GI, Chanland R, Karl K, et al. Spinal solitary fibrous tumors: a series of four patients: case report. *Neurosurgery* 2005;57:E195discussion E.
- [15] Michele B, Carlos G, Giuseppe G, et al. Solitary fibrous tumor of the central nervous system: a 15-year literature survey of 220 cases (August 1996–July 2011). *Adv Anat Pathol* 2011;18:356–92.
- [16] Keraliya AR, Tirumani SH, Shinagare AB, et al. Solitary fibrous tumors: 2016 imaging update. *Radiol Clin North Am* 2016;54:565–79.
- [17] Stout AP, Murray MR. Hemangiopericytoma: a vascular tumor featuring Zimmermann's pericytes. *Ann Surg* 1942;116:26.
- [18] Yamamoto H, Fujita A, Imahori T, et al. Focal hyperintensity in the dorsal brain stem of patients with cerebellopontine angle tumor: a high-resolution 3 T MRI study. *Sci Rep UK* 2018;8:1–6.