




# Management of Covid Associated Mucormycosis of Mandible: A Mountain Beneath a Molehill—A Lesson Learnt

Saubhik Dasukil<sup>1</sup> · Kiran Kumar Boyina<sup>2</sup> · Saurav Sarkar<sup>3</sup>  ·  
Vinaykumar Hallur<sup>4</sup> · Anindya Nayak<sup>3</sup> · Abhijeet Kumar Mishra<sup>3</sup> ·  
KV Aswathi<sup>3</sup> · Chappity Preetam<sup>3</sup> · Pradipta Kumar Parida<sup>3</sup>

Received: 22 September 2021 / Accepted: 2 October 2021  
© Association of Otolaryngologists of India 2021

**Abstract** The opportunistic infection of post-Covid associated mucormycosis has been reported globally; however, it has reached alarming proportions in India. Mucormycosis of the mandibular region is rare, and only a few cases have been reported to date. Covid associated mucormycosis has not been reported in the literature before, and we are the first to report them. We report two patients who presented with tooth loosening with pus discharge a few weeks following recovery from Covid infection. After tooth extraction adjacent necrotic bony specimen was sent for calcofluor potassium hydroxide mount, which was found positive for broad pauciseptate hyphae. Although CT scan imaging demonstrated the involvement of a mandible segment, we found a much more extensive involvement in both cases during resection. There was intramedullary spread of the mucormycosis throughout the inferior alveolar canal, with pus discharge and foul odor. The management of covid associated mandibular mucormycosis consists of surgical debridement with antifungal therapy and control of the underlying disease. It became challenging because the radiological extent of the disease was different from the definite clinical extension of the lesion found during surgery. The authors recommend surgeons adopt a flexible approach during surgery to plan resection depending on the clinical judgment and not rely entirely on

CT scans. And the reconstruction of the mandible will follow as per the extent of excision.

**Keywords** Mandibular mucormycosis · COVID associated mucormycosis · Fungal epidemic

## Introduction

While the world is trying to recover from the clutches of the deadly virus causing COVID -19, India is hit with a severe and potentially fatal fungal epidemic of mucormycosis. In past this angioinvasive disease was caused by fungi Mucoralean in individuals with various conditions of immune suppression like uncontrolled diabetes, corticosteroid therapy etc. [1, 2]. In a COVID—19 patient interaction of several factors like immune dysregulation, steroid therapy, exacerbation of preexisting diabetes may allow the mucoralean fungi to cause this disease [3]. The opportunistic infection of mucormycosis has been reported globally; however, it has reached alarming proportions in India. As of the second week of July 2021, 40,845 cases of mucormycosis have been reported in India, and 31,344 (76.7%) of these are rhino cerebral. [4] Mucormycosis of the mandibular region is unusual (Table 1), and to the best of our knowledge, no cases of COVID associated mandibular mucormycosis have been reported to date. Herein, we report three patients who presented with the covid associated mandibular mucormycosis.

✉ Saurav Sarkar  
doc.sauravsarkar@gmail.com

<sup>1</sup> Department of Dentistry, AIIMS, Bhubaneswar, India

<sup>2</sup> Department of TEM, AIIMS, Bhubaneswar, India

<sup>3</sup> Department of ENT and HNS, AIIMS, Bhubaneswar, India

<sup>4</sup> Department of Microbiology, AIIMS, Bhubaneswar, India

**Table 1** The list of articles found in literature with mandibular mucormycosis. Ours is the first, Covid associated mandibular mucormycosis (CAMM). Adapted form Agarwal et al. 2020

Sl No	Study type	Year	Author	Risk factor	Management	Outcome
1	CR	1986	Brown and Finn	Uncontrolled DM with Chronic kidney disease	Total maxillectomy + AMB	Death
2	CR	1993	Jones et al	AML with renal dysfunction	Surgical + AMB	Satisfactory resolution
3	CR	1997	Salisbury et al	AML/oral tobacco use/dental extraction	Surgical + AMB	Satisfactory resolution
4	CR	2006	Bakhtiar et al	1. AML/dental extraction 2. DM with DKA/ALL	Surgical + L-AMB for both	Resolution
5	CR	2007	Dogen et al	AML	Surgical + L-AMB	Death
6	CR	2010	Ojeda-Uribe M	AML/Uncontrolled DM	Surgical + ABLC + Caspofungin	Satisfactory resolution
7	CR	2012	Oswal et al	Uncontrolled DM	Surgical with 50 mg LAMB	Death
8	CR	2012	Mutan Hamdi Aras	1. AML 2. Neuroblastoma	1. Surgical + AMB 2. Surgical + AMB	Death Death
9	CR	2017	Mc Spadden et al	CML with post bone marrow transplant with Graft vs host disease	Surgical	Death
10	CR	2019	Cohen et al	1. B-ALL 2. ALL	Surgical (marginal madibulectomy) + LAMB	Satisfactory resolution followed by reconstruction of mandible
11	CR	2019	AB Urs et al	Dental extraction	Surgical with LAMB	Satisfactory resolution
12	CR	2020	Subham Agarwal et al	Renal dysfunction, Chronic granulomatous disease	Surgical debridement + LAMB + Posaconazole	Satisfactory resolution
13	CR	2020	Eun Jung Kwak et al	Uncontrolled DM AML	LAMB LAMB + Posaconazole	Satisfactory resolution
14	CR	2021	Our cases	Covid associated mucormycosis, DM	Mandibulectomy + reconstruction + AMB	Satisfactory healing

### Case 1

A 60-year-old male diabetic patient presented with pain and loosening of teeth 5 days following recovery from COVID-19. He was admitted to the general ward under oxygen support for 3 weeks with mild to moderate symptoms of COVID. He had received a single dose of Tocilizumab and injectable dexamethasone over 15 days of his hospital stay.

### Case 2

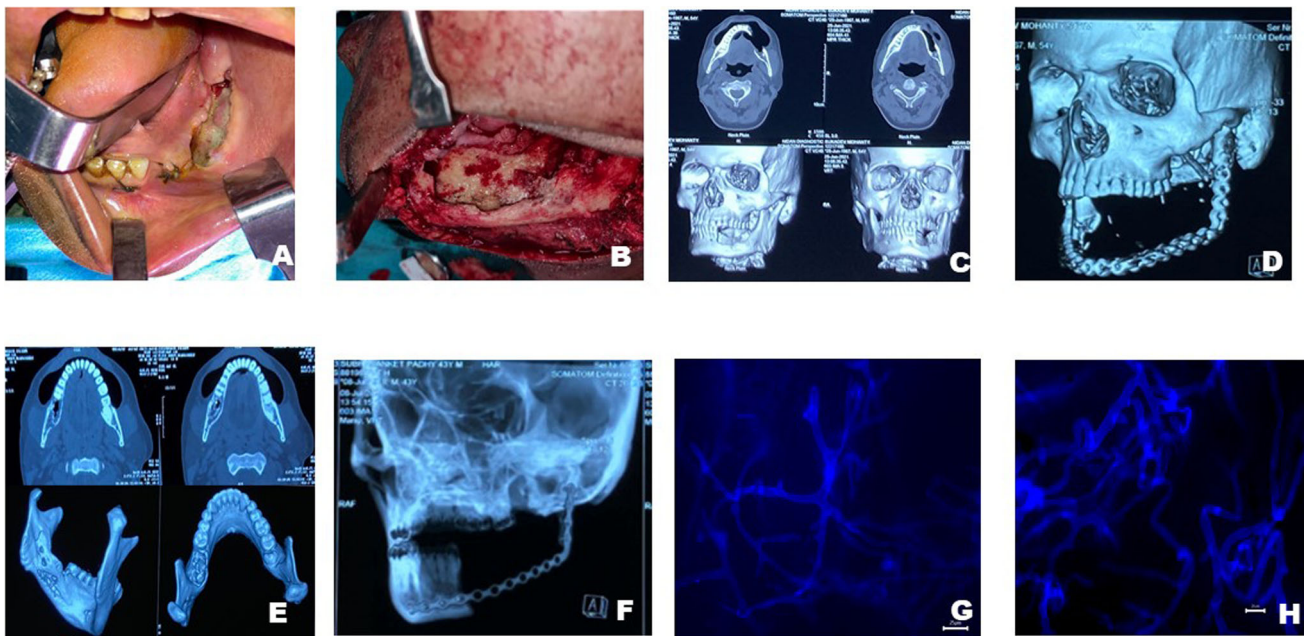
A 48-year-old male, the non-diabetic patient, had pain, pus discharge, and tooth mobility 1-week post covid. He was admitted to the hospital with oxygen support and treated

with steroid therapy (Tab Dexamethasone) for 2 weeks. The patient was developed diabetes post covid.

### Case 3

A 29-year female patient presented with gingival inflammation, pain, and tooth mobility 6 weeks after recovery from covid. She was a known case of diabetes mellitus and was on insulin therapy. The patient was admitted to the ICU 3 days after onset of COVID-19 symptoms and received a single dose of Tocilizumab and Injectable dexamethasone over 14 days of ICU admission.

All the patients had undergone extraction of offending tooth and the adjacent necrotic bony specimen was sent for calcofluor potassium hydroxide mount (KOH), which was positive for broad pauciseptate hyphae (Fig. 1).



**Fig. 1** a Photo showing involvement of the molar and premolar region of the alveolus of case 2, b Per-operative photo showing blackish areas of fungal involvement along the inferior alveolar canal case 2, c Pre-operative CT scan of case 2 with 3D reconstruction showing limited mandibular involvement, d Post-operative CT scan of case 2 with 3D reconstruction of the hemimandible and condylar process of the left side, e Pre-operative CT scan of case 1 with 3D

reconstruction showing involvement of the molar region of the alveolus, f Post-operative CT scan of case 1 with 3D reconstruction showing excision of a much larger portion of the mandible along with reconstruction, g and h Calcofluor KOH mount showing broad aseptate hyphae with perpendicular branching suggestive of mucormycosis

**Discussions**

The consensus for the management of mucormycosis is surgical debridement with antifungal therapy and control of the underlying disease [3–6].

In two (Case 1 and 2) patients, both, extraoral sub-mandibular and intraoral vestibular approach was adopted whereas, in case 3 surgical site exposure done through intraoral approach. The offending bone was resected until the healthy bone was encountered, as evidenced by bleeding edges. While imaging demonstrated the involvement of a segment of the mandible, we found a much larger involvement in two cases (Case 1 and 2) during resection. There was intramedullary spread of the mucormycosis throughout the entire course of the inferior alveolar canal with pus discharge and foul odor. In routine a CT scan is used for assessing disease extent, but the true extent of the disease in the mandible will be evident only during surgery. In Case 1, both sides of the mandible were involved sparing only the right condyle and ramus, while in the second patient (Case 2), only one side of the mandible was involved sparing the condyle head. In both cases, the

radiological extent of the pathology was different from the definite clinical extension of the lesion. This concealing nature of the pathology can be alarming, causing mismanagement of mandibular mucormycosis. Immediate bony reconstruction is debatable and should be deferred to a later date in cases of extensive mucormycosis [2]. In the two cases (Case 1 and 2), reconstruction of the defect was done using a titanium plate (2.8 mm) and screws that were pre-bent according to the contour of the bone. In case 1, the condylar replacement was done using a condylar implant (Stryker® India). However, in Case 3, lingual cortical bone and lower border of the mandible were spared.

The management of covid associated mandibular mucormycosis is challenging, especially because the radiology may not correlate with the actual extent of disease. Surgical planning needs to have a foreseeable leeway for modification based on the bone’s clinical extension or osteomyelitic changes. Patient counselling and planning for reconstruction should be kept flexible, and the patients should be involved in every part of planning during surgery. A mountain of clinical disease may hide behind a molehill of radiological evidence.

## Conclusion

Thus, the authors recommend an open mind and an eagle's eye to take a radical decision on resection margins and a flexible plan for the reconstruction of the defect to restore functional rehabilitation.

**Funding** The authors did not receive any financial support for this article.

## Declarations

**Conflict of interest** The authors declare no conflict of interest.

## References

1. Prakash H, Chakrabarti A (2021) Epidemiology of mucormycosis in India. *Microorganisms* 9(3):523

2. Pillsbury HC, Fischer ND (1977) Rhinocerebral mucormycosis. *Arch Otolaryngol* 103(10):600–604. <https://doi.org/10.1001/archotol.1977.00780270068011>
3. Moorthy A, Gaikwad R, Krishna S, Hegde R, Tripathi KK, Kale PG, Rao PS, Haldipur D, Bonanthaya K (2021) SARS-CoV-2, Uncontrolled diabetes and corticosteroids-An unholy trinity in invasive fungal infections of the maxillofacial region? A retrospective, multi-centric analysis. *J Maxillofac Oral Surg* 1–8. Advance online publication.
4. <https://www.livemint.com/news/india-records-over-40k-cases-of-mucormycosis> 11624875874985.html
5. Aras MH, Kara MI, Erkiliç S, Ay S (2012) Mandibular mucormycosis in immunocompromised patients: report of 2 cases and review of the literature. *J Oral Maxillofac Surg: Off J Am Assoc Oral Maxillofac Surg* 70(6):1362–1368
6. Agarwal S, Anand A, Ranjan P, Meena VP, Ray A, Dutta R, Jadon RS, Vikram NK (2020) Case of mucormycosis of mandible after self-extraction of teeth incidentally detected to have chronic granulomatous disease: case report and literature review. *Med Mycol Case Rep* 28:55–59

**Publisher's Note** Springer Nature remains neutral with regard to jurisdictional claims in published maps and institutional affiliations.