



HHS Public Access

Author manuscript

Am J Med Case Rep. Author manuscript; available in PMC 2019 August 27.

Published in final edited form as:

Am J Med Case Rep. 2019 ; 7(10): 236–239. doi:10.12691/ajmcr-7-10-4.

Rare Case of Bilateral Cerebellar Hemorrhage in a Male Boxer

Pramod Theetha Kariyanna^{1,#}, Alix Charles^{2,#}, Muhammad Faizan Ahmed³, Apoorva Jayarangaiah⁴, Sushruth Das⁵, Mohammed Al-Sadawi⁶, Madina Abduraimova⁶, Samy I. McFarlane^{6,*}

¹Division of Cardiovascular Disease, Department of Internal Medicine, State University of New York, Downstate Medical Center, Brooklyn, New York, U.S.A- 11203

²Ross University School of Medicine, Miramar, Portsmouth, Dominica- 00109

³Department of Internal Medicine, Brookdale University Hospital and Medical Center, Brooklyn, NY, U.S.A- 11203

⁴Department of Internal Medicine, NYC Health and Hospitals/Jacobi Medical Center, Bronx, New York, U.S.A-10461

⁵Base PU College, Rajajinagar, Bangalore, India- 560010

⁶Department of Internal Medicine, State University of New York: Downstate Medical Center, Brooklyn, New York, United States-11203

Abstract

The sport of boxing carries with it the risk of brain injury with acute and chronic neurological injuries such as contusion, concussion and intracranial bleeding has been reported. The force sustained from a boxing blow can be as powerful as being hit with a 6-kg wooden mallet striking at 20 mph. Bilateral cerebellar hemorrhage secondary to trauma is a rare entity that has not been reported in the literature previously. One can only speculate as to how a boxer could potentially develop a cerebellar bleed. Regardless of whether a very powerful punch or the act of falling back and hitting the occipital region directly on the floor, it is very likely that a predisposing factor exist. We present you a rare case of a 26 year-old male boxer who was knocked out in a boxing match and was noted to have acute parenchymal and subarachnoid hemorrhage bilaterally in the cerebellar hemispheres. Our report highlights the need to consider cerebellar bleed in boxers who present after ataxia after boxing/knocked out.

Keywords

bilateral cerebellar hemorrhage; boxing

This article is an open access article distributed under the terms and conditions of the Creative Commons Attribution (CC BY) license (<http://creativecommons.org/licenses/by/4.0/>).

*Corresponding author: Samy.mcfarlane@downstate.edu.

#These authors contributed equally to this work.

1. Introduction

The sport of boxing carries with it the risk of brain injury [1]. Cerebral microhemorrhages [2], brain stem hematoma [3], subdural hematoma [4] with boxing have been previously reported. Boxing related neurological damage can be acute or chronic [5]. Acute neurological injuries include concussion, intracranial hemorrhage, brain contusion and traumatic brain injury is among the chronic neurological changes from boxing [6]. Bilateral cerebellar hemorrhage secondary to trauma is a rare entity that has not been reported in the literature previously. We present you a rare case of a 26 year-old male boxer who was knocked out in a boxing match and was noted to have acute parenchymal and subarachnoid hemorrhage in bilateral cerebellar hemispheres.

2. Case Presentation

A 26 year old male presented with unsteady gait after he was knocked out in a boxing match. He was wearing a protective headgear however it slid during the match and subsequently, multiple strikes were sustained to the face and head. On arrival to the emergency department he was afebrile, heart rate was 123 beats/minute, blood pressure was 123/78 mmHg, and respiratory rate was 18 breath per minute. Physical examination of chest, heart and abdomen was within normal limits. Neurological examination has been summarized in Table 1. He was awake with Glasgow Coma Scale score (GCS) of 14 but had some memory impairment. His metabolic panel revealed Blood Urea Nitrogen (BUN) of 26 mg/dl, Creatinine (Cr) of 4.39 mg/d, creatinine phosphokinase (CPK) > 160,000U/L, potassium (K) of 8.1mEq/L and lactate of 5.8 mmol/L. Electrocardiography (EKG) revealed normal sinus rhythm with first degree atrioventricular block. EKG later revealed atrial fibrillation. Computed tomography (CT) of the head revealed acute parenchymal and subarachnoid hemorrhage in bilateral cerebellar hemispheres; left greater than right with surrounding edema (Figure 1). Magnetic resonance imaging of brain revealed subarachnoid hemorrhage in the cerebellar hemispheres bilaterally with moderate surrounding edema (Figure 2). Patient was subsequently intubated due to worsening mental status and acute respiratory failure. Continuous veno-venous hemodialysis (CVVHD) was initiated to manage acute renal failure, hyperkalemia and rhabdomyolysis. Neurosurgery performed ventriculostomy with drain which revealed clear cerebrospinal fluid that jetted out under pressure. Following ventriculostomy, the patient was noted to have absent brain reflexes with fixed and dilated pupils. Neurology evaluated the patient and declared him brain dead after positive apnea test.

3. Discussion

Boxing is a sport that consists of two opponents fighting with padded gloves that weighs between 8–10 ounces with the ultimate goal of either knocking out the opponent or delivering more punches before reaching the allotted time. Per the World Boxing Federation, allotted time for a boxing bout is described as a total of 10–12 rounds depending on the event with each round consisting of a 3-minute duration, with a 1-minute rest period between rounds. Fighters are grouped in different classes depending on their weight to assure a comparable fight [6]. Due to the nature of the sport, injuries are quite common and

according to Unterharnscheidt et al, intracranial injuries in boxing can affect any area of the brain. Especially involved are the large neurons of different layers of the cerebral cortex, and the purkinje cells of the cerebellum [7]. In one study, the overall incidence rate of injury in boxing was 17.1 per 100 boxer-matches or 3.4 per 100 boxer-rounds. Even more a high rate of injuries in boxing like lacerations to soft tissues or contusions are the most common [8] despite wearing padded gloves. Hand injuries have been found to be the second most common type of injuries. The force sustained from a boxing blow can be as powerful as being hit with a 6-kg wooden mallet striking at 20 mph [9]. Even though head injuries with neurological symptoms occur at a rate of 4.2% [10], it is no surprise that significant consequence even fatalities can happen if neurological dysfunction is sustained given how forceful and impactful a punch can be. Furthermore, fatigue and cognitive awareness starts to decline as a match goes on. This in turn leads to relaxation of cervical muscles, lowering the effective head mass resisting a head blow. The consequence of a lowered resistance to head blows puts a boxer at a high risk for head injuries due to increase in translational and rotational accelerations with each subsequent blow [11,12]. Intraparenchymal hemorrhage injuries are associated with linear acceleration [13] with subdural hemorrhage rates as high as 75% of all acute brain injuries and are the most common cause of death in boxing [14,15]. Unterharnscheidt further supports this finding in that the most common cause of death due to boxing injury is a subdural hemorrhage [7,11]. Cerebellar hemorrhages seem to be very rare and are hardly reported in the literature. One can only speculate as to how a boxer could potentially develop a cerebellar bleed. Regardless of whether a very powerful punch or the act of falling back and hitting the occipital region directly on the floor, it is very likely that a predisposing factor was the culprit. In a paper that examined the brain of 15 boxers, it would seem as though the most common cerebellar injuries were scarring, atrophy, fine fibrous gliosis and demyelination with considerable Purkinje and granule cell loss [16]. These ongoing changes in a boxer's cerebellar region with continuous repeated blows throughout one's career can predispose to an acute bleed if the right circumstances are met. In earlier works by Linderberg and Freytag, they described hemorrhage in the subarachnoid space between the folia of the tonsils. This damage has been ascribed to the brain being forced into the Foramen Magnum, which along the way caused shearing in the medulla oblongata and cerebellar tonsils [17]. Furthermore, authors believe that the origin of glial scarring and the loss of Purkinje cells probably transpired in a similar manner. While there isn't a lot of data in terms of management of acute cerebellar bleed sustained during or shortly after a boxing match, the management and outcome of subdural bleeds head injury in a study evaluating acute subdural hematoma caused by boxing, 10 boxers were compared against 26 non-boxers with acute subdural hematoma were classified into three groups in accordance to their consciousness level. Transient unconsciousness type consisted of boxers who had returned to alertness within an hour from the time of injury. Lucid interval type entailed boxers who presented with neurological deterioration with a lucid interval from ten minutes to an hour after knockout and thirdly a deterioration of consciousness type. After resuscitation measures, stabilization efforts and evaluation by a neurologist, all patients underwent an axial cranial CT. If acute neurological deterioration or increased intracranial pressure was subsequently noted on examination or ensuing CT, operative management was initiated. All 10 boxers in the study underwent extensive decompressive craniotomy within four hours of surgery and the mortality rate was reported to be 30% [17,18].

Correspondingly, Koyama et al reported a mortality rate of 33% when craniotomy was done within 2 hour [19].

4. Conclusion

We presented a rare case of bilateral cerebellar bleeding in a 26 year old boxer complicated by multi-organ failure and subsequently brain death. The case highlights the need to consider cerebellar bleeding in the differential diagnosis of boxing brain injury and the institution of prompt therapeutic interventions as the case requires.

Acknowledgements

This work is supported, in part, by the efforts of Dr. Moro O. Salifu M.D., M.P.H., M.B.A., M.A.C.P., Professor and Chairman of Medicine through NIH Grant number S21MD012474.

References

- [1]. Falvey ÉC, and McCrory Paul. "Because not all blows to the head are the same." *Br J Sports Med* 49 17 (2015): 1091–1093. [PubMed: 26282366]
- [2]. Lee JK, Wu J, Banks S, Bernick C, Massand MG, Modic MT, Ruggieri P, Jones SE. Prevalence of traumatic findings on routine MRI in a large cohort of professional fighters. *American Journal of Neuroradiology* 2017 7 1; 38(7): 1303–10. [PubMed: 28473342]
- [3]. Hart MG, Trivedi RA, Hutchinson PJ. Boxing sparring complicated by an acute subdural haematoma and brainstem haemorrhage. *British journal of neurosurgery* 2012 10 1; 26(5): 776–8. [PubMed: 22380874]
- [4]. Garfield J Acute subdural haematoma in a boxer. *British journal of neurosurgery* 2002 1 1; 16(2): 96–101. [PubMed: 12046746]
- [5]. Jordan BD. Neurologic aspects of boxing. *Archives of neurology* 1987 4 1; 44(4): 453–9. [PubMed: 3827699]
- [6]. World Boxing Federation Rules & Regulations of Championship Contest (n.d.). Retrieved November 24, 2018, from <http://www.worldboxingfederation.net/wbfrulesandregulations.htm>.
- [7]. Unterharnscheidt F "A neurologist's reflections on boxing. I: Impact mechanics in boxing and injuries other than central nervous system damage." *Revista de neurologia* 23121 (1995): 661–674. [PubMed: 8597990]
- [8]. Bledsoe Gregory H., Li Guohua, and Levy Fred. "Injury risk in professional boxing." *Southern medical journal* 9810 (2005): 994–999. [PubMed: 16295814]
- [9]. Atha J, Yeadon MR, Sandover J, Parsons KC. The damaging punch. *Br Med J (Clin Res Ed)* 1985 12 21;291(6511):1756–7.
- [10]. Siewe J, Rudat J, Zarghooni K, Sobottke R, Eysel P, Herren C, Knöll P, Illgner U, Michael J. Injuries in competitive boxing. A prospective study. *International journal of sports medicine* 2015 3; 36(03): 249–53. [PubMed: 25376728]
- [11]. Unterharnscheidt F Head injury after boxing. *Scand J Rehabil Med* 1972; 4(2): 77–84. [PubMed: 4645038]
- [12]. Miele VJ, Norwig JA, Bailes JE. Sideline and ringside evaluation for brain and spinal injuries. *Neurosurg Focus* 2006; 21(4): E8.
- [13]. Refshauge JG. The medical aspects of boxing. *Med J Aust* 1963; 1: 611–613. [PubMed: 13973620]
- [14]. Ommaya AK, Gennarelli TA. Experimental head injury: In Vinken & Bruyn (Eds) *Handbook of clinical neurology*, Vol. 23, pp. 67–90, North-Holland, Amsterdam, 1975.
- [15]. Kushi H, Saito T, Sakagami Y, Ohtsuki J, Tanjoh K. Acute subdural hematoma because of boxing. *Journal of Trauma and Acute Care Surgery* 2009 2 1; 66(2): 298–303.

- [16]. Corsellis JAN, Bruton CJ, and Freeman-Browne Dorothy. "The aftermath of boxing." *Psychological medicine* 33 (1973): 270–303. [PubMed: 4729191]
- [17]. Lindenberg R, and Freytag E (1960). The mechanism of cerebral contusions. *Archives of Pathology*, 69, 440–469. [PubMed: 14417116]
- [18]. Bullock R, Chesnut RM, Clifton G, et al. Guidelines for the management of severe traumatic brain injury. *J Neurotrauma* 2000; 17: 451–627.
- [19]. Koyama T, Suzuki T, Nakamura N. Acute subdural hematoma caused by boxing. *J Clin Sports Med (Jpn)* 1987; 4: 1032–1037.

Author Manuscript

Author Manuscript

Author Manuscript

Author Manuscript

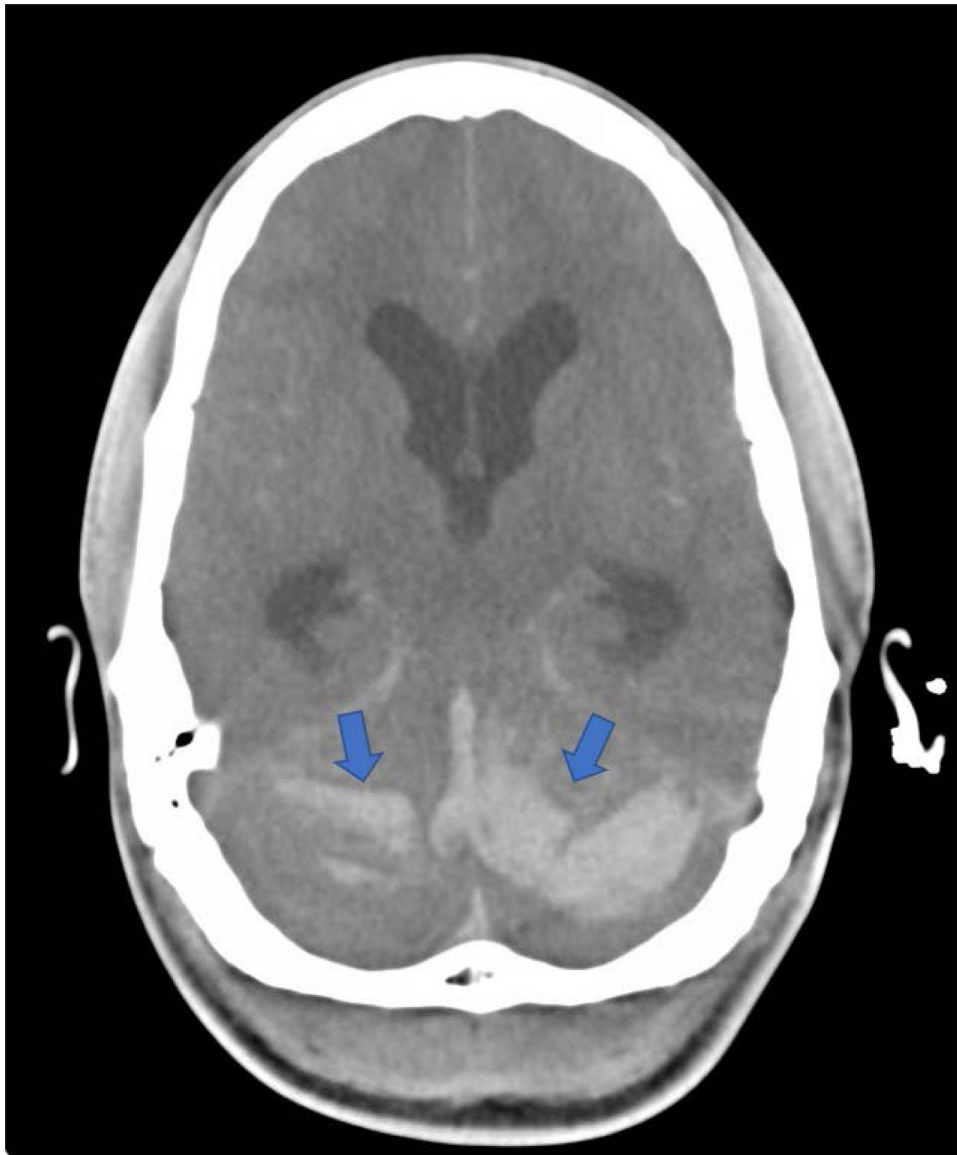


Figure 1.
CT brain demonstrating bilateral cerebellar hemorrhages with extension into the Vermis

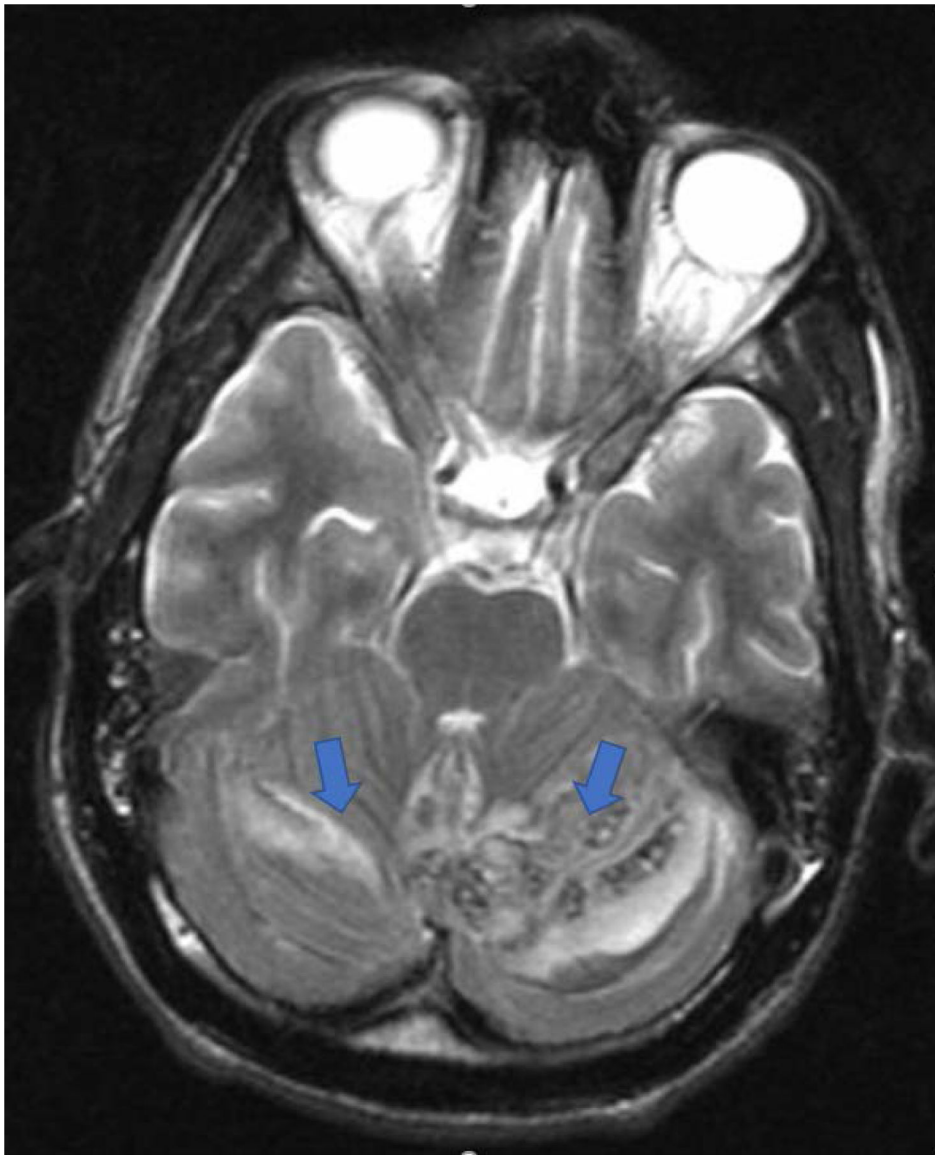


Figure 2.
MRI brain demonstrating subarachnoid hemorrhage in the cerebellar hemispheres bilaterally with moderate surrounding edema

Table 1.

Neurological examination at the time of presentation

Cranial nerves II-XII		Grossly intact
Muscle Strength:		
	Right	Left
Deltoid	3/5	3/5
Biceps	3/5	3/5
Triceps	3/5	3/5
Grip	3/5	3/5
Hand intrinsic muscle	3/5	3/5
Psoas	4/5	4/5
Quadriceps	4/5	4/5
Hamstring	4/5	4/5
Dorsiflexion	4/5	4/5
Plantar flexion	4/5	4/5
Extensor hallicis longus	4/5	4/5
Sensory	Normal in the C4-T1 distributions bilaterally, and the L2/S1 distributions bilaterally	

Author Manuscript

Author Manuscript

Author Manuscript

Author Manuscript