




Contents lists available at ScienceDirect

# Journal of Clinical Tuberculosis and Other Mycobacterial Diseases

journal homepage: [www.elsevier.com/locate/jctube](http://www.elsevier.com/locate/jctube)

## Case Report

# Disseminated *Mycobacterium peregrinum* and *Mycobacterium avium* infection in a patient with AIDS: A case report and review of literature

Chong Kei Lao<sup>a</sup>, Ting-Shu Wu<sup>a,b</sup>, Kuan-Yin Lin<sup>c</sup>, Ming-Hsun Lee<sup>a,\*</sup><sup>a</sup> Division of Infectious Diseases, Department of Internal Medicine, Chang Gung Memorial Hospital Linkou Branch, Chang Gung University College of Medicine, 5 Fuxing St., Guishan Dist., Taoyuan 33305, Taiwan<sup>b</sup> School of Medicine, Chang Gung University, 259, Wenhua 1st Rd, Guishan Dist., Taoyuan 33302, Taiwan<sup>c</sup> Division of Infectious Diseases, Department of Internal Medicine, National Taiwan University Hospital, No. 7, Chung-Shan South Rd. (Zhongshan S. Rd.), Zhongzheng Dist., Taipei City 100, Taiwan

## ARTICLE INFO

### Keywords:

Case report  
Disseminated infection  
*Mycobacterium peregrinum*  
Nontuberculous mycobacteria  
AIDS

## ABSTRACT

Disseminated nontuberculous mycobacterial infections are frequently recognized in patients living with human immunodeficiency virus/acquired immunodeficiency syndrome (AIDS) and *Mycobacterium avium-intracellulare* complex (MAIC) is the most common species. *Mycobacterium peregrinum* is a rapidly growing mycobacterium that accounts for 1–2% of community-acquired and healthcare-associated infections. It mainly causes skin and soft tissue infection. Disseminated infection by *M. peregrinum* has never been reported in patients with AIDS. We describe a case of disseminated co-infection of *M. peregrinum* and *M. avium* in a 33-year-old male with newly diagnosed AIDS, and review the literature regarding *M. peregrinum* infection. The patient's bone marrow culture grew *M. peregrinum* and his blood culture grew *M. avium*. The diagnosis of disseminated co-infection of *M. peregrinum* and *M. avium* was confirmed. Disseminated infection due to *M. peregrinum* is rare and diagnosis can be challenging. Due to limited case numbers, there is no treatment guideline for *M. peregrinum* nowadays. Further study is warranted for better understanding *M. peregrinum* related infections.

## 1. Background

Nontuberculous mycobacteria (NTM) are universal in the environment, including soil, animals, household water, aquatic systems, and healthcare water systems [1]. NTM comprise more than 150 species and are further divided into slowly growing mycobacteria (SGM) and rapidly growing mycobacteria (RGM) [1,2]. Around 50 species are considered human pathogens. Among people living with human immunodeficiency virus (HIV)/acquired immunodeficiency syndrome (AIDS) (PLWHA), disseminated NTM infections are more frequently recognized and *Mycobacterium avium-intracellulare* complex (MAIC) is the most common species [3]. *M. peregrinum* is a RGM and belongs to the *M. fortuitum* complex. Skin and soft tissue infection, pneumonia, bacteremia (catheter-related and primary infection), implantable cardioverter device infection, and tonsillar abscess by *M. peregrinum* have been reported, in which skin and soft tissue infection is the most common form of infection [3–11]. Disseminated infection by *M. peregrinum* is rare as *M. fortuitum* complex rarely causes disseminated infections compared to other pathogenic RGM, especially *M. chelonae* and *M. abscessus* [1]. Here

we report a case of disseminated co-infection of *M. peregrinum* and *M. avium* in a patient with AIDS. To our best knowledge, this is the first HIV-infected patient reported to have disseminated *M. peregrinum* infection, provoking us to review literature of this bacterium.

## 2. Case presentation

A 33-year-old male visited our Hematology Clinic in April 2021 due to anemia for one year after receiving colon polypectomy a year ago. He also had chronic watery diarrhea after flu-like symptoms 2 months ago. Physical examinations only revealed pale conjunctivae. His hemogram showed pancytopenia with a white blood cell count of  $1.7 \times 10^9/L$ , a hemoglobin level of 3.9 g/dL (reticulocyte index: 0.12), and a platelet count of 134,000/ $\mu L$ . Folate, vitamin B12, and lactate dehydrogenase levels were within normal range. Protein electrophoresis disclosed a chronic inflammation pattern with decrease of albumin and polyclonal increase of gamma globulin (albumin 1.7 g/dL, total protein 5.7 g/dL). Ferritin level was 3,212 ng/mL. The patient was transferred to our Emergency Department on April 26, 2021. Fever with a body

\* Corresponding author.

E-mail address: [drharrylee@gmail.com](mailto:drharrylee@gmail.com) (M.-H. Lee).

<https://doi.org/10.1016/j.jctube.2022.100314>

Available online 12 April 2022

2405-5794/© 2022 The Authors. Published by Elsevier Ltd. This is an open access article under the CC BY-NC-ND license (<http://creativecommons.org/licenses/by-nc-nd/4.0/>).

temperature 39 °C was noted at triage. His C-reactive protein (CRP) level was 45.75 mg/L. Two sets of blood cultures yielded serogroup D *Salmonella enterica*. Stool analysis showed positive fecal occult blood test. Abdominal ultrasonography found hepatosplenomegaly. Bone marrow biopsy disclosed normal cellularity and iron stores, without granuloma or malignant cells. His HIV antigen/antibody combination test was positive, with an absolute CD4 T cell count of 16 cells/ $\mu$ L and a HIV RNA viral load of 338,610 copies/mL. Biktarvy™ (bictegravir, emtricitabine and tenofovir alafenamide) was started on April 29. Pancytopenia gradually improved after treatment. The other virology survey revealed 358 copies and 755 copies of CMV DNA/ml and EBV DNA/mL, respectively. Ganciclovir was prescribed and CMV DNA was not detectable after a 2-week course of treatment. For chronic diarrhea, colonofiberscopy showed an ulcerative mass involving ileocecal valve, cecum, and terminal ileum. Biopsy disclosed ulcer only. Repeated colonofiberscopy with biopsy found acute colitis without granuloma, malignancy, crypt abscess, viral inclusion body or parasite. For salmonellosis with elevated alkaline phosphatase (604 U/L), whole-body <sup>18</sup>fluorodeoxyglucose positron-emission tomography/computed tomography (<sup>18</sup>FDG PET/CT) was arranged for metastatic infection evaluation, which incidentally found prominent left mesenteric lymph nodes and lesions over left adrenal gland, stomach, and ascending colon. Esophagogastroduodenoscopy for the stomach lesion revealed superficial gastritis only. As lymphoma was highly suspected and fever persisted without definite infectious focus since May 19, bone marrow aspiration and biopsy were arranged again on June 02 and showed no evidence of malignancy or lymphoma cells. Bone marrow culture was also sent this time. Abdominal CT was arranged for lymphoma survey and showed multiple enlarged lymph nodes at mesentery, para-aortic and porta hepatis areas, an ill-defined, infiltrated and hypodense lesion (about 3 cm) at segment 5 of liver, diffuse wall thickening of jejunum and focal wall thickening of ileum. Echo-guided biopsy of liver tumor showed fatty liver with scattered tiny granulomas and many acid fast bacilli with Ziehl-Neelsen stain. One set of sputum mycobacterial culture yielded *M. avium*. Rifabutin (300 mg per day), ethambutol (1200 mg per day) and clarithromycin (500 mg twice a day) were started for suspected disseminated MAIC infection. Biktarvy™ was shifted to Triumeq™ (dolutegravir, abacavir and lamivudine) to avoid drug-drug interaction with rifabutin. Bone marrow in Myco/F Lytic culture medium disclosed growth of mycobacteria after 6 days of incubation and the mycobacterium was identified to be *M. peregrinum* by matrix-assisted laser desorption ionization time-of-flight mass spectrometry (MALDI-TOF MS) Biotyper system (Bruker Daltonics), with scores ranging from 2.17 to 2.41. Rifabutin was discontinued and levofloxacin (750 mg administered intravenously once a day) was added. Dexamethasone was prescribed for suspected immune reconstitution inflammatory syndrome (IRIS). Fever subsided and CRP level was normalized 3 weeks after addition of levofloxacin. The patient was discharged with clarithromycin, ethambutol and levofloxacin. However, after one and a half months, progressive leukopenia (white blood cell count:  $3.2 \times 10^9$ /L), anemia (hemoglobin: 6.5 g/dL) and elevated CRP level (89.9 mg/L) were noted at our outpatient clinic follow-up. Fever was noted upon admission. As treatment failure was a concern, we tried to regrow the previous *M. peregrinum* isolate from the stock culture and get the antimicrobial susceptibility profile, but the isolate failed to regrow. According to the previous antimicrobial susceptibility profiles of *M. peregrinum* in our hospital, trimethoprim-sulfamethoxazole, ciprofloxacin, moxifloxacin, amikacin, tigecycline, clarithromycin, linezolid and imipenem showed good *in vitro* activities against this bacterium. Thus, for a better disseminated *M. peregrinum* infection control, amikacin (500 mg twice a day), ciprofloxacin (500 mg administered orally twice a day) and clarithromycin (500 mg twice a day) were prescribed. However, his fever persisted and then dexamethasone was given for suspected IRIS. He responded well to amikacin-containing antibiotic regimen and steroid, with a normal CRP level 10 days later. He was discharged with clarithromycin, ciprofloxacin and linezolid (600 mg twice a day). Six weeks after his discharge, the

hospital Central Laboratory informed about *M. avium* growth from his blood culture obtained eight weeks ago. We intended to inform the patient about his condition and suggest admission, but the patient had been hospitalized at another medical center to manage his abdominal pain. Colonofiberscopy there showed an obstructive lesion at hepatic flexure. Lymphadenopathy over left neck and inguinal region was also observed. Pathology report of these lesions led to a diagnosis of Kaposi's sarcoma with visceral involvement. His serum HHV-8 DNA level was 595,000 copies/mL. He received chemotherapy with doxorubicin hydrochloride liposome and was still hospitalized at the time of writing. The timeline of the case is presented in Fig. 1.

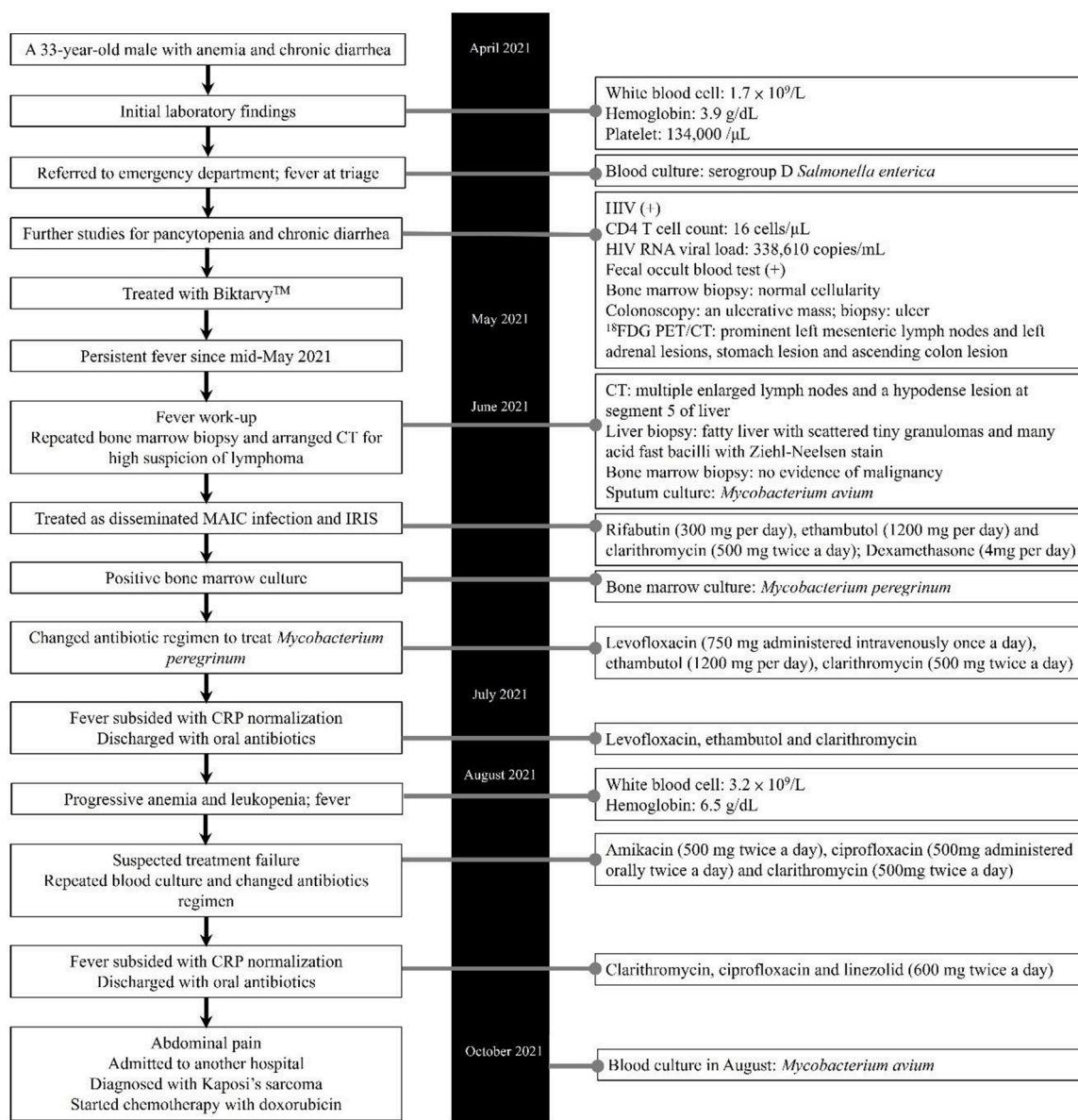
We tested the antimicrobial susceptibility profiles for the *M. avium* isolates. The minimum inhibitory concentration (MIC) ranges and interpretation were shown in Table 1. Both *M. avium* isolates were resistant to levofloxacin, ciprofloxacin, ethambutol and linezolid (the antimicrobial agents prescribed to treat *M. peregrinum* for this patient). Only amikacin and clarithromycin were effective against both *M. peregrinum* and *M. avium* to treat mycobacterial infection for the patient.

### 3. Discussion

Although NTM are ubiquitous in the environment, only some of them are pathogenic in humans and are mostly SGM (about 82% of cases) [2]. These NTM can cause opportunistic infections in both immunocompromised and immunocompetent patients, with various clinical manifestations. There are four main clinical syndromes: pulmonary infection, skin and soft tissue infection, lymphadenitis, and disseminated infection. Though there is no clear-cut definition for disseminated NTM infection, a consensus seems to be reached among most literatures that disseminated NTM infection is defined as isolation of NTM from blood or bone marrow [12–14]. Some literature also included isolation of NTM from liver biopsy or from  $\geq 2$  noncontiguous organs as disseminated infection [13–15]. Disseminated NTM infections are mainly found in patients with immunodeficiency, such as AIDS and leukemia/lymphoma, and in those with genetic defects or mutations (for examples, Mendelian susceptibility to mycobacterial disease, nuclear factor  $\kappa$ B essential modulator mutation, signal transducer and activator of transcription 1 deficiency) or presence of anti-interferon- $\gamma$  autoantibodies or anti-granulocyte-macrophage colony-stimulating factor antibodies [14,15]. In PLWHA, 70% to 94.6% of disseminated NTM infections were caused by MAIC [12,13,15].

To the best of our knowledge, this is the first description of a disseminated *M. peregrinum* infection in a patient with AIDS. *M. peregrinum*, a RGM and member of *M. fortuitum* complex, accounts for 1 to 2% of RGM infections [1]. A total nineteen publications were reviewed on the PUBMED and MEDLINE databases and there were 21 cases (including our case) reporting *M. peregrinum* infection. The demographic characteristics, infection sites, antimicrobial susceptibilities and outcomes were summarized in Table 2. Skin and soft tissue was the most commonly infected site ( $n = 11$ , 52.4%) and 54.5% of the cases (6/11) were related to surgical site or artificial-device related infections, similar clinical behavior as other members in the *M. fortuitum* complex [1]. Catheter-related bloodstream infection, pneumonia, lymphadenitis, tonsillar abscess, and infective endocarditis by *M. peregrinum* have also been reported [2,3,5–7,10,16–18]. Nine cases (42.9%) were recorded to be immunocompromised. But *M. peregrinum* could also cause sporadic invasive infections in immunocompetent patients. Pneumonia caused by *M. peregrinum* have been reported in two patients (2/4, 50%) who were previously healthy [7,18]. With increasing numbers of NTM infections in the last four decades and improvement in methods of identifying different NTM species, a rise in *M. peregrinum* infection is anticipated and physicians should be aware of the clinical significance of *M. peregrinum*.

As previously mentioned, the majority of disseminated NTM infections in PLWHA is caused by MAIC. These patients with disseminated



$^{18}F$ FDG PET/CT:  $^{18}$ fluorodeoxyglucose positron-emission tomography/computed tomography. CRP: C-reactive protein. HIV: Human immunodeficiency virus. IRIS: immune reconstitution inflammatory syndrome. MAIC: *Mycobacterium avium-intracellulare* complex..

Fig. 1. Timeline of the case.

**Table 1**  
Antibiotic susceptibility and interpretation of the *Mycobacterium avium* isolates.

Antibiotics	MIC range ( $\mu g/mL$ )	Interpretation
Clarithromycin	2	S
Rifabutin	0.5	S
Ethambutol	8	R
Isoniazid	4	-
Moxifloxacin	2	S
Rifampin	16	R
Trimethoprim-sulfamethoxazole	4/76	R
Amikacin	16	S
Linezolid	32	R
Ciprofloxacin	16–32	R
Streptomycin	32	-
Doxycycline	32	-
Ethionamide	2.5	-

MIC: minimum inhibitory concentration. S: susceptible. I: intermediate. R: resistant

MAIC infections are usually presented as prolonged fever without obvious origin, weight loss, fatigue, abdominal pain, chronic diarrhea and hepatosplenomegaly [19]. Other opportunistic infections or common malignancies in AIDS patients share similar clinical manifestations. Our patient also presented with resembling symptoms, leading to an initial tentative diagnosis of disseminated MAIC infection. It is unlikely to differentiate between these two NTM infections by clinical symptoms. Empiric treatment will be initiated for MAIC after excluding tuberculosis if there is evidence of mycobacterial growth from specimens. Drugs effective against MAIC include macrolides, ethambutol, rifabutin, fluoroquinolones and amikacin [19]. For *M. peregrinum*, amikacin, ciprofloxacin, clarithromycin, imipenem and linezolid showed good *in vitro* activities (Table 2). Although we cannot differentiate between disseminated MAIC and *M. peregrinum* infections before species identification, both can be inhibited by macrolides, fluoroquinolones and amikacin. But accurate identification of the isolate is still crucial for definite diagnosis and appropriate treatment regimen. The treatment duration for disseminated MAIC infection is at least 12 months [19]. Due to small

**Table 2**  
Previous reports of *Mycobacterium peregrinum* infections.

Author	Year	Country	Age	Gender	Immunocompromised status	Foreign body/procedure	Type of infection (specimen)	Susceptible	Resistant	Antibiotics	Duration of treatment	Intervention	Mortality
Ishii [20]	1998	Japan	45	M	–	–	Skin and soft tissue (skin tissue)	NA	NA	SPFX, MIN	7 weeks	–	Survived
Pagnoux [21]	1998	France	30	F	DM	Continuous subcutaneous insulin infusion	Skin and soft tissue (abscess)	AN, CIP, IMP, CLR	NA	CIP, IMP, AN	3 months	surgical drainage	Survived
Rodríguez-Gancedo [5]	2001	Spain	38	M	Myelomonocytic leukemia	Hickman catheter	Bacteremia (blood)	AN, VA, CIP	ERM, TCN, GM, TOB, IMP, MEM, CAZ, CXM, CTX, CEF, PCN, OX, AMC, SXT, CHL, CC, RIF	VA	NA	catheter removal	Survived
Koscielniak [10]	2003	Germany	1.2	M	Interferon-gamma receptor-1 deficiency	–	Lymphadenitis (lymph node)	IMP, CPM	NA	IMP, CPM	1 year	bone marrow transplantation	Survived
Marie [6]	2005	France	68	M	Polymyositis treated with infliximab	–	Pneumonia (sputum, gastric aspiration products and BAL)	NA	NA	RIF, INH, EMB, PZA	NA	–	Dead
Sakai [3]	2005	Japan	30	F	AIDS (CD4 count: 8 cells/ $\mu$ l)	–	Tonsillar abscess (abscess)	AN, CIP, IMP, CLR	PCN, AM, ERM, VA, CZ, anti-tuberculous drugs	IMP, CLR	6 weeks	drainage	Survived
Short [22]	2005	USA	74	M	–	Automatic implantable cardioverter defibrillator	Skin and soft tissue, bacteremia (wound, blood)	AN, CIP, IMP, CLR, DOX, GAT, LZD, MEM, TOB	NA	–	–	ICD removal	Survived
Rivera-Olivero <sup>a</sup> [23]	2006	Venezuela	NA	NA	NA	Mesotherapy	Skin and soft tissue (biopsy/aspirates)	NA	NA	AN, CIP	4–5 months	NA	Survived
Tsolia [16]	2006	Greece	2	M	Interferon-gamma receptor-1 deficiency	–	Lymphadenitis (lymph node, gastric aspirate)	AN, CLR, CIP	RIF	AN, CLR, CIP	at least 1 year	–	No improvement
Appelgren [24]	2008	Sweden	40	M	NA	–	Skin and soft tissue (wound)	NA	NA	AN, CLR, CIP	3 months	–	Survived
Nagao [4]	2009	Japan	58	F	NA	Artificial sheets for chest wall reconstruction	Skin and soft tissue (pus)	AN, IMP, LVX	CLR, DOX	AN, IMP, LVX	5 weeks	Artificial sheet removal	Survived
Swahata [7]	2010	Japan	24	M	–	–	Pneumonia (sputum)	AN, CLR, LVX, EMB	INH	CLR, LVX, EMB	NA	–	Survived
Torres-Duque [17]	2010	Colombia	17	F	–	Mechanical aortic valve	Infective endocarditis (blood, sputum)	NA	NA	AN, IMP, CLR, SXT, RIF, DOX	12 months	Biological aortic valve replacement	Survived
Kamijo [25]	2012	Japan	83	M	–	–	Skin and soft tissue (skin tissue)	NA	NA	MIN	28 weeks	–	Survived
Todorova [18]	2015	Bulgaria	72	M	–	–	Pneumonia (sputum)	NA	INH	RIF, INH, EMB, PZA	NA	–	Survived
Wachholz [8]	2016	Brazil	53	F	Psoriasis (not using immunosuppressive therapy)	–	Skin and soft tissue (skin tissue)	NA	NA	DOX	30 days	–	Survived
Lazo-Vasquez [11]	2020	USA	59	F	–	Dual-chamber permanent pacemaker	Skin and soft tissue (wound)	AN, AZI, FOX, CIP, CLR, GM, IMP, LZD, MIN, MXF, TGC, SXT	AMC, FEP, CTX, CRO, DOX, TOB	AN, IMP, LZD, MXF, SXT	4 months	Pacemaker removal	Survived

(continued on next page)



Table 2 (continued)

Author	Year	Country	Age	Gender	Immunocompromised status	Foreign body/procedure	Type of infection (specimen)	Susceptible	Resistant	Antibiotics	Duration of treatment	Intervention	Mortality
Pérez-Alfonzo [9]	2020	Venezuela	13	F	-	Dental procedure	Skin and soft tissue and lymphadenitis (skin tissue and lymph node)	NA	NA	AN, CIP	19 weeks	Debridement and surgical removal of lymph node	Survived
Rolan [2]	2020	Argentina	40	F	Autoimmune uveitis under mycophenolate	-	Pneumonia (sputum)	AN, CIP, CLR, LZD	NA	CIP, CLR	6 months	-	Survived
Present study	2021	Taiwan	33	M	AIDS	-	Bone marrow (bone marrow)	NA	NA	LVX, CLR, EMB	Still under treatment	-	Survived

AIDS, acquired immunodeficiency syndrome; AM, ampicillin; AMC, amoxicillin-clavulanic acid; AZI, azithromycin; CC, clindamycin; CEF, cephalotin; CHL, chloramphenicol; CLR, clarithromycin; CPM capreomycin; CRO, ceftriaxone; CTX, cefotaxime; CXM, cefuroxime; Cz, cefazolin; DM, diabetes mellitus; DOX, doxycycline; EMB, ethambutol; ERM, erythromycin; FEP, cefepime; FOX, ceftioxin; GAT, gatifloxacin; GM, gentamicin; IMP, imipenem; INH, isoniazid; LZD, linezolid; MEM, meropenem; MIN, minocycline; MXF, moxifloxacin; NA, not available; OX, oxacillin; RF, rifampin; SPFX, sparflaxacin; SXT, trimethoprim-sulfamethoxazole; TCN tetracycline; TGC, tigecycline; VA, vancomycin

a This is a retrospective study in which *Mycobacterium peregrinum* were identified in 2 patients.

numbers of disseminated *M. peregrinum* infection, there is no recommendation for treatment duration. In Table 2, the duration of treatment for *M. peregrinum* infection varied between different sites. For disseminated infection, it was at least 12 months. The IDSA guidelines suggest lifelong treatment for disseminated MAIC infection in patients with AIDS unless they restore their immunity. The treatment duration of disseminated *M. peregrinum* infection should be individualized according to the patient's immune status. Fortunately, the prognosis of *M. peregrinum* infection seems to be good with mortality documented in only one patient [6].

#### 4. Conclusion

We presented a disseminated *M. peregrinum* infection in a patient with AIDS. Disseminated infection due to this bacterium is rare and patients affected are usually immunocompromised. Due to limited cases, there is no treatment guideline for *M. peregrinum* nowadays. Most physicians chose macrolides, fluoroquinolones, imipenem or amikacin as combination therapy for *M. peregrinum* infection. Larger numbers of isolates and cases are warranted to provide more information about the clinical features, antimicrobial susceptibility pattern and prognosis of this species.

#### 5. Ethics statement

This study was approved by the Institution Review Board (IRB) of Chang Gung Medical Foundation (IRB No.: 202101410A3). Written informed consent was obtained from the patient for publication of this case report and accompanying images. A copy of the written consent is available for review by the Editor-in-Chief of this journal on request.

#### Funding

The authors received no financial support for the research, authorship, and/or publication of this article.

#### Declaration of Competing Interest

The authors declare that they have no known competing financial interests or personal relationships that could have appeared to influence the work reported in this paper.

#### Acknowledgments

We thank the Bank of Bacteria, Linkou Chang Gung Memorial Hospital for providing bacterial isolates.

#### References

- [1] Brown-Elliott BA, Wallace Jr RJ. Clinical and taxonomic status of pathogenic nonpigmented or late-pigmenting rapidly growing mycobacteria. Clin Microbiol Rev 2002;15(4):716–46.
- [2] Rolan N, Limongi L, Putruele AM. Mycobacterium peregrinum: an atypical and uncommon mycobacterium. A case report. Arch Bronconeumol (Engl Ed) 2020;56(5):331–2.
- [3] Sakai T, Kobayashi C, Shinohara M. Mycobacterium peregrinum infection in a patient with AIDS. Intern Med 2005;44(3):266–9.
- [4] Nagao M, Sonobe M, Bando T, Saito T, Shirano M, Matsushima A, et al. Surgical site infection due to Mycobacterium peregrinum: a case report and literature review. Int J Infect Dis 2009;13(2):209–11.
- [5] Rodríguez-Gancedo MB, Rodríguez-González T, Yagüe G, Valero-Guillén PL, Segovia-Hernández M. Mycobacterium peregrinum bacteremia in an immunocompromised patient with a Hickman catheter. Eur J Clin Microbiol Infect Dis 2001;20(8):589–90.
- [6] Marie I, Heliot P, Roussel F, Hervé F, Muir JF, Levesque H. Fatal Mycobacterium peregrinum pneumonia in refractory polymyositis treated with infliximab. Rheumatology (Oxford) 2005;44(9):1201–2.
- [7] Sawahata M, Hagiwara E, Ogura T, Komatsu S, Sekine A, Tsuchiya N, et al. Pulmonary mycobacteriosis caused by Mycobacterium peregrinum in a young, healthy man. Nihon Kokyuki Gakkai Zasshi 2010;48(11):866–70.

- [8] Wachholz PA, Sette CS, Caitano do Nascimento D, Soares CT, Diório SM, Masuda PY. *Mycobacterium peregrinum* skin infection: case report. *J Cutan Med Surg* 2016;20(3):249–51.
- [9] Pérez-Alfonzo R, Poleo Brito LE, Vergara MS, Ruiz Damasco A, Meneses Rodríguez PL, Kannee Quintero CE, et al. Odontogenic cutaneous sinus tracts due to infection with nontuberculous mycobacteria: a report of three cases. *BMC Infect Dis* 2020;20(1).
- [10] Koscielniak E, de Boer T, Dupuis S, Naumann L, Casanova JL, Ottenhoff TH. Disseminated *Mycobacterium peregrinum* infection in a child with complete interferon-gamma receptor-1 deficiency. *Pediatr Infect Dis J* 2003;22(4):378–80.
- [11] Lazo-Vasquez AF, Gonzales-Zamora JA. *Mycobacterium peregrinum* pacemaker pocket infection: a case report and review of the literature. *Case Rep Infect Dis* 2020;2020. 8831026.
- [12] Varley CD, Ku JH, Henkle E, Schafer SD, Winthrop KL. Disseminated nontuberculous mycobacteria in HIV-infected patients, Oregon, USA, 2007–2012. *Emerg Infect Dis* 2017;23(3):533–5.
- [13] Wetzstein N, Geil A, Kann G, Lehn A, Schüttfort G, Kessel J, et al. Disseminated disease due to non-tuberculous mycobacteria in HIV positive patients: a retrospective case control study. *PLoS ONE* 2021;16(7):e0254607.
- [14] Lai CC, Lee LN, Ding LW, Yu CJ, Hsueh PR, Yang PC. Emergence of disseminated infections due to nontuberculous mycobacteria in non-HIV-infected patients, including immunocompetent and immunocompromised patients in a university hospital in Taiwan. *J Infect* 2006;53(2):77–84.
- [15] Chou CH, Chen HY, Chen CY, Huang CT, Lai CC, Hsueh PR. Clinical features and outcomes of disseminated infections caused by non-tuberculous mycobacteria in a university hospital in Taiwan, 2004–2008. *Scand J Infect Dis* 2011;43(1):8–14.
- [16] Tsolia MN, Chappier A, Taprantzi P, Servitzoglou M, Tassios I, Spyridis N, et al. Disseminated nontuberculous mycobacterial infection in a child with interferon-gamma receptor 1 deficiency. *Eur J Pediatr* 2006;165(7):458–61.
- [17] Torres-Duque CA, Díaz C, Vargas L, Serpa EM, Mosquera W, Garzón MC, et al. Disseminated mycobacteriosis affecting a prosthetic aortic valve: first case of *Mycobacterium peregrinum* type III reported in Colombia. *Biomedica* 2010;30(3):332–7.
- [18] Todorova TT, Kaludova V, Tsankova G, Ermenlieva N. A pulmonary infection caused by *Mycobacterium peregrinum* - a case report. *J IMAB* 2015;21(4):1000–2.
- [19] Corti M, Palmero D. *Mycobacterium avium* complex infection in HIV/AIDS patients. *Expert Rev Anti Infect Ther* 2008;6(3):351–63.
- [20] Ishii N, Sugita Y, Sato I, Nakajima H. A case of mycobacterial skin disease caused by *Mycobacterium peregrinum* and *M. scrofulaceum*. *Acta Derm Venereol* 1998;78(1):76–7.
- [21] Pagnoux C, Nassif X, Boitard C, Timsit J. Infection of continuous subcutaneous insulin infusion site with *Mycobacterium peregrinum*. *Diabetes Care* 1998;21(1):191–2.
- [22] Short WR, Emery C, Bhandary M, O'Donnell JA. Misidentification of *Mycobacterium peregrinum*, the causal organism of a case of bacteremia and automatic implantable cardioverter defibrillator-associated infection, due to its unusual acid-fast staining characteristics. *J Clin Microbiol* 2005;43(4):2015–7.
- [23] Rivera-Olivero IA, Guevara A, Escalona A, Oliver M, Pérez-Alfonzo R, Piquero J, et al. Soft-tissue infections due to non-tuberculous mycobacteria following mesotherapy. What is the price of beauty. *Enferm Infecc Microbiol Clin* 2006;24(5):302–6.
- [24] Appelgren P, Farnebo F, Dotevall L, Studahl M, Jönsson B, Petrini B. Late-onset posttraumatic skin and soft-tissue infections caused by rapid-growing mycobacteria in tsunami survivors. *Clin Infect Dis* 2008;47(2):e11–6.
- [25] Kamijo F, Uhara H, Kubo H, Nakanaga K, Hoshino Y, Ishii N, et al. A case of mycobacterial skin disease caused by *Mycobacterium peregrinum*, and a review of cutaneous infection. *Case Rep Dermatol* 2012;4(1):76–9.