

Primary cutaneous anaplastic large cell lymphoma arising from a long-standing erythema nodosum

A case report

Liang-Liang Ma, PhD^a, Shi-Xin Han, PhD^b, Mei-Yun Fang, PhD^{a,c,*}

Abstract

Rationale: Primary cutaneous anaplastic large cell lymphoma (pcALCL) is a rare subtype of non-Hodgkin lymphoma, which is rarely associated with erythema nodosum (EN).

Patient concerns: A 57-year-old woman complained of recurrent rashes involving her abdomen, back, upper and lower limbs for over 20 years, with severity in symptoms for 2 weeks.

Diagnoses: The first skin biopsy was performed in 2011 in another hospital and she was diagnosed idiopathic EN. The second skin biopsy was performed in 2014 and she was diagnosed as pcALCL with stage IA.

Interventions: She was treated with oral prednisone, cyclosporine, and thalidomide.

Outcomes: One month later, the ulcerative lesion was decreased in size and became smooth and the patient achieved partial remission. She is still under treatment and has been monitored closely for 4 years.

Lessons: The case suggested that stimulation of inflammation in the skin lesions for a long period might be related to clonal transformation into pcALCL and hence should be closely monitored. Immunosuppressive treatment may be effective and safe for patients with pcALCL at early stages.

Abbreviations: AD = atopic dermatitis, EN = erythema nodosum, pcALCL = primary cutaneous anaplastic large cell lymphoma.

Keywords: erythema nodosum, primary cutaneous anaplastic large cell lymphoma, 20-year history

1. Introduction

Primary cutaneous anaplastic large cell lymphoma (pcALCL) is a subtype of cutaneous T-cell lymphoma histologically characterized by large, highly atypical CD30+ T-cells.^[1] The incidence of pcALCL among other types of peripheral T-cell NHL is 1.7%. Erythema nodosum (EN) is a panniculitis consisting of an infiltrate of lymphocytes and multinucleate giant cells within subcutaneous fat.^[2] Previously, fewer than 10 cases have been reported about pcALCL arising from atopic dermatitis (AD) and burn scar.^[3–6] To our knowledge, there was no report of pcALCL arising from a long-standing EN.

Editor: N/A.

This case report was approved by the ethics committee of the First Affiliated Hospital of Dalian Medical University, Dalian, Liaoning, China.

The authors declare no conflicts of interest.

^a Department of Hematology, ^b Department of Dermatology, The First Affiliated Hospital of Dalian Medical University, Dalian, China, ^c Department of Hematology, Affiliated Zhongshan Hospital of Dalian University.

* Correspondence: Mei-Yun Fang, Department of Hematology, The First Affiliated Hospital of Dalian Medical University, 222 Zhongshan Road, Dalian, Liaoning Province, China (e-mail: fangmeiyun@aliyun.com).

Copyright © 2018 the Author(s). Published by Wolters Kluwer Health, Inc. This is an open access article distributed under the terms of the Creative Commons Attribution-Non Commercial License 4.0 (CCBY-NC), where it is permissible to download, share, remix, transform, and buildup the work provided it is properly cited. The work cannot be used commercially without permission from the journal.

Medicine (2018) 97:49(e13211)

Received: 24 May 2018 / Accepted: 15 October 2018

<http://dx.doi.org/10.1097/MD.0000000000013211>

Here we report the rare case of pcALCL occurring in a patient with over 20-year history of EN and achieved good clinical response with oral prednisone, cyclosporine, and thalidomide.

2. Case report

This study was approved by the ethics committee of the First Affiliated Hospital of Dalian Medical University, Dalian, China. Informed consent was obtained from the patient for publication of this report.

A 57-year-old woman was admitted to our hospital in May 2014 with complaints of a disseminated rash involving her abdomen, back, upper, and lower limbs which could regress without therapy spontaneously for over 20 years. The first skin biopsy was performed in another hospital in December 2011. Histopathological examination demonstrated that a dense lymphocytic infiltrate around deep plexus capillaries (Fig. 1A and 1B). The patient did not have any other symptoms, and no secondary diseases, such as rheumatologic diseases, tuberculosis, and tumor. She was diagnosed idiopathic EN and was given oral tripterygium glycosides daily for half a year, without improvement. With a gradually enlarged ulcerative lesion (7 cm × 5 cm) in the right of lower limb in May 2014, the lesion biopsy was performed again in our hospital. It showed diffuse proliferation and invasion of large-sized lymphoid cells with pleomorphic nuclei containing conspicuous nucleoli and relatively rich cytoplasm (Fig. 1C and 1D). Immunohistochemical panel showed that these lymphoid cells expressed CD30, CD3, CD4, Ki67, and were negative for CD8, CD20, ALK, EBER, CD56 and granzyme B. Complete blood count, metabolic panels, antinuclear antibodies, positron emission

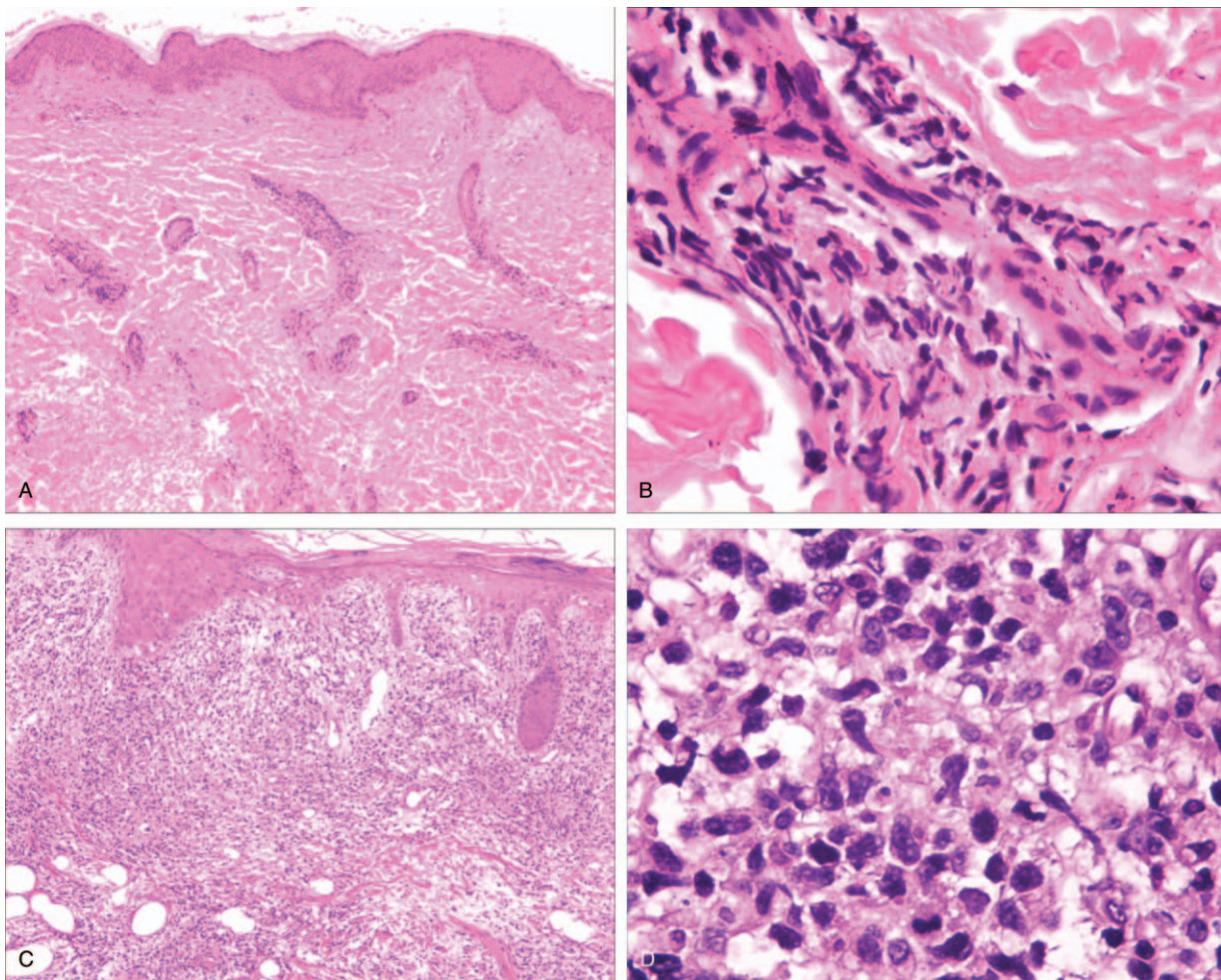


Figure 1. Pathological features of patient's rash. (A and B) Histopathological examination of the first skin biopsy obtained from one of the rashes showing a dense lymphocytic infiltrate around deep plexus capillaries (Hematoxylin & eosin, original magnification of A x 40, and B x 400). (C and D) Histopathological examination of the second skin biopsy obtained from one of the rashes showing diffuse proliferation of atypical lymphocytes in the dermis accompanying epidermal erosion (Hematoxylin & eosin, original magnification of C x 40, and D x 400).

tomography/computed tomography scan (PET/CT), and bone marrow biopsy were unremarkable. $\beta 2$ -microglobulin was 3.84 mg/L and LDH was 364U/L in serum which was both slightly higher than normal. All tests did not show evidence of systemic involvement. Accordingly, a diagnosis of pcALCL with stage IA ($T_1N_0M_0B_0$) was made, with <10% skin involvement. Considering her age, the size, and location of ulcerative lesion, she was treated with oral prednisone 30mg daily, cyclosporine 200mg daily and thalidomide 100mg daily. After 1 month treatment, the ulcerative lesion was decreased in the size (4cm x 3cm) and became smooth, achieved partial remission. She is still on treatment and is monitored closely for 4 years. She is generally in good condition. The erythemas nodules are smaller and without ulcers.

3. Discussion

There are a few reports regarding EN transforming into subcutaneous panniculitis lymphoma and Hodgkin lymphoma, however, EN transforming into pcALCL has not been reported.^[7] To date, fewer than 10 cases with pcALCL occurring in AD and burn scar have been reported.^[3-6] In this case, pcALCL developed at the site of EN after 20 years. It seems advisable to perform

careful and continuous follow-up of all cases with EN, with regular repetition of skin biopsies at appropriate intervals.

Biopsy of lesions from the patient expressed CD30 in the tumor cells, did not exhibit ALK. CD30 is a TNF receptor superfamily member, which is an activation antigen of lymphoid cells and express in a subset of lymphocytes with a Th2 phenotype. It has been reported that CD30 ligand is upregulated in cutaneous inflammation and mediates degranulation-independent chemokine secretion.^[8] Stimulation of inflammation in the skin lesions and dysfunction of immune system for a long time might be related to clonal transformation, further studies are needed to clarify the pathogenesis.

Because pcALCL is rare, prognostic variables have not been prospectively validated. Risk factors for worse prognosis may include involvement of the leg and more extensive disease based on a proposed tumor node metastasis staging system. Previous 5 cases arising from AD, 2 of them died earlier, 1 relapsed several times and only 1 was freed from disease after bone marrow transplantation.^[3-5] It revealed that AD history may be another poor factor for pcALCL prognosis, however, we were unable to obtain any conclusive evidence to show the prognosis of pcALCL with EN history now. As in the case, the patient achieved good

clinical response owing partly to the early stage and partly to the effective treatment. It has been demonstrated variety therapy, such as excision, external beam radiation, methotrexate, thalidomide, and chemotherapy are useful in treatment of pcALCL, but there is no standard treatment for this tumor.^[1,9,10] Considering the size and wide distribution of erythema nodules presented, it is not suitable for radiotherapy and surgery resection. Chemotherapy may be useful for the patient, but it is easy to recurrence. Our promising result suggests that combination of prednisone, cyclosporine and thalidomide may be a useful method in the treatment of pcALCL. It is also necessary to closely monitor the patient because of the potential risk of dissemination, besides recurrence of the disease or even development of other malignancies.

Recently, brentuximab vedotin was approved by FDA for relapsed or refractory Hodgkin's lymphoma and ALCL, with impressive response rates of 75% and 86%, respectively. Brentuximab vedotin is an antibody-drug conjugate that contains anti-CD30 Fab' domains linked to the antimetabolic agent monomethyl auristatin E.^[11] A 60-year-old man with a 6 cm pcALCL located on the right cheek, near the eye, received brentuximab vedotin therapy after failing 4 months of methotrexate. After 2 cycle's treatment, he had a complete response that was histologically confirmed.^[12] This demonstrates that brentuximab vedotin may be an effective option for pcALCL in the future.

Author contributions

LM was the physician in charge of this patient and collected the data. LM and MF did the literature review and wrote the article. SH finished the pathological test and revised the article. All authors read and approved the final article.

Conceptualization: Liang liang Ma, Shi xin Han, Mei yun Fang.

Data curation: Liang liang Ma, Shi xin Han, Mei yun Fang.

Formal analysis: Liang liang Ma, Shi xin Han, Mei yun Fang.

Investigation: Liang liang Ma.

Writing – original draft: Liang liang Ma.

Writing – review & editing: Shi xin Han, Mei yun Fang.

References

- [1] Chao-Lo MP, King-Ismael D, Lopez RA. Primary cutaneous CD30+ anaplastic large cell lymphoma: report of a rare case. *J Dermatol Case Rep* 2008;2:31–4.
- [2] Cheong KA, Rodgers NG, Kirkwood ID. Erythema nodosum associated with diffuse, large B-cell non-Hodgkin lymphoma detected by FDG PET. *Clin Nucl Med* 2003;28:652–4.
- [3] Kirby B, Owen CM, Blewitt RW, et al. Cutaneous T-cell lymphoma developing in a patient on cyclosporine therapy. *J Am Acad Dermatol* 2002;47:S165–7.
- [4] Fletcher CL, Orchard GE, Hubbard V, et al. CD30+ cutaneous lymphoma in association with atopic eczema. *Arch Dermatol* 2004;140:449–54.
- [5] Ishida M, Hodohara K, Yoshii M, et al. Primary cutaneous anaplastic large cell lymphoma occurring in an atopic dermatitis patient: a case report with review of the literature with emphasis on their association. *Int J Clin Exp Pathol* 2014;7:1735–41.
- [6] Morihara K, Takenaka H, Morihara T, et al. Primary cutaneous anaplastic large cell lymphoma associated with vascular endothelial growth factor arising from a burn scar. *J Am Acad Dermatol* 2007;57: S103–5.
- [7] Risulo M, Rubegni P, Sbrano P, et al. Subcutaneous panniculitis lymphoma: erythema nodosum-like. *Clin Lymphoma Myeloma* 2006; 7:239–41.
- [8] Fischer M, Harvima IT, Carvalho R, et al. Mast cell CD30 ligand is upregulated in cutaneous inflammation and mediates degranulation-independent chemokine secretion. *J Clin Invest* 2006;116:2748–56.
- [9] Oliveira LS, Nobrega MP, Monteiro MG, et al. Primary cutaneous anaplastic large-cell lymphoma-case report. *A Bras Dermatol* 2013;88:132–5.
- [10] Lee JH, Cheng AL, Lin CW, et al. Multifocal primary cutaneous CD30+ anaplastic large cell lymphoma responsive to thalidomide: the molecular mechanism and the clinical application. *Br J Dermatol* 2009; 160:887–9.
- [11] Mody K, Wallace JS, Stearns DM, et al. CD30-positive cutaneous T-cell lymphoma and response to Brentuximab Vedotin:2 illustrative cases. *Clin Lymphoma Myeloma Leuk* 2013;13:319–23.
- [12] Kaffenberger BH, Kartono Winardi F, Frederickson J, et al. Periocular cutaneous anaplastic large cell lymphoma clearance with brentuximab vedotin. *J Clin Aesthet Dermatol* 2013;6:29–31.