

Pneumocystosis as a Complication of H1N1 Influenza A Infection in an HIV-Positive Patient on Effective cART

Iacopo Franconi,^{1,✉} Caterina Monari,² Marco Tutone,¹ Giacomo Ciusa,¹ Luca Corradi,¹ Erica Franceschini,¹ Marianna Meschieri,¹ Cinzia Puzzolante,¹ William Gennari,³ Monica Pecorari,³ Giovanni Guaraldi,¹ and Cristina Mussini¹

¹Infectious Diseases Unit, University of Modena and Reggio Emilia, Modena, Italy; ²Infectious Diseases Unit, University of Naples Federico II, Napoli, Italy; ³Microbiology and Virology Unit, University of Modena and Reggio Emilia, Modena, Italy

H1N1 influenza A virus can affect the immune system, causing lymphopenia. This might be of great concern for HIV individuals undergoing effective antiretroviral therapy (cART). We report the first confirmed case of H1N1-induced AIDS and *Pneumocystis jiroveci* pneumonia in an HIV-positive woman on effective cART since 2006.

Keywords. AIDS; H1N1; HIV; PJP.

CASE REPORT

A 53-year-old HIV-positive woman was admitted to the emergency department of the Policlinico di Modena for a rapid onset of dyspnea, nonproductive cough, frontal and retro-orbital headache, fatigue, malaise, myalgia, and fever that started 3 days before and worsened within the last 24 hours.

On medical history, she had HIV infection, diagnosed in 1988 (Centers for Disease Control and Prevention = C3), and *Pneumocystis jiroveci* pneumonia (PJP), and she had been on combination antiretroviral therapy (cART) with abacavir 600 mg/lamivudine 300 mg and atazanavir 300 mg/ritonavir 100 mg since 2006. At her last HIV visit, 2 months before hospital admission, she had a CD4+ cell count of 876 cells/mm³, a CD4 of 35.6%, and undetectable HIV viral load (<40 copies/uL). She also reported former intravenous drug use (IDU) and current methadone therapy 50 mg/d, and she was an active heavy smoker (30 pack-years). Reverse transcription polymerase chain reaction (RT-PCR) on sputum and nasal swab at

admission were performed. They were both positive for influenza A H1N1, and oseltamivir therapy (75 mg bid) was started.

After an initial improvement, on day 3 after admission, she had an unexpected worsening of her clinical conditions. On physical examination, she had bilateral chest wheezing and pharyngeal hyperemia. Routine blood tests showed a white blood cell count of 4860/mm³, and arterial hemogas analysis showed acidosis (pH 7.30), hypoxia (pO₂ 40.3 mmHg), and hypercapnia (pCO₂ 52.7 mmHg), and her Lactate dehydrogenase (LDH) was 503 mg/dL. As mild hypercapnia was consistent with the heavy smoking history and prior PJP, the subsequent clinical workup focused mainly on hypoxia. She denied any cART interruption, but her CD4+ count had dropped to 133 cells/mm³. Her total lymphocyte count was 440 cells/mm³, with CD4 of 30.2%, CD8 of 27%, and CD4/CD8 of >1%. Chest computed tomography scan, performed on day 3 after admission, showed a pattern of multinodular and interstitial pneumonia (Figure 1). Suspecting PJP, intravenous therapy with trimetoprim/sulphamethoxazole (TMP/SMX 15 mg/kg/d of TMP) was empirically started. She then underwent bronchoalveolar lavage, and the PJP diagnosis was confirmed by a Beta-D-glucan elevation (>523 pg/mL) and positive immunofluorescence microscopy (IFA) and RT-PCR for *Pneumocystis jiroveci* in bronchoalveolar lavage fluid (BALF). On day 6 of her hospital stay, her HIV viral load was <40 copies/mL. TMP/SMX was continued for a total of 3 weeks, and at the end of treatment, her CD4+ cell count was 433 cell/mm³, her CD4 was 27.3%, and her HIV viral load remained undetectable.

PJP is not a common consequence of influenza A infection in HIV/AIDS subjects. Only 1 case has been described, a patient on effective cART with an HIV viral load of 56 copies/mL and 644 CD4+ cell/mm³, with a CD4/CD8 of 0.46 4 months before H1N1 infection and consequent PJP. The authors referred to this PJP diagnosis as possible due to suggestive clinical findings, elevated LDH, clinical response to related primary therapy, and a positive PCR in BALF, but negative traditional staining methods [1]. Our case describes an immunofluorescence-confirmed diagnosis of PJP as a complication of H1N1 influenza-induced lymphopenia.

H1N1 is able to infect and induce apoptosis in several cell types, such as dendritic cells, macrophages, monocytes, T cells, and NK cells [2, 3]. In vitro studies have reported that influenza A neuroaminidase may enhance HIV-1 replication, syncytium formation, and consequent T-cell CD4+ apoptosis and depletion [2]. It is intriguing to notice that despite lymphopenia is a clinical manifestation of H1N1 infection, although another case of suspected PJP as a complication of influenza A infection has been reported in an HIV-infected individual on effective cART.

Received 14 November 2018; editorial decision 22 February 2019; accepted 1 March 2019; Published online March 7, 2019.

Correspondence: I. Franconi, MD, University of Modena and Reggio Emilia, Via del Pozzo 71, 41124, Modena, Italy (iacopo.franconi@studio.unibo.it).

Open Forum Infectious Diseases®

© The Author(s) 2019. Published by Oxford University Press on behalf of Infectious Diseases Society of America. This is an Open Access article distributed under the terms of the Creative Commons Attribution-NonCommercial-NoDerivs licence (<http://creativecommons.org/licenses/by-nc-nd/4.0/>), which permits non-commercial reproduction and distribution of the work, in any medium, provided the original work is not altered or transformed in any way, and that the work is properly cited. For commercial re-use, please contact journals.permissions@oup.com
DOI: 10.1093/ofid/ofz105

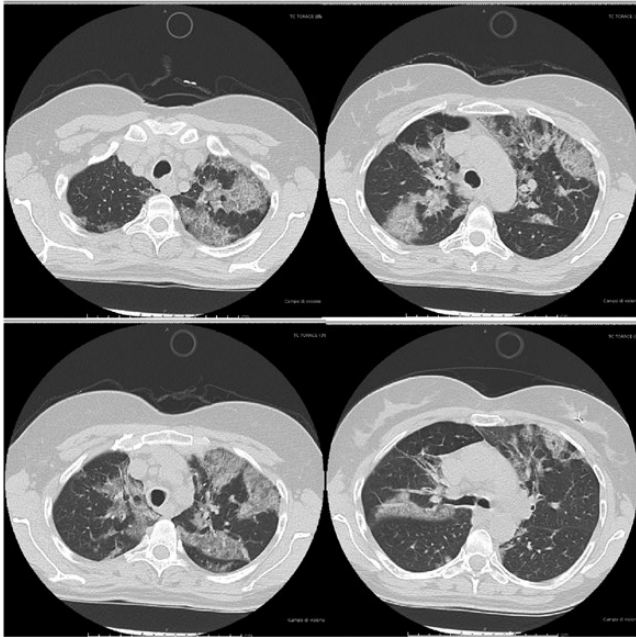


Figure 1. High-resolution computed tomography scans of the chest from upper to lower lobes showing multiple areas of parenchymal thickening with a ground glass appearance and concomitant thickening of the inter- and intralobular septa in the upper lobes bilaterally, with several parenchymal consolidations with nodular morphology prevalent in the right lower lobar site.

Thus, the vast majority of people living with HIV with a CD4+ T-cell count >500 cell/mm³ and undetectable viremia who experience H1N1 infection do not develop PJP [4].

In our patient, cigarette smoke and chronic obstructive pulmonary disease could have played a role in the pathogenesis of PJP. Tobacco smoke induces oxidative stress, mucosal inflammation, and impaired mucociliary clearance in the airways and affects the production of surfactant proteins A and D [5]. Our patient also presented with mild chronic obstructive pulmonary disease but refused to take specific therapy.

As latency is not described in PJP, colonization could have played a major role in the pathogenesis of this case [7]. The patient presented several risk factors for *Pneumocystis jirovecii* colonization: history of *Pneumocystis jirovecii* isolation from bronchoalveolar fluid at the time of AIDS diagnosis, hard smoking habit (30 pack-years), chronic obstructive pulmonary disease, and patient-reported daily gardening and hiking activities [7–9].

In addition, at admission and during her hospital stay, the patient did not come into contact with other patients with PJP as potential sources of a newly acquired *Pneumocystis* infection [10]. In fact, there were no other cases of PJP in the Infectious Diseases in-patient unit at the time, and the patient spent the first 7 days of her hospital stay in a respiratory isolation room, as per hospital protocol (an infection control measure to

prevent the in-ward spread of H1N1 infection). When respiratory isolation was lifted, she was moved to a 2-bed room with an immunocompetent patient, and no other cases of PJP were reported among other immunosuppressed subjects even after our patient's discharge.

We consequently presume that the patient was colonized by *Pneumocystis jirovecii* at the time of H1N1 infection [7–9]. Therefore, the association of both H1N1 and hard smoking on innate alveolar immunity and associated H1N1-induced T-cell CD4+ and NK-cell depletion at the time of *Pneumocystis* lung colonization might explain this rare case of PJP in an immune-reconstituted HIV-positive host on effective cART.

This work describes a rare case of PJP after influenza A H1N1 pneumonia and induced lymphopenia in a hard-smoking HIV subject on effective cART with undetectable HIV viral load throughout her hospital stay. Our case report underlines the importance of influenza vaccination among HIV-positive individuals and strengthens the importance of close monitoring of CD4+ T-cell count and clinical conditions in HIV-positive patients with hard-smoking habits, even on effective cART, presenting with influenza-like signs and symptoms during influenza season.

Acknowledgments

Potential conflicts of interest. The corresponding author and co-authors state that there are no conflicts of interest. All authors: no reported conflicts of interest. All authors have submitted the ICMJE Form for Disclosure of Potential Conflicts of Interest. Conflicts that the editors consider relevant to the content of the manuscript have been disclosed.

References

1. Pulcini C, Houssein L, Mondain V, et al. Possible pandemic H1N1 influenza complicated by *Pneumocystis jirovecii* pneumonia in an HIV-infected patient. *J Mycol Med* 2012; 22:88–91.
2. Wang X, Tan J, Biswas S, et al. Pandemic influenza A (H1N1) virus infection increases apoptosis and HIV-1 replication in HIV-1 infected jurkat cells. *Viruses* 2016; 8:33.
3. Mao H, Liu Y, Sia SF, et al. Avian influenza virus directly infects human natural killer cells and inhibits cell activity. *Virology* 2017; 32:122–9.
4. Sheth AN, Althoff KN, Brooks JT. Influenza susceptibility, severity, and shedding in HIV-infected adults: a review of the literature. *Clin Infect Dis* 2011; 52:219–27.
5. Bauer M, Fink B, Thürmann L, et al. Tobacco smoking differently influences cell types of the innate and adaptive immune system—indications from CpG site methylation. *Clin Epigenetics* 2016; 7:83.
6. Buttignol M, Pires-Neto RC, Rossi E Silva RC, et al. Airway and parenchyma immune cells in influenza A(H1N1)pdm09 viral and non-viral diffuse alveolar damage. *Respir Res* 2017; 18:147.
7. Davis JL, Welsh DA, Beard CB, et al. *Pneumocystis* colonisation is common among hospitalised HIV infected patients with non-*Pneumocystis pneumonia*. *Thorax* 2008; 63:329–34.
8. Dohn MN, White ML, Vigdorth EM, et al. Geographic clustering of *Pneumocystis carinii* pneumonia in patients with HIV infection. *Am J Respir Crit Care Med* 2000; 162:1617–21.
9. Djawe K, Levin L, Swartzman A, et al. Environmental risk factors for *Pneumocystis pneumonia* hospitalizations in HIV patients. *Clin Infect Dis* 2013; 56:74–81.
10. Fréalle E, Valade S, Guigue N, et al. Diffusion of *Pneumocystis jirovecii* in the surrounding air of patients with *Pneumocystis* colonization: frequency and putative risk factors. *Med Mycol* 2017; 55:568–72.