

Original Paper

Injected Hyaluronidase Reduces the Volume of Exogenous Hyaluronate Fillers in Mice and Results in Clinical Improvement in a Patient with Pretibial Myxedema

Sébastien Menzinger^a Aysin Kaya^b Jean-Hilaire Saurat^b Gürkan Kaya^a

^aDepartment of Dermatology, University Hospital of Geneva, and ^bSwiss Center for Applied Human Toxicology, University of Geneva, Geneva, Switzerland

Key Words

Hyaluronidase · Hyaluronate fillers · Pretibial myxedema

Abstract

Background: Hyaluronidases are essential for the breakdown of hyaluronate (HA) in tissues and may be used to prevent the adverse effects of HA fillers. **Objectives:** We explored the effect of hyaluronidase on exogenous and endogenous HA in vitro and in vivo. **Materials and Methods:** HA fillers were incubated with different concentrations of hyaluronidase and visualized by electrophoresis. HA fillers were injected in the skin of hairless mice, and 4 h later hyaluronidase was injected in the papules of exogenous HA. Hyaluronidase was injected in the nodule of pretibial myxedema of a male patient with Graves' disease. Skin sections of mice and of the patient were performed, and a skin ultrasound system was used to monitor the evolution of skin lesions. **Results:** Hyaluronidase showed a degrading effect on HA with increasing concentrations. Hyaluronidase injection significantly decreased the content of exogenous HA within 3 days. Intralesional injection of hyaluronidase resulted in dissolution of the nodule of pretibial myxedema with no recurrence during 3 months. **Conclusion.** These results show that the injection of hyaluronidase is capable of degrading exogenous HA in mouse skin and endogenous HA in human skin in vivo and may be a therapeutic option for skin diseases characterized by abnormal accumulation of HA.

© 2016 The Author(s)
Published by S. Karger AG, Basel

Sébastien Menzinger
Hôpitaux Universitaires de Genève
4, rue Gabrielle-Perret-Gentil
CH-1205 Geneva (Switzerland)
E-Mail Sebastien.Menzinger@hcuge.ch

Introduction

Hyaluronidases are endo- β -N-acetyl-hexosaminidases essential for the breakdown of glycosaminoglycan hyaluronate (HA), a major constituent of the extracellular matrix of the skin [1].

It is now recognized that the hyaluronidases are a family of enzymes. There are six hyaluronidase-like sequences in the human genome clustered in groups of three at two chromosomal sites, on chromosomes 3p21.3 (*HYAL1*, *HYAL2* and *HYAL3*) and 7q31.3 (*HYAL4*, *PH20/SPAM1* and *HYALP1*) [2]. Hyal-1 is an acid-active hyaluronidase found in mammalian plasma and urine, and is also found at high levels in major organs such as the liver, kidney, spleen and heart. Another widely expressed and important human acid-active hyaluronidase, Hyal-2, is encoded by a gene at an adjacent chromosomal site to Hyal-1. Hyal-2 is the major tissue HA-degrading enzyme; it is believed to be a lysosomal enzyme but is also found in the membrane [3]. Hyal-2 cleaves HA to 50 disaccharides (20 kDa); Hyal-1 rapidly cleaves HA into small fragments (0.8 kDa) [4].

HA is used as filler and shows an excellent safety profile, compared to other temporary agents. There is no antigenic specificity for species or tissues; thus, these agents have a low potential for allergic or immunogenic reaction [5]. Negatively charged, it binds to large amounts of water and forms a viscoelastic gel. Natural HA has a half-life in tissue of only 1–2 days, which is insufficient for use as effective dermal filler. The process of cross-linking results in larger, more stable HA molecules that have biocompatibility and viscoelastic properties similar to those of the naturally occurring substance. Cross-linking causes the ordinarily hygroscopic gel to become less water-soluble, thereby increasing product stability in tissue.

The most common side effects reported are local nonallergic reactions at the sites of injections, including pain, bruising and transient edema, but they disappear in a few days and usually do not need any treatment. Misplacement (superficial) or an uneven distribution of HA fillers can lead to visible, pale nodules in the skin.

Hyaluronidase is used to adjust misplacement of HA fillers and has also been suggested for the treatment of the rare adverse reactions to HA fillers, as by hypothesis some of the HA might still be present in the skin which might be targeted by hyaluronidase [6].

Many case reports have shown the efficacy of hyaluronidase in reducing unwanted depots of HA, with very few adverse reactions (erythema, pruritus) [7–10]. A small prospective randomized study demonstrated the efficacy of hyaluronidase in reducing small amounts of injected HA (hyaluronidase vs. saline solution) [11]. There is less evidence that hyaluronidase is also helpful in adverse reactions to HA-based fillers, but some case reports have shown an improvement after hyaluronidase injection [12, 13].

The lesions of localized myxedema occur most commonly in the pretibial area and contain large amounts of HA. In this study, we explored the effect of hyaluronidase on HA fillers in vitro and in vivo, and on endogenous HA of nodular pretibial myxedema lesions in vivo.

Materials and Methods

This study was conducted in three steps. In the first step, HA fillers (Restylane[®] and Perlane[®]) were incubated with different concentrations of hyaluronidase (Lido-Hyal B[®]) (HA:Hyal ratio = 1:1, 1:2, 1:3) for 1, 3 or 5 h and then visualized on SDS gel (lidocaine + bovine testicle hyaluronidase).

In the second step, four groups of SKH1 hairless mice were constituted. HA fillers (100 μ l = 2 mg) were injected i.d./s.c. in the back skin of three groups of mice, and 4 h later hyaluronidase (100 μ l = 17.5 U plus 2 mg lidocaine) was injected in the papules of exogenous HA

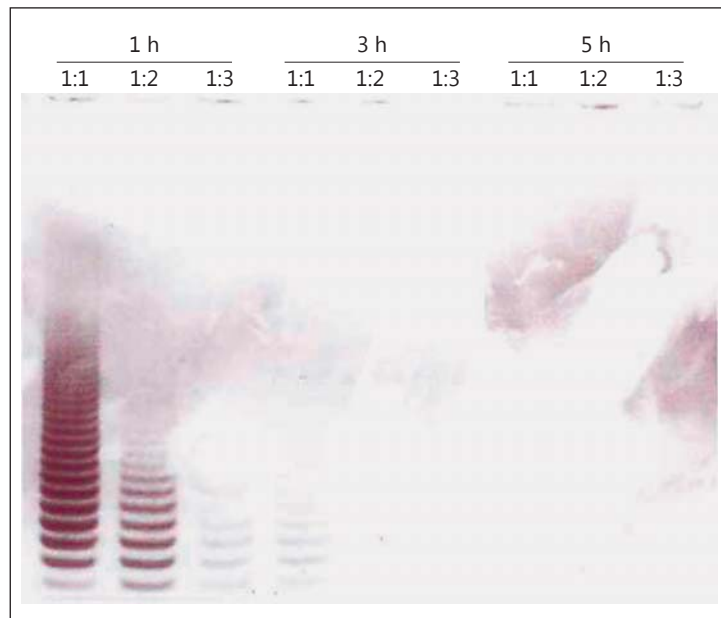


Fig. 1. Effect of hyaluronidase on exogenous HA in vitro. HA fillers were incubated with different concentrations of hyaluronidase (HA:Hyal ratio = 1:1, 1:2, 1:3) for 1, 3 or 5 h and then visualized on SDS gel with alcian blue and silver.

in one group, lidocaine only (100 μ l = 2 mg) in a second group, and nothing in a third group. The fourth group of mice was injected only hyaluronidase (plus lidocaine) without HA. The volume of the papules were then evaluated using a skin ultrasound system, and histological sections of the dorsal skin of mice injected were performed, stained with hematoxylin-eosin, colloidal iron, and immunostained by using biotin-labeled hyaluronate-binding protein (HABP; Seikagaku Kogyo, Japan), specific for HA.

In the third step, histological sections of the dorsal region of the left foot of a 51-year-old African male patient who suffered from Graves' disease and presented with post-traumatic indurated plaque and several nodules on the left pretibial area and dorsal region of the left foot consistent with pretibial myxedema, were performed, stained with hematoxylin-eosin and colloidal iron, and immunostained by using biotin-labeled HABP. Hyaluronidase (500 μ l = 87.5 U) was injected in a nodule (1.5 \times 2 cm) of the left pretibial region. The evolution of the nodule was followed clinically at days 0, 10, 17, 30 and 90. Three volume measurements of the injected nodule were performed at days 0, 10 and 17, using a skin ultrasound system.

Results

Hyaluronidase showed a clear degrading effect on exogenous high-molecular-weight HA in vitro. Figure 1 shows this effect on HA fillers incubated with different concentrations of hyaluronidase, and for different durations. HA and its fragments were completely degraded after 5 h of incubation at any concentration, after 3 h at a HA:Hyal ratio of 1:2 and 1:3 and almost completely degraded at a ratio of 1:1. After 1 h of incubation, we saw a progressive dose effect.

The degrading effect of hyaluronidase on exogenous HA (HA fillers) is also observed in vivo in mice (described in fig. 2A). In three groups of mice, HA fillers were injected into the back skin. Four hours later, in two of these three groups, lidocaine only (HA + Lido) or hyaluronidase + lidocaine (HA + Hyal/Lido) was injected in the well-formed papules. In the third

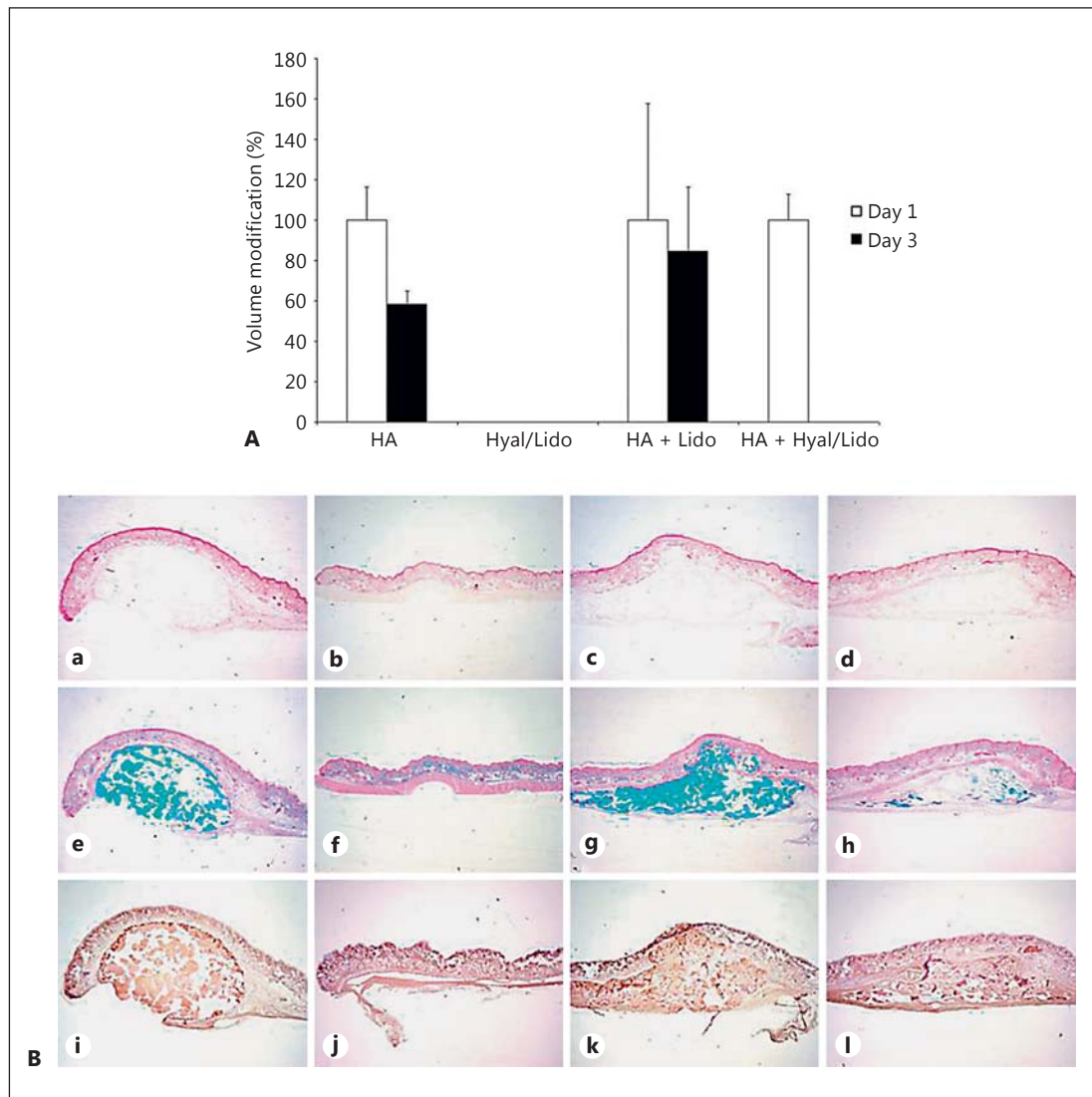


Fig. 2. A Effect of hyaluronidase on exogenous HA in vivo. HA fillers (100 μ l = 2 mg) were injected i.d./s.c. in the back skin of SKH1 hairless mice. Four hours later, hyaluronidase (100 μ l = 17.5 U) was injected in the papules of exogenous HA. The volume of the papules was calculated using a skin ultrasound system. **B** Histological sections of the dorsal skin of SKH1 hairless mice injected with exogenous HA (**a, e, i**), hyaluronidase/lidocaine (**b, f, j**), exogenous HA + lidocaine (**c, g, k**) and exogenous HA + hyaluronidase/lidocaine (**d, h, l**) stained with hematoxylin-eosin (**a–d**), colloidal iron (**e–h**) and HABP (**i–l**). Note the significant decrease of exogenous HA with hyaluronidase/lidocaine treatment (**h, l**).

group (HA), nothing was injected. Finally, in the fourth group (Hyal/Lido), no HA filler was injected. The volume of the papules was calculated using a skin ultrasound system, after 1 and 3 days.

In the HA group, the volume of exogenous HA was not changed after 1 day but decreased spontaneously by 40% after 3 days. In the HA + Lido group, the volume was also not changed after 1 day but showed a smaller reduction after 3 days, about 15%. In the HA + Hyal/Lido group, the papule of exogenous HA completely disappeared.

Histological sections (fig. 2B) were performed in all groups, stained with hematoxylin-eosin and colloidal iron, and immunostained by HABP. They showed a spontaneous decrease

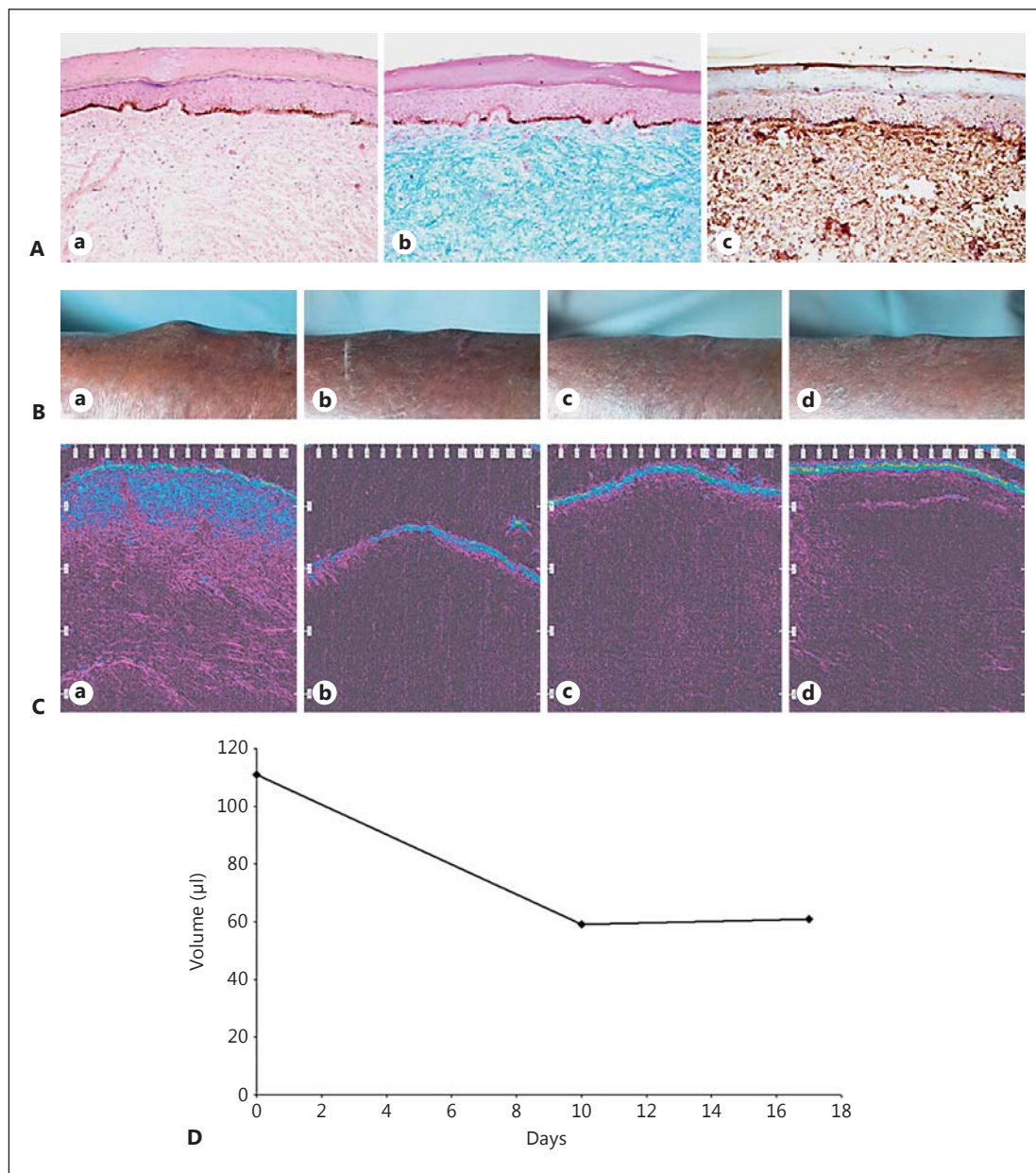


Fig. 3. A Histological sections of the dorsal region of the left foot stained with hematoxylin-eosin (**a**), colloidal iron (**b**) and HABP (**c**). Note the presence of important amounts of HA in the dermis (**b, c**). **B** Effect of injected hyaluronidase on the mucinous nodules of pretibial myxedema. Hyaluronidase (500 µl = 87.5 U) was injected in a nodule (1.5 × 2 cm) of the left pretibial region. The evolution of the nodule on day 0 (**a**), day 10 (**b**), day 17 (**c**) and day 30 (**d**). The nodule clinically disappeared within 3 days (data not shown). **C** The evolution of the nodule on day 0 (**b**), day 10 (**c**) and day 17 (**d**), observed by a skin ultrasound system and compared to nonlesional skin (**a**). **D** The evolution of the volume of the nodule was calculated using a skin ultrasound system, on days 0, 10 and 17.

of exogenous HA in the HA + Lido group and a substantial reduction of exogenous HA in the HA + Hyal/Lido group.

In pretibial myxedema, large amounts of HA are accumulated in the dermis. Figure 3A shows histological sections of a lesion of the dorsal region of the left foot in our patient

suffering from Graves' disease, confirming the presence of HA by special stains. We injected hyaluronidase in a pretibial nodule in the same patient and have followed the evolution of the nodule clinically (fig. 3B) and ultrasonographically (fig. 3C). Clinically, the nodule disappeared within 3 days and did not show any recurrence after 10, 17 and 30 days. Three volume measurements of the pretibial treated nodule were performed at days 0, 10 and 17. Figure 3D shows the evolution of the volume of the nodule. Between day 0 and day 10, the volume of the nodule was reduced by almost 50% (from 110 to 60 μ l). Between day 10 and day 17, the volume of the nodule remained unchanged.

Conclusion

It is known that hyaluronidase has a rapid degrading effect on exogenous HA [14]. Our results show that HA fillers incubated with hyaluronidase can be almost entirely degraded in 1 h with a high concentration of hyaluronidase (HA:Hyal, 1:3) and in 3 h at lower concentrations (1:2 and 1:1).

Hyaluronidase has been used for years for the treatment of side effects and misplacement of HA fillers in patients. The evidence for this treatment is based on numerous case reports, using clinical assessment and evolution as a measure of the reduction of side effects and of the amount of exogenous HA. Our study has enabled us to visualize and accurately measure the effect of hyaluronidase on HA fillers in vivo in mice using a skin ultrasound system, as well as through histological sections with different stains showing the amount of HA. We were able to show that 3 days after injection of hyaluronidase in a papule of exogenous HA, the entire volume of HA (ultrasonographically measured) disappeared, versus 40% of spontaneous volume reduction when no product was injected in the papule of exogenous HA.

In 1949, Grais [15] described the use of hyaluronidase for the treatment of pretibial myxedema. The right leg was treated by incision and drainage and the left leg with injections of hyaluronidase. He observed a clear reduction of the lesions on both sides, but without scar on the left side (hyaluronidase) [15]. In 1977, Paver [16] published a case series with 4 patients with pretibial myxedema. He treated the upper half of the leg with corticosteroid in occlusion and the lower half with injection of hyaluronidase and corticosteroid. One week later, the area treated with injection was cleared, but not the rest of the leg [16].

Therapy with hyaluronidase injections for pretibial myxedema is not currently used [17] and has not been the subject of a randomized study. Our study shows that intralesional injection of hyaluronidase results in progressive dissolution of the mucinous nodules of pretibial myxedema in a patient suffering from Graves' disease, clinically and ultrasonographically, with no recurrence during a follow-up of 3 months.

These results show that the injection of hyaluronidase may be a therapeutic option for skin disease characterized by abnormal accumulation of HA.

Acknowledgements

The authors wish to thank C. Tran, L. Stücki, D. Grand and D. Salomon for their assistance in and contributions to this publication.

Statement of Ethics

The patient gave his informed consent prior to the study. Animal experiments were in compliance with institutional standards.

Disclosure Statement

The authors declare no conflicts of interest.

References

- 1 Stern R: Devising a pathway for hyaluronan catabolism: are we there yet? *Glycobiology* 2003;13:105R–115R.
- 2 Csoka AB, Frost GI, Stern R: The six hyaluronidase-like genes in the human and mouse genomes. *Matrix Biol* 2001;20:499–508.
- 3 Lepperdinger G, Müllegger J, Kreil G: Hyal2 – less active, but more versatile? *Matrix Biol* 2001;20:509–514.
- 4 Stern R, Kogan G, Jedrzejewski MJ, et al: The many ways to cleave hyaluronan. *Biotech Adv* 2007;25:537–557.
- 5 Monheit GD, Coleman KM: Hyaluronic acid fillers. *Dermatol Ther* 2006;19:141–150.
- 6 Rzany B, Becker-Wegerich P, Bachmann F, et al: Hyaluronidase in the correction of hyaluronic acid-based fillers: a review and a recommendation for use. *J Cosmet Dermatol* 2009;8:317–323.
- 7 Hirsch RJ, Narurkar V, Carruthers J: Management of injected hyaluronic acid induced Tyndall effects. *Lasers Surg Med* 2006;38:202–204.
- 8 Soparkar CN, Patrinely JR, Tschien J: Erasing restylane. *Ophthalmol Plast Reconstr Surg* 2004;20:317–318.
- 9 Pierre A, Levy PM: Hyaluronidase offers an efficacious treatment for inaeesthetic hyaluronic acid overcorrection. *J Cosmet Dermatol* 2007;6:159–162.
- 10 Brody HJ: Use of hyaluronidase in the treatment of granulomatous hyaluronic acid reactions or unwanted hyaluronic acid misplacement. *Dermatol Surg* 2005;31:893–897.
- 11 Vartanian AJ, Frankel AS, Rubin MG: Injected hyaluronidase reduces restylane-mediated cutaneous augmentation. *Arch Facial Plast Surg* 2005;7:231–237.
- 12 Hirsch RJ, Cohen JL, Carruthers JD: Successful management of an unusual presentation of impending necrosis following a hyaluronic acid injection embolus and a proposed algorithm for management with hyaluronidase. *Dermatol Surg* 2007;33:357–360.
- 13 Soparkar CN, Patrinely JR: Managing inflammatory reaction to restylane. *Ophthalmol Plast Reconstr Surg* 2005;21:151–153.
- 14 Lambros V: The use of hyaluronidase to reverse the effects of hyaluronic acid filler. *Plast Reconstr Surg* 2004;114:277.
- 15 Grais ML: Local injections of a preparation of hyaluronidase in the treatment of localized (pretibial) myxedema. *J Invest Dermatol* 1949;12:345–348.
- 16 Paver WK: The treatment of pretibial myxoedema and cutaneous myxoid cysts. *Australas J Dermatol* 1977;18:144–145.
- 17 Fatourechi V: Pretibial myxedema: pathophysiology and treatment options. *Am J Clin Dermatol* 2005;6:295–309.