




Pulmonary embolism in patients with COVID-19 pneumonia on adequate oral anticoagulation

Giuseppe Di Tano¹ · Meghi Dede² · Irene Pellicelli³ · Enrico Martinelli³ · Luigi Moschini¹ · Elva Calvaruso¹ · Gian Battista Danzi^{1,4} 

Accepted: 13 October 2021 / Published online: 27 October 2021

© The Author(s), under exclusive licence to Springer Science+Business Media, LLC, part of Springer Nature 2021

Abstract

Thrombotic complications are common in patients with severe COVID-19 pneumonia with important consequences on the diagnostic and therapeutic management. We report a consecutive series of five patients on long-term oral anticoagulation therapy who presented to our hospital for severe COVID-19 pneumonia associated with segmental acute pulmonary embolism despite adherence to therapy and with an adequate anticoagulant range at the time of the event. Four patients were receiving a direct oral anticoagulant (two with edoxaban, one with rivaroxaban and one with apixaban) and one patient a vitamin K antagonist. No significant thrombotic risk factors, active cancer, or detectable venous thromboembolism were present. In all cases, elevated d-dimer and fibrinogen levels with a parallel rise in markers of inflammation were documented. The combination of these findings seems to support the hypothesis that considers the local vascular damage determined by severe viral infection as the main trigger of thrombi detected in the lungs, rather than emboli from peripheral veins.

Keywords Pulmonary embolism · Infectious diseases · Anticoagulant

Highlights

- COVID-19 infection is associated with frequent thromboembolic events.
- Systemic anticoagulant therapy appears to be generally useful.
- Despite appropriate chronic anticoagulant therapy, segmental and subsegmental acute pulmonary embolism is documented.
- In this specific clinical scenario, the embolic genesis of pulmonary embolism is uncertain and complex interactions

between inflammation and coagulation play a major role.

Introduction

The COVID-19 does not involve only the respiratory tract, but has also major implications for the cardiovascular system [1]. Recently, accumulating data have shown an increased number of thromboembolic events among hospitalized patients which seems to suggest that coagulation function may be significantly impaired [2, 3] with important consequences on the diagnostic and therapeutic management of these patients [4]. Some studies pointed out that a dysregulated immune response, as seen during the inflammatory storm associated with COVID-19, could play a decisive role in endothelial dysfunction and thrombosis [5, 6], and microvascular permeability is crucial in viral infections. This condition is aggravated by hypoxia, which augments thrombosis by both increasing blood viscosity and hypoxia-inducible transcription factor-dependent signaling pathway [7].

Recently, clinical and autopsic studies reported a high rate of thrombotic complications in hospitalized patients, despite

✉ Gian Battista Danzi
gbdanzi@gmail.com

¹ Cardiology Unit, Cremona Hospital, Cremona, Italy

² Maxillo-Facial Surgery Unit, Head and Neck Department, Santi Paolo e Carlo University Hospital, Università degli Studi di Milano, Milan, Italy

³ Pneumology Unit, Cremona Hospital, Cremona, Italy

⁴ Divisione di Cardiologia, Ospedale di Cremona, Viale Concordia, 1, 26012 Cremona, Italy

systematic prophylactic [8] or therapeutic anticoagulation [9, 10].

We report a consecutive series of five patients on long-term oral anticoagulation therapy who presented to our hospital for severe COVID-19 pneumonia associated with segmental pulmonary embolism (PE) despite a correct adherence to therapy and with adequate anticoagulant range at the time of the event. Our observations seem to reinforce the hypothesis of inflammatory-procoagulant pathogenesis undermining the clinical manifestations of COVID-19 which appear to be not fully protected by conventional anticoagulant treatment.

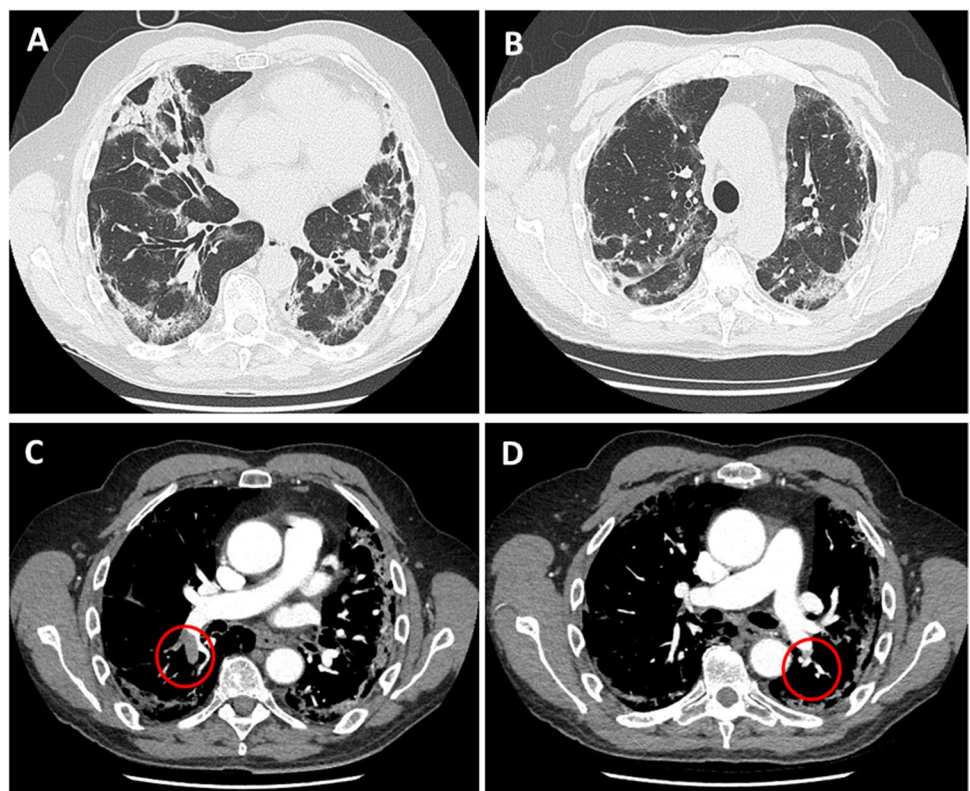
Case reports

We analyzed demographic, clinical, radiological and laboratory characteristics of five consecutive patients on chronic anticoagulation therapy who presented in the emergency department (between March 1st and May 5th 2020) for severe COVID-19 pneumonia. Pneumonia was associated with acute PE diagnosed by means of CT pulmonary angiography (CTPA) at the time of admission (Fig. 1). According to our Institutional protocol, CTPA was performed in all subjects who met a Geneva score > 10 [11], and/or when the clinical suspicion of PE was very high, based on inadequate response to ventilation, or to high-flow oxygen therapy.

CTPA was performed by a 64-row multidetector computed tomography scanner. The scan included the entire chest, with a cranio-caudal direction of scanning, and supine patient position. Standard CT scan settings were adopted: 120 kV tube voltage; 100–300 mA for tube current; 0.5 s of gantry rotation time; 64×0.6 mm detector collimation. Vessel attenuation was obtained by injecting 50–70 mL (volume calculated based on patient's body weight) of non-ionic iodinated contrast media (iopamidol, Iopamiron 370 mg iodine/mL; Bracco, Milan, Italy) followed by a saline chaser of 25 mL through an antecubital vein at a flow rate of 3–4 mL/s, using a mechanical power injector. CT acquisition was timed by using bolus-tracking technique with a region-of-interest (ROI) placement in the pulmonary trunk. Once a threshold of 100 Hounsfield Units (HU) was reached, the scan automatically started after a delay of 5 s. Images were reconstructed with a thickness and increment of 1.25 mm. All CTPA scans were interpreted by two experienced radiologists and disagreements were resolved through discussion until consensus was reached.

SARS-CoV2 infection was confirmed by positive nasopharyngeal swab on real-time reverse transcriptase–polymerase chain reaction assay. Four of them were on chronic direct oral anticoagulants (DOAC) therapy (two patients were receiving edoxaban, one patient rivaroxaban, and one patient apixaban) and one was receiving a vitamin K antagonist (VKA). At admission, all patients claimed to diligently

Fig. 1 Panel **A** and **B** Chest CT scan showing diffuse areas of consolidations and interlobular and intralobular septal thickenings involving both lung parenchymas. Panel **C** and **D** CT pulmonary angiography in axial view showing filling defects involving the inferior branch of the right pulmonary artery (open circles) and the posterior basal segmental branch of the left pulmonary artery (open circle)



take the drugs, and at the same, time plasma samples were collected (an average of 15 h after the last dose intake). Appropriated DOAC plasma levels, and a prothrombin time, international normalized ratio (PT INR) > 2, with a time in therapeutic range (TTR) > 75% were confirmed by laboratory findings in all cases (Table 1). DOAC levels measurements (expressed as drug concentration-equivalent in ng/ml) were evaluated by using a specific anti FXa assay calibrated for apixaban, edoxaban, and rivaroxaban (Atellica COAG 360TM, Stago, France) [12]. At the time of admission, oral anticoagulant therapy was promptly replaced with a full dose (100UI/kg bid) of subcutaneous low-molecular-weight heparin up to one month of follow-up.

The chronic anticoagulant treatment had been previously prescribed as primary prevention of atrial fibrillation (AF)-related stroke in three patients and as secondary prevention of venous thromboembolism (VTE) in the remaining two patients. The dosages of DOACS were prescribed

for each drug according to age, weight, and renal function as recommended by the international guidelines [13]. Two patients received anticoagulation after an episode of PE that was a consequence of a deep venous thrombosis (DVT) as a complication of a fracture of the lower limb. These episodes have occurred one year and six months before the present hospitalization. No other predisposing or genetic factors were reported. Demographic, comorbidities data, and main risk factors were recorded, as well as the main clinical features (ARDS severity by PaO₂/FIO₂ ratio, according to Berlin definition [14], PE type based on CTPA description, laboratory findings (including coagulation markers) and clinical outcomes. All the collected data are summarized in Table 1. All patients underwent lower extremities doppler ultrasonography but no sign of deep vein thrombosis (DVT) was detected. Transthoracic echocardiography showed no dilatation of right ventricular or pulmonary hypertension.

Table 1 Demographic, clinical, radiological and laboratory findings

	Case 1	Case 2	Case 3	Case 4	Case 5
Age (years)	86	67	63	83	86
Gender	M	M	M	F	F
Weight (Kg)	68	65	72	49	60
BMI > 30	–	–	–	–	–
Hypertension	+	–	–	+	–
Diabetes	+	–	–	–	+
Heart failure	+	–	–	+	–
COPD	+	+	–	–	+
Active cancer	–	–	–	–	–
Chronic renal failure	+	–	–	–	–
Anticoagulant drug	Rivaroxaban	Edoxaban	Apixaban	Edoxaban	Warfarin
Anticoagulant dose	15 mg day	60 mg day	5 mg BID	30 mg day	
Plasma drug concentration ng/ml	68 (LloD: 25)	54 (LloD: 20)	48 (LloD: 25)	62 (LloD: 20)	
Indication to anticoagulation	AF	Previous PE	Previous PE	AF	AF
PE distribution	Segmental	Segmental	Subsegmental	Subsegmental	Subsegmental
ARDS severity at admission	Mild	Severe	Mild	Severe	Mild
PaO ₂ /FIO ₂ ratio	187	93	178	88	190
PLT count x10 ³	283	116	160	269	215
CRP mg/l (nv: <5)	70.5	82	33.2	321	27.3
D-dimer µg/ml (nv: 0.5)	3.99	18.4	7.2	0.27	1.7
LDH U/l (nv: <248)	234	786	214	447	358
INR	1.85	1.03	1.18	2.69	2.33
APTT (nv: < 1.2)	1.37	0.99	1.01	1.59	1.62
TTr (nv: <1.2)	1.10	1.3	1.60	1.2	0.9
Fibrinogen ml/dl (nv: < 200)	348	476	365	286	210
Creatinine mg/dl (nv: < 1.18)	1.28	1.09	0.86	0.74	0.6
eGFR (mL/min)	39.8	60.5	89	44.6	63.8

BMI body mass index, *AF* atrial fibrillation, *PE* pulmonary embolism, *ARDS* acute respiratory distress syndrome, *PaO₂* arterial partial pressure of oxygen, *FIO₂* fraction of inspired oxygen, *PLT* platelet, *CRP* C-reactive protein, *LDH* lactate dehydrogenase, *INR* international normalized ratio, *APTT* activated partial thromboplastin time, *TTr* thrombin time ratio, *LloD* lower limit of detection, *eGFR* estimated glomerular filtration rate

Discussion

Increased thromboembolic events among COVID-19 hospitalized patients have been largely reported [2, 3]. A French experience observed a frequency of PE twice higher than that found in a control period [15]. Additionally, clinical [16] and autopsy studies of patients who died of COVID-19 described a high incidence of deep venous thrombosis, with one-third of the patients who had a pulmonary embolism as the direct cause of death [17].

Approximately 1–2% of the western population is chronically treated with an oral anticoagulant [18], but, in the pre-COVID-19 era thrombotic events in patients on anticoagulation therapy were pretty uncommon [19]. In the PREFER Registry, among patients receiving chronic anticoagulation for AF (VKA in 48.7% of cases and a DOAC in 24.5%), the DVT recurrence was 3.9% with an overall incidence of PE of 1.3% [20]. Furthermore, only one recurrent episode of VTE (1.7 events per 100 patient-years) was documented in the more recent Dresden NOAC Registry [21]. However, COVID-19 infection is now considered an additional risk factor for DVT in hospitalized patients, but the rate of thrombotic recurrence in treated patients is unknown.

We report a series of five consecutive patients on chronic anticoagulant therapy who presented to our emergency department with severe COVID-19 pneumonia associated with acute PE. The peculiarity of this population is characterized by absence of major predisposing thrombotic risk factors: lack of detectable or recurrent history of VTE; no signs of active cancer or impairment of renal function; elevated D-dimer and fibrinogen levels with a parallel rise in markers of inflammation; localization of thrombus in the segmental and subsegmental branches of pulmonary arteries. Even if our observation is concerning a small sample of patients, these findings seem to support the hypothesis of a local vascular damage determined by viral infection in severe COVID-19 as the main trigger of thrombi detected in the lungs, rather than emboli from peripheral veins [22]. Recent morphologic studies may corroborate this pathological mechanism. In a series of autopsies of deceased COVID-19 patients [10, 23], pulmonary arteries at the hilum were free of thrombo-emboli, moreover, an elevated rate of platelet-fibrin thrombi in small arterial vessels (< 1 mm) was documented in the lung periphery, along with inflammatory infiltrate composed by macrophages in alveolar lumens and lymphocytes. This etiopathogenetic mechanism based on intense inflammatory-hypercoagulable status could explain the lack of protective effects of oral anticoagulant drugs (DOACS and VKA) despite their correct dose of administration and the evidence of adequate INR values and plasma levels. The latter were

obtained by means of a validated specific anti FXa assay [12] and not via mass-spectrometry [24]. Consequently, we should cautiously consider the findings of DOACS concentration in this limited sample size.

In conclusion, recent observations suggest that COVID-19 infection promotes hypercoagulability. Our case series of severe interstitial pneumonia associated with acute PE in patients chronically treated with oral anticoagulant therapy underlines the role of complex interactions between inflammation and coagulation, representing a further challenge in the treatment of COVID-19 disease.

Author contributions GDT designed the study; MD and IP contributed to data collection; all authors contributed to the interpretation of the data collected; GDT, MD and GBT wrote the draft of the manuscript; all the authors contributed to the final revision and accepted the manuscript.

Declarations

Conflict of interest None of the authors has a conflict of interest to declare.

References

1. Guo T, Fan Y, Chen M et al (2020) Cardiovascular implications of fatal outcomes of patients with coronavirus disease 2019 (COVID-19). *JAMA Cardiol* 5:811–818
2. Bikdeli B, Madhavan MV, Jimenez D (2020) e al. COVID-19 and Thrombotic or Thromboembolic Disease: Implications for prevention, antithrombotic therapy, and follow-up. *J Am Coll Cardiol* 75:2950–2973
3. Danzi GB, Loffi M, Galeazzi G, Gherbesi E (2020) Acute pulmonary embolism and COVID-19 pneumonia: a random association? *Eur Heart J* 41:1858
4. Tang N, Bai H, Chen X et al (2020) Anticoagulant treatment is associated with decreased mortality in severe coronavirus disease 2019 patients with coagulopathy. *J Thromb Haemost* 18:1094–1099
5. Schulz C, Engelmann B, Massberg S (2013) Crossroads of coagulation and innate immunity: the case of deep vein thrombosis. *J Thromb Haemost* 11(Suppl 1):233–241
6. Mezger M, Nording H, Sauter R et al (2019) Platelets and Immune Responses During Thromboinflammation. *Front Immunol* 10:1731
7. Varga Z, Flammer AJ, Steiger P et al (2020) Endothelial cell infection and endotheliitis in COVID-19. *Lancet* 395:1417–1418
8. Klok FA, Kruip MJHA, van der Meer NJM et al (2020) Incidence of thrombotic complications in critically ill ICU patients with COVID-19. *Thromb Res* 191:145–147
9. Llitjos JF, Leclerc M, Chochois C et al (2020) High incidence of venous thromboembolic events in anticoagulated severe COVID19 patients. *Thromb Haemost* 18:1743–1746
10. Lax SF, Skok K, Zechner P et al (2020) Pulmonary arterial thrombosis in COVID-19 with fatal outcome: results from a prospective, single-center, clinicopathologic case series. *Ann Intern Med* 173:350–361

11. Klok FA, Mos ICM, Nijkeuter M et al (2008) Simplification of the revised Geneva score for assessing clinical probability of pulmonary embolism. *Arch Intern Med* 168:2131–2136
12. Gosselin RC, Adcock DM, Bates SM et al (2018) International council for standardization in Hematology (ICSH). Recommendations for laboratory measurement of direct oral anticoagulants. *J Thromb Haemost* 118:437–450
13. Steffel TJ, Verhamme P, Tatjana S. Potpara TS et al (2018) The 2018 European Heart Rhythm Association Practical Guide on the use of non-vitamin K antagonist oral anticoagulants in patients with atrial fibrillation. *Eur Heart J* 39:1330–1393
14. Ranieri VM, Rubenfeld GD, Thompson BT et al (2012) Acute respiratory distress syndrome. *JAMA* 307:2526–2533
15. Poissy J, Goutay J, Caplan M et al (2020) Pulmonary embolism in COVID-19 patients: awareness of an invcreased prevalence. *Circulation* 142:184–186
16. Zhang L, Fenf X, Zhang D et al (2020) Deep Vein Thrombosis in Hospitalized Patients with Coronavirus Disease 2019 (COVID-19) in Wuhan, China: Prevalence, Risk Factors, and Outcome. *Circulation* 142:114–128
17. Fox SE, Akmatbekov A, Harbert JL et al (2020) Pulmonary and cardiac pathology in COVID-19: The first autopsy series from new orleans. *Lancet Respir Med* 8(7):681–686
18. Testa S, Paoletti O, Giorgi-Pierfranceschi M, Pan A (2020) Switch from oral anticoagulants to parenteral heparin in SARS-CoV-2 hospitalized patients. *Intern Emerg Med* 15:751–753
19. Schulman S (2017) How I treat recurrent venous thromboembolism in patients receiving anticoagulant therapy. *Blood* 129:3285–3293
20. Cohen AT, Gitt AK, Bauersachs R et al (2017) The management of acute venous thromboembolism in clinical practice. Results from the European PREFER in VTE Registry. *J Thromb Haemost* 117:1326–1337
21. Beyer-Westendorf J, Förster K, Pannach S et al (2014) Management, and outcome of rivaroxaban bleeding in daily care: results from the Dresden NOAC Registry. *Blood* 124:955–962
22. Cattaneo M, Bertinato EM, Birocchi S, Brizio et al (2020) Pulmonary embolism or pulmonary thrombosis in COVID-19? Is the recommendation to ude high-dose heparin for thromboprophylaxis justified. *J Thromb Haemost* 120:1230–1232
23. Wichmann D, Sperhake JP, Lütgehetmann M et al (2020) Autopsy Findings and Venous Thromboembolism in Patients With COVID-19: A Prospective Cohort Study. *Ann Intern Med*. <https://doi.org/10.7326/M20-2003>
24. Douxfils J, Gosselin RC (2017) Laboratory Assessment of Direct Oral Anticoagulants. *Semin Thromb Hemost* 43:277–290

Publisher's Note Springer Nature remains neutral with regard to jurisdictional claims in published maps and institutional affiliations.