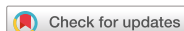

Review Article



Mechanical Circulatory Support for Acute Heart Failure Complicated by Cardiogenic Shock

Min Suk Choi , MD¹, Hunbo Shim , MD, PhD², and Yang Hyun Cho , MD, PhD³

¹Department of Thoracic and Cardiovascular Surgery, Dongguk University Ilsan Hospital, Dongguk University School of Medicine, Goyang, Korea

²Division of Cardiac Surgery, Brigham and Women's Hospital, Harvard Medical School, Boston, MA, USA

³Department of Thoracic and Cardiovascular Surgery, Samsung Medical Center, Sungkyunkwan University School of Medicine, Seoul, Korea

OPEN ACCESS

Received: Dec 15, 2019

Revised: Jan 14, 2020

Accepted: Jan 14, 2020

Correspondence to

Yang Hyun Cho, MD, PhD


Department of Thoracic and Cardiovascular Surgery, Samsung Medical Center, Sungkyunkwan University School of Medicine, 81, Irwon-ro, Gangnam-gu, Seoul 06351, Korea.
E-mail: yanghyun.cho@samsung.com


Copyright © 2020. Korean Society of Heart Failure

This is an Open Access article distributed under the terms of the Creative Commons Attribution Non-Commercial License (<https://creativecommons.org/licenses/by-nc/4.0>) which permits unrestricted noncommercial use, distribution, and reproduction in any medium, provided the original work is properly cited.

ORCID iDs

Min Suk Choi 
<https://orcid.org/0000-0002-5482-1272>

Hunbo Shim 
<https://orcid.org/0000-0002-8140-1097>

Yang Hyun Cho 
<https://orcid.org/0000-0003-1685-3641>

Conflict of Interest

The authors have no financial conflicts of interest.

Author Contributions

Conceptualization: Choi MS, Cho YH; Data curation: Cho YH; Formal analysis: Choi MS; Investigation: Choi MS, Shim H; Methodology: Cho YH; Project administration: Choi MS; Resources: Shim H, Cho YH; Supervision: Cho

ABSTRACT

Acute heart failure is a potentially life-threatening condition that can lead to cardiogenic shock, which is associated with hypotension and organ failure. Although there have been many studies on the treatment for cardiogenic shock, early mortality remains high at 40–50%. No new medicines for cardiogenic shock have been developed. Recently, there has been a gradual decline in the use of the intra-aortic balloon pump mainly due to a lack of adequate hemodynamic support. Extracorporeal membrane oxygenation and the percutaneous ventricular assist device have become more widely used in recent years. A thorough understanding of the mechanisms of such mechanical support devices and their hemodynamic effects, components of the devices, implantation technique, management, criteria for indications or contraindications of use, and clinical outcomes as well as multidisciplinary decision making may improve the outcomes in patients experiencing cardiogenic shock.

Keywords: Extracorporeal membrane oxygenation; Heart-assist devices; Heart failure; Intra-aortic balloon pumping; Shock, cardiogenic

ACUTE HEART FAILURE AND CARDIOGENIC SHOCK

Acute heart failure (AHF) and cardiogenic shock (CS) are similar but somewhat different concepts. The 2016 European Society of Cardiology (ESC) described AHF as a “rapid onset or worsening of symptoms and/or signs of heart failure”.¹ CS is defined as a state of circulatory shock caused by dysfunction of cardiac pumping. We believe that the cause of both conditions is dysfunctional cardiac pumping. However, the presentation is more severe in CS than in AHF. Circulatory shock refers to hypotension accompanied by symptoms and signs of organ hypoperfusion such as altered mentality, cold and mottled skin, reduced urine output, low central venous oxygen saturation, and increased serum lactate.² Symptoms and signs of heart failure are dyspnea, indigestion, peripheral edema, and increased jugular venous pressure and so on.

The causes of AHF and CS are diverse. Acute myocardial infarction (AMI) with subsequent ventricular dysfunction, the most frequent cause of CS, accounts for approximately 80% of cases. Mechanical complications of AMI, such as ventricular septal (4%) or free wall (2%) rupture and acute severe mitral regurgitation (7%) are less frequent causes of CS after AMI.³

YH; Visualization: Choi MS; Writing - original draft: Choi MS; Writing - review & editing: Choi MS, Shim H, Cho YH.

Causes of non-AMI-related CS include acute myocarditis, arrhythmias, cardiac tamponade, traumatic cardiac injury, pulmonary thromboembolism (PTE), dynamic left ventricular (LV) outflow tract obstruction, myocardial depression in sepsis, and acute decompensated heart failure superimposed on chronic stable heart failure in conditions such as valvular heart disease, dilated cardiomyopathy, and constrictive pericarditis.¹⁾⁴⁾⁵⁾

CS is associated with a high rate of in-hospital mortality, with in-hospital mortality rate of AMI complicated by CS at 33–45%.⁶⁻⁸⁾ Therefore, successful treatment of CS will result in an increased survival rate. To treat CS, various mechanical circulatory support (MCS) devices have recently been introduced, although medications such as inotropes, vasopressors, or diuretics are still priority treatment options. Intra-aortic balloon pump (IABP) has become the most widely used hemodynamic support device since its introduction in the 1960s.⁹⁾ However, IABP was replaced by other advanced MCS devices during the recent decade. In Korea, the use of IABP decreased by >50% between 2012 and 2017. However, the use of extracorporeal membrane oxygenation (ECMO) has dramatically increased in the country (**Figure 1**).

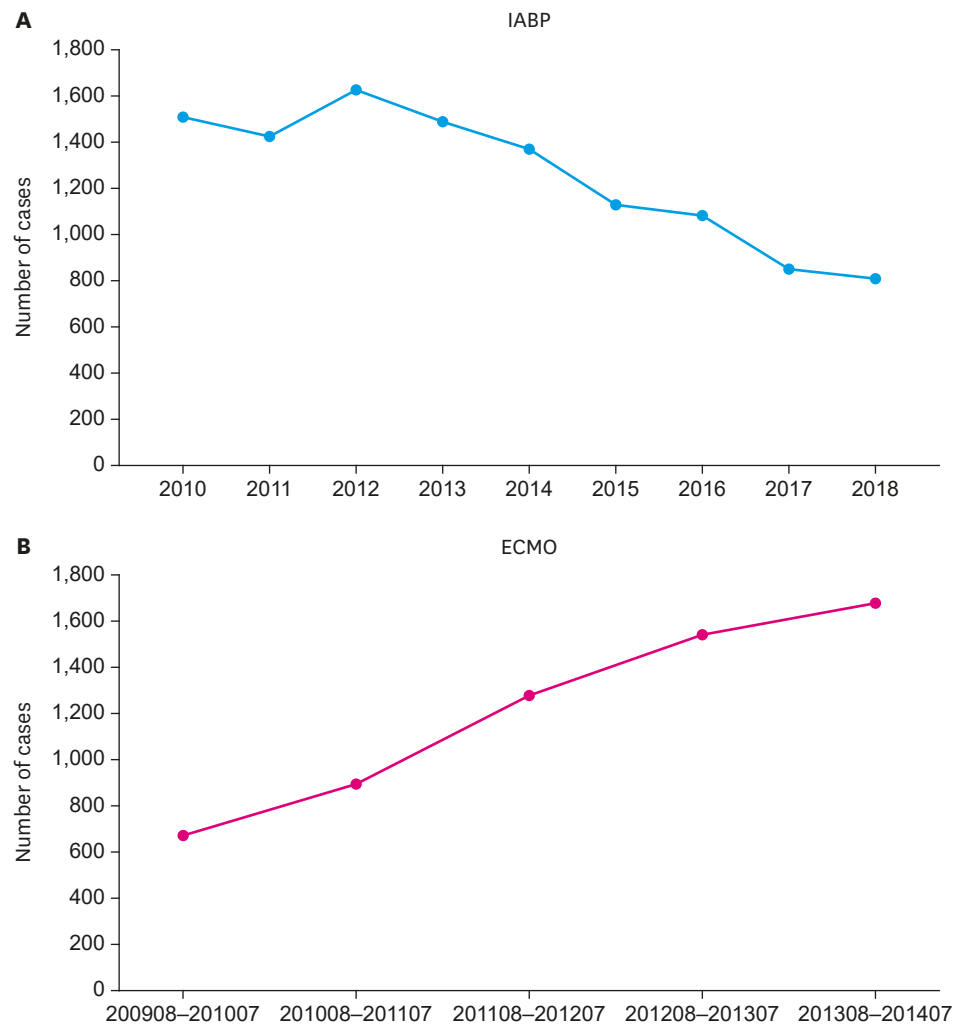

Figure 1. Trends in the number of cases involving the use of the IABP and ECMO in Korea. (A) IABP cases in Korea from Healthcare Bigdata Hub (<http://opendata.hira.or.kr/op/opc/olapDiagBhvinfo.do>). (B) ECMO cases in Korea.⁵²⁾ ECMO = extracorporeal membrane oxygenation; IABP = intra-aortic balloon pump.

MEDICAL MANAGEMENT OF CARIOGENIC SHOCK

The key principles of the medical management of CS are as follows: (i) maintenance of adequate blood pressure (BP) and organ perfusion, (ii) management of organ failure using ventilator and hemodialysis, and (iii) identification and resolution of the cause of cardiac failure. To stabilize a patient in CS, physicians attempt to optimize volume status and infuse inotropes and vasopressors to maintain adequate BP and organ perfusion. Although several inotropes, vasopressors, and combination methods have been used to treat CS, their selection is generally based on a physician's judgement and experience. Therefore, their use in a patient with CS is extremely diverse. Subgroup analysis in a multicenter, randomized trial showed that dopamine, compared to norepinephrine, was associated with an increased early mortality rate among patients with CS.¹⁰⁾ The role of medical therapy may be confined to the stabilization of the patient until the cause is resolved. Current inotropes for CS may complicate AHF by increasing myocardial oxygen demand and consumption, and vasoconstrictors may impair microcirculation or tissue perfusion of the heart and other major organs¹¹⁾; therefore, their use should be restricted to the shortest possible duration and the lowest possible dose.⁵⁾ The ESC recommended that short-term intravenous infusion of inotropes may be considered in patients with CS (class IIb recommendation).¹⁾ Failure of maximal medical therapy is no longer a justifiable endpoint, given the array of available mechanical circulatory supports.¹²⁻¹⁵⁾

TIMING OF MECHANICAL SUPPORT: STABILIZATION PRIORITY STRATEGY

Although the most studied disease among the causes of CS is AMI, there are only a few randomized trials for AMI complicated by CS in which better management options were investigated. In 1999, Hochman et al. (the SHOCK investigators) found that early revascularization did not improve 30-day survival.¹⁶⁾ In 2012, Thiele et al.¹⁷⁾ (IABP-SHOCK II investigators) reported that compared with medical management, IABP did not improve 30-day survival. Thiele et al.¹⁸⁾ (CULPRIT-SHOCK investigators) revealed that the 30-day survival of culprit-only revascularization is superior to that of complete revascularization in patients with CS caused by AMI. Because the most common cause of 30-day death in these patients is multi-organ failure due to profound shock or cardiac arrest, maintaining adequate hemodynamic support during the initial stage may be crucial. Therefore, short-term MCS other than IABP has been recommended in medically refractory CS to unload the failing ventricle and maintain sufficient end-organ perfusion; however, the level of recommendations and evidence in the guidelines of major cardiology societies is low.¹⁾¹⁹⁻²¹⁾

Esposito et al.²²⁾ introduced the term “door-to-support time” and recommended that this time should be reduced. In fact, the most important factor in the delay of “door-to-support time” is thought to be the decision-making time taken to implement MCS rather than the MCS procedure time. The SHOCK and CULPRIT-SHOCK trials showed that the timing and completeness of revascularization of a coronary artery may not be the critical factor for early survival of patients with AMI and CS. The IABP-SHOCK II trial revealed that IABP may be insufficient to support such unstable patients, i.e., 45% of patients had cardiopulmonary resuscitation (CPR) before randomization. These facts support the recommendation of strong MCS followed by cause correction. Cardiac output, BP, and systemic vascular resistance have a compound effect on systemic circulation. Esposito et al.²²⁾ described

heart failure that is not complicated by CS as a “hemodynamic” problem and heart failure complicated by CS as a “hemometabolic” problem. If hemodynamic derangements persist in patients with AHF, a potentially reversible hemodynamic problem transitions to a more complex “hemometabolic” problem that may not respond to hemodynamic support alone.

We believe that the decision-making time is usually extended by administering inotropes or vasopressors to the maximum dosage. However, as mentioned previously, most medications for CS increase myocardial oxygen demand and impair microcirculation. Basir et al.²³⁾ described that early implantation of an MCS device before the use of inotropes and vasopressors was associated with increased survival ($p=0.05$). Survival was 68%, 46%, 35%, 35%, and 26% for patients requiring 0, 1, 2, 3, and ≥ 4 inotropes before MCS support, respectively ($p<0.001$). Therefore, we believe that the prognosis would be optimal if the decision regarding MCS implementation occurs as soon as AHF becomes complicated by CS or when the end-organ perfusion begins to decrease. Indicators of end-organ malperfusion are blood lactate level, mixed venous saturation, and urine output.²²⁾²⁴⁾ Certainly, early MCS implementation before the patient requires high-dose medications is theoretically attractive but requires further study in controlled trials. Several recent studies have reported improved survival with early initiation of MCS before percutaneous coronary revascularization in patients with CS complicating AMI.²³⁾²⁵⁻²⁸⁾

In addition, comprehensive consideration should be given to the risk of complications of MCS, possibility of MCS weaning (bridge to recovery), and intention of the patient and family members to bridge the long-term MCS (bridge to bridge or destination therapy) or heart transplantation (bridge to transplant). In addition, MCS devices can be used as a “bridge to decision or diagnosis.”²⁹⁾

MECHANICAL CIRCULATORY SUPPORT DEVICES

Intra-aortic balloon pump counterpulsation

Mechanism

This device uses the counterpulsation of a balloon in the descending thoracic aorta to decrease the LV afterload and increase coronary perfusion.

Hemodynamic effects

Inflation occurs at the onset of diastole, just after the dicrotic notch on the aortic pressure waveform, which increases the diastolic pressure of the aorta. There is a resulting increase in systemic perfusion, including coronary perfusion. Balloon deflation is timed to occur at the end of diastole or immediately prior to systole and reduces the LV afterload leading to improved cardiac output (**Figure 2A**).³⁰⁾

Components and catheterization

The balloon catheter is inserted through the femoral artery and positioned in the proximal descending thoracic aorta. The system comprises a dual-lumen 7.5-F to 8.0-F catheter with a polyethylene balloon and the control console. The inner catheter lumen accepts the guidewire during placement and transduces the aortic pressure for monitoring. The gas lumen serves as the conduit for the rapid exchange of helium in and out of the balloon.³⁰⁾

The proper position of the distal tip is 1–2 cm distal to the left subclavian artery (the second to third intercostal space or 2 cm above the carina).³¹⁾ Balloon obstruction of the

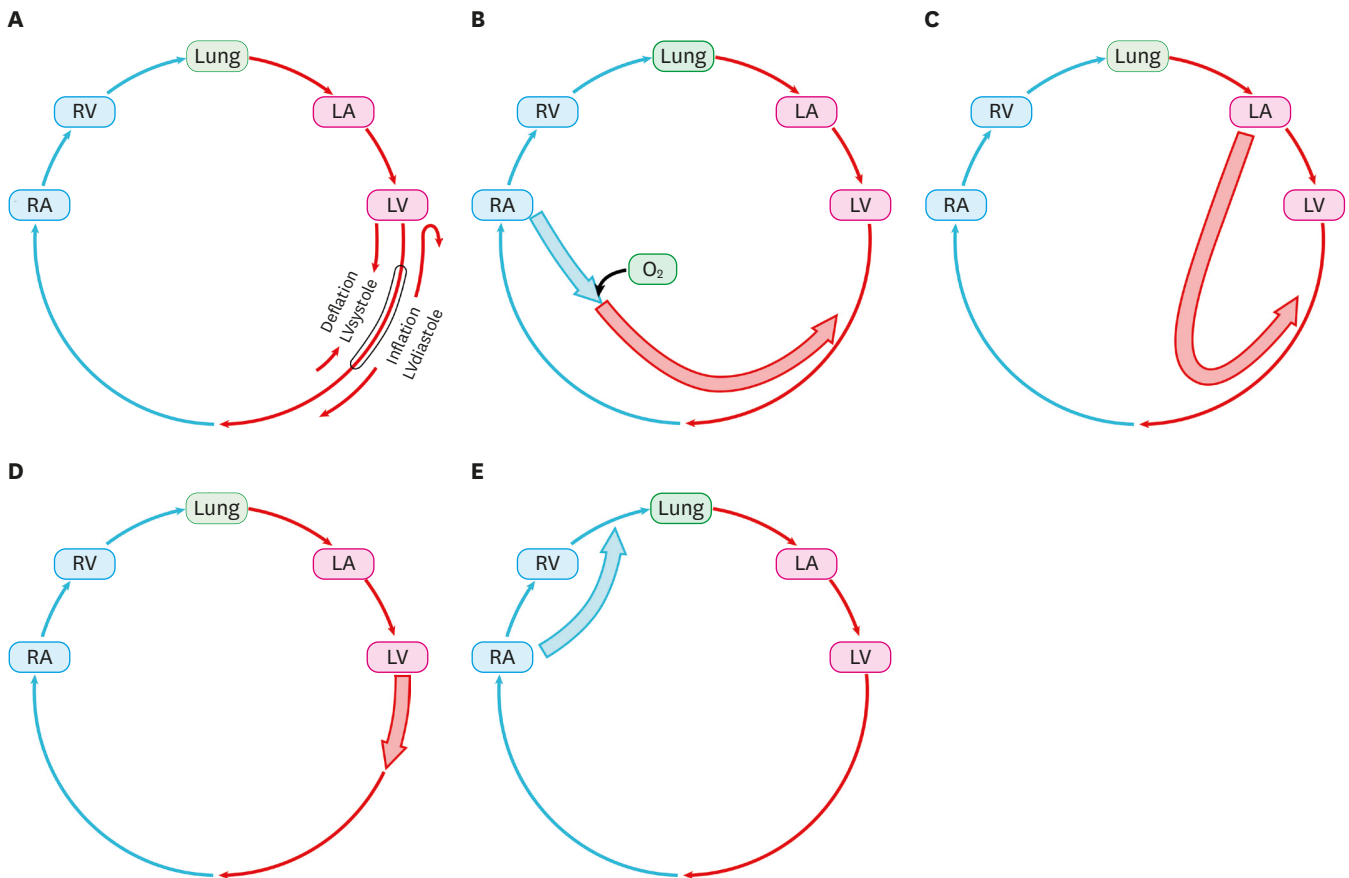


Figure 2. Mechanical circulatory support devices. (A) Intra-aortic balloon pump, (B) Venoarterial extracorporeal membrane oxygenation, (C) TandemHeart, (D) Impella 2.5/CP/5, and (E) Impella RP.

LA = left atrium; LV = left ventricular; RA = right atrium; RV = right ventricular.

left subclavian artery and visceral arteries, such as the superior mesenteric artery and renal arteries, should be avoided, and balloon positioning should be performed under fluoroscopy to avoid these potential complications. If the placement cannot be performed under fluoroscopy, immediate verification via a plain chest film is warranted. Serial monitoring of the left radial pulse and urine output can indicate IABP malposition.

Management

There are 2 modes for setting the balloon trigger, namely, electrocardiogram and pressure. Scenarios including early or late timing of inflation or deflation are undesirable. Early inflation or late deflation leads to increased afterload and increased myocardial oxygen demand. Late inflation or early deflation does not sufficiently increase coronary perfusion.

Complications

Complications include balloon rupture, bowel ischemia, and stroke.³²⁾

Contraindications

Contraindications to IABP placement include severe aortic insufficiency, aortic disease, and peripheral vascular disease.³²⁾ Unlike other MCS devices, an IABP needs synchronization with the ventricular cycle. Therefore, the implementation is restricted in case of cardiac arrest or severe tachy- or brady-arrhythmia.

Clinical outcomes and indications

In 2013, the American College of Cardiology and the American Heart Association recommended the use of an IABP in patients with CS after ST-elevation myocardial infarction who do not quickly stabilize with pharmacological therapy (IIa, B)¹⁹⁾; however, contrary results have been reported. IABP does not provide any survival benefit to high-risk patients with CS because it only provides modest hemodynamic support (0.5–0.8 L/min).³³⁾ In the intra-aortic balloon counterpulsation in patients with AMI complicated by CS (IABP-SHOCK I) trial, the use of IABP for hemodynamic stability was not beneficial.³⁴⁾ In addition, the IABP-SHOCK II trial concluded no mortality benefit of IABP compared to that of medical therapy.³⁵⁾ The results of the IABP-SHOCK II trial influenced the 2014 ESC guidelines with a further downgrading of IABP with a new class III (harm) recommendation for routine use in CS.³⁶⁾ The ESC still does not recommend the routine use of IABP in patients with CS (III, B).¹⁾²⁰⁾²¹⁾ The use of IABP support for patients with AMI-associated mechanical complication of acute mitral regurgitation or ventricular septal rupture remains a class II indication in the 2017 ESC guidelines.²⁰⁾

Some doctors do not include IABP in MCS devices because IABP is limited in its effect to reducing cardiac afterload and increasing coronary perfusion rather than increasing the systemic circulation. We suggest that the indication for the use of IABP should be limited to only those patients with AHF not complicated by CS.

Right atrial-to-aorta access device: extracorporeal membrane oxygenation

All ECMO cases described in this article used the venoarterial (VA) type of ECMO.

Mechanism

ECMO involves the withdrawal of deoxygenated blood from the venous system through a drainage cannula, pumping the blood through a membrane lung, and returning the blood to the arterial circulation through a return cannula.

Hemodynamic effects

ECMO does not directly decompress the left ventricle. As blood is pulled from the venous system, there is a decrease in the right ventricular (RV) preload and consequently the LV preload, which can reduce wall tension and workload. In contrast, as blood returns to the arterial system in a retrograde manner, there is an increase in the LV afterload and workload.²⁴⁾ Left ventricular end-diastolic pressure (LVEDP) may increase as the ECMO flow increases.³⁷⁾ Left ventricular end-diastolic volume (LVEDV) may increase or decrease depending on the balance between the decreased LV preload and remnant native LV contractility to overcome the increased LV afterload. Without satisfactory ejection, blood will accumulate under pressure until it eventually equalizes with systemic arterial pressure (**Figure 2B**).

Components and cannulation

The basic ECMO circuit includes cannulae for drainage and return, tubing, a pump, and a membrane lung. The cannulae can be placed either centrally or peripherally, but most ECMO is cannulated peripherally. Peripheral cannulation entails drainage of the venous blood from the right atrium (RA) through a cannula that exits through the femoral vein. The arterial cannula is a short cannula inserted into the femoral artery with the tip in the common iliac artery. It is relatively easy to place and can be inserted without fluoroscopy, making it an ideal device to support patients receiving ongoing CPR.⁴⁾

Management

A major advantage of ECMO is the relative ease of implementation; however, some disadvantages include the need for specialized perfusion expertise and skillful nursing care.³⁸⁾ The reason for specialized skill and expertise is because during ECMO, it is necessary to monitor the recovery of adequate systemic perfusion while maintaining sufficient ECMO flow and adequate BP.

- A. **Left ventricular distension:** As mentioned earlier, the LV will not eject if the systolic function is too poor to overcome the afterload. Without urgent correction, severe pulmonary edema will occur, followed by fatal pulmonary hemorrhage. If the left ventricle is distended despite the infusion of inotropes or vasodilators, the left heart must be physically decompressed.³⁹⁾⁴⁰⁾ The benefit of the simultaneous application of ECMO and the Impella device for unloading has been recently demonstrated in a multi-center retrospective cohort of 157 patients with profound refractory CS compared to patients treated with ECMO alone.⁴¹⁾ Another method to reduce the load is to decompress the left atrium (LA). If a multistage drainage cannula is available, we prefer inserting a single multistage drainage cannula over the interatrial septum.²⁴⁾⁴²⁾ This approach is referred to as LV-VA ECMO.⁴³⁾
- B. **Harlequin syndrome:** During ECMO, perfusate blood from ECMO mixes in the aorta with LV blood that has traversed the lungs. Therefore, the content of oxygen and carbon dioxide in the patient's arterial blood represents a combination of blood from these 2 sources. Thus, the total systemic blood flow is the sum of the extracorporeal flow plus the amount of blood passing through the heart and lungs (**Figure 3**).²⁴⁾⁴⁴⁾ Fully saturated blood from the ECMO circuit will meet the blood ejected from the native ventricle. The location of this mixing point, known as the watershed point, depends upon the amount of ECMO support provided and the degree of native cardiac output. If the myocardial dysfunction is severe, the mixing point will typically be in the proximal ascending aorta or the aortic root. As the myocardial function improves, the mixing point may migrate distally into the descending thoracic aorta. The oxygen content of blood ejected by the left ventricle depends on the gas exchange ability of the native lungs. If significant pulmonary edema is present, hypoxic blood may perfuse the proximal aortic branches, including the coronary arteries or aortic arch branches. The patient's upper body will appear blue, while the lower body will appear pink; this is the reason it is known as "Harlequin syndrome."³⁹⁾ The watershed point has been demonstrated in computed tomography or fluoroscopy images in several reports.⁴⁵⁻⁴⁸⁾ Therefore, measuring saturations in the right hand and analyzing arterial blood gases from the right arm are important.³⁹⁾
- C. **Anticoagulation:** There may be two sources of thrombi, namely, the native cardiopulmonary system and the extracorporeal circuit. The more dangerous site of thrombi is the native cardiopulmonary system because it may result in embolism to the coronary arteries or cerebral vessels. We recommend maintaining the hypocoagulable status during high-flow ECMO because native cardiopulmonary blood flow is slow or static (**Figure 4**).

Complications

Complications include bleeding, local vascular injury, limb ischemia, thromboembolism, LV distension, pulmonary edema, and air embolism.²⁴⁾⁴⁹⁾⁵⁰⁾

Contraindications

Contraindications for the placement of the ECMO circuit include severe aortic regurgitation (AR) and peripheral arterial occlusive disease.³²⁾

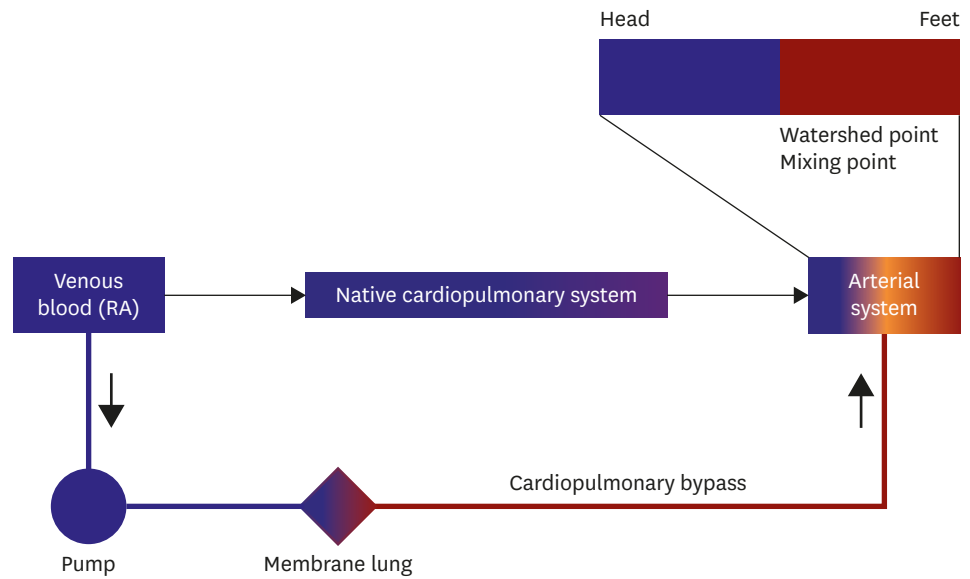


Figure 3. A simplified diagram showing the physiology of VA ECMO. Patients receiving VA ECMO often have lung failure caused by pulmonary edema due to left ventricular failure, combined pneumonia, and ventilation-perfusion mismatch. If the mixing point is distal to the aortic arch, patients are at risk for cerebral ischemia. Modified from published article of *Korean Circ J*.²⁴⁾ ECMO = extracorporeal membrane oxygenation; RA = right atrium; VA = venoarterial.

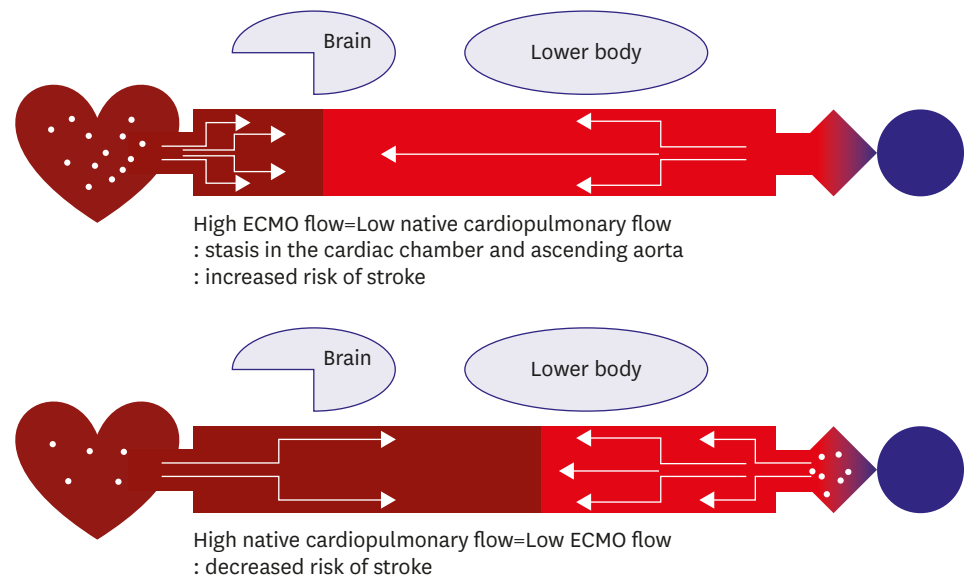


Figure 4. Simplified diagrams showing the interaction between a patient's cardiac output and VA ECMO flow. Embolic stroke is usually caused by thrombi in the native cardiac chambers rather than the extracorporeal circuit. Anticoagulation is more crucial when implementing high-flow than low-flow ECMO. Modified from published article of *Korean Circ J*.²⁴⁾ ECMO = extracorporeal membrane oxygenation; VA = venoarterial.

Clinical outcomes and indications

While the use of ECMO has increased in the USA from 2004–2014, the outcomes remain poor with an in-hospital mortality of 47% in 2014.⁵¹⁾ The usage trend of ECMO in Korea has also increased, and the in-hospital mortality was 63.4% between 2009 and 2014 (**Figure 1B**).⁵²⁾

Muller et al.⁵³⁾ assessed the clinical and quality of life outcomes of ECMO in 138 AMI patients with CS who did not require CPR. Based on multivariable logistic-regression analyses of data of this cohort of patients, the ENCOURAGE score to predict mortality in ECMO-treated AMI patients was calculated using the following pre-ECMO parameters: age >60 years, female sex, BMI >25 kg/m², Glasgow coma score <6, creatinine >150 µmol/L, lactate <2, 2–8 or >8 mmol/L, and prothrombin activity <50%. Six months after ECMO, the probabilities of survival were 80%, 58%, 25%, 20%, and 7% for ENCOURAGE score classes 0–12, 13–18, 19–22, 23–27, and at least 28, respectively.⁵³⁾

Combes et al.⁵⁴⁾ analyzed 65 patients receiving ECMO (72% of patients were cannulated percutaneously) for CS secondary to dilated cardiomyopathy, fulminant myocarditis, post-cardiotomy, post-transplantation, and other conditions; their in-hospital mortality was 58%.

Because it is less expensive than other devices, allows rapid improvement in oxygenation, and is the only short-term MCS suitable for patients with severe biventricular failure or cardiac arrest, ECMO has emerged as the first-line support system, with a growing number of accepted indications.⁵⁵⁾

The typical indications for the use of ECMO include the following:

- A. **Cardiogenic shock and cardiac arrest:** The best indication for the use of ECMO is CS. Common causes of CS are AMI, acute myocarditis, progression of cardiomyopathy, acute allograft rejection after heart transplantation, overdose of cardiotoxic drugs, refractory ventricular tachycardia, failure to wean off cardiopulmonary bypass, and cardiac failure coexistent with severe respiratory dysfunction. It is very important to start ECMO before cardiac arrest. The outcome of ECMO before cardiac arrest is much better than that of extracorporeal cardiopulmonary resuscitation (ECPR).⁵⁶⁾⁵⁷⁾ ECPR is the rapid implementation of ECMO to provide circulatory support in patients under cardiac arrest who fail to achieve a sustained return of spontaneous circulation.²⁹⁾ Two studies using propensity score matching demonstrated the neurological or survival benefits of ECPR over those of conventional CPR.⁵⁶⁾⁵⁸⁾ Previous reports have suggested that the duration of CPR before ECMO should be <30 minutes and not >60 minutes.⁵⁹⁻⁶¹⁾ Another important inclusion criterion for ECPR is witnessed arrest with bystander CPR initiation within 5 minutes.²⁹⁾⁶²⁾ The 2015 American Heart Association Guidelines recommend that in settings where it can be rapidly implemented, ECPR may be considered for selected patients under cardiac arrest for whom the suspected etiology of the cardiac arrest is potentially reversible during a limited period of ECMO use.⁶³⁾
- B. **Pulmonary thromboembolism:** ECMO is useful in patients with rapidly deteriorating vital signs such as cardiac arrest or refractory shock due to acute PTE, that is, massive PTE.⁶⁴⁻⁶⁸⁾ Moreover, if we consider ECMO's ability to offer partial cardiopulmonary bypass, it is the most suitable approach for the treatment of right heart failure due to PTE.²⁴⁾ The ESC 2014 acute PTE guidelines briefly mentioned that ECMO can be used to treat massive PTE as a method for hemodynamic support and as an adjunct to surgical thrombectomy.⁶⁹⁾ Because ECMO itself requires systemic anticoagulation, ECMO with or without catheter-directed thrombectomy may be used to treat acute PTE.⁷⁰⁾
- C. **Septic shock:** Sepsis has been historically regarded as a contraindication to ECMO,⁷¹⁾ and there are controversies surrounding the benefits of ECMO in septic shock.⁷²⁾ Favorable outcomes of ECMO in patients with septic shock combined with heart failure have been reported in recent years.⁷³⁻⁷⁶⁾ We suggest using ECMO only when there are significant signs of combined CS, such as high central venous pressure or pulmonary artery occlusion pressure.²⁹⁾

Left atrial-to-aorta access device: the TandemHeart device

Mechanism

The TandemHeart device (CardiacAssist Inc., Pittsburgh, PA, USA) is a support device that delivers blood from the LA to the arterial system using an extracorporeal centrifugal pump. The TandemHeart works in tandem with the left ventricle. Outflow from the TandemHeart device and left ventricle run in tandem, but toward each other.³⁰⁾

Hemodynamic effect

During the TandemHeart support, the LV preload decreases and the LV afterload increases (**Figure 2C**).

Components and cannulation

The TandemHeart system is composed of a drainage cannula, return cannula, centrifugal pump, and control console. The drainage cannula is placed from the femoral vein into the LA, whereas the return cannula is inserted retrogradely into the femoral artery. The placement of the drainage cannula requires a transseptal puncture. For an experienced operator, performing a transseptal puncture is a relatively safe procedure.

Management

The flow provided by the TandemHeart device is dependent on several factors, including the systemic and pulmonary resistance, cannula size and position, and fluid balance. Adequate RV function is required to maintain the left atrial volume.³⁰⁾ Continued hemodynamic monitoring, as well as the utility of a Swan-Ganz catheter, help to assess the total cardiac output and filling pressures. Vibration in the system's tubing may signal inadequate filling of the LA and should trigger an evaluation of the root cause, which may include hypovolemia, pulmonary hypertension, cardiac tamponade, bleeding, RV failure, or arrhythmias. Kinks in the tubing, cannula migration, and thrombus in the circuit should also be assessed. Rarely, the left atrial cannula can migrate into the RA, causing hemodynamic collapse and profound hypoxia.⁴⁾ If the pulmonary edema and hypoxemia complicating AHF is severe, it is possible to insert a membrane lung into the TandemHeart circuit, making it similar to ECMO.⁷⁷⁾

Adequate anticoagulation is important because the drainage cannula could form thrombi in the LA. The manufacturer of the TandemHeart device recommends using a heparinized purge solution. Unlike the Impella devices, the TandemHeart device purge solution is released at a fixed rate.⁷⁸⁾

Complications

Complications include bleeding, local vascular injury, limb ischemia, air embolism, thromboembolism, device dislodgement, arrhythmias, cardiac wall perforation, aortic root puncture, pericardial effusion or cardiac tamponade, stroke, and residual atrial septal defects.⁴⁾³⁰⁾³⁸⁾⁷⁹⁾

Contraindications

Contraindications include any condition that prohibits anticoagulation. In addition, the presence of a left atrial thrombus, ventricular septal defect, or aortic insufficiency precludes placement.⁴⁾³⁸⁾⁷⁹⁾

Clinical outcomes and indications

In an analysis of 117 patients with severe refractory CS, Kar et al.⁸⁰⁾ observed significant

improvements in the cardiac index, systolic BP, mixed venous oxygen saturation, and urine output with the use of TandemHeart support. Thirty-day and 6-month mortality rates were 40.2% and 45.3%, respectively, even though 47.9% patients underwent CPR immediately before or at the time of implantation.

Burkhoff et al.⁸¹⁾ randomized 33 patients within 24 hours of developing CS to treatment with an IABP or TandemHeart device. Compared with the IABP group, the TandemHeart group showed a greater increase in the cardiac index and mean arterial BP and a decrease in the pulmonary capillary wedge pressure; however, no difference in severe adverse events or 30-day mortality was observed between the 2 groups.

Alli et al.⁸²⁾ reported a series of 54 patients who received support of TandemHeart device while undergoing high-risk percutaneous coronary intervention (PCI). The procedural success was high at 97%, and the 6-month survival was 87%. However, major vascular complications occurred in 13% of patients.

Left ventricular-to-aorta access device: the Impella device

The Impella device (Abiomed Inc., Danvers, MA, USA) and HeartMate Percutaneous Heart Pump (Thoratec Corporation, Abbott Laboratories, Pleasanton, CA, USA) are current percutaneous ventricular assist devices (VADs). The Impella device that is described in this article is a left VAD, and a description of the Impella RP, which is a right VAD, is provided later.

Mechanism

The Impella is a percutaneous VAD that uses a microaxial pump to move blood continuously from the left ventricle to the ascending aorta. The device utilizes a constant axial flow, does not need electronic synchronization, and permits steady output regardless of arrhythmias.⁸³⁾

Hemodynamic effects

There are 2 primary effects of the Impella device, including (i) unloading of the ventricle (lower end-diastolic volume and pressure) and (ii) an increase in forward flow (higher mean arterial pressure) (**Figure 2D**). There is a reduction in LVEDP and LVEDV that translates into a decrease in the wall tension and myocardial oxygen demand.³⁸⁾⁷⁹⁾ The hemodynamic effect of the Impella device is similar to the effect of an IABP, however, the amount of circulatory support is considerably higher than that of IABP.

The Impella device effectively empties the left ventricle, lowers the end-diastolic pressure, and increases the peak coronary blood flow, resulting in an increased supply and decreased demand of myocardial oxygen.⁸⁴⁾

Components and catheterization or cannulation

There are three types of Impella devices that are available to provide increasing levels of LV support, namely, the Impella 2.5 (2.5 L/min; 12Fr motor pump), the Impella CP (approximately 3.5 L/min; 14Fr motor pump), and the Impella 5.0 (5.0 L/min; 21Fr motor pump). All three devices have been approved in the United States to provide hemodynamic support for up to 6 hours.

The Impella support system is comprised of 3 major components, namely, (i) a catheter, (ii) a purge system, and (iii) the automated controller. An impeller and its adjacent motor are located near the outlet area in the ascending aorta. As it rotates, negative pressure draws

Table 1. Characteristics of the 3 types of Impella devices

Variables	Impella 2.5	Impella CP	Impella 5.0
Access technique	Percutaneous	Percutaneous	Surgical
Access artery	femoral	femoral	axillary or femoral
Output (max)	2.5 L/min	4.0 L/min	5.0 L/min
Guiding catheter size	9F	9F	9F
Motor pump size	12F	14F	21F
Introducer size	13F peel away sheath	14F peel away sheath	10 mm Dacron graft

Modified from Burzotta et al.⁸⁵⁾

ventricular blood into the inlet area and through the cannula. The rotation speed of the impeller has nine settings (P0 to P8). To protect the motor, the purge fluid (5% dextrose with heparin) forms a hydraulic pressure shield that prevents blood from migrating past the impeller and into the motor housing.

Sizes of the catheters, motor pumps, and introducers and access methods for each type are presented in **Table 1**.⁸⁵⁾ The motor pump of the Impella 5.0 device (21F) requires an end-to-side anastomosis of the 10-mm Dacron graft to the femoral or axillary artery.³⁰⁾

Management

- A. Position monitoring: The automated Impella controller continuously monitors the catheter based on the placement signal wave and motor current wave. The placement signal wave is a pressure wave of the aorta or left ventricle. The motor current wave is a current wave. If the catheter needs to be repositioned, then fluoroscopic guidance is the best method. If the catheter is either partly (just the pigtail) or completely in the ventricle, the catheter can be pulled out under imaging guidance. If the catheter is completely in the aorta, pushing in the catheter across the valve should not be attempted without a guidewire. If the catheter is in the correct position, the pulse pressure of the placement signal is similar to the normal range of arterial pressure, and the motor current wave is pulsatile. However, when a patient has severe ventricular dysfunction, the pulse pressure of the placement signal will be low or dampened. In this situation, the automated Impella controller may not be able to determine the catheter position. In this case, the operator must rely on the patient's hemodynamic parameters and imaging to monitor the position.³⁰⁾
- B. Suction alarm: Suction may occur with the Impella device due to improper positioning or inadequate LV volume, and the presence of suction may lead to hemolysis.³⁰⁾ The Impella position should always be confirmed with imaging, and adjustments should be made to space the inlet from the ventricular wall. The device relies on a functional RV to provide LV filling. An inadequate LV volume may be secondary to overall volume depletion or poor RV function, leading to poor LV preload. During Impella support, the central venous pressure should be maintained between 8 and 12 mmHg to prevent suck-down events.⁸³⁾ Echocardiography or Swan-Ganz catheter-guided monitoring can help to assess the root cause of a suction alarm. It is paramount to recognize that a suction alarm at the initial placement of the catheter may signal the presence of an LV thrombus.
- C. Anticoagulation: There is a need for anticoagulation as there is a risk of systemic embolization. A unique aspect of the Impella system is the release of a dextrose-based purge solution from the motor housing that flows countercurrent to the discharge of blood from the outlet area. The resulting pressure barrier prevents the entry of blood into the motor housing, thereby reducing the risk of thrombus-related complications. The manufacturer also recommends adding heparin to the dextrose purge solution as soon as possible.⁷⁸⁾

Complications

Abaunza et al.⁸⁶⁾ reported acute limb ischemia in up to 13% of patients after they had inserted the Impella 2.5 or CP, which was related to emergency procedures. Other complications included bleeding at the vascular access site, which required transfusion in 24.2% of cases and vascular surgery in 4.2% of patients. Hemolysis resulting in blood transfusion was reported in 7.5% of patients. In 1.7% of patients, pericardial drainage was necessary because of cardiac tamponade. Device malfunction that necessitated the removal of the device occurred in 2.5% of patients during long-term support.⁸⁷⁾

Contraindications

The presence of a mechanical aortic valve or LV mural thrombi precludes the use of the Impella device, as does significant aortic valve stenosis. These clinical parameters do not prohibit the use of the TandemHeart device or ECMO.³⁰⁾ The use of the Impella device is also contraindicated in patients with moderate-to-severe AR, ventricular septal defect, and severe peripheral vascular disease.⁴⁾

Clinical outcomes and indications

An evidence-based efficacy study conducted in patients with CS showed that the Impella device can improve cardiac output and the cardiac index; however, no significant reduction in mortality was observed.⁸⁸⁾⁸⁹⁾ Seyfarth et al.⁹⁰⁾ randomly allocated 25 patients with AMI and CS to receive percutaneous support with either an IABP or the Impella 2.5 device and showed that the cardiac index after 30 min of support was greater with the use of the Impella. However, the overall 30-day mortality was 46% in both groups.

The PROTECT 2 trial was a randomized clinical trial that enrolled 452 patients who underwent high-risk PCI with the support of an IABP or the Impella 2.5 device. There was an increased number of 30-day major adverse events in the IABP group. At 90 days, a strong trend toward decreased major adverse events was observed in the Impella 2.5-supported patients compared with that in the IABP group. This trial was terminated at 69% of the planned enrollment for futility.⁹¹⁾

Mechanical right ventricular assist devices

For patients with RV failure complicated by CS, percutaneous RV MCS may be necessary. Diagnosing acute RV failure remains a major clinical challenge. Invasive hemodynamic measures can be obtained using a pulmonary artery (PA) catheter and are predictive of RV failure. The simplest approach to quantify RV dysfunction is to measure the ratio of RA pressure to pulmonary capillary wedge pressure.⁹²⁾ In the setting of AMI, Lopez-Sendon et al.⁹³⁾ identified that a ratio >0.86 was associated with pathological evidence of RV infarction at necropsy. Korabathina et al.⁹⁴⁾ reported the clinical utility of the PA pulsatility index (<1.0) as a measure of RV failure in the setting of AMI.

For a direct RV bypass, the Impella RP or TandemHeart using a Protek-Duo catheter (CardiacAssist Inc.) is appropriate. For an indirect RV bypass, ECMO support is suitable.⁴⁾

The Impella RP device

The Impella RP device is implanted into the femoral vein for inflow through the inferior vena cava to the outlet area in the PA. The Impella RP device is Food and Drug Administration approved for patients who develop acute right heart failure or decompensation after left VAD implantation, myocardial infarction, heart transplantation, or open-heart surgery (**Figure 2E**).

To achieve biventricular support, Pappalardo et al.⁹⁵⁾ reported the first case of biventricular support using 2 Impella pumps, that is, a combination of an Impella CP with an Impella RP system, for acute biventricular failure due to suspected acute myocarditis. This concept extends the possibilities of different unloading strategies for patients with biventricular failure in whom oxygenation is not a major issue.⁹⁶⁾ For example, for right heart failure due to massive PTE, even if the Impella CP and RP devices are supported at the same time, the blood of the main or proximal PA cannot be transmitted to the pulmonary veins through the thromboemboli in the pulmonary arteries. To date, the ECMO device is the only MCS device for massive PTE complicated by CS.

SELECTION OF MECHANICAL CIRCULATORY SUPPORT

Multiple factors must be considered when choosing MCS, including the hemodynamic condition of the patient; hemodynamic effects; indications or limitations of the devices; technical considerations, including ease and rapidity of insertion; and the ultimate goals of support.¹⁵⁾³⁸⁾⁹⁷⁾ Some considerations that we believe should be taken into account are as follows:

- Common contraindications for percutaneous MCS such as moderate-to-severe AR restricting of LV unloading and peripheral arterial occlusive disease precluding femoral cannulation or catheterization.³²⁾

In particular, for ECMO or the TandemHeart device, which requires insertion of a thicker cannula than a catheter used for the IABP or Impella, close monitoring of distal limb perfusion is important.
- Easy cannulation or catheterization: IABP > ECMO > Impella > TandemHeart
 - i. Fluoroscopy is inevitable for the implantation of the Impella or TandemHeart device, but the IABP or ECMO device can be implanted at the bedside.
 - ii. The practical reason why ECMO is only applicable in cardiac arrest is not only because it can support both ventricles as described earlier but also because it can be cannulated at the bedside without fluoroscopy support.
- Need for anticoagulation: Impella = TandemHeart > IABP > ECMO
 - i. Although all MCS devices require anticoagulation by default, especially for the TandemHeart and Impella devices, stricter anticoagulation is needed because of the high-risk of critical systemic embolization.
 - ii. In the case of ECMO, the blood contact surface of the component in the arterial system is the smallest, and the membrane lung has the effect of blocking embolism from the centrifugal pump or the membrane lung itself. However, anticoagulation is important to prevent intracardiac thrombus formation and systemic embolization, especially if LV contractility is poor (**Figure 4**).²⁴⁾
- Duration of support: TandemHeart > ECMO > Impella
- LV unloading: TandemHeart ≥ Impella > ECMO > IABP
- RV unloading: Impella RP or TandemHeart using a Protek-Duo catheter ≥ ECMO
 - i. It is possible to determine which MCS devices will be implemented depending on the degree of LV unloading of each device and whether RV failure is accompanied by LV failure.
 - ii. The Impella and TandemHeart devices can be used if only LV dysfunction is present, and

- RV function is normal or tolerable. Inotropes are often required to support RV function after the placement of left-side support devices.³⁸⁾
- iii. ECMO can be used if there is LV or RV dysfunction because most cardiac chambers and lungs are bypassed (**Figure 2B**). In particular, biventricular failure after cardiac arrest, severe pulmonary edema complicating cardiogenic shock, or massive PTE complicated by shock are exclusive indications for ECMO. However, because the direct LV loading effect is low, there is a risk of LV distension when severe LV dysfunction is present.
 - iv. Because the amount of LV unloading and systemic circulatory support of the IABP is the lowest, it is only recommended to be implanted in cases of AHF with pre-shock or early shock.
 - v. A closer look at **Figure 2** shows that MCS devices, except for the IABP, basically act as bypasses. Thus, if the function of any cardiac chamber or lung is decreased, an MCS device that can bypass the impaired section can be selected.

The algorithm for MCS selection is presented in **Figure 5**, reflecting the various factors above.

FUTURE DIRECTIONS

Technological developments are ongoing and include simpler and faster cannulation or catheterization, less anticoagulation, more ventricular unloading effect, and easier management with less complications.

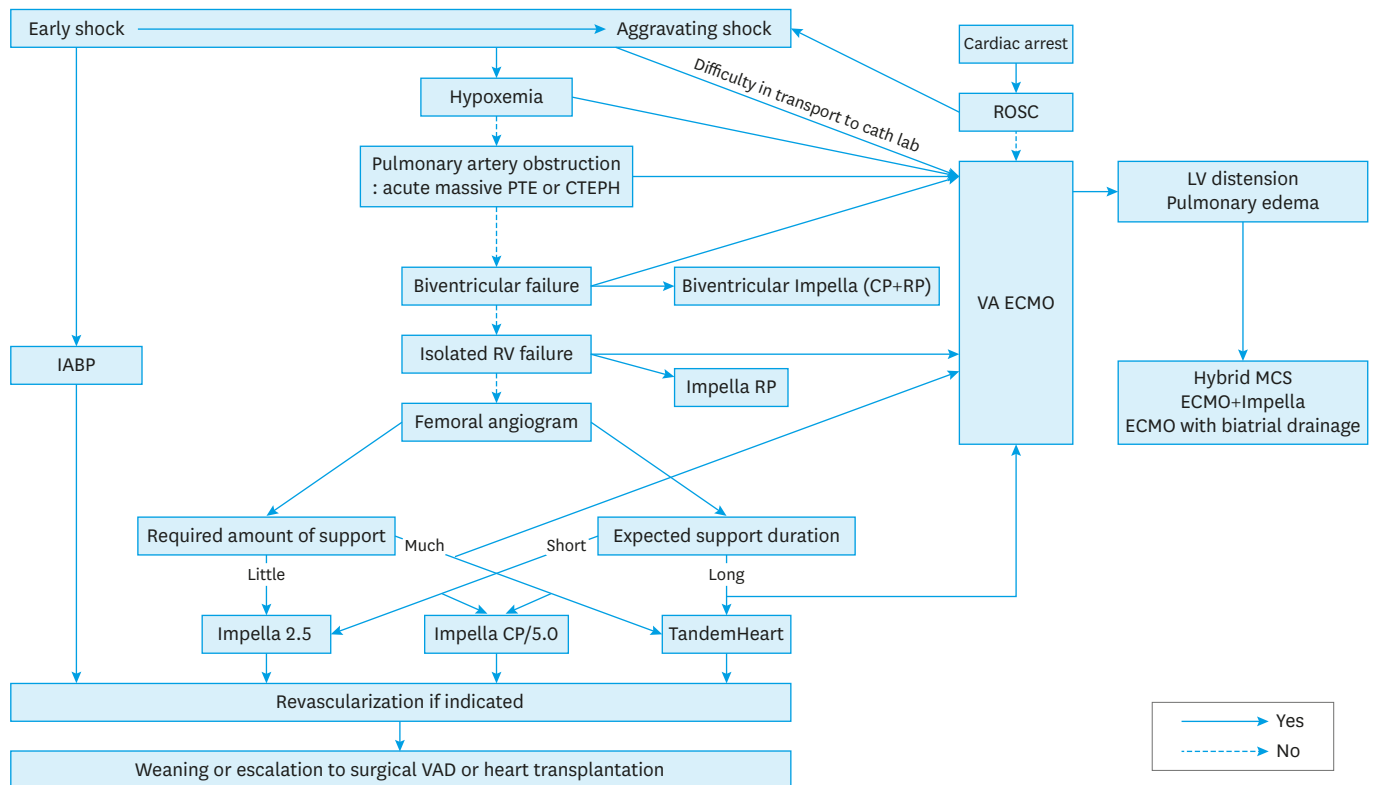


Figure 5. Algorithm for mechanical circulatory support device selection in patients with cardiogenic shock and cardiac arrest complicating acute heart failure. Modified from Atkinson et al.³⁹⁾ and Chakravarthy et al.⁴⁾

CTEPH = chronic thromboembolic pulmonary hypertension; ECMO = extracorporeal membrane oxygenation; IABP = intra-aortic balloon pump; LV = left ventricular; MCS = mechanical circulatory support; PTE = pulmonary thromboembolism; RAVD = right ventricular assist device; ROSC = return of spontaneous circulation; RV = right ventricular; VA = venoarterial; VAD = ventricular assist device.

There are multiple open questions regarding MCS devices, as reflected by the high number of recommendations with a level of evidence C (limited data or expert opinion) in current guidelines.¹⁹⁾⁽³⁶⁾⁽⁹⁸⁾ Moreover, randomized clinical trials on CS are difficult to perform, and only a few randomized clinical trials came to clinical outcomes with completion of the required patient number.¹⁶⁾⁽¹⁷⁾ This should be the motivation for future randomized clinical trials involving MCS devices.

CONCLUSIONS

MCS for patients with AHF complicated by CS has been increasing in popularity. Proper device selection with appropriate timing of application is important. Considering that various factors are involved in the complexity of decision making, the hospital should have its own standardized approach to patients with AHF complicated by CS.

ACKNOWLEDGMENTS

We would like to thank Editage (www.editage.co.kr) for English language editing.

REFERENCES

1. Ponikowski P, Voors AA, Anker SD, et al. 2016 ESC Guidelines for the diagnosis and treatment of acute and chronic heart failure: the Task Force for the diagnosis and treatment of acute and chronic heart failure of the European Society of Cardiology (ESC) Developed with the special contribution of the Heart Failure Association (HFA) of the ESC. *Eur Heart J* 2016;37:2129-200.
[PUBMED](#) | [CROSSREF](#)
2. Vincent JL, De Backer D. Circulatory shock. *N Engl J Med* 2013;369:1726-34.
[PUBMED](#) | [CROSSREF](#)
3. Hochman JS, Buller CE, Sleeper LA, et al. Cardiogenic shock complicating acute myocardial infarction--etiologies, management and outcome: a report from the SHOCK Trial Registry. Should we emergently revascularize Occluded Coronaries for cardiogenic shock? *J Am Coll Cardiol* 2000;36:1063-70.
[PUBMED](#) | [CROSSREF](#)
4. Chakravarthy M, Tsukashita M, Murali S. A targeted management approach to cardiogenic shock. *Crit Care Clin* 2018;34:423-37.
[PUBMED](#) | [CROSSREF](#)
5. Thiele H, Ohman EM, Desch S, Eitel I, de Waha S. Management of cardiogenic shock. *Eur Heart J* 2015;36:1223-30.
[PUBMED](#) | [CROSSREF](#)
6. Hashmi KA, Abbas K, Hashmi AA, et al. In-hospital mortality of patients with cardiogenic shock after acute myocardial infarction; impact of early revascularization. *BMC Res Notes* 2018;11:721.
[PUBMED](#) | [CROSSREF](#)
7. Kolte D, Khera S, Aronow WS, et al. Trends in incidence, management, and outcomes of cardiogenic shock complicating ST-elevation myocardial infarction in the United States. *J Am Heart Assoc* 2014;3:e000590.
[PUBMED](#) | [CROSSREF](#)
8. Reynolds HR, Hochman JS. Cardiogenic shock: current concepts and improving outcomes. *Circulation* 2008;117:686-97.
[PUBMED](#) | [CROSSREF](#)
9. Thompson KA, Philip KJ, Simsir S, Schwarz ER. The new concept of "interventional heart failure therapy": part 2--inotropes, valvular disease, pumps, and transplantation. *J Cardiovasc Pharmacol Ther* 2010;15:231-43.
[PUBMED](#) | [CROSSREF](#)

10. De Backer D, Biston P, Devriendt J, et al. Comparison of dopamine and norepinephrine in the treatment of shock. *N Engl J Med* 2010;362:779-89.
[PUBMED](#) | [CROSSREF](#)
11. Tamargo J, Caballero R, Gómez R, Barana A, Amorós I, Delpón E. Investigational positive inotropic agents for acute heart failure. *Cardiovasc Hematol Disord Drug Targets* 2009;9:193-205.
[PUBMED](#) | [CROSSREF](#)
12. Burkhoff D, Naidu SS. The science behind percutaneous hemodynamic support: a review and comparison of support strategies. *Catheter Cardiovasc Interv* 2012;80:816-29.
[PUBMED](#) | [CROSSREF](#)
13. Kapur NK, Dimas V, Sorajja P, et al. The Interventional Heart Failure Initiative: a mission statement for the next generation of invasive cardiologists. *Catheter Cardiovasc Interv* 2015;86:353-5.
[PUBMED](#) | [CROSSREF](#)
14. Shekar K, Gregory SD, Fraser JF. Mechanical circulatory support in the new era: an overview. *Crit Care* 2016;20:66.
[PUBMED](#) | [CROSSREF](#)
15. Chera HH, Nagar M, Chang NL, et al. Overview of Impella and mechanical devices in cardiogenic shock. *Expert Rev Med Devices* 2018;15:293-9.
[PUBMED](#) | [CROSSREF](#)
16. Hochman JS, Sleeper LA, Webb JG, et al. Early revascularization in acute myocardial infarction complicated by cardiogenic shock. SHOCK Investigators. Should We Emergently Revascularize Occluded Coronaries for Cardiogenic Shock. *N Engl J Med* 1999;341:625-34.
[PUBMED](#) | [CROSSREF](#)
17. Thiele H, Zeymer U, Neumann FJ, et al. Intraaortic balloon support for myocardial infarction with cardiogenic shock. *N Engl J Med* 2012;367:1287-96.
[PUBMED](#) | [CROSSREF](#)
18. Thiele H, Akin I, Sandri M, et al. PCI strategies in patients with acute myocardial infarction and cardiogenic shock. *N Engl J Med* 2017;377:2419-32.
[PUBMED](#) | [CROSSREF](#)
19. O'Gara PT, Kushner FG, Ascheim DD, et al. 2013 ACCF/AHA guideline for the management of ST-elevation myocardial infarction: a report of the American College of Cardiology Foundation/American Heart Association Task Force on Practice Guidelines. *Circulation* 2013;127:e362-425.
[PUBMED](#) | [CROSSREF](#)
20. Ibanez B, James S, Agewall S, et al. 2017 ESC Guidelines for the management of acute myocardial infarction in patients presenting with ST-segment elevation: The Task Force for the management of acute myocardial infarction in patients presenting with ST-segment elevation of the European Society of Cardiology (ESC). *Eur Heart J* 2018;39:119-77.
[PUBMED](#) | [CROSSREF](#)
21. Neumann FJ, Sousa-Uva M, Ahlsson A, et al. 2018 ESC/EACTS Guidelines on myocardial revascularization. *Eur Heart J* 2019;40:87-165.
[PUBMED](#) | [CROSSREF](#)
22. Esposito ML, Kapur NK. Acute mechanical circulatory support for cardiogenic shock: the "door to support" time. *F1000 Res* 2017;6:737.
[PUBMED](#) | [CROSSREF](#)
23. Basir MB, Schreiber TL, Grines CL, et al. Effect of early initiation of mechanical circulatory support on survival in cardiogenic shock. *Am J Cardiol* 2017;119:845-51.
[PUBMED](#) | [CROSSREF](#)
24. Choi MS, Sung K, Cho YH. Clinical pearls of venoarterial extracorporeal membrane oxygenation for cardiogenic shock. *Korean Circ J* 2019;49:657-77.
[PUBMED](#) | [CROSSREF](#)
25. O'Neill WW, Schreiber T, Wohns DH, et al. The current use of Impella 2.5 in acute myocardial infarction complicated by cardiogenic shock: results from the USpella Registry. *J Interv Cardiol* 2014;27:1-11.
[PUBMED](#) | [CROSSREF](#)
26. Meraj PM, Doshi R, Schreiber T, Maini B, O'Neill WW. Impella 2.5 initiated prior to unprotected left main PCI in acute myocardial infarction complicated by cardiogenic shock improves early survival. *J Interv Cardiol* 2017;30:256-63.
[PUBMED](#) | [CROSSREF](#)
27. Briasoulis A, Telila T, Palla M, et al. Meta-analysis of usefulness of percutaneous left ventricular assist devices for high-risk percutaneous coronary interventions. *Am J Cardiol* 2016;118:369-75.
[PUBMED](#) | [CROSSREF](#)

28. Loehn T, O'Neill WW, Lange B, et al. Long term survival after early unloading with Impella CP® in acute myocardial infarction complicated by cardiogenic shock. *Eur Heart J Acute Cardiovasc Care*. 2018 [Epub ahead of print].
[PUBMED](#) | [CROSSREF](#)
29. Guglin M, Zucker MJ, Bazan VM, et al. Venoarterial ECMO for adults: JACC Scientific Expert Panel. *J Am Coll Cardiol* 2019;73:698-716.
[PUBMED](#) | [CROSSREF](#)
30. Sodhi N, Lasala JM. Mechanical circulatory support in acute decompensated heart failure and shock. *Interv Cardiol Clin* 2017;6:387-405.
[PUBMED](#) | [CROSSREF](#)
31. Kim JT, Lee JR, Kim JK, et al. The carina as a useful radiographic landmark for positioning the intraaortic balloon pump. *Anesth Analg* 2007;105:735-8.
[PUBMED](#) | [CROSSREF](#)
32. Atkinson TM, Ohman EM, O'Neill WW, Rab T, Cigarroa JE; Interventional Scientific Council of the American College of Cardiology. A practical approach to mechanical circulatory support in patients undergoing percutaneous coronary intervention: an interventional perspective. *JACC Cardiovasc Interv* 2016;9:871-83.
[PUBMED](#) | [CROSSREF](#)
33. Perera D, Stables R, Thomas M, et al. Elective intra-aortic balloon counterpulsation during high-risk percutaneous coronary intervention: a randomized controlled trial. *JAMA* 2010;304:867-74.
[PUBMED](#) | [CROSSREF](#)
34. Prondzinsky R, Unverzagt S, Russ M, et al. Hemodynamic effects of intra-aortic balloon counterpulsation in patients with acute myocardial infarction complicated by cardiogenic shock: the prospective, randomized IABP shock trial. *Shock* 2012;37:378-84.
[PUBMED](#) | [CROSSREF](#)
35. Thiele H, Zeymer U, Neumann FJ, et al. Intra-aortic balloon counterpulsation in acute myocardial infarction complicated by cardiogenic shock (IABP-SHOCK II): final 12 month results of a randomised, open-label trial. *Lancet* 2013;382:1638-45.
[PUBMED](#) | [CROSSREF](#)
36. Authors/Task Force members, Windecker S, Kolh P, et al. 2014 ESC/EACTS Guidelines on myocardial revascularization: the Task Force on Myocardial Revascularization of the European Society of Cardiology (ESC) and the European Association for Cardio-Thoracic Surgery (EACTS) Developed with the special contribution of the European Association of Percutaneous Cardiovascular Interventions (EAPCI). *Eur Heart J* 2014;35:2541-619.
[PUBMED](#) | [CROSSREF](#)
37. Burkhoff D, Sayer G, Doshi D, Uriel N. Hemodynamics of mechanical circulatory support. *J Am Coll Cardiol* 2015;66:2663-74.
[PUBMED](#) | [CROSSREF](#)
38. Rihal CS, Naidu SS, Givertz MM, et al. 2015 SCAI/ACC/HFSA/STS clinical expert consensus Statement on the use of percutaneous mechanical circulatory support devices in cardiovascular care: endorsed by the American Heart Association, the Cardiological Society of India, and Sociedad Latino Americana de Cardiologia Intervencion; Affirmation of Value by the Canadian Association of Interventional Cardiology-Association Canadienne de Cardiologie d'intervention. *J Am Coll Cardiol* 2015;65:e7-26.
[PUBMED](#) | [CROSSREF](#)
39. Haft JW, Firmin R. Adult cardiac support. In: Annich GM, Lynch WR, MacLaren G, Wilson JM, Bartlett RH, editors. *ECMO: Extracorporeal Cardiopulmonary Support in Critical Care*. 4th ed. Ann Arbor (MI): Extracorporeal Life Support Organization; 2012. p.323-30.
40. Wozniak CJ, Stehlik J, Baird BC, et al. Ventricular assist devices or inotropic agents in status 1A patients? Survival analysis of the United Network of Organ Sharing database. *Ann Thorac Surg* 2014;97:1364-71.
[PUBMED](#) | [CROSSREF](#)
41. Vallabhajosyula S, O'Horo JC, Antharam P, et al. Concomitant intra-aortic balloon pump use in cardiogenic shock requiring veno-arterial extracorporeal membrane oxygenation. *Circ Cardiovasc Interv* 2018;11:e006930.
[PUBMED](#) | [CROSSREF](#)
42. Na SJ, Yang JH, Yang JH, et al. Left heart decompression at venoarterial extracorporeal membrane oxygenation initiation in cardiogenic shock: prophylactic versus therapeutic strategy. *J Thorac Dis* 2019;11:3746-56.
[PUBMED](#) | [CROSSREF](#)

43. Dulnuan K, Guglin M, Zwischenberger J, Gurley J. Left atrial veno-arterial extracorporeal membrane oxygenation: percutaneous bi-atrial drainage to avoid pulmonary edema in patients with left ventricular systolic dysfunction. *J Am Coll Cardiol* 2018;71:A1358.
[CROSSREF](#)
44. Bartlett RH, Conrad SA. The physiology of extracorporeal life support. In: Brogan TV, Lequier L, Lorusso R, MacLaren G, Peek G, editors. *Extracorporeal Life Support: The ELSO Red Book*. 5th ed. Ann Arbor (MI): Extracorporeal Life Support Organization; 2017. p.31-47.
45. Batista PM, Cavarocchi NC, Hirose H. Extracorporeal membranous oxygenation mimics aortic dissection on CAT scan. *Ann Thorac Surg* 2013;95:357.
[PUBMED](#) | [CROSSREF](#)
46. Goslar T, Stankovic M, Ksela J. Contrast layering artefact mimicking aortic dissection in a patient on veno-arterial extracorporeal membrane oxygenation undergoing computed tomography scan. *Interact Cardiovasc Thorac Surg* 2016;22:507-9.
[PUBMED](#) | [CROSSREF](#)
47. Sirol M, Sideris G, Deye N, Henry P, Baud F, Soyer P. A bizarre aortic dissection. *Ann Thorac Surg* 2012;93:2070.
[PUBMED](#) | [CROSSREF](#)
48. Auzinger G, Best T, Vercueil A, Willars C, Wendon JA, Desai SR. Computed tomographic imaging in peripheral VA-ECMO: where has all the contrast gone? *J Cardiothorac Vasc Anesth* 2014;28:1307-9.
[PUBMED](#) | [CROSSREF](#)
49. Yang F, Hou D, Wang J, et al. Vascular complications in adult postcardiotomy cardiogenic shock patients receiving venoarterial extracorporeal membrane oxygenation. *Ann Intensive Care* 2018;8:72.
[PUBMED](#) | [CROSSREF](#)
50. Aziz F, Brehm CE, El-Banyosy A, Han DC, Atnip RG, Reed AB. Arterial complications in patients undergoing extracorporeal membrane oxygenation via femoral cannulation. *Ann Vasc Surg* 2014;28:178-83.
[PUBMED](#) | [CROSSREF](#)
51. Mandawat A, Rao SV. Percutaneous mechanical circulatory support devices in cardiogenic shock. *Circ Cardiovasc Interv* 2017;10:e004337.
[PUBMED](#) | [CROSSREF](#)
52. Tay CK, Cho YH, Park J, et al. Extracorporeal membrane oxygenation in Korea - Trends and impact of hospital volume on outcome: analysis of national insurance data 2009-2014. *J Crit Care* 2019;49:1-6.
[PUBMED](#) | [CROSSREF](#)
53. Muller G, Flecher E, Lebreton G, et al. The ENCOURAGE mortality risk score and analysis of long-term outcomes after VA-ECMO for acute myocardial infarction with cardiogenic shock. *Intensive Care Med* 2016;42:370-8.
[PUBMED](#) | [CROSSREF](#)
54. Combes A, Leprince P, Luyt CE, et al. Outcomes and long-term quality-of-life of patients supported by extracorporeal membrane oxygenation for refractory cardiogenic shock. *Crit Care Med* 2008;36:1404-11.
[PUBMED](#) | [CROSSREF](#)
55. Pineton de Chambrun M, Bréchet N, Combes A. Mechanical circulatory devices in acute heart failure. *Curr Opin Crit Care* 2018;24:286-91.
[PUBMED](#) | [CROSSREF](#)
56. Shin TG, Choi JH, Jo IJ, et al. Extracorporeal cardiopulmonary resuscitation in patients with in-hospital cardiac arrest: a comparison with conventional cardiopulmonary resuscitation. *Crit Care Med* 2011;39:17.
[PUBMED](#) | [CROSSREF](#)
57. Ouweneel DM, Schotborgh JV, Limpens J, et al. Extracorporeal life support during cardiac arrest and cardiogenic shock: a systematic review and meta-analysis. *Intensive Care Med* 2016;42:1922-34.
[PUBMED](#) | [CROSSREF](#)
58. Chen YS, Lin JW, Yu HY, et al. Cardiopulmonary resuscitation with assisted extracorporeal life-support versus conventional cardiopulmonary resuscitation in adults with in-hospital cardiac arrest: an observational study and propensity analysis. *Lancet* 2008;372:554-61.
[PUBMED](#) | [CROSSREF](#)
59. Huang SC, Wu ET, Chen YS, et al. Extracorporeal membrane oxygenation rescue for cardiopulmonary resuscitation in pediatric patients. *Crit Care Med* 2008;36:1607-13.
[PUBMED](#) | [CROSSREF](#)
60. Prodhon P, Fiser RT, Dyamenahalli U, et al. Outcomes after extracorporeal cardiopulmonary resuscitation (ECPR) following refractory pediatric cardiac arrest in the intensive care unit. *Resuscitation* 2009;80:1124-9.
[PUBMED](#) | [CROSSREF](#)

61. Sivarajan VB, Best D, Brizard CP, Shekerdemian LS, d'Udekem Y, Butt W. Duration of resuscitation prior to rescue extracorporeal membrane oxygenation impacts outcome in children with heart disease. *Intensive Care Med* 2011;37:853-60.
[PUBMED](#) | [CROSSREF](#)
62. Jaski BE, Ortiz B, Alla KR, et al. A 20-year experience with urgent percutaneous cardiopulmonary bypass for salvage of potential survivors of refractory cardiovascular collapse. *J Thorac Cardiovasc Surg* 2010;139:753-757.e1-2.
[PUBMED](#) | [CROSSREF](#)
63. Link MS, Berkow LC, Kudenchuk PJ, et al. Part 7: adult advanced cardiovascular life support: 2015 American Heart Association guidelines update for cardiopulmonary resuscitation and emergency cardiovascular care. *Circulation* 2015;132:S444-64.
[PUBMED](#) | [CROSSREF](#)
64. Šimek M, Hutyra M, Gwozdziwicz M, Fluger I, Steriovský A, Konečný J. The role of surgical embolectomy and extracorporeal membrane oxygen therapy in the treatment of massive pulmonary embolism - a review. *Rozhl Chir* 2015;94:103-10.
[PUBMED](#)
65. Watanabe Y, Sakakura K, Akashi N, et al. Veno-arterial extracorporeal membrane oxygenation with conventional anticoagulation can be a best solution for shock due to massive PE. *Int Heart J* 2017;58:831-4.
[PUBMED](#) | [CROSSREF](#)
66. Cho YH, Kim WS, Sung K, et al. Management of cardiac arrest caused by acute massive pulmonary thromboembolism: importance of percutaneous cardiopulmonary support. *ASAIO J* 2014;60:280-3.
[PUBMED](#) | [CROSSREF](#)
67. Swol J, Buchwald D, Ewers A, Schildhauer TA. Arteriovenous extracorporeal membrane oxygenation (ECMO). A therapeutic option for fulminant pulmonary embolism. *Med Klin Intensivmed Notf Med* 2013;108:63-8.
[PUBMED](#) | [CROSSREF](#)
68. Yusuff HO, Zochios V, Vuylsteke A. Extracorporeal membrane oxygenation in acute massive pulmonary embolism: a systematic review. *Perfusion* 2015;30:611-6.
[PUBMED](#) | [CROSSREF](#)
69. Konstantinides SV. 2014 ESC Guidelines on the diagnosis and management of acute pulmonary embolism. *Eur Heart J* 2014;35:3145-6.
[PUBMED](#) | [CROSSREF](#)
70. Lauren Lindsey J, Jain R, Vachharajani V. Catheter directed thrombolysis combined with ECMO for massive pulmonary emboli. *Respir Med Case Rep* 2018;25:6-8.
[PUBMED](#) | [CROSSREF](#)
71. Fortenberry JD, Lorusso R. The history and development of extracorporeal support. In: Brogan TV, Lequier L, Lorusso R, MacLaren G, Peek G, editors. *Extracorporeal Life Support: The ELSO Red Book*. 5th ed. Ann Arbor (MI): Extracorporeal Life Support Organization; 2017. p.1-15.
72. Chvojka J, Martinkova V, Benes J, et al. Mechanical circulatory support in refractory vasodilatory septic shock: a randomized controlled porcine study. *Shock* 2020;53:124-31.
[PUBMED](#) | [CROSSREF](#)
73. Perdue SM, Poore BJ, Babu AN, Stribling WK. Successful use of extracorporeal membrane oxygenation support in severe septic shock with associated acute cardiomyopathy. *J Card Surg* 2018;33:50-2.
[PUBMED](#) | [CROSSREF](#)
74. Asaki M, Masuda T, Miki Y. Veno-arterial extracorporeal membrane oxygenation for septic cardiomyopathy due to *Legionella* pneumonia after influenza virus infection. *Case Rep Crit Care* 2018;2018:6973197.
[PUBMED](#) | [CROSSREF](#)
75. Liu C, Zhu R, Zhou Z, et al. Sepsis-induced cardiomyopathy complicated with cardiogenic shock patients supported with extracorporeal membrane oxygenation. *Zhonghua Wei Zhong Bing Ji Jiu Yi Xue* 2017;29:1140-3.
[PUBMED](#) | [CROSSREF](#)
76. Lees NJ, Rosenberg A, Hurtado-Doce AI, et al. Combination of ECMO and cytokine adsorption therapy for severe sepsis with cardiogenic shock and ARDS due to Pantone-Valentine leukocidin-positive *Staphylococcus aureus* pneumonia and H1N1. *J Artif Organs* 2016;19:399-402.
[PUBMED](#) | [CROSSREF](#)
77. Li YW, Rosenblum WD, Gass AL, Weiss MB, Aronow WS. Combination use of a TandemHeart with an extracorporeal oxygenator in the treatment of five patients with refractory cardiogenic shock after acute myocardial infarction. *Am J Ther* 2013;20:213-8.
[PUBMED](#) | [CROSSREF](#)

78. Allender JE, Reed BN, Foster JL, et al. Pharmacologic considerations in the management of patients receiving left ventricular percutaneous mechanical circulatory support. *Pharmacotherapy* 2017;37:1272-83.
[PUBMED](#) | [CROSSREF](#)
79. Naidu SS. Novel percutaneous cardiac assist devices: the science of and indications for hemodynamic support. *Circulation* 2011;123:533-43.
[PUBMED](#) | [CROSSREF](#)
80. Kar B, Gregoric ID, Basra SS, Idelchik GM, Loyalka P. The percutaneous ventricular assist device in severe refractory cardiogenic shock. *J Am Coll Cardiol* 2011;57:688-96.
[PUBMED](#) | [CROSSREF](#)
81. Burkhoff D, Cohen H, Brunckhorst C, O'Neill WW; TandemHeart Investigators Group. A randomized multicenter clinical study to evaluate the safety and efficacy of the TandemHeart percutaneous ventricular assist device versus conventional therapy with intraaortic balloon pumping for treatment of cardiogenic shock. *Am Heart J* 2006;152:469.e1-8.
[PUBMED](#) | [CROSSREF](#)
82. Alli OO, Singh IM, Holmes DR Jr, Pulido JN, Park SJ, Rihal CS. Percutaneous left ventricular assist device with TandemHeart for high-risk percutaneous coronary intervention: the Mayo Clinic experience. *Catheter Cardiovasc Interv* 2012;80:728-34.
[PUBMED](#) | [CROSSREF](#)
83. Lawson WE, Koo M. Percutaneous ventricular assist devices and ECMO in the management of acute decompensated heart failure. *Clin Med Insights Cardiol* 2015;9:41-8.
[PUBMED](#) | [CROSSREF](#)
84. Sauren LD, Accord RE, Hamzeh K, et al. Combined Impella and intra-aortic balloon pump support to improve both ventricular unloading and coronary blood flow for myocardial recovery: an experimental study. *Artif Organs* 2007;31:839-42.
[PUBMED](#) | [CROSSREF](#)
85. Burzotta F, Trani C, Doshi SN, et al. Impella ventricular support in clinical practice: collaborative viewpoint from a European expert user group. *Int J Cardiol* 2015;201:684-91.
[PUBMED](#) | [CROSSREF](#)
86. Abaunza M, Kabbani LS, Nypaver T, et al. Incidence and prognosis of vascular complications after percutaneous placement of left ventricular assist device. *J Vasc Surg* 2015;62:417-23.
[PUBMED](#) | [CROSSREF](#)
87. Lauten A, Engström AE, Jung C, et al. Percutaneous left-ventricular support with the Impella-2.5-assist device in acute cardiogenic shock: results of the Impella-EUROSHOCK-registry. *Circ Heart Fail* 2013;6:23-30.
[PUBMED](#) | [CROSSREF](#)
88. Ergle K, Parto P, Krim SR. Percutaneous ventricular assist devices: a novel approach in the management of patients with acute cardiogenic shock. *Ochsner J* 2016;16:243-9.
[PUBMED](#)
89. Nalluri N, Patel N, Saouma S, et al. Utilization of the Impella for hemodynamic support during percutaneous intervention and cardiogenic shock: an insight. *Expert Rev Med Devices* 2017;14:789-804.
[PUBMED](#) | [CROSSREF](#)
90. Seyfarth M, Sibbing D, Bauer I, et al. A randomized clinical trial to evaluate the safety and efficacy of a percutaneous left ventricular assist device versus intra-aortic balloon pumping for treatment of cardiogenic shock caused by myocardial infarction. *J Am Coll Cardiol* 2008;52:1584-8.
[PUBMED](#) | [CROSSREF](#)
91. O'Neill WW, Kleiman NS, Moses J, et al. A prospective, randomized clinical trial of hemodynamic support with Impella 2.5 versus intra-aortic balloon pump in patients undergoing high-risk percutaneous coronary intervention: the PROTECT II study. *Circulation* 2012;126:1717-27.
[PUBMED](#) | [CROSSREF](#)
92. Kapur NK, Esposito ML, Bader Y, et al. Mechanical circulatory support devices for acute right ventricular failure. *Circulation* 2017;136:314-26.
[PUBMED](#) | [CROSSREF](#)
93. Lopez-Sendon J, Coma-Canella I, Gamallo C. Sensitivity and specificity of hemodynamic criteria in the diagnosis of acute right ventricular infarction. *Circulation* 1981;64:515-25.
[PUBMED](#) | [CROSSREF](#)
94. Korabathina R, Heffernan KS, Paruchuri V, et al. The pulmonary artery pulsatility index identifies severe right ventricular dysfunction in acute inferior myocardial infarction. *Catheter Cardiovasc Interv* 2012;80:593-600.
[PUBMED](#) | [CROSSREF](#)

95. Pappalardo F, Scandroglio AM, Latib A. Full percutaneous biventricular support with two Impella pumps: the Bi-Pella approach. *ESC Heart Fail* 2018;5:368-71.
[PUBMED](#) | [CROSSREF](#)
96. Tschöpe C, Van Linthout S, Klein O, et al. Mechanical unloading by fulminant myocarditis: LV-IMPELLA, ECMELLA, BI-PELLA, and PROPELLA concepts. *J Cardiovasc Transl Res* 2019;12:116-23.
[PUBMED](#) | [CROSSREF](#)
97. van Diepen S, Katz JN, Albert NM, et al. Contemporary management of cardiogenic shock: a scientific statement from the American Heart Association. *Circulation* 2017;136:e232-68.
[PUBMED](#) | [CROSSREF](#)
98. Task Force on the management of ST-segment elevation acute myocardial infarction of the European Society of Cardiology (ESC), Steg PG, James SK, et al. ESC Guidelines for the management of acute myocardial infarction in patients presenting with ST-segment elevation. *Eur Heart J* 2012;33:2569-619.
[PUBMED](#) | [CROSSREF](#)