

Case Report

The combined treatment of stenting and surgery in a giant unruptured aneurysm of the middle cerebral artery

Miran Skrap, Benedetto Petralia¹, Giovanni Toniato

Departments of Neurosurgery, ¹Neuroradiology, Udine University-Hospital P. le S. Maria della Misericordia 15, 33100, Udine, Italy

E-mail: Miran Skrap - skrap@aoud.sanita.fvg.it; Benedetto Petralia - petralia.benedetto@aoud.sanita.fvg.it; *Giovanni Toniato - giovanni.toniato@libero.it

*Corresponding author

Received: 22 September 14 Accepted: 14 January 15 Published: 24 April 15

This article may be cited as:

Skrap M, Petralia B, Toniato G. The combined treatment of stenting and surgery in a giant unruptured aneurysm of the middle cerebral artery. *Surg Neurol Int* 2015;6:67.

Available FREE in open access from: <http://www.surgicalneurologyint.com/text.asp?2015/6/1/67/155802>

Copyright: © 2015 Skrap M. This is an open-access article distributed under the terms of the Creative Commons Attribution License, which permits unrestricted use, distribution, and reproduction in any medium, provided the original author and source are credited.

Abstract

Background: This case study reports on a combined therapy of stenting and surgery for a giant unruptured middle cerebral artery (MCA) aneurysm with the aim of preserving the patency of the vessel during surgery.

Case description: A 51-year-old male presented with a sudden onset of moderate left hemiparesis and dysarthria. Neuro-radiological evaluations showed a giant right unruptured MCA aneurysm without subarachnoid hemorrhage (SAH). The cerebral angiography confirmed the presence of such an aneurysm producing compression of both M2 branches with consequent slowing of the blood flow. Two weeks later, the patient underwent the positioning of an Enterprise stent and inside this, a flow diverter Silk stent. They were placed across the aneurysm and in one of the two M2 branches with the aim of protecting them during surgical manipulation. The patient went immediately to surgery, where the aneurysm was resected and both M2 branches decompressed.

Conclusion: The combined placement of the stents allowed safe and successful surgical dissection of the M2 branches and clipping of the aneurysm without interrupting the blood flow.

Key Words: Aneurysm, clip, combined treatment, stent

Access this article online

Website:

www.surgicalneurologyint.com

DOI:

10.4103/2152-7806.155802

Quick Response Code:



INTRODUCTION

The endovascular treatment of intracranial aneurysms is well-defined in neurosurgery and its role is becoming increasingly preeminent, thanks to continuous technical improvements.^[1,39,49] We present the case of a right giant unruptured middle cerebral artery (MCA) aneurysm treated with a combined procedure of first stenting and then immediate clipping of the aneurysm. The reason for positioning a stent across the neck of the aneurysm and along the main branch of the MCA was to guarantee the patency of the vessel during dissection of the sac and the maneuvers of clipping. Furthermore, considering the

preexistent critical blood perfusion it seemed mandatory to avoid any temporary closure of the MCA. To our knowledge, this is a novel approach where a preliminary stenting has been performed with the aim of making the surgical procedure of resecting a giant aneurysm in the same morning safe.

CASE DESCRIPTION

Clinical history and baseline data

A 51-year-old male was hospitalized in our department following sudden onset of a left hemiparesis. The cerebral computed tomography (CT) and the

computed tomographic angiogram (CTA) scans, carried out at admission, showed a right giant MCA aneurysm without subarachnoid hemorrhage (SAH) but with mass effect [Figure 1]. The baseline cerebral angiography confirmed the presence of a giant aneurysm (about 20 × 30 mm with the largest perpendicular diameters in the anteroposterior projection) at the MCA bifurcation. The vascular flow through the MCA was very slow and its contrast opacification was delayed with respect to the ipsilateral anterior cerebral artery (ACA) by 1.75 s [Figure 2]. No embolic occlusions were seen. Angiographic images of the left carotid artery and vertebro-basilar complex were normal. At admission, an antiedema therapy with dexamethason was administered, which favoured the almost complete recovery of the symptoms within a few days.

Therapeutic strategy and clinical neuroradiological follow-up

With the aim of avoiding any interruption of the blood flow, we decided to perform a combined therapeutic strategy with stenting and surgery. The stenting would protect the MCA and its branches during the surgical maneuvers of dissection and clipping of the aneurysm.

On the day of surgery under general anesthesia in the radiology unit, an Enterprise stent (4.5 × 37 mm) (Cordis Neurovascular, Miami Lakes, Florida, USA) was first placed from the right carotid dichotomy to the proximal M2 segment of the inferior trunk. Afterwards a flow diverter Silk stent (2.5 × 15 mm) (Balt, Montmorency, France) from the distal M1 segment to the proximal M2 segment of the inferior trunk was placed to complete the coverage of the aneurysmal neck. No stent was placed in the M2 superior thinner trunk of the right MCA. At the end of the endovascular procedure, an angiogram was performed, which showed a major stanching of blood within the sac, patency of the MCA, and the correct position of both stents [Figure 3]. At this point, the

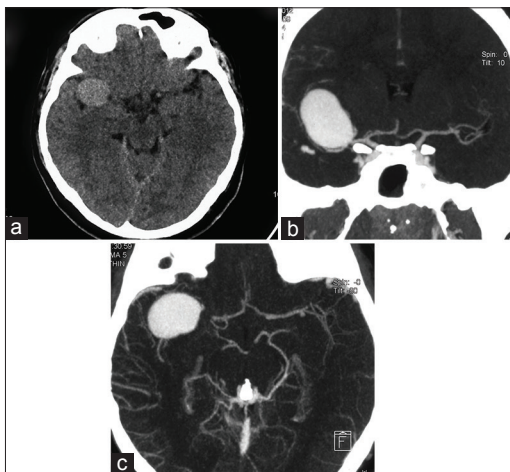


Figure 1: (a,b,c) The CT and CTA carried out at admission showed a right giant unruptured MCA aneurysm

patient was moved to the neurosurgical operating room, where a standard pterional approach was performed. Once the sylvian fissure was opened, the aneurysm was immediately visible. Both the M2 trunks of the MCA were seen firmly adhered to the sac. The inferior trunk was larger and the flow diverter Silk stent was visible through the transparency of the arterial wall. Stenting had made the vessel stiffer [Figure 4a and b], easing significantly surgical manipulation during the dissection and also preventing arterial spasms. After freeing the M2 superior trunk [Figure 4c], the aneurysmal neck has been exposed and multiple clips were applied. Because of the consistency of the neck, the first clip tended to slip on the neck, which in effect was protected by the stent. Three clips and the opening of the aneurysm were necessary to collapse the sac, which was then resected [Figure 4d]. Despite the previous stenting, abundant bleeding occurred during the emptying of the sac. As expected, the patency of the vessels remained protected by the stents during the entire surgical phase.

After surgery the patient remained in the intensive care unit for 2 days. Upon awakening, he showed a moderate left hemiparesis, which improved 3 weeks after surgery. A postoperative CT showed hypodensity around the surgical field [Figure 5].

Cerebral angiography monitoring at 1-year showed the complete exclusion of the aneurysmal sac, no delay in the venous phase was seen while optimal flow through both M2 branches was noted [Figure 6].

Anticoagulant and antiplatelet therapy management

An important issue is the management of the anticoagulant/antiplatelet therapy. We use a standard protocol for stenting alone or with coiling as follows:

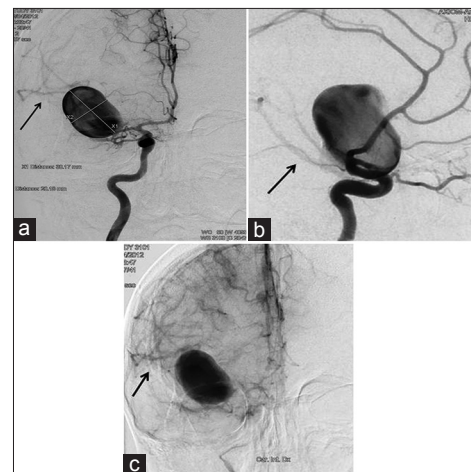


Figure 2: (a,b) The baseline cerebral angiography showed a giant right MCA aneurysm with the largest perpendicular diameters at the anteroposterior projection of about 20 × 30 mm. Note the delayed and reduced contrast opacification (a and b, black arrows) of the MCA distal to the aneurysm. (c) The slowing of the blood flow (c, black arrow) was well-evident in venous phase

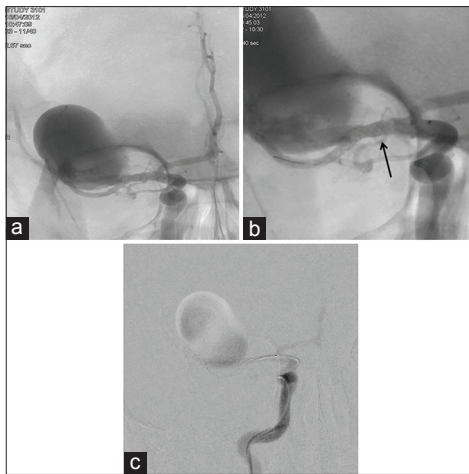


Figure 3: (a,b,c) The right carotid artery injection on the day of combined treatment just before surgery. It was clearly visible the flow diverter SILK stent (b, black arrow) allocated from the distal M1 to the proximal M2 for a length equal to 15 mm

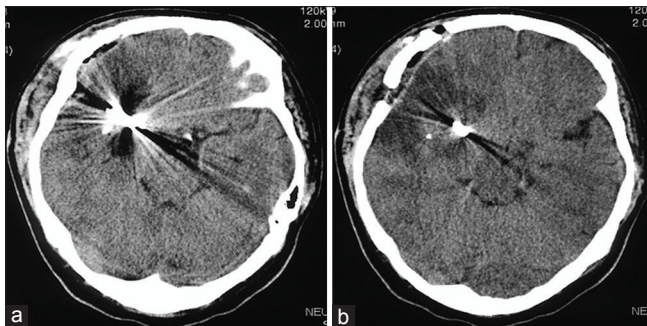


Figure 5: (a,b) The CT performed 2 days after the combined treatment showed hypodensity in the surgical field

5 days of double antiplatelet therapy before the procedure with acetylsalicylic acid (100 mg once daily) and clopidogrel (75 mg once daily), a bolus of 5000 UI of heparin at beginning of the treatment followed by 1000 UI of heparin hourly during the procedure. After that, we administer both antiplatelet drugs for the first 3 months and then only acetylsalicylic acid for the following 2 months after the procedure at dosages reported in the pretreatment regimen.

In this case, we decided to modify the standard therapy on the days before and on the day of combined treatment.

Three days before the combined treatment, prophylaxis with heparin, started at admission, was interrupted and antiplatelet therapy only with acetylsalicylic acid (100 mg once daily) was administered orally. On the day of combined treatment, a double pharmacological antiplatelet therapy was administered. Acetylsalicylic acid (100 mg once daily) was administered before the stenting and clopidogrel (75 mg once daily) just after closing the duramater. No bolus of heparin was administered at the beginning of endovascular procedure. However, as in all endovascular procedures, all pressure

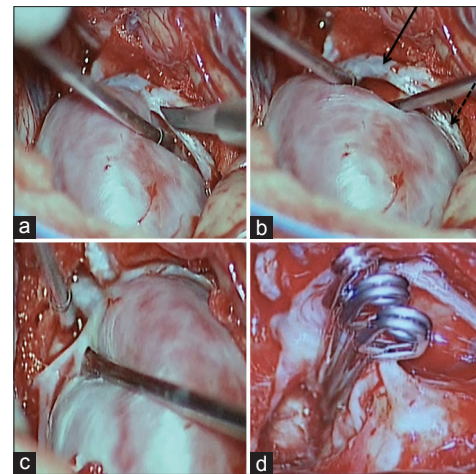


Figure 4: (a,b) The M2 inferior branch was sharply dissected from the wall of the giant aneurysm with a microblade, the vessel kept his steadiness facilitating the dissection and the branch of the MCA maintained the shape thanks to the Silk stent (b, black continued arrow) and the Enterprise stent (b, black interrupted arrow). (c) The dissection of the M2 superior branch with the exposure of adequate working-space around neck aneurysm for clipping. (d) Note the clipping of the aneurysm with three clips and patency of the protected neck

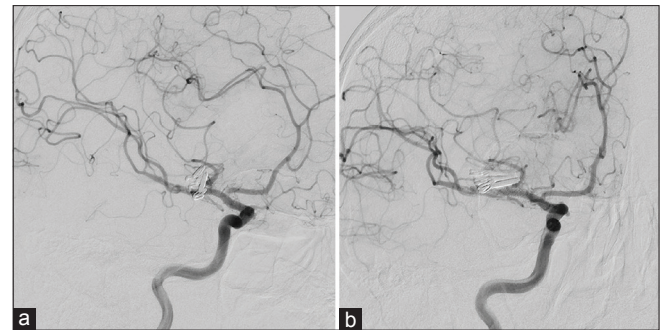


Figure 6: (a) The cerebral angiography performed 1 year after the combined treatment showed a normal blood flow through the M1 segment and both M2 trunks. (b) Note the allocation of the more proximal clip that runs along the wall of MCA being protected from stents

washing systems were fully heparinized. One day after surgery, the patient started with the standard therapy with both antiplatelet drugs for the first 3 months and then with acetylsalicylic acid only for the following 2 months at the usual dosages. No particular problems of immediate or later bleeding with the wound was managed in this case.

DISCUSSION

Intracranial giant aneurysms are severe neurovascular lesions, which should be treated aggressively considering their poor natural history.^[12,26] Most frequently, giant aneurysms are localised at MCA bifurcation, with an incidence of about 4–7%.^[12,41] They are characterized by intraluminal thrombi, mural calcifications, fusiform

aspect, incorporation of M1 tract-M2 branches into the base or dome becoming consequently challenging for either surgical clipping or coiling alone.^[41] Due to the anatomical variability of such aneurysms, several surgical strategies have been performed for these complex cases, as aneurysm thrombectomy with clip reconstruction,^[16,41,45,50] aneurysm excision with an *in situ* bypass,^[31,40,41] Hunterian proximal MCA occlusion^[6,10,14,41,50] and surgical trapping^[7,10,14,37,41,50] both with or without cerebral revascularization. Many vascular neurosurgeons actually prefer safe alternatives to surgery, as endovascular parent artery sacrifice with possible surgical extracranial-intracranial bypass.^[9,24,34,41,48] More recently, Kato *et al.*^[12] have treated two giant MCA aneurysms combining multiple arterial reimplantation, Nakajima *et al.*^[26] cured 13 giant MCA aneurysms with clipping (4), trapping and removal of sac (1), and microvascular reconstruction techniques (8); not lastly, Shi *et al.*^[41] managed nine giant MCA aneurysms with incorporated branches performing partial endovascular coiling alone or in combination with extracranial bypass.

Moreover, among different surgical strategies documented in the literature, direct clipping^[26,44,50] or eventually reconstructive neck clipping^[32,38,50] of giant MCA aneurysms have been suggested, when the morphology of the aneurysm, its location and hemodynamic features are favorable. Furthermore we have to underline that the majority of the above-mentioned strategies have included temporary or permanent parent vessel occlusion.

In our case, the main problem was insufficient vascular blood flow distally to the giant MCA aneurysm due to the aneurysmal mass effect on M2 branches. The situation was clear with the CTA at admission, and later it was confirmed by the angiogram. Esteban *et al.*^[8] described already that perfusion abnormalities due to arterial stenoses or occlusions may be suspected even from angio CT. In spite of the collateral vessel formation at the baseline angiogram after right carotid injection, the blood flow was not adequate to prevent the onset of a left hemiparesis and dysarthria. Vascular flow through the MCA was delayed with the respect to the ipsilateral ACA of 1.75 s. In effect, Kim *et al.*^[13] have showed a correlation between angiographic collateral flow, infarct volume and outcome in patients with MCA occlusion highlighting that leptomeningeal collateral flow may be insufficient to sustain cerebral perfusion without recanalization.

In the reported case, the aneurysmal compression on the M1 tract-M2 branches was persistent and likely also affected the lenticulostriate arteries around the MCA bifurcation. For this reason we have considered at risk any strategy that would accept any form of even temporary proximal occlusion of MCA. Consequently, despite the development of endovascular technology,^[1,3,22,23,28,29,39,47,49] we did not consider safe enough the possibility of

stenting alone or in combination with coiling, as this would probably increase the compression on M1 tract-M2 branches further reducing blood flow.

In this case, we also retained that direct clipping of the aneurysm would also create the risk of spasm and damage to the M2 branches during their dissection. Furthermore, the clipping itself, due to the thickness of the wall, would increase the risk of losing the patency of MCA at the level of the neck during the surgical maneuvers. We did not trust the possibility of a compensatory blood pressure augmentation and burst suppression as we would probably need them for a longer period.

Evaluating then the strategy of revascularization with high-flow bypass, the compressed recipient M2 vessels, partially hidden by the aneurysmal sac, would be too thin to build a safe and patent bypass, apart from the usual well known problem of the temporary occlusion of a M2 branch. Neither did we consider a low-flow bypass sufficient. The low-flow bypass could be anyway inadequate or, in any case, would need a longer time to become functionally helpful, while the clinical situation required more urgent therapeutical management.

We decided finally to adopt a combined strategy that would keep the vascularization during the entire procedure. In the literature, a combined treatment approach for the same aneurysm has been described in the following different situations: (i) Delayed endovascular^[2,4,17] or surgical treatment^[2,15,17,19,33] after previously unsuccessful surgical or endovascular treatment; (ii) temporary endovascular parent artery occlusion during clipping,^[27,42,43,46] and (iii) microsurgical revascularization followed by endovascular parent artery occlusion and flow-redirection techniques.^[9,17,30] In our experience,^[42] we have previously treated a series of eight giant paraclinoid and four vertebro-basilar aneurysms in combination with the neuroradiologist, where an adequate flow allowed a temporary occlusion. However, according to our knowledge, such a combined treatment in the same morning has never been described and represents a novel strategy in the exclusion of giant aneurysms. Reinforcing with stents the MCA at the level of the aneurysmal neck and the main M2 branch has allowed to keep the patency of vessels during surgery giving to the surgeon the time to perform in safety all the surgical maneuvers to resect the aneurysm and free the M2 branches. The first stent was used with the aim of allowing a better expansion and adhesion of the flow-diverter stent to the wall, thus reducing the risk of dislocation.^[20] Both types of stents were chosen by the neuroradiologist due to his own experience. In his opinion, the Enterprise stent is easier to use in positioning, navigability and it has a good radial force, while the Silk stent is more adaptable inside another stent and has a wide range of measures, which makes it very versatile.

Another issue in this case was the antiplatelet and heparinic anticoagulant drug therapy before, during, and after the combined treatment. According to several authors,^[5,11,18,21,25,35,36] this therapy is commonly established by the administration of dual antiplatelet therapy pre- and poststenting phase, usually acetylsalicylic acid and clopidogrel. If necessary, heparin may be administered during the endovascular procedure and even some variability in dosages and timing might be considered. However, no data is available concerning variations of antiplatelet/anticoagulant therapy in advance of early surgery. In this case, no bolus of heparin was administered at beginning of the stenting but as in any endovascular procedures all the pressure washing systems were fully heparinized. Furthermore, to speed all the procedure the patient and the operating room were prepared for surgery, so about 2 h after stenting, the aneurysm was already clipped and the dura closed, thus allowing the administration of clopidogrel.

CONCLUSION

The combined treatment of a giant aneurysm with stenting, followed by immediate clipping, may be taken into consideration, whenever it is necessary to protect and strengthen the arterial walls during surgical maneuvers. Selected neoplastic lesions might also benefit from this strategy.

REFERENCES

1. Alshekhlee A, Mehta S, Edgell RC, Vora N, Feen E, Mohammadi A, et al. Hospital mortality and complications of electively clipped or coiled unruptured intracranial aneurysms. *Stroke* 2010;41:1471-6.
2. Asgari S, Doerfler A, Wanke I, Schoch B, Forsting M, Stolke D. Complementary management of partially occluded aneurysms by using surgical or endovascular therapy. *J Neurosurg* 2002;97:843-50.
3. Byrne JV, Beltechi R, Yarnold JA, Birks J, Kamran M. Early experience in the treatment of intra-cranial aneurysms by endovascular flow diversion: A multicentre prospective study. *PLoS One* 2010;5:e12492.
4. Cekirge HS, Islak C, Firat MM, Kocer N, Saatci I. Endovascular coil embolization of residual or recurrent aneurysms after surgical clipping. *Acta Radiol* 2000;41:1111-5.
5. Çinar C, Bozkaya H, Oran I. Endovascular treatment of cranial aneurysms with the pipeline flow-diverting stent: Preliminary mid-term results. *Diagn Interv Radiol* 2013;19:154-64.
6. Drake CG, Peerless SJ, Ferguson GG. Hunterian proximal arterial occlusion for giant aneurysms of the carotid circulation. *J Neurosurg* 1984;81:656-65.
7. El Beltagy M, Muroi C, Imhof HG, Yonekawa Y. Peripheral large or giant fusiform middle cerebral artery aneurysms: Report of our experience and review of literature. *Acta Neurochir Suppl* 2008;103:37-44.
8. Esteban JM, Cervera V. Perfusion CT, and angioCT in the assessment of acute stroke. *Neuroradiology* 2004;46:705-15.
9. Gonzalez NR, Duckwiler G, Jahan R, Murayama Y, Viñuela F. Challenges in the endovascular treatment of giant intracranial aneurysms. *Neurosurgery* 2008;62:1324-35.
10. Kalani MY, Zabramski JM, Hu YC, Spetzler RF. Extracranial-intracranial bypass and vessel occlusion for the treatment of unclippable giant middle cerebral artery aneurysms. *Neurosurgery* 2013;72:428-35.
11. Kanaan H, Jankowitz B, Aleu A, Kostov D, Lin R, Lee K, et al. In-stent thrombosis and stenosis after neck-remodeling device-assisted coil embolization of intracranial aneurysms. *Neurosurgery* 2010;67:1523-32.
12. Kato N, Prinz V, Finger T, Schomacher M, Onken J, Dengler J, et al. Multiple reimplantation technique for treatment of complex giant aneurysms of the middle cerebral artery: Technical note. *Acta Neurochir (Wien)* 2013;155:261-9.
13. Kim JJ, Fischbein NJ, Lu Y, Pham D, Dillon WP. Regional angiographic grading system for collateral flow: Correlation with cerebral infarction in patients with middle cerebral artery occlusion. *Stroke* 2004;35:1340-4.
14. Kivipelto L, Niemelä M, Meling T, Lehecka M, Lehto H, Hernesniemi J. Bypass surgery for complex middle cerebral artery aneurysms: Impact of the exact location in the MCA tree. *J Neurosurg* 2014;120:398-408.
15. Kumar R, Deopujari CE, Shah R, Luhana R. Surgical management of intracranial aneurysms previously treated with endovascular therapy. *Neurol India* 2010;58:292-7.
16. Lawton MT, Quiñones-Hinojosa A, Chang EF, Yu T. Thrombotic intracranial aneurysms: Classification scheme and management strategies in 68 patients. *Neurosurgery* 2005;56:441-54.
17. Lawton MT, Quinones-Hinojosa A, Sanai N, Malek JY, Dowd CF. Combined microsurgical and endovascular management of complex intracranial aneurysms. *Neurosurgery* 2003;52:263-74.
18. Lee DH, Kim HS, Kim SM, Kwon SU, Suh DC. Change of Platelet Reactivity to Antiplatelet Therapy after Stenting Procedure for Cerebral Artery Stenosis: Verify Now Antiplatelet Assay before and after Stenting. *Neurointervention* 2012;7:23-6.
19. Lejeune JP, Thines L, Taschner C, Bourgeois P, Henon H, Leclerc X. Neurosurgical treatment for aneurysm remnants or recurrences after coil occlusion. *Neurosurgery* 2008;6:684-91.
20. Leonardi M, Cirillo L, Toni F, Dall'olio M, Princiotta C, Stafa A, et al. Treatment of intracranial aneurysms using flow-diverting silk stents (BALT): A single centre experience. *Interv Neuroradiol* 2011;17:306-15.
21. Lessne ML, Shah P, Alexander MJ, Barnhart HX, Powers CJ, Golshani K, et al. Thromboembolic complications after Neuroform stent-assisted treatment of cerebral aneurysms: The Duke Cerebrovascular Center experience in 235 patients with 274 stents. *Neurosurgery* 2011;69:369-75.
22. Lubicz B, Collignon L, Raphaeli G, Pruvo JP, Bruneau M, De Witte O, et al. Flow-diverter stent for the endovascular treatment of intracranial aneurysms: A prospective study in 29 patients with 34 aneurysms. *Stroke* 2010;41:2247-53.
23. Lylyk P, Miranda C, Ceratto R, Ferrario A, Scrivano E, Luna HR, et al. Curative endovascular reconstruction of cerebral aneurysms with the pipeline embolization device: The Buenos Aires experience. *Neurosurgery* 2009;64:632-42.
24. Martin NA. The combination of endovascular and surgical techniques for the treatment of intracranial aneurysms. *Neurosurg Clin N Am* 1998;9:897.
25. Mocco J, Fargen KM, Albuquerque FC, Bendok BR, Boulous AS, Carpenter JS, et al. Delayed thrombosis or stenosis following enterprise-assisted stent-coiling: Is it safe? Midterm results of the interstate collaboration of enterprise stent coiling. *Neurosurgery* 2011;69:908-13.
26. Nakajima H, Kamiyama H, Nakamura T, Takizawa K, Tokugawa J, Ohata K. Direct surgical treatment of giant middle cerebral artery aneurysms using microvascular reconstruction techniques. *Neurol Med Chir (Tokyo)* 2012;52:56-61.
27. Parkinson RJ, Bendok BR, Getch CC, Yashar P, Shaibani A, Ankenbrandt VW, et al. Retrograde suction decompression of giant paraclinoid aneurysms using a No. 7 French balloon-containing guide catheter: Technical note. *J Neurosurg* 2006;105:479-81.
28. Pierot L, Spelle L, Vitry F; ATENA Investigators. Immediate clinical outcome of patients harboring unruptured intracranial aneurysms treated by endovascular approach: Results of the ATENA study. *Stroke* 2008;39:2497-504.
29. Piotin M, Blanc R, Spelle L, Mounayer C, Piantino R, Schmidt PJ, et al. Stent-assisted coiling of intracranial aneurysms: Clinical and angiographic results in 216 consecutive aneurysms. *Stroke* 2010;41:110-5.
30. Ponce FA, Albuquerque FC, McDougall CG, Han PP, Zabramski JM, Spetzler RF. Combined endovascular and microsurgical management of giant and complex unruptured aneurysms. *Neurosurg Focus* 2004;17:E11.
31. Quiñones-Hinojosa A, Lawton MT. *In situ* bypass in the management of complex intracranial aneurysms: Technique application in 13 patients. *Neurosurgery* 2008;62:1442-9.
32. Rodríguez-Hernández A, Sughrue ME, Akhavan S, Habdank-Kolaczowski J, Lawton MT. Current management of middle cerebral artery aneurysms:

- Surgical results with a "clip first" policy. *Neurosurgery* 2013;72:415-27.
33. Romani R, Lehto H, Laakso A, Horcajadas A, Kivisaari R, von und zu Fraunberg M, et al. Microsurgery for previously coiled aneurysms: Experience with 81 patients. *Neurosurgery* 2011;68:140-53.
 34. Ross IB, Weill A, Piotin M, Moret J. Endovascular treatment of distally located giant aneurysms. *Neurosurgery* 2008;62 (6 Suppl 3):S1354-60.
 35. Rossen JD, Chalouhi N, Wassef SN, Thomas J, Abel TJ, Jabbour PM, et al. Incidence of cerebral ischemic events after discontinuation of clopidogrel in patients with intracranial aneurysms treated with stent-assisted techniques. *J Neurosurg* 2012;117:929-33.
 36. Saatci I, Yavuz K, Ozer C, Geyik S, Cekirge HS. Treatment of intracranial aneurysms using the pipeline flow-diverter embolization device: A single-center experience with long-term follow-up results. *AJNR Am J Neuroradiol* 2012;33:1436-46.
 37. Saito H, Ogasawara K, Kubo Y, Saso M, Otawara Y, Ogawa A. Treatment of ruptured spontaneous saccular aneurysm in the central artery of the middle cerebral artery using bypass surgery combined with trapping-Case report. *Neurol Med Chir (Tokyo)* 2007;47:471-4.
 38. Sano H. Treatment of complex intracranial aneurysms of anterior circulation using multiple clips. *Acta Neurochir Suppl* 2010;107:27-31.
 39. Seibert B, Tummala RP, Chow R, Faridar A, Mousavi SA, Divani AA. Intracranial aneurysms: Review of current treatment options and outcomes. *Front Neurol* 2011;2:45.
 40. Sekhar LN, Stimac D, Bakir A, Rak R. Reconstruction options for complex middle cerebral artery aneurysms. *Neurosurgery* 2005;56 (1 Suppl):66-74.
 41. Shi ZS, Ziegler J, Duckwiler GR, Jahan R, Frazee J, Ausman JJ, et al. Management of giant middle cerebral artery aneurysms with incorporated branches: Partial endovascular coiling or combined extracranial-intracranial bypass-a team approach. *Neurosurgery* 2009;65 (6 Suppl):S121-9.
 42. Skrap M, Petralia B, Toniato G. Temporary balloon occlusion during the surgical treatment of giant paraclinoid and vertebrobasilar aneurysms. *Acta Neurochir (Wien)* 2010;152:435-42.
 43. Steiger HJ, Lins F, Mayer T, Schmid-Elsaesser R, Stummer W, Turowski B. Temporary aneurysm orifice balloon occlusion as an alternative to retrograde suction decompression for giant paraclinoid internal carotid artery aneurysm: Technical note. *Neurosurgery* 2005;56:E442.
 44. Sughrue ME, Saloner D, Rayz VL, Lawton MT. Giant intracranial aneurysms: Evolution of management in a contemporary surgical series. *Neurosurgery* 2011;69:1261-70.
 45. Sugita M, Kinouchi H, Nishiyama Y, Kanemaru K, Yoshioka H, Horikoshi T. Direct clipping of a thrombosed giant cerebral aneurysm after thrombectomy without bleeding to minimize the temporary occlusion time-technical case report. *Neurol Med Chir (Tokyo)* 2009;49:600-3.
 46. Thorell W, Rasmussen P, Perl J, Masaryk M, Mayberg M. Balloon-assisted microvascular clipping of paraclinoid aneurysms. *J Neurosurg* 2004;100:713-6.
 47. Vendrell JF, Costalat V, Brunel H, Riquelme C, Bonafe A. Stent-assisted coiling of complex middle cerebral artery aneurysms: Initial and midterm results. *AJNR Am J Neuroradiol* 2011;32:259-63.
 48. Wehman JC, Hanel RA, Levy EI, Hopkins L. Giant cerebral aneurysms: Endovascular challenges. *Neurosurgery* 2006;59 (5 Suppl 3):S125-38.
 49. Yoon W. Current update on the randomized controlled trials of intracranial aneurysms. *Neurointervention* 2011;6:1-5.
 50. Zhu W, Liu P, Tian Y, Gu Y, Xu B, Chen L, et al. Complex middle cerebral artery aneurysms: A new classification based on the angioarchitecture and surgical strategies. *Acta Neurochir (Wien)* 2013;155:1481-91.