

# Use of sacubitril/valsartan in non-compaction cardiomyopathy: a case report

Marcely Gimenes Bonatto<sup>1,2\*</sup>, Rodrigo Albanez<sup>1</sup>, Vera Maria Cury Salemi<sup>3</sup> and Lídia Zytynski Moura<sup>2</sup>

<sup>1</sup>Department of Cardiology, Heart Failure and Heart Transplantation Section of Santa Casa de Misericórdia Hospital, Curitiba, Paraná, Brazil; <sup>2</sup>Department of Cardiology, Pontifical Catholic University of Paraná, Curitiba, Brazil; <sup>3</sup>Heart Failure Section of Heart Institute (InCor), University of São Paulo Medical School, São Paulo, Brazil

## Abstract

The use of sacubitril/valsartan significantly reduces death or hospitalization in patients with ejection fraction < 40%. There is no study evaluating this drug effects in non-compaction cardiomyopathy (NCCM) individuals.

The aim of this article is to report a case of a patient with NCCM initially refractory to gold standard treatment and afterwards treated with sacubitril/valsartan and its improvements. This is a case report of a 48-year-old woman, presenting with NCCM heart failure, who had received standard guideline-directed medical therapy for 18 months without any improvement in clinical and echocardiographic parameters. After that period, sacubitril/valsartan was initiated. After 18 months of refractory usage of guideline-directed medical therapy, sacubitril/valsartan was started, and significant change in functional class (III to I) and important ventricular remodelling were achieved with an improvement of 29% in the ejection fraction, reduction of 7 mm in ventricular diastolic diameter, and mild to none mitral valve functional regurgitation.

In this case report, sacubitril/valsartan use was associated with improvement of echocardiographic and clinical parameters in a patient with NCCM.

**Keywords** Heart failure; non-compaction cardiomyopathy; Sacubitril/valsartan; Reverse remodelling

Received: 10 November 2019; Revised: 2 March 2020; Accepted: 31 March 2020

\*Correspondence to: Marcely Gimenes Bonatto, Department of Cardiology, Centre for Heart Failure and Heart Transplantation, Santa Casa de Misericórdia Hospital, Praça Rui Barbosa, 694-Centro, Curitiba, Paraná 80010-030, Brazil. Email: marcelyonatto@gmail.com

## Introduction

Non-compaction cardiomyopathy (NCCM) is a myocardial disorder, characterized by an exceptional ventricular wall development of an external compacted layer and an internal non-compacted one, with prominent trabeculations and deep intertrabecular recesses, which communicate with the ventricular cavity.<sup>1</sup>

It is frequent in the left ventricle (LV), but it may also be presented in the right one.<sup>1</sup> The prevalence is not well established because of the lack of standardized diagnostic criteria, but it is estimated to be 0.01–0.3% of the population, with average diagnostic age of 40–50 years old.<sup>2–6</sup> The associated morbidity and mortality rates are high with 26% of death or cardiac transplantation in 3 years<sup>4</sup> and 5–12% mortality per year.<sup>6</sup>

There is no specific study or recommendation for the NCCM heart failure (HF) treatment.<sup>7</sup>

The case illustrates the therapeutic optimization with angiotensin receptor-neprilysin inhibitors (ARNI) in an NCCM HF patient.

## Case report

A 48-year-old woman, Caucasian, former smoker (15 pack-years), with a history of hypothyroidism, atrial fibrillation, and NCCM diagnosed in September 2016.

She was referred to the advanced HF team with important effort-induced dyspnoea (New York Heart Association III). The physical exam showed systolic blood pressure of 90–100 mmHg, mean heart rate of 64, and no signs of systemic congestion.

The primary echocardiogram and cardiac magnetic resonance imaging revealed apical (e) medium apical

trabeculations with a non-compaction/compaction ratio of 2.5 (Table 1 and Figure 1).

The patient had been treated daily with carvedilol 50 mg, losartan 100 mg, spironolactone 25 mg, furosemide 120 mg, digoxin 0,125 mg, hydralazine 100 mg, isosorbide mononitrate 80 mg, levothyroxine 25mcg, and warfarin.

After 18 months (March 2018), the clinical conditions and echocardiogram were unchanged, she was still exercise limited despite guideline-directed medical therapy optimization.

At the follow-up visit in May 2018, the clinical status had deteriorated. She complained of worsening dyspnoea and fatigue. Her medical therapy was modified by switching losartan to sacubitril/valsartan, and the dose was adjusted after 30 days to 97/103 mg BID. All other medications were maintained in equal doses.

In September 2018, the patient had clinical and echocardiographic improvement, presenting with New York Heart Association functional class I, reverse remodelling with improved LV parameters. She kept improving her status during the next 8 months (Table 1 and Figure 1).

## Literature review/discussion

NCCM is usually attributed to a pause or delay in myocardial compaction that occurs on the early phase of embryogenesis. Therefore, it is accepted as a congenital disease.<sup>1,6,7</sup>

Unlike the most common causes of HF, as ischaemic, hypertensive, and valvular disease that develops a hypertrophy or dilation of the ventricle with segmental or diffuse contractility loss, its physiopathology is attributed to a pause or delay in myocardial compaction that occurs in the early phase of embryogenesis. Between the 12th and 18th week of development, the ventricular myocardium gradually becomes compacted, and the larger intertrabecular recesses are transformed into capillaries. If this process does not occur, a thickened, non-compacted endomyocardial layer with

prominent trabeculations that are continuous with the LV cavity and lack communication with the epicardial circulation, deep recesses, and a thin compacted epicardial layer circulation develops.

Nevertheless, NCCM may also present as acquired or reversible form. Trabeculations in the LV are found in almost 30% of patients with HF of any cause. About 8% of all high-performance athletes have a non-compaction myocardium, which is probably a benign condition, associated with physiological adaptation to exercise.<sup>1,7</sup> During pregnancy, 25% of all women may also have trabeculations with complete resolution after this period. Presumably there is also a non-genetic form of the condition.<sup>3,6,7</sup>

Most individuals are asymptomatic. The most common clinical presentations are HF, arrhythmias, and thromboembolic events.<sup>1,7,8</sup>

The prevailing presentation is HF (58% in adults), commonly with reduced ejection fraction (EF) (58–76% cases).<sup>6,7,9</sup>

Thromboembolic events are frequent (5–38%), especially when atrial fibrillation or HF is present.<sup>4,6</sup>

First-degree relatives must be genetically tested for NCCM. The chance of confirming the diagnosis is 13–50%.<sup>6</sup> The screening should be done every 1–3 years in adults and should include clinical, genetic, and image evaluation.<sup>5,6</sup>

The diagnosis is not based on unique and absolute criteria.<sup>7</sup>

The evaluation should include electrocardiography, echocardiography, cardiac magnetic resonance imaging (MRI), 24-h Holter monitoring, and screening in first-degree relatives.<sup>1</sup>

The electrocardiography is abnormal in 88–94% of all cases. Left bundle branch block and atrial fibrillation may be found in 44% and 26% of all patients, respectively.<sup>7</sup>

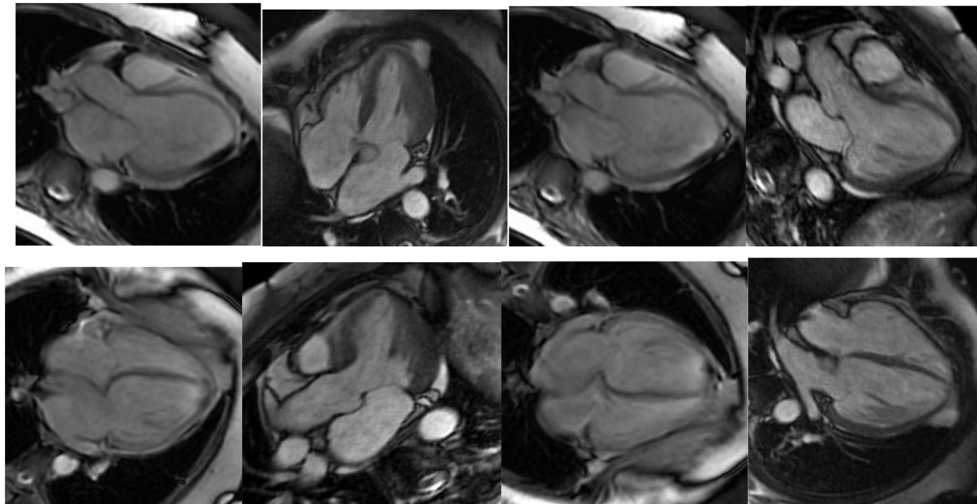
Echocardiogram is the first-line method. However, MRI is the gold standard method for diagnosis. The echocardiogram has a high sensitivity with a considerable chance of false-positive results, which makes the MRI frequently necessary.<sup>4</sup> The most used criteria are Petersen's, characterized by

**Table 1** Echocardiographic evolution

	LA (mm)	RV (mm)	LV mass (g/m <sup>2</sup> )	LV (mm)	EF	Comments
Diagnosis	35	21	142	62 × 56	Teicholz: 21%; Simpson: 24%	Moderate diastolic dysfunction; moderate functional mitral valve regurgitation
6 months ST	30	20	128	56 × 48	Teicholz: 30%; Simpson: 25%	Moderate diastolic dysfunction; mild functional mitral valve regurgitation
18 months ST	30	20	129	56 × 46	Teicholz: 32%; Simpson: 27%	Moderate diastolic dysfunction; mild functional mitral valve regurgitation
3 months SV	29	21	99	48 × 36	Teicholz: 49%; Simpson: 45%	Mild diastolic dysfunction; no mitral valve regurgitation
6 months SV	32	22	96	49 × 36	Teicholz: 52%; Simpson: 54%	Mild diastolic dysfunction; no mitral valve regurgitation
12 months SV	31	22	94	49 × 34	Teicholz: 58%; Simpson: 56%	Mild diastolic dysfunction; no mitral valve regurgitation

EF, ejection fraction; LA, left atrium; RV, right ventricle; LV, left ventricle; ST, Standard treatment; SV, Sacubitril/Valsartan.

**Figure 1** Cardiac magnetic resonance image of non-compaction left ventricle with functional improve after a 6-month treatment with sacubitril/valsartan.



a non-compaction/compaction relationship  $\geq 2.3$  in the end of diastole.<sup>2,4</sup>

Patients with atrial fibrillation, severe LV dysfunction, intracavitary thrombus, and history of embolic events should be started on anticoagulation.<sup>7,10</sup> The indication for implantable cardioverter in secondary prophylaxis is consensual. However, for primary prevention, the indication should be very thorough, considering family history, syncope, and non-sustained ventricular tachycardia.<sup>10</sup>

The indication for pharmacological treatment follows the usual guideline-directed medical therapy.<sup>7</sup> Renin-angiotensin system inhibitors, beta-blockers, aldosterone antagonists and cardiac devices are established as optimal therapy for HF.<sup>11–13</sup>

In 2014, the PARADIGM-HF study compared the effects of sacubitril/valsartan vs. enalapril on reduced EF HF patients. Sacubitril/valsartan group showed reduction of 16% mortality of all causes, 20% reduction of cardiovascular death, and 21% reduction in hospitalization for HF.<sup>14</sup> Nonetheless, there are no previous reports of ARNI use in NCCM HF individuals. Sub-analysis showed although ischaemic heart disease was the most common aetiology (60%), when adjusted for other prognostic variables, the benefit of ARNI over enalapril was not changed by aetiology.<sup>15</sup> Nonetheless, there are no previous reports of ARNI use in NCCM HF individuals.

The association between reversed remodelling (improvement in EF and reduction in LV dimensions) and better clinical outcomes, including reduced mortality, is well recognized in the literature.<sup>11–13</sup>

In an animal model study, the use of sacubitril/valsartan was associated with cardiac function improvement and fibrosis reduction when compared with placebo or valsartan alone.<sup>16</sup>

Iborra-Egea *et al.* recently published an analysis of the molecular ARNI mechanisms that leads to reversed remodelling. They mainly suggested that remodelling effect is not associated with individual mechanisms but mostly with the synergic action of drug combination. Valsartan was found to improve cardiac remodelling by inhibiting members of the guanine nucleotide-binding protein family, while Sacubitril attenuated cardiomyocyte cell death, hypertrophy, and impaired myocyte contractility.<sup>17</sup>

PROVE-HF study demonstrated echocardiographic parameters improvements with sacubitril/valsartan on reduced EF HF patients. At 12 months, the mean LVEF increased 9.6% with significant decrease in LV, left atrial volume index, and the diastolic dysfunction.<sup>18</sup>

Unfortunately, patients with NCCM were not represented in this study, and data on reverse remodelling in this population with Sacubitril/valsartan are still very scarce.

Nevertheless, there are some data suggesting that patients with non-ischaemic HF, in general, have better outcomes of LV remodelling than ischaemic patients using sacubitril-valsartan.<sup>19</sup> In the PARADIGM-HF study, almost 40% of all patients were non-ischaemic, corroborating the benefit that this drug has on the patients.<sup>14</sup>

In this case report, sacubitril/valsartan use was associated with improvement of clinical and echocardiographic parameters in a patient with NCCM.

## Conflict of interest

None declared.

## References

1. Arbustini E, Favalli V, Narula N, Serio A, Grasso M. Left ventricular noncompaction: a distinct genetic cardiomyopathy? *J Am Coll Cardiol* 2016; **68**: 949–966.
2. Anderson RH, Jensen B, Mohun TJ, Petersen SE, Aung N, Zemrak F, Planken RN, MacIver D. Key questions relating to left ventricular noncompaction cardiomyopathy: is the emperor still wearing any clothes? *Can J Cardiol* 2017; **33**: 747–757.
3. Hussein A, Karimianpour A, Collie P, Krasuski RA. Isolated noncompaction of the left ventricle in adults. *J Am Coll Cardiol* 2015; **66**: 578–585.
4. Towbin JA, Lorts A, Jefferies JL. Left ventricular non-compaction cardiomyopathy. *The Lancet* 2015; **386**: 813–825.
5. Gati S, Rajani R, Carr-White GS, Chambers JB. Adult left ventricular noncompaction. *J Am Coll Cardiol Img* 2014; **7**: 1266–1275.
6. Ikeda U, Minamisawa M, Koyama J. Isolated left ventricular non-compaction cardiomyopathy in adults. *J Cardiol* 2015; **65**: 91–97.
7. Arbustini E, Weidemann F, Hall JL. Left ventricular noncompaction: a distinct cardiomyopathy or a trait shared by different cardiac diseases? *J Am Coll Cardiol* 2014; **64**: 1840–1850.
8. Finsterer J, Stöllberger C, Towbin JA. Left ventricular noncompaction cardiomyopathy: cardiac, neuromuscular, and genetic factors. *Nat Rev Cardiol* 2017; **14**: 224–237.
9. Salazar-Mendiguchía J, González-Costello J, Oliveras T, Gual F, Lupón J, Manito N. Long-term follow-up of symptomatic adult patients with noncompaction cardiomyopathy. *Rev Esp Cardiol (Engl Ed)* 2017; **72**: 169–171.
10. van Waning JI, Caliskan K, Hoedemaekers YM, van Spaendonck-Zwarts KY, Baas AF, Boekholdt SM, van Melle J, Teske AJ, Asselbergs FW, Backx APCM, du Marchie Sarvaas GJ, Dalinghaus M, Breur JMPJ, Linschoten MPM, Verlooi LA, Kardys I, Dooijes D, Lekanne Deprez RH, Ijma AS, van den Berg M, Hofstra RMW, van Slegtenhorst M, Jongbloed JDH, Majoor-Krakauer D. Genetics, clinical features, and long-term outcome of noncompaction cardiomyopathy. *J Am Coll Cardiol* 2018; **71**: 711–722.
11. Stacey RB, Caine AJ Jr, Hundley WGCurr evaluation and management of left ventricular noncompaction cardiomyopathy. *Heart Fail Rep* 2015; **12**: 61–67.
12. Kramer DG, Trikalinos TA, Kent AJV, Konstam MA, Udelson JE. Quantitative evaluation of drug or device effects on ventricular remodeling as predictors of therapeutic effects on mortality in patients with heart failure and reduced ejection fraction: a meta-analytic approach. *J Am Coll Cardiol* 2010; **56**: 392–406.
13. Sekaran NK, Crowley AL, Souza FR, Resende ES, Rao SV. The role for cardiovascular remodeling in cardiovascular outcomes. *Curr Atheroscler Rep* 2017; **19**: 23.
14. Saraon T, Katz SD. Reverse remodeling in systolic heart failure. *Cardiol Rev* 2015-Aug; **23**: 173–181.
15. McMurray JJV, Packer M, Desai AS, Gong J, Lefkowitz MP, Rizkala AR, Rouleau JL, Shi VC, Solomon SD, Swedberg K, Zile MR, PARADIGM-HF Investigators and Committees. Angiotensin-neprilysin inhibition versus enalapril in heart failure. *N Engl J Med* 2014; **371**: 993–1004.
16. Balmforth C, Simpson J, Shen L, Jhund PS, Lefkowitz M, Rizkala AR, Rouleau JL, Shi V, Solomon SD, Swedberg K, Zile MR, Packer M, McMurray JJV. Outcomes and effect of treatment according to etiology in HFREF: an analysis of PARADIGM-HF. *JACC Heart Fail* 2019; **7**: 457–465.
17. Iborra-Egea O, Gálvez-Montón C, Roura S, Perea-Gil I, Prat-Vidal C, Soler-Botija C, Bayes-Genis A. Mechanisms of action of sacubitril/valsartan on cardiac remodeling: a systems biology approach. *NPJ Syst Biol Appl* 2017; **3**: 1–9.
18. Januzzi JL Jr, Prescott MF, Butler J, Felker GM, Maisel AS, McCague K, Camacho A, Piña IL, Rocha RA, Shah AM, Williamson KM, Solomon SD. PROVE-HF investigators association of change in N-terminal pro-B-type natriuretic peptide following initiation of sacubitril-valsartan treatment with cardiac structure and function in patients with heart failure with reduced ejection fraction. *JAMA* 2019; **2**: 1–11.
19. Chang HY, Chen KC, Fong MC, Feng AN, Fu HN, Huang KC, Chong E, Yin WH. Recovery of left ventricular dysfunction after sacubitril/valsartan: predictors and management. *J Cardiol* 2019; **75**: 233–241.