



Intraoperative risk factors for peritumoral infarctions following glioma surgery



Per Sveino Strand^{a,b,*}, Sasha Gulati^{a,b}, Lisa Millgård Sagberg^{b,c}, Ole Solheim^{a,b}

^a Department of Neuromedicine and Movement Science, Norwegian University of Science and Technology, Trondheim, Norway

^b Department of Neurosurgery, St. Olavs Hospital, Trondheim University Hospital, Norway

^c Department of Public Health and Nursing, Faculty of Medicine and Health Sciences, Norwegian University of Science and Technology, Trondheim, Norway

ARTICLE INFO

Keywords:
Glioma
Surgery
Infarction
Diffusion-weighted imaging

ABSTRACT

Background: Surgical intraoperative risk factors for peritumoral infarctions are not much studied. In the present study, we explore the possible association between intraoperative factors and infarctions diagnosed from early postoperative MRIs.

Methods: We screened all adult patients operated for newly diagnosed or recurrent diffuse gliomas at our department from December 2015 to October 2020 with available postoperative MRI including DWI sequences. Patient data was prospectively collected in a local tumor registry. Immediately after surgery, the surgeon completed a questionnaire on tumor vascularization, tumor stiffness, delineation of tumor from normal brain tissue, which surgical tool(s) were used, and if they had sacrificed a functional artery or a significant vein.

Results: Data from 175 operations were included for analysis. Of these, 66 cases (38%) had postoperative peritumoral infarctions. 24 (36%) were rim-shaped and 42 (64%) infarctions were sector-shaped. The median infarction volume was 2.4 cm³. Surgeon reported sacrifice of a significant vein was associated with infarctions, but we found no clear “dose-response”, as “perhaps” was associated with fewer infarctions than “no”. None of the other studied factors reached statistical significance. However, there was a trend for more infarctions when an ultrasonic aspirator was used for tumor resection. Subgroup analyses were done for rim-shaped and sector-shaped infarctions, and ultrasonic aspirator was associated with sector-shaped infarctions ($p = 0.032$). Infarction rates differed across surgeons (range 15%–67%), $p = 0.021$.

Conclusion: In this single center study, no clear relationships between surgeon reported intraoperative factors and postoperative infarctions were observed. Still, risks seem to be surgeon dependent.

1. Introduction

Maximal safe resection remains the primary treatment strategy in most diffuse gliomas (Hardesty and Sanai, 2012; Sanai and Berger, 2008). However, due to an infiltrating growth pattern in the brain parenchyma (Louis et al., 2016), glioma surgery is a balance between removing cancerous tissue while minimizing the potential damage to functional brain tissue. Despite a wide range of aids to guide resection of tumor tissue while sparing functional or normal brain tissue, surgically induced deficits are unfortunately still rather common. In addition to inadvertent resection of functional tissue, surgical contusions (e.g., from spatulas), postoperative hematomas or postoperative infections, postoperative deficits may also result from surgically induced brain

infarctions (Gempt et al., 2013; Jakola et al., 2014; Ulmer et al., 2006; Bo et al., 2019; Gogos et al., 2020; Lupa et al., 2020).

In a recent publication, we observed peritumoral infarctions after 44% of diffuse glioma surgeries (Strand et al., 2021). Infarctions were more common in the temporal lobes and in the periventricular watershed regions. Patient age and intraoperative bleeding were positively associated with infarction volume. Resident surgeons did not have more infarctions or higher median infarction volumes than consultants, but there were still significant differences in both frequencies of infarctions and infarction volumes across different surgeons.

Although perioperative hemodynamic parameters, for instance mean arterial pressure (MAP) and liquid balance, have been correlated to infarction volume (Bette et al., 2017), little is known about surgical

* Corresponding author. Department of Neuromedicine and Movement Science, Norwegian University of Science and Technology, Trondheim, Norway.

E-mail addresses: persst@stud.ntnu.no (P. Sveino Strand), sasha.gulati@ntnu.no (S. Gulati), lisa.millgard.sagberg@ntnu.no (L. Millgård Sagberg), ole.solheim@ntnu.no (O. Solheim).

<https://doi.org/10.1016/j.bas.2022.100903>

Received 17 January 2022; Received in revised form 25 April 2022; Accepted 3 June 2022

Available online 7 June 2022

2772-5294/© 2022 Published by Elsevier B.V. on behalf of EUROSPINE, the Spine Society of Europe, EANS, the European Association of Neurological Societies. This is an open access article under the CC BY-NC-ND license (<http://creativecommons.org/licenses/by-nc-nd/4.0/>).

intraoperative risk factors for peritumoral infarctions. In the present study we explore the possible association between intraoperative factors and infarctions diagnosed from early postoperative MRIs.

2. Methods

2.1. Study population

We screened all adult patients (≥ 18 years) operated for newly diagnosed or recurrent diffuse gliomas WHO grade 2–4 at the Department of Neurosurgery at St. Olavs Hospital, Trondheim University Hospital, from December 2015 to October 2020 with available postoperative MRI including DWI sequences taken less than 72 h after surgery. This department exclusively serves approximately 750 000 inhabitants in a defined geographical catchment region.

2.2. Data collection

Patient characteristics and questionnaires were prospectively collected in a local tumor registry, and the study was retrospectively designed. Tumor grading was done by a neuropathologist. Gliomas operated prior to the second half of 2016 were classified according to the 2007-WHO classification of central nervous system tumors and tumors operated in the latter half of 2016 through 2018 were classified according to the 2016 WHO-classification. The operating surgeon filled out a questionnaire immediately after the operation, where the following parameters were retrieved: 1) Was a normal artery sacrificed during surgery (yes/perhaps/no) 2) Was a significant vein sacrificed during surgery (yes/perhaps/no) 3) Was the tumor heterogeneous (yes/no) 4) How was the tumor vascularization (avascular/medium vascular/very vascular) 5) How was the tumor delineated from normal brain tissue (easily delineated/possible, but difficult to delineate from normal brain/impossible to delineate tumor borders) 6) What was the stiffness of the tumor tissue? (softer than normal brain, like normal brain, harder than normal brain) 7) Which tools were used for tumor resection (ultrasonic aspirator, suction/micro scissors). The name of the operating surgeon was also acquired and anonymized in the analyses. At our institution, there is variability in surgical techniques and tool preference between surgeons. In many cases, a combination of tools and techniques are in use in individual patients, tailoring the use of tools and techniques to the location and tumor characteristics. Moreover, combinations of inside-out and outside-in resections and suction-based or ultrasonic aspirator-based resections are often used. In many cases, especially in softer tumors, suction only might be preferred for tumor resection.

Our postoperative MRI-protocols have been described in detail earlier (Strand et al., 2021). All patients in the study had an early postoperative MRI control before 72 h after surgery. Infarctions were detected using postoperative B100-sequences on diffusion-weighted images (DWI) and apparent diffusion coefficient (ADC) maps. Areas with high signals on B1000-images and corresponding low values on ADC-maps, which could not be explained by other diffusion abnormalities, were defined as infarctions. As done in previous studies, infarctions were classified as either rim-shaped (ischemic lesions surrounding the operation cavity), sector-shaped or a combination of sector-and rim-shaped, and a 3 mm radial cutoff was used to distinguish normal postoperative changes from infarctions (Loit et al., 2019; Jakola et al., 2014). Examples of rim- and sector-shaped infarctions are presented in Figs. 1 and 2, respectively. Extent of resection was scored as either gross total tumor resection (all radiologically visible tumor was removed) or subtotal tumor resection, based upon early postoperative MRI controls.

2.3. Statistical analyses

Statistical analyses and descriptive statistics were performed with IBM SPSS Statistics version 27.0 (IBM, Armonk, New York). Q-Q-plots were used to determine normal distribution of data. Differences between categorical and continuous variables were assessed using Fisher's exact

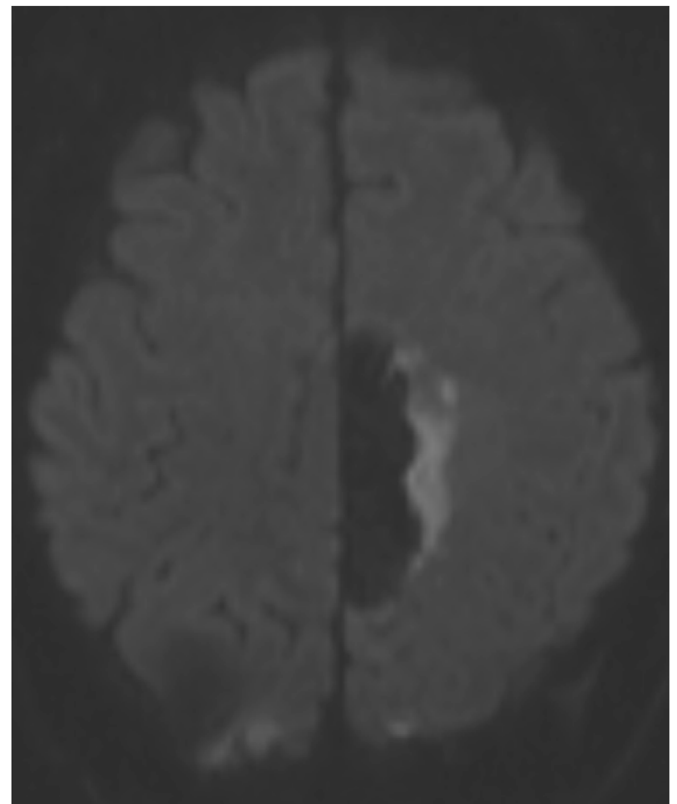


Fig. 1. A rim-shaped infarction located laterally in the operation cavity.

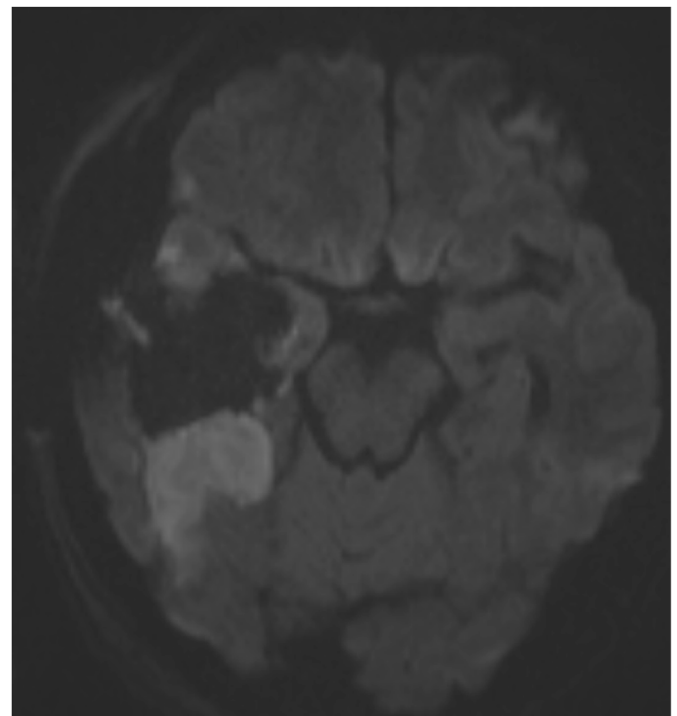


Fig. 2. A sector-shaped infarction located posteriorly in the operation cavity.

tests and Mann-Whitney U tests, respectively. Statistical significance level was set to $P \leq 0.05$.

2.4. Ethics and approval

The study protocol was approved by the Regional Ethical Committee

for Health Region Mid-Norway (REK), (REK reference 2018/1187). All patients provided written informed in the Health Region Mid-Norway Brain Tumor Registry (REK reference 2015/215). The data collection was done according to the guidelines of the Helsinki Declaration.

3. Results

Patient characteristics at baseline are presented in Table 1. 188 operations were eligible, but 13 were excluded from analyses due to missing questionnaires, leaving 175 operations for inclusion. In 16 cases the questionnaire was incomplete as one or more items were missing. Following the 175 operations, 66 cases (38%) had postoperative peritumoral infarctions, 24 (36%) were rim-shaped and 42 (64%) infarctions were sector-shaped. The median infarction volume was 2.4 cm³ (interquartile range [IQR]) 0.9–4.0). A comparison of patients with versus without infarctions is presented in Table 2. As seen, surgeon reported sacrifice of a significant vein was statistically associated with infarctions, but there is no clear “dose-response” as “perhaps” was associated with fewer infarctions than “no”. There was no difference in the frequencies of infarctions across different WHO grades or between patients with versus without a gross total tumor resection. None of the other studied factors reached statistical significance, but there was a trend for more infarctions when an ultrasonic aspirator was used for tumor resection.

Separate subgroup analyses were done for both rim-shaped and sector-shaped infarctions, but the results were similar to the unselected data as presented in Table 2. However, use of ultrasonic aspirator was associated with sector-shaped infarctions (p = 0.032). As a post hoc analysis, we assessed frequencies of infarctions and volume of infarctions from individual surgeons at our institution in the study period. The total frequencies of infarctions across individual surgeons were different (range 15%–67%, p = 0.021) and there was a statistically non-significant trend that infarction volumes differed across surgeons (range median infarction volume 0.6–3.2 cm³, p = 0.065).

4. Discussion

In this prospective single-center cohort study, no clear relationships between surgeon reported intraoperative factors and peritumoral infarctions were observed. Still, risks may be dependent on surgical technique as infarction rates differ across surgeons. Surprisingly, intraoperative artery damage reported by the operating surgeon was not predictive of postoperative infarctions as seen on early postoperative MRIs. This might reflect collateral arterial supply in some brain regions and a more unpredictable nature of peritumoral infarctions. There was a trend towards more infarctions in patients where the ultrasonic aspirator was used for resections.

The main finding of our study is that postoperative infarctions are not easily predicted based on intraoperative events. Previous studies have found that perioperative hemodynamic monitoring and tumor location are associated with risk of peritumoral infarctions (Bette et al., 2017; Dutzmann et al., 2012), but intraoperative risk factors are not known. Still, as risks may be surgeon dependent, surgical technique or approaches may play a role. For instance, an anatomical study demonstrated that trans-gyral, para-sulcal and trans-sulcal approaches pose different challenges in relation to functional vessels (Latini and Ryttefjors, 2015). As the technical practice of glioma surgery varies greatly (Chang et al., 2005), further research on how surgical techniques impact the risk of peritumoral infarctions is warranted.

While it is evident that arterial damage cause infarctions, we still found no association between surgeon reported sacrifice of presumed functional arteries and postoperative infarctions. Several pre-and perioperative tools are available to plan careful dissection around major brain vessels, and vessels in relation to the tumor may also be appreciated

Table 1
Patient characteristics at baseline.

Characteristic	Value (%)
Number of operations	175
Median age in years (IQR)	56.0 (41–63)
Sex	
Male	109 (62.3)
Female	66 (37.7)
Tumor histology	
WHO grade 2	33 (18.9)
WHO grade 3	31 (17.7)
WHO grade 4	111 (63.4)
Primary operation	
Yes	117 (66.9)
No	58 (33.10)

Table 2
Association between peritumoral infarctions and surgical risk factors.

	Infarction	No infarction	P-value
WHO grade			
WHO grade 2	10 (29.4%)	24 (70.6%)	0.205
WHO grade 3	9 (29.0%)	22 (71.0%)	
WHO grade 4	47 (42.7%)	63 (57.3%)	
Sacrifice of functional artery during surgery			
Yes	6 (30.0%)	14 (70.0%)	0.444
No	52 (40.3%)	77 (59.7%)	
Perhaps	7 (29.2%)	17 (70.8%)	
Sacrifice of significant vein during surgery			
Yes	4 (80.0%)	1 (20.0%)	0.0290
No	58 (38.2%)	94 (61.8%)	
Perhaps	2 (14.3%)	12 (85.7%)	
Heterogenous tumor			
Yes	40 (39.6%)	61 (60.4%)	0.513
No	25 (34.7%)	47 (65.3%)	
Tumor vascularization			
Avascular	24 (30.8%)	54 (69.2%)	0.0820
Medium vascular	35 (47.3%)	39 (52.7%)	
Very vascular	6 (30.0%)	14 (70.0%)	
Delineation of tumor from normal brain tissue			
Easily demarcated	3 (20.0%)	12 (80.0%)	0.316
Possible, but difficult to delineate from normal brain	32 (40.5%)	47 (59.5%)	
Impossible to delineate tumor borders	30 (39.0%)	47 (61.0%)	
Tumor stiffness			
Harder than normal brain tissue	10 (23.3%)	33 (76.7%)	0.0560
Like normal brain tissue	23 (46.9%)	26 (53.1%)	
Softer than normal brain tissue	23 (33.3%)	46 (66.7%)	
Surgical tool			
Suction/bipolar/scissors/forceps	13 (26.0%)	37 (74.0%)	0.0880
Ultrasonic surgical aspirator	13 (38.2%)	21 (61.8%)	
Both	40 (44.9%)	49 (55.1%)	
Gross total resection			
Yes	28 (30.8%)	63 (69.2%)	0.930
No	38 (45.2%)	46 (54.8%)	

on preoperative T2-weighted MRI-sequences (Del Bene et al., 2018; Saito et al., 2009). However, the cortical microvasculature is more intricate than seen macroscopically during tumor resection (Moody et al., 1990), and it may not be obvious for a surgeon that he or she has damaged a functional small blood vessel. This may be further complicated by intraoperative bleeding, making it more difficult to distinguish pathological tumor vessels from functional vessels, and in an earlier study we found that peritumoral infarction volume is positively associated with intraoperative bleeding (Strand et al., 2021). In a publication on motor evoked potentials (MEP) during resection of insular gliomas, it was found that MEP correctly identifies areas of ischemia, which may help the surgeon to correct his or her technique or surgical approach during tumor resection (Neuloh et al., 2007). However, there are no prospective trials that have shown better outcomes as a result of MEP.

Ultrasonic aspirators are used in a variety of neurosurgical procedures (Henzi et al., 2019), and consists of an oscillating tip that causes tissue fragmentation, in addition to aspirate cellular debris (Brock et al., 1984; Epstein, 1983). Ultrasonic aspirators are designed to spare larger blood vessels due to a higher concentration of collagen (Henzi et al., 2019; Ramazanov et al., 1999; Tang et al., 2014), but smaller vessels may be destroyed during resection (Brock et al., 1984). Animal studies have found that blood flow and nervous tissue are not affected more than 1 mm from the operation cavity using ultrasonic aspirators (Young et al., 1981; Tamburus et al., 1984), but caution should be taken as higher power settings in the ultrasonic aspirators may be associated with increased damage (Bagley et al., 2001).

Although the reported incidence varies (Kageyama et al., 1996; SAITO et al., 1998), it is known that larger venous infarctions may occur after sacrifice of cerebral veins during surgery (Nakase et al., 2005). Yet, due to much collateral venous circulation, and the absence of venous valves, the relationship between common peritumoral infarctions and sacrifice of veins is not so clear (Savardekar et al., 2018). A vein was damaged more often in the group with infarctions and this difference reached statistical significance; yet, the total number of events is very small, and there was no clear dose-response relationship between “yes”, “maybe”, and “no”, and the clinical interpretation is thus difficult.

Although we failed to detect clear explanations of infarctions seen on early postoperative MRIs from the studied intraoperative factors, this should motivate further studies as the clinical significance of infarctions may be important, not at least in eloquent regions. For instance, xenon light from modern operation microscopes have been reported to cause damage to patients (Choudhry et al., 2013; Latuska et al., 2014; Lopez et al., 2016), yet it does not necessarily have a significant impact on the brain temperature under craniotomies (Gayatri et al., 2013). However, little is known of its potential effect on cortical damage during surgery. Moreover, it is possible that coagulation using bipolar coagulation in the resection bed, as opposed to passive hemostasis using hemostatic agents, which is more time-consuming, may play a role.

The main strengths of our study are the prospective collection of variables, and the relatively large sample size. There are several limitations to our study. The single center setting may result in somewhat homogenous surgical techniques that may reduce power to detect differences. Still, surgical techniques vary somewhat among our surgeons. Furthermore, the questionnaire in use is not validated, which may impact the external validity of the study. Also, the surgeon reported on their own surgical events which may result in a reporting bias. The odd number of alternatives in the questionnaire may have resulted in an excess of neutral or indecisive answers for several questions. The difference in infarctions among surgeons may also be affected by selection bias, as different surgeons are selected for different cases.

5. Conclusion

In this single center study, no clear relationships between surgeon reported intraoperative factors and postoperative infarctions were observed. Still, risks seem to be surgeon dependent.

Disclosures and funding

None of the authors report any conflicts of interest.

The paper has not been presented or published previously. The study was supported by the Norwegian Research Council and the Faculty of Medicine at the Norwegian University of Science and Technology (NTNU), through the Student Research Program at NTNU. The founding source did not in any form take part in study design, acquisition of data, analysis, writing, or reviewing the final paper.

References

- Bagley, R.S., Harrington, M.L., Gay, J.M., Silver, G.M., 2001. Effects of changes in power setting of an ultrasonic aspirator on amount of damage to the cerebral cortex of healthy dogs. *Am. J. Vet. Res.* 62, 248–251.
- Bette, S., Wiestler, B., Wiedenmann, F., Kaesmacher, J., Bretschneider, M., Barz, M., Huber, T., Ryang, Y.M., Kochs, E., Zimmer, C., Meyer, B., Boeckh-Behrens, T., Kirschke, J.S., Gempt, J., 2017. Safe brain tumor resection does not depend on surgery alone - role of hemodynamics. *Sci. Rep.* 7, 5585. <https://doi.org/10.1038/s41598-017-05767-2>.
- Bo, H.K., Solheim, O., Kvistad, K.A., Berntsen, E.M., Torp, S.H., Skjulsvik, A.J., Reinertsen, I., Iversen, D.H., Unsgard, G., Jakola, A.S., 2019. Intraoperative 3D ultrasound-guided resection of diffuse low-grade gliomas: radiological and clinical results. *J. Neurosurg.* 1–12. <https://doi.org/10.3171/2018.10.JNS181290>.
- Brock, M., Ingwersen, I., Roggendorf, W., 1984. Ultrasonic aspiration in neurosurgery. *Neurosurg. Rev.* 7, 173–177. <https://doi.org/10.1007/BF01780701>.
- Chang, S.M., Parney, I.F., Huang, W., Anderson, F.A., Asher, A.L., Bernstein, M., Lillehei, K.O., Brem, H., Berger, M.S., Laws, E.R., 2005. Patterns of care for adults with newly diagnosed malignant glioma. *JAMA* 293, 557–564.
- Choudhry, I.K., Kyriakides, J., Foad, M.B., 2013. Iatrogenic burn caused by an operating microscope: case report. *J. Hand Surg.* 38, 545–547.
- Del Bene, M., Perin, A., Casali, C., Legnani, F., Saladino, A., Mattei, L., Vetrano, I.G., Saini, M., DiMeco, F., Prada, F., 2018. Advanced ultrasound imaging in glioma surgery: beyond gray-scale B-mode. *Front. Oncol.* 8, 576.
- Dutzmann, S., Gessler, F., Bink, A., Quick, J., Franz, K., Seifert, V., Senft, C., 2012. Risk of ischemia in glioma surgery: comparison of first and repeat procedures. *J. Neuro Oncol.* 107, 599–607. <https://doi.org/10.1007/s11060-011-0784-1>.
- Epstein, F., 1983. The Cavitron ultrasonic aspirator in tumor surgery. *Clin. Neurosurg.* 31, 497–505. https://doi.org/10.1093/neurosurg/31.cn_suppl_1.497.
- Gayatri, P., Menon, G.G., Suneel, P.R., 2013. Effect of operating microscope light on brain temperature during craniotomy. *J. Neurosurg. Anesthesiol.* 25, 267–270. <https://doi.org/10.1097/ANA.0b013e3182894a01>.
- Gempt, J., Forschler, A., Buchmann, N., Pape, H., Ryang, Y.M., Krieg, S.M., Zimmer, C., Meyer, B., Ringel, F., 2013. Postoperative ischemic changes following resection of newly diagnosed and recurrent gliomas and their clinical relevance. *J. Neurosurg.* 118, 801–808. <https://doi.org/10.3171/2012.12.JNS12125>.
- Gogos, A.J., Young, J.S., Morshed, R.A., Avalos, L.N., Noss, R.S., Villanueva-Meyer, J.E., Hervey-Jumper, S.L., Berger, M.S., 2020. Triple motor mapping: transcranial, bipolar, and monopolar mapping for supratentorial glioma resection adjacent to motor pathways. *J. Neurosurg.* 1–10. <https://doi.org/10.3171/2020.3.JNS193434>.
- Hardesty, D.A., Sanai, N., 2012. The value of glioma extent of resection in the modern neurosurgical era. *Front. Neurol.* 3, 140. <https://doi.org/10.3389/fneur.2012.00140>.
- Henzi, S., Krayenbuhl, N., Bozinov, O., Regli, L., Stienen, M.N., 2019. Ultrasonic aspiration in neurosurgery: comparative analysis of complications and outcome for three commonly used models. *Acta Neurochir.* 161, 2073–2082. <https://doi.org/10.1007/s00701-019-04021-0>.
- Jakola, A.S., Berntsen, E.M., Christensen, P., Gulati, S., Unsgard, G., Kvistad, K.A., Solheim, O., 2014. Surgically acquired deficits and diffusion weighted MRI changes after glioma resection—a matched case-control study with blinded neuroradiological assessment. *PLoS One* 9, e101805. <https://doi.org/10.1371/journal.pone.0101805>.
- Kageyama, Y., Watanabe, K., Kobayashi, S., Nakamura, H., Satoh, A., Watanabe, Y., Yamaura, A., 1996. Postoperative Brain Damage Due to Cerebral Vein Disorders Resulting from the Pterional Approach. *Surgery of the intracranial venous system* Springer, Berlin Heidelberg New York Tokyo, pp. 311–315.
- Latini, F., Ryttefjors, M., 2015. Rethinking the standard trans-cortical approaches in the light of superficial white matter anatomy. *Neu. Regen. Res.* 10, 1906.
- Latuska, R.F., Carlson, M.L., Neff, B.A., Driscoll, C.L., Wanna, G.B., Haynes, D.S., 2014. Auricular burns associated with operating microscope use during otologic surgery. *Otol. Neurotol.* 35, 227–233.
- Loit, M.-P., Rheault, F., Gayat, E., Poisson, I., Froelich, S., Zhi, N., Velut, S., Mandonnet, E., 2019. Hotspots of small strokes in glioma surgery: an overlooked risk? *Acta Neurochir.* 161, 91–98.
- Lopez, J., Soni, A., Calva, D., Susarla, S.M., Jallo, G.I., Redett, R., 2016. Iatrogenic surgical microscope skin burns: a systematic review of the literature and case report. *Burns* 42, e74–e80.
- Louis, D.N., Perry, A., Reifenberger, G., von Deimling, A., Figarella-Branger, D., Cavenee, W.K., Ohgaki, H., Wiestler, O.D., Kleihues, P., Ellison, D.W., 2016. The 2016 World Health Organization classification of tumors of the central nervous system: a summary. *Acta Neuropathol.* 131, 803–820. <https://doi.org/10.1007/s00401-016-1545-1>.
- Lupa, J.T., Raizer, J.J., Helenowski, I.B., Liu, B.P., Kesavabhotla, K., Tate, M.C., 2020. The impact of perioperative arterial infarct on recurrence, functional outcomes, and

- survival in glioblastoma patients. *Front. Oncol.* 10, 706. <https://doi.org/10.3389/fonc.2020.00706>.
- Moody, D., Bell, M., Challa, V., 1990. Features of the cerebral vascular pattern that predict vulnerability to perfusion or oxygenation deficiency: an anatomic study. *Am. J. Neuroradiol.* 11, 431–439.
- Nakase, H., Shin, Y., Nakagawa, I., Kimura, R., Sakaki, T., 2005. Clinical features of postoperative cerebral venous infarction. *Acta Neurochir.* 147, 621–626.
- Neuloh, G., Pechstein, U., Schramm, J., 2007. Motor tract monitoring during insular glioma surgery. *J. Neurosurg.* 106, 582–592.
- Ramazanov, R., Dreval, O.N., Akatov, O.V., Zaretsky, A.A., 1999. Ultrasound microneurosurgery. *Neurol. Res.* 21, 73–76.
- Saito, F., Haraoka, J., Ito, H., Nishioka, H., Inaba, I., Yamada, Y., 1998. Venous complications in pterional approach: about Fronto-temporal Bridging veins. *脳卒中外科* 26, 237–241.
- Saito, R., Kumabe, T., Inoue, T., Takada, S., Yamashita, Y., Kanamori, M., Sonoda, Y., Tominaga, T., 2009. Magnetic resonance imaging for preoperative identification of the lenticulostriate arteries in insular glioma surgery. *J. Neurosurg.* 111, 278–281.
- Sanai, N., Berger, M.S., 2008. Glioma extent of resection and its impact on patient outcome. *Neurosurgery* 62, 753–764. <https://doi.org/10.1227/01.neu.0000318159.21731.cf> discussion 264-756.
- Savardekar, A.R., Patra, D.P., Narayan, V., Thakur, J.D., Nanda, A., 2018. Incidence, pathophysiology, and prevention strategies for cerebral venous complications after neurologic surgery: a systematic review of the literature. *World Neurosurg* 119, 294–299.
- Strand, P.S., Berntsen, E.M., Fyllingen, E.H., Sagberg, L.M., Reinertsen, I., Gulati, S., Bouget, D., Solheim, O., 2021. Brain infarctions after glioma surgery: prevalence, radiological characteristics and risk factors. *Acta Neurochir.* <https://doi.org/10.1007/s00701-021-04914-z>.
- Tamburus, R., Roggendorf, W., Stein, E., Brock, M., 1984. Morphologic changes in brain tissue following ultrasonic aspiration. In: *CNS Metastases Neurosurgery in the Aged*. Springer, pp. 332–337.
- Tang, H., Zhang, H., Xie, Q., Gong, Y., Zheng, M., Wang, D., Zhu, H., Chen, X., Zhou, L., 2014. Application of CUSA Excel ultrasonic aspiration system in resection of skull base meningiomas. *Chin. J. Cancer Res.* 26, 653.
- Ulmer, S., Braga, T.A., Barker 2nd, F.G., Lev, M.H., Gonzalez, R.G., Henson, J.W., 2006. Clinical and radiographic features of peritumoral infarction following resection of glioblastoma. *Neurology* 67, 1668–1670. <https://doi.org/10.1212/01.wnl.0000242894.21705.3c>.
- Young, W., Cohen, A.R., Hunt, C.D., Ransohoff, J., 1981. Acute physiological effects of ultrasonic vibrations on nervous tissue. *Neurosurgery* 8, 689–694.