



## Role of cerebral digital subtraction angiography in the evaluation of pulse synchronous tinnitus

Gregory P. Lekovic<sup>b, \*</sup>, Zachary R. Barnard<sup>a, b</sup>, Adam Master<sup>b</sup>, Gautam U. Mehta<sup>b</sup>, M. Marcel Maya<sup>d</sup>, Eric P. Wilkinson<sup>c</sup>

<sup>a</sup> Department of Neurosurgery, Cedars-Sinai Medical Center, 127 S San Vicente Blvd, Los Angeles, CA, 90048, United States

<sup>b</sup> Division of Neurosurgery, House Institute, 2100 West 3rd Street, Los Angeles, CA, 90057, United States

<sup>c</sup> Division of Neurotology, House Institute, 2100 West 3rd Street, Los Angeles, CA, 90057, United States

<sup>d</sup> Department of Imaging, Cedars-Sinai Medical Center, 127 S San Vicente Blvd, Los Angeles, CA, 90048, United States

### ARTICLE INFO

#### Article history:

Received 13 January 2021

Received in revised form

24 March 2021

Accepted 28 March 2021

#### Keywords:

Pulse-synchronous tinnitus

Transverse-sigmoid arteriovenous fistula

Vascular tinnitus

Cerebral angiography

### ABSTRACT

**Objectives:** The aim of this study was to evaluate the value of digital subtraction angiography (DSA) in the diagnostic evaluation of a highly selected patient population presenting with pulse-synchronous tinnitus (PST).

**Methods:** We retrospectively reviewed the charts of all patients referred for evaluation of possible vascular etiology of pulsatile tinnitus. Patients were evaluated with regards to presenting signs, comorbidities, non-invasive imaging results, angiographic findings and outcomes.

**Results:** Fifteen patients underwent cerebral DSA. Dural arteriovenous fistula (dAVF) was identified in six patients, and five patients had other significant vascular pathology identified on DSA. Seven patients with 'negative' non-invasive imaging were found to have significant pathology on DSA.

**Conclusions:** Catheter angiography may have a significant yield in appropriately selected patients presenting with pulse synchronous tinnitus.

© 2021 PLA General Hospital Department of Otolaryngology Head and Neck Surgery. Production and hosting by Elsevier (Singapore) Pte Ltd. This is an open access article under the CC BY-NC-ND license (<http://creativecommons.org/licenses/by-nc-nd/4.0/>).

## 1. Introduction

The causes of pulse-synchronous tinnitus (PST) include both benign and life-threatening disease. This form of tinnitus is created by non-laminar blood flow synchronous to cardiac rhythm, which is then transmitted to the inner ear. PST may be either unilateral or bilateral; it can be related to systemic disease, such as hyperthyroidism or anemia (Hofmann et al, 2013; Waldvogel et al, 1998), as a consequence of conductive hearing loss such as otosclerosis, or related to an underlying structural etiology such as temporal bone abnormality (Liu et al, 2020; Tian et al, 2019; Trivelato et al, 2015) or neoplasm. Both arterial and venous pathology may cause PST, including dural arteriovenous fistula (dAVF) (Kirsch et al, 2009; Lv et al, 2010), arteriovenous malformation (AVM), sigmoid sinus

dehiscence and/or diverticulum (Lenck et al, 2012; Mehanna et al, 2010), carotid-cavernous fistulae, carotid stenosis, cerebral venous sinus thrombosis, transverse sinus stenosis, fibromuscular dysplasia (Foyt et al, 2006), and aberrant carotid artery or persistent stapedial artery (Kizildag et al, 2016). Benign intracranial hypertension may in some cases be secondary to venous outflow obstruction and present with pulsatile tinnitus (Pereira et al, 2020). Neoplastic etiologies of PST include hypervascular tumors such as glomus tympanicum or jugulare, and meningioma.

The diagnosis of PST is above all a clinical one, based on detailed clinical history and thorough physical examination with attention to otoscopic examination. Important clinical observations include whether tinnitus is arterial or venous in nature (i.e. "venous hum"), and whether the tinnitus can be appreciated by the examiner (e.g. a palpable thrill or auscultated bruit). The importance of detailed investigation of PST is justified by its close association with treatable causes compared to other forms of tinnitus, and the fact that some causes of PST cause significant morbidity. PST is not usually associated with a high risk of morbidity, and the tinnitus may be little more than a nuisance. Unfortunately, no definite consensus

\* Corresponding author. 2100 West Third Street, Ste. 111 Los Angeles, CA, 90057 United States.

E-mail address: [glekovic@houseclinic.com](mailto:glekovic@houseclinic.com) (G.P. Lekovic).

Peer review under responsibility of PLA General Hospital Department of Otolaryngology Head and Neck Surgery.

exists as to the appropriate imaging modalities needed for evaluation of PST (Sajisevi et al, 2014); both CT angiography and MR angiography have been advocated (Dietz et al, 1994; Narvid et al, 2011; Shweel and Hamdy, 2013). The sensitivity of MR or CT based imaging protocols is not established, and digital subtraction catheter angiography (DSA) remains the ‘gold standard’ for the evaluation of vascular etiologies of PST (Hofmann et al, 2013; Sajisevi et al, 2014). The goal of the present study is to describe the results of cerebral DSA in a selected patient population presenting with PST for whom non-invasive imaging was inconclusive, non-diagnostic, or vascular lesion was apparent and DSA was necessary for treatment.

## 2. Materials and methods

The charts of all patients evaluated in a multi-disciplinary pulsatile tinnitus clinic consisting of both neurotology and neurosurgery services over a five year period were retrospectively reviewed. Electronic medical records were used to gather demographic and clinical information. All patients presenting to our tertiary neurotology practice with the chief complaint of pulsatile tinnitus were retrospectively identified by query of billing records and international diagnosis code. Selected patients were further referred to a multidisciplinary pulsatile tinnitus clinic based on selected criteria. Research was conducted in accordance with institutional IRB policies; due to retrospective character of our study consent of the participants was not obtained as the study was classified as exempt from consent requirements.

Tinnitus was defined as pulse-synchronous when the patient described a sound that was synchronous with heartbeat. When the sound was audible to the auscultating examiner or palpable (i.e. thrill), tinnitus was considered objective. When it was heard only by the patient it was classified as subjective.

During the study period, all patients underwent detailed neurotological examination including audiological evaluation and otoscopy. All patients were evaluated with CT of the temporal bone, contrast-enhanced brain MRI, and non-contrast MRA/V as their initial diagnostic imaging modalities. Patients with vascular tumors identified on MRI (e.g. paraganglioma) were excluded. Medical causes of pulsatile tinnitus (e.g. hyperthyroidism.) as well as structural etiologies related to middle ear disease or temporal bone anatomy (e.g. dehiscent jugular bulb) were also excluded from this study.

Indications for DSA included pulsatile tinnitus and either: 1) non-invasive imaging suggestive of possible vascular lesion; or 2) Negative non-invasive imaging but with accompanying findings of objective tinnitus, progressive and/or disabling symptoms, or associated neurologic complaint (including headache). All patients suffered from PST on the day of MR imaging and DSA examination.

## 3. Results

### 3.1. Clinical presentation and patient characteristics

One hundred and eighty seven patients were evaluated in our clinic for pulsatile tinnitus during the study period. Cerebral digital subtraction angiography (DSA) was recommended in 19 of these patients for suspected vasogenic PST. Four patients refused angiography (and are therefore excluded from this analysis), and 15 patients (13 female: 2 male; mean age 53.4 years, range 31–76) underwent DSA. The clinical presentation and findings are summarized in Table 1 and Table 2. Ten of the 15 patients who underwent DSA showed a vascular pathology consistent with clinical symptoms. The algorithm we used to select patients for referral to angiography is represented in Fig. 1. The diagnostic yield of our

algorithm for utilization of DSA in selected pulsatile tinnitus was 67% (10/15 patients). The mean duration of symptoms prior to evaluation of 10.25 months (range, 4–42). Only two patients presented acutely: one with acute onset of symptoms during pregnancy, and one had history of acute onset of symptoms following closed head injury. Otologic comorbidities/past surgical history included three patients with a concomitant history of sensorineural hearing loss, and two patients had history of prior middle ear surgery.

Tinnitus was characterized as either ‘arterial’ or ‘venous’ in etiology based on clinical history and physical exam. When the patient reported minimal variation in sound intensity (albeit still pulsatile), a ‘venous hum’ was diagnosed. In four patients, PST could be diminished or suppressed with external compression of the neck; this was generally thought to support a venous origin. Higher subjective volume (meaning a noise perceived by the patient to be loud enough to interfere with audition), abrupt onset, and objective tinnitus were factors felt to support the clinical diagnosis of ‘arterial’ PST. Based on these clinical characterizations, PST was thought to be arterial in nine patients, venous in origin in four patients, and indeterminate in two.

Indications for DSA included objective tinnitus (n = 6), acute onset and/or progressive symptoms (n = 6), headache (n = 1), and evidence of possible abnormality on non-invasive imaging (n = 8). Six patients had more than one indication for DSA.

### 3.2. Non-invasive imaging findings

MRA findings included evidence of possible dAVF in four patients: two patients with transverse-sigmoid (TS) sinus stenosis and soft tissue density suggestive of dAVF, one patient had arterialized blood in the transverse-sigmoid sinus, and one patient with an aneurysm of the middle meningeal artery in association with abnormal appearance of external carotid artery branches. One patient was identified on CT venogram as having possible obstruction of venous outflow at the skull base due to compression by the styloid process. Ten patients had negative or unremarkable non-invasive imaging (including CT temporal bone and MRI/A). Incidental findings on non-invasive imaging included two patients with anterior communicating artery aneurysms, one patient with middle cerebral artery aneurysm, and two patients with an empty sella, one of which also had a left temporal encephalocele (see case illustration below).

### 3.3. DSA findings

Dural AVF was identified in 6 patients undergoing DSA. Dural fistulas included three occipital artery feeding vessels draining into the TS sinus, one fistula involving occipital artery feeding vessel into both the TS and superior sagittal (SS) sinuses, one middle meningeal artery feeder (with an associated aneurysm) draining into the cavernous and petrosal sinuses, and one complex calvarial dAVF involving multiple ECA branches draining into the SS sinus. All identified dAVF were Cognard grade 1 fistulae, i.e. without evidence of retrograde filling of cortical veins.

Other significant pathology found on DSA include: fibromuscular dysplasia (n = 1), sigmoid sinus diverticulum (n = 1), and venous outflow obstruction including either stenosis of the ipsilateral TS sinus (n = 2), or obstruction at the skull base due to compression of the internal jugular vein by an enlarged styloid process (n = 1). In five patients no significant abnormalities or pathology was identified on DSA, and one patient had two significant DSA findings.

**Table 1**  
Patient characteristics and presentation.

Patient	Gender	Age	Side	SNHL	Objective	Origin	Symptoms
1	F	60	left	yes	yes	arterial	progressive severity after acute onset
2	F	31	left	no	no	venous	acute onset during pregnancy; progressive symptoms
3	F	52	left	no	yes	arterial	progressive/louder; associated with headache
4	F	52	right	no	yes	venous	objective (bruit); disabling, suppressed with compression
5	F	55	left	no	yes	arterial	objective (thrill); tinnitus
6	F	57	bilateral	yes	no	venous hum	venous hum
7	F	40	right bilateral, left >	no	no	arterial	acute onset, headache
8	F	50	right	no	no	arterial	progressive symptoms
9	F	44	left	no	no	arterial	acute onset right side, progressive symptoms
10	M	60	right	no	no	venous	progressive; suppressed with external compression
11	F	64	left			unclear	
12	F	76	right>left	no	yes	arterial	pulsatile
13	M	52	right		no	arterial	progressive
14	F	51	right	no	no	unclear	disabling
15	F	58	left	no	no	arterial	progressive, acute onset after trauma

SNHL: sensorineural hearing loss.

**Table 2**  
Results of patient non-invasive imaging, DSA, and consequential treatment.

Patient	Non-Invasive Imaging (MRI, MRV, MRA, CTA)	Digital Subtraction Angiogram (DSA)	Treatment
1	MRI negative	Fibromuscular dysplasia of ICA	None
2	MRA suggests 6-mm aneurysm of MMA	Middle meningeal artery aneurysm, skull base fistula	Partial spontaneous thrombosis on follow up angiography
3	Negative	Left transverse-sigmoid sinus dAVF	Embolization
4	MRI/A/V: negative	dAVF and transverse sinus stenosis	dAVF embolization: sx recurrent after ~1 month and then patient had TS stent with complete resolution of sx
5	MRA/V: negative	dAVF	Glue embolization
6	MRI/A/V: negative CTV IJ obstruction at skull base	Venous outflow obstruction at skull base	None
7	Negative, incidental ACOM aneurysm	Negative	None
8	MRV: partially thrombosed or irregular superior sagittal sinus suggestive of prior thrombosis; MRI: enlarged, empty sella on MRI	Negative	None
9	MRI possible small dAVF; MRV left transverse sigmoid sinus occlusion/stenosis	Negative; right dominant transverse sigmoid	None
10	MRI possible meningoencephalocele with right tegmen defect	Negative	None
11	MRV: thrombosed right transverse sigmoid sinus; left soft tissue density in temporal bone	Large left transverse sinus arachnoid granulation with obstruction; possible left transverse sigmoid diverticulum	None
12	MRI/V negative	Large calvarial a-v fistula	Craniotomy
13	MRI, CT temp bone, and CTA negative	Negative (incidental ACOM aneurysm)	None
14	Negative	Large arachnoid granulation right transverse sigmoid sinus	None
15	Arterialization of sigmoid sinus	Left transverse sigmoid sinus dAVF	Embolization

### 3.4. Treatment

Treatment was recommended in all patients with dAVF; one patient declined treatment and was observed to have spontaneous thrombosis of middle meningeal artery fistula and associated aneurysm. Three patients underwent Onyx embolization with complete resolution of symptoms. One patient underwent embolization of both TS and SS fistulae but experienced recurrence of symptoms three months later, her symptoms subsequently resolved following stenting of concomitant ipsilateral TS sinus stenosis (see case illustration). One patient with a large complex dAVF involving the transverse and sigmoid sinuses was treated initially with craniotomy and subsequently required Onyx embolization for residual dAVF seen on post-operative DSA. Complications included femoral artery dissection in one patient.

### 3.5. Illustrative case

This 52-year-old female presented with acute onset of right-sided tinnitus one year prior to neurovascular evaluation. She had a significant past medical history of endometrial cancer, during the

treatment for which she reported a history of sudden onset of severe headaches that preceded the onset of pulse-synchronous tinnitus. Her headaches subsequently resolved. Non-invasive imaging demonstrated an empty sella and left sphenoid sinus encephalocele without evidence of dAVF or transverse sinus obstruction. The patient reported that the intensity of sound had become disabling and only relieved by external compression of the neck. Given the acute onset of symptoms and crescendo progression of her complaints DSA was recommended. Findings included a Cognard grade 1 dAVF involving both the transverse and superior sagittal sinuses (Fig. 2A) as well as right-sided TS stenosis (Fig. 2B). The patient underwent embolization and despite significant initial improvement in her symptoms she had a recurrence of her complaints three months later. Repeat DSA showed successful obliteration of the fistula, and the patient’s right transverse sinus stenosis was stented with complete resolution of tinnitus (Fig. 2C). She subsequently underwent endoscopic repair of her left sphenoid sinus encephalocele without incident. The patient has remained symptom free at last follow up (62 months after fistula embolization and stenting of transverse sinus).

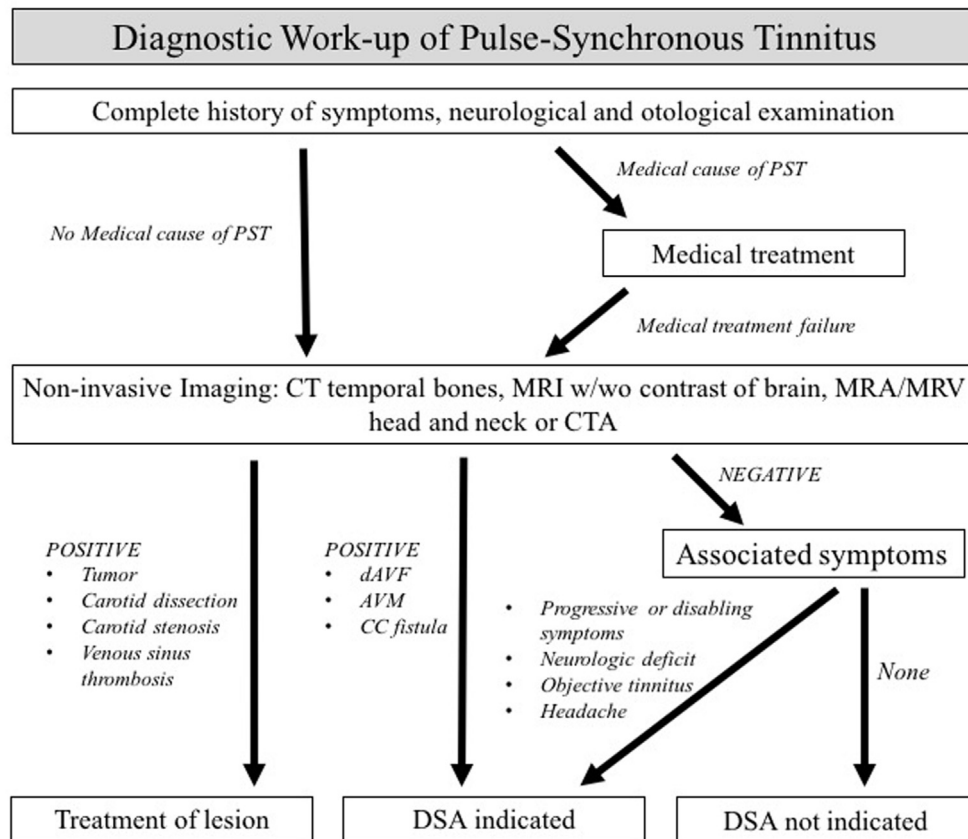


Fig. 1. Diagnostic work-up flow chart for PST.

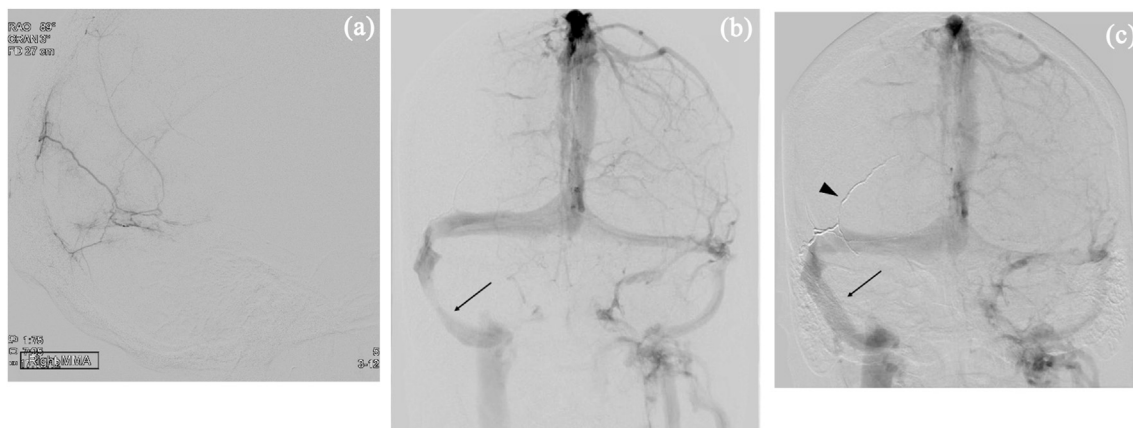


Fig. 2. (A) Digital subtraction angiogram, selective occipital artery catheter injection, lateral view, demonstrating opacification of superior sagittal and transverse sinuses indicative of dural arteriovenous malformation. (B) Digital subtraction angiogram, anteroposterior view, demonstrating stenosis of sigmoid sinus pre-treatment (C) Digital subtraction angiogram, anteroposterior view, demonstrating stented sigmoid sinus (arrow) and glue cast of feeding artery of dAVF (arrowhead).

#### 4. Discussion

Tinnitus is a complaint commonly encountered by the general otorhinolaryngologist, and pulse synchronous tinnitus comprises up to 10% of all patients with tinnitus (Hofmann et al, 2013). The need for cerebral catheter angiography for patients with isolated PST remains controversial. While DSA remains the ‘gold standard’ for diagnosis and grading of dAVF, CT and MR based angiography studies have been shown to have sensitivity of 86% and 80%, and specificity of 100% and 88%, respectively (Narvid et al, 2011; Shweel

and Hamdy, 2013). In particular, the risks of invasive cerebral catheter angiography (including stroke, retroperitoneal hematoma, arterial dissection, etc) are sufficient to give most clinicians pause prior to recommending invasive imaging for a ‘nuisance’ complaint. On the other hand, in a large series in the neurosurgical literature, many patients with high-grade dAVF present with isolated PST (Kirsch et al, 2009; Lv et al, 2010). In one meta-analysis of patients with pulsatile tinnitus, dAVF was diagnosed by angiography in 7% of patients, which is a significantly lower diagnostic yield than in our study (40%) (Hofmann et al, 2013). In the literature there is no



estimate of the prevalence of significant vascular abnormalities in the population of patients complaining of PST in the outpatient ENT clinical practice setting. In our study we showed a prevalence of dAVF and/or other significant vascular pathology is 5.3% and therefore we believe that DSA is unwarranted for all patients with a pulsatile component of tinnitus, but rather is warranted in selected patients only. The goal of the present study was to provide data on the prevalence of vascular lesions in the pulsatile tinnitus population as well as the diagnostic yield of invasive imaging in a highly selected patient population.

In our series, seven patients were found to have identifiable vascular pathology associated with PST (including dAVF, FMD, TS stenosis, and SS diverticulum), who previously had non-invasive imaging studies that failed to identify cerebrovascular pathology. Only three patients (patients 7,10,13 on Table 2) had both negative non-invasive imaging and negative DSA. Interestingly, of the four patients identified on MRA as having possible dAVF, two were found on DSA to have no evidence of a fistula. One of these patients did have a prominent arachnoid granulation that may have contributed to the MR impression of TS sinus stenosis.

The risk of a high-grade dAVF (i.e. Cognard grade IIb-IV) presenting as isolated PST is the clinical entity most likely to be associated with significant morbidity if a delay in diagnosis occurs. Furthermore, DSA remains the gold standard for grading of dAVF. In our series we did not diagnose a single dAVF with retrograde venous drainage or other high-risk features, suggesting that the prevalence of high-grade fistula in patients with PST is low. However, given the small number of patients in our study with dAVF this is difficult to say conclusively. In our study we have demonstrated that MRI/A is insufficient to rule out dAVF, however we do not know if non-invasive imaging would have greater sensitivity in the diagnosis of high-grade fistulae (because none were observed in our series). Moreover, high-grade fistulae have been associated with specific imaging findings—such as dilated cortical veins—that would be consistent with a higher sensitivity of MRI for fistulae with this specific high-grade feature. Our ability to make a firm conclusion regarding the sensitivity of non-invasive imaging is further limited by the small sample size of our patient population.

#### 4.1. Arterial vs venous PST

Vascular causes of PST can be either arterial or venous in origin. Subjective pulsations that extinguish with gentle neck pressure or altered head position supports a more benign venous origin of PST. In contrast, the presence of a bruit or thrill raises concern for a high flow arterial abnormality. We did not observe any high-grade fistulas. Other arterial causes include carotid artery stenosis/carotid occlusion (Hofmann et al., 2013), fibromuscular dysplasia (Foyt et al., 2006), persistent stapedial artery (Waldvogel et al., 1998), aberrant ICA (Sonmez et al., 2007; Waldvogel et al., 1998). The role of venous obstruction or turbulent blood flow limited to the venous sinuses is less well established. Jugular plate dehiscence and venous sinus diverticulum are two entities that have been described in which venous pulsations are audible due to either aberrant transmission of high flow within the sinus (dehiscence) or turbulent flow (diverticulum) (Grewal et al., 2014; Santa Maria et al., 2013).

Our series supports the hypothesis that clinically significant pulse-synchronous tinnitus may be due in some cases to isolated audible turbulence venous outflow obstruction (Pereira et al., 2020). Evidence that obstruction of venous outflow can also cause clinically significant PST comes TS sinus stenosis seen in association with idiopathic intracranial hypertension (Lazzaro et al., 2012); similarly Dashti et al. reported on a patient “styloidgenic” venous compression syndrome (Dashti et al., 2012) that was relieved by resection of the styloid process. Lazzaro et al. showed the existence

of pressure gradients within the dural sinuses associated with idiopathic intracranial hypertension in three patients; one patient had PST that resolved after stenting of the sinus and elimination of the pressure gradient (Lazzaro et al., 2012). Two of our patients experienced resolution of PST with treatment of stenosis of venous outflow: via stenting of the transverse sinus and decompression of the jugular vein at the skull base due to compression by an enlarged styloid process (patients #4 and 6, respectively). In addition to venous outflow obstruction, we observed one case of sigmoid sinus aneurysm or diverticulum, which is also associated with PST in the literature (Lenck et al., 2012; Mehanna et al., 2010). Patients #11 and 14 were noted to have significant TS stenosis due to arachnoid granulations seen on DSA. Whether arachnoid granulations contribute to PST is not well established, but may functionally be similar to dural sinus incompetence in the etiology of PST as described by Lazzaro et al. (Lazzaro et al., 2012).

## 5. Conclusion

Cerebral catheter angiography is indicated for patients with pulsatile tinnitus and either: 1) non-invasive imaging suggestive of possible vascular lesion; or 2) Negative non-invasive imaging but with accompanying findings of objective tinnitus, progressive and/or disabling symptoms, or associated neurologic complaint (including headache). Non-invasive imaging and careful clinical examination are sufficient for the evaluation of most causes of PST.

## Funding

This research did not receive any specific grant from funding agencies in the public, commercial, or not-for-profit sectors.

## References

- Dashti, S.R., et al., 2012. Styloidogenic jugular venous compression syndrome: diagnosis and treatment: case report. *Neurosurgery* 70 (3), E795–E799. <https://doi.org/10.1227/NEU.0b013e3182333859>.
- Dietz, R.R., et al., 1994. MR imaging and MR angiography in the evaluation of pulsatile tinnitus. *AJNR Am. J. Neuroradiol.* 15 (5), 879–889. PMID: 8059655.
- Foyt, D., et al., 2006. Fibromuscular dysplasia of the internal carotid artery causing pulsatile tinnitus. *Otolaryngol. Head Neck Surg.* 134 (4), 701–702. <https://doi.org/10.1016/j.otohns.2005.03.066>.
- Grewal, A.K., et al., 2014. Clinical presentation and imaging findings in patients with pulsatile tinnitus and sigmoid sinus diverticulum/dehiscence. *Otol. Neurotol.* 35 (1), 16–21. <https://doi.org/10.1097/MAO.0b013e31829ab6d7>.
- Hofmann, E., et al., 2013. Pulsatile tinnitus: imaging and differential diagnosis. *Dtsch. Arztebl Int.* 110 (26), 451–458. <https://doi.org/10.3238/arztebl.2013.0451>.
- Kirsch, M., et al., 2009. Endovascular management of dural arteriovenous fistulas of the transverse and sigmoid sinus in 150 patients. *Neuroradiology* 51 (7), 477–483. <https://doi.org/10.1007/s00234-009-0524-9>.
- Kizildag, B., et al., 2016. The relationship between tinnitus and vascular anomalies on temporal bone CT scan: a retrospective case control study. *Surg. Radiol. Anat.* 38, 835–841. <https://doi.org/10.1007/s00276-016-1629-6>.
- Lazzaro, M.A., et al., 2012. Venous sinus pulsatility and the potential role of dural incompetence in idiopathic intracranial hypertension. *Neurosurgery* 71 (4), 877–883. <https://doi.org/10.1227/NEU.0b013e318267a8f9>.
- Lenck, S., et al., 2012. Pulsatile tinnitus caused by an aneurysm of the transverse-sigmoid sinus: a new case report and review of literature. *J. Neuroradiol.* 39 (4), 276–279. <https://doi.org/10.1016/j.neurad.2012.02.001>.
- Liu, Z., et al., 2020. Hemodynamic changes in the sigmoid sinus of patients with pulsatile tinnitus induced by sigmoid sinus wall anomalies. *Otol. Neurotol.* 41, e163–e167. <https://doi.org/10.1097/MAO.0000000000002512>.
- Lv, X., et al., 2010. Transverse-sigmoid sinus dural arteriovenous fistulae. *World Neurosurg.* 74 (2–3), 297–305. <https://doi.org/10.1016/j.wneu.2010.02.063>.
- Mehanna, R., et al., 2010. Endovascular treatment of sigmoid sinus aneurysm presenting as devastating pulsatile tinnitus. A case report and review of literature. *Intervent. Neuroradiol.* 16 (4), 451–454. <https://doi.org/10.1177/159101991001600413>.
- Narvid, J., et al., 2011. CT angiography as a screening tool for dural arteriovenous fistula in patients with pulsatile tinnitus: feasibility and test characteristics. *AJNR Am. J. Neuroradiol.* 32 (3), 446–453. <https://doi.org/10.3174/ajnr.A2328>.
- Pereira, V.M., et al., 2020. Torrents of torment: turbulence as a mechanism of pulsatile tinnitus secondary to venous stenosis revealed by high-fidelity computational fluid dynamics. *J. Neurointerventional Surg.* <https://doi.org/>

- [10.1136/neurintsurg-2020-016636](https://doi.org/10.1136/neurintsurg-2020-016636). PMID: 33219149. Online ahead of print.
- Sajisevi, M., et al., 2014. What is the role of imaging in tinnitus? *Laryngoscope* 124 (3), 583–584. <https://doi.org/10.1002.lary.24147>.
- Santa Maria, P.L., 2013. Sigmoid sinus dehiscence resurfacing as treatment for pulsatile tinnitus. *J. Laryngol. Otol.* 127 (Suppl. 2), S57–S59. <https://doi.org/10.1017/S0022215113000649>.
- Shweel, M., Hamdy, B., 2013. Diagnostic utility of magnetic resonance imaging and magnetic resonance angiography in the radiological evaluation of pulsatile tinnitus. *Am. J. Otolaryngol.* 34 (6), 710–717. <https://doi.org/10.1016/j.amjoto.2013.08.001>.
- Sonmez, G., et al., 2007. Imaging of pulsatile tinnitus: a review of 74 patients. *Clin. Imag.* 31 (2), 102–108. <https://doi.org/10.1016/j.clinimag.2006.12.024>.
- Tian, S., et al., 2019. A study on relationship between pulsatile tinnitus and temporal bone pneumatization grade. *Comput. Methods Biomech. Biomed. Eng.* 22, 788–796. <https://doi.org/10.1080/10255842.2019.1593386>.
- Trivelato, F.P., et al., 2015. Endovascular treatment of pulsatile tinnitus associated with transverse sigmoid sinus aneurysms and jugular bulb anomalies. *Intervent. Neuroradiol.* 21, 548–551. <https://doi.org/10.1177/1591019915590367>.
- Waldvogel, D., et al., 1998. Pulsatile tinnitus—a review of 84 patients. *J. Neurol.* 245 (3), 137–142. <https://doi.org/10.1007/s004150050193>.