

Mesotherapy with Snake Venom Pharmacopuncture to Treat Hand Eczema: Two Cases Report

Sungha Kim¹, Jinbok Lee², Minseop Shin^{2*}

¹Department of Clinical Research, Korea Institute of Oriental Medicine, Daejeon, Republic of Korea

²Spine Care Korean Medicine Clinic, Jeonju, Republic of Korea

Received October 6, 2020
Reviewed October 7, 2020
Accepted November 5, 2020

***Corresponding Author**

Minseop Shin
Spine Care Korean Medicine Clinic, 163
Geomapyeong-ro, Wansan-gu, Jeonju
55056, Republic of Korea
Tel: +82-63-229-7579
E-mail: kahn815@hanmail.net

Hand eczema is a recurrent and resistant disease that seriously affects the quality of life of patients; currently, there are no ideal treatments for hand eczema. Here, we describe two patients who presented with hand eczema to illustrate the potential efficacy of mesotherapy with snake venom pharmacopuncture (SVP). A 23-year-old woman (Case 1) and a 47-year-old woman (Case 2) presented to the clinic with symptoms of pruritic rash, blisters, and itchiness on both the hands and the left hand, respectively. Both patients were diagnosed with hand eczema based on the physical examination of blisters and redness only on the hands. The patients underwent 1 month (Case 1) and 1 week (Case 2) of mesotherapy with SVP. After treatment, the lesions completely improved and did not recur at 1 year of follow-up. These outcomes suggest that mesotherapy with SVP may be effective for the resolution of hand eczema; however, further research is needed to confirm these findings.

Keywords: pompholyx, snake venom, mesotherapy, case report

INTRODUCTION

Hand eczema involves the eruption of large vesicles on the palms entailing a specific type of eczematous reaction with pronounced spongiosis and accumulation of edema fluid in regions with a thicker epidermis and an even thicker overlying, horny layer [1, 2]. Most cases are idiopathic. According to Pieter-Jan Coenraads [1], there are several types of hand eczema with no known cause; these include irritant contact dermatitis, atopic hand dermatitis, allergic contact dermatitis, hybrid hand eczema, protein contact dermatitis, and unclassified eczema. Hand eczema is a recurrent and resistant disease that seriously effects the quality of life of patients and for which no ideal treatments have been developed [3]. It is a common condition, with a point prevalence of 4% among adults in the general population and a 1-year prevalence of up to 10% [1].

Recently, the use of snake venom components as a natural resource for biotechnological applications has received attention in the pharmaceutical industry and applied research fields. Drugs derived from snake venom produced by the pharmaceu-

tical industry include captopril, Aggrastat[®], and eptifibatide. Snake venom induces changes in cell membrane permeability or exerts antimicrobial activities, among other effects [4]. In Korean Medicine, snake venom pharmacopuncture (SVP) has been known for expelling the wind, removing obstruction in the channels, its antispasmodic effects, and treating hemiplegia, facial palsy, and peripheral neuropathy [5, 6].

Mesotherapy involves the injection of active substances into the dermis and subcutaneous tissue to treat local medical conditions [7]. This procedure has been used for multiple subcutaneous or intradermal injections of pharmaceutical and homeopathic medications, plant extracts, vitamins, and other bioactive substances into the dermis or subcutaneous fat [8]. Hand eczema can be difficult to treat because of the thick overlying horny layer on the hand and the accumulation of edematous fluid in regions with a thick epidermis [9]. Using mesotherapy, drugs can be delivered at a faster rate and more accurately to intradermal areas than by oral medication or moisturizers. Here, we report two cases of hand eczema that were successfully treated by mesotherapy with SVP.

CASE REPORTS

Two women, aged 23 (case 1) and 47 years (case 2), presented with a 4- and 1-month history of pruritic rash, blisters, and itchiness on both the hands and the left hand, respectively (Fig. 1). The patients approved publication of this case report and consented to the publication of clinical images. The Institutional Review Board of the Korean Institute of Oriental Medicine approved this study (I-2002/002-005).

They had no hyperhidrosis on the palms or soles, atopy, or tinea pedis and no history of skin diseases. Both patients were working in stressful environments: one as a kindergarten teacher and the other as a cosmetics saleswoman. Both were treated with topical steroids and showed transitory improvement; however, their conditions sharply worsened when the treatment was discontinued. Case 1 consumed fried chicken 1-2 times per week. Case 2 likely came in contact with preservatives through her profession as a cosmetics saleswoman and showed symptoms only on the left hand. Physical examination revealed

blisters and redness only on the hands. On the basis of these features, a diagnosis of hand eczema was made. In case 1, based on the characteristic of deterioration according to diet, this type of eczema included aspects of atopic hand dermatitis. In case 2, considering the possibility of contact with preservatives in cosmetics during her job activities, a diagnosis of allergic contact dermatitis was speculated. Case 1 was treated with SVP (KPRI, Wonjusi, South Korea) at a dose of 2 mL twice per week (i.e., eight times a month), and case 2 was treated with 0.5 mL of SVP five times for a week [5]. A sterile hypodermic syringe (30 gauge, 1.0 mL; DM Medicrat, Seoul, Korea) was loaded onto a mesogun (Dr. Injector, MSG-500, MOOHAN Co., Ltd., Gwangjusi, Gyeonggi-do, South Korea), and 0.1 mL per point was injected in a standard mode. In total, 10 and 5 points were injected on each palm at a time based on the affected area (Supplemental Video). The treatment was well tolerated, and no adverse events were reported. Case 1 reported that the procedure was very painful but showed an improvement each week. Epidermal detachment was observed before treatments, especially

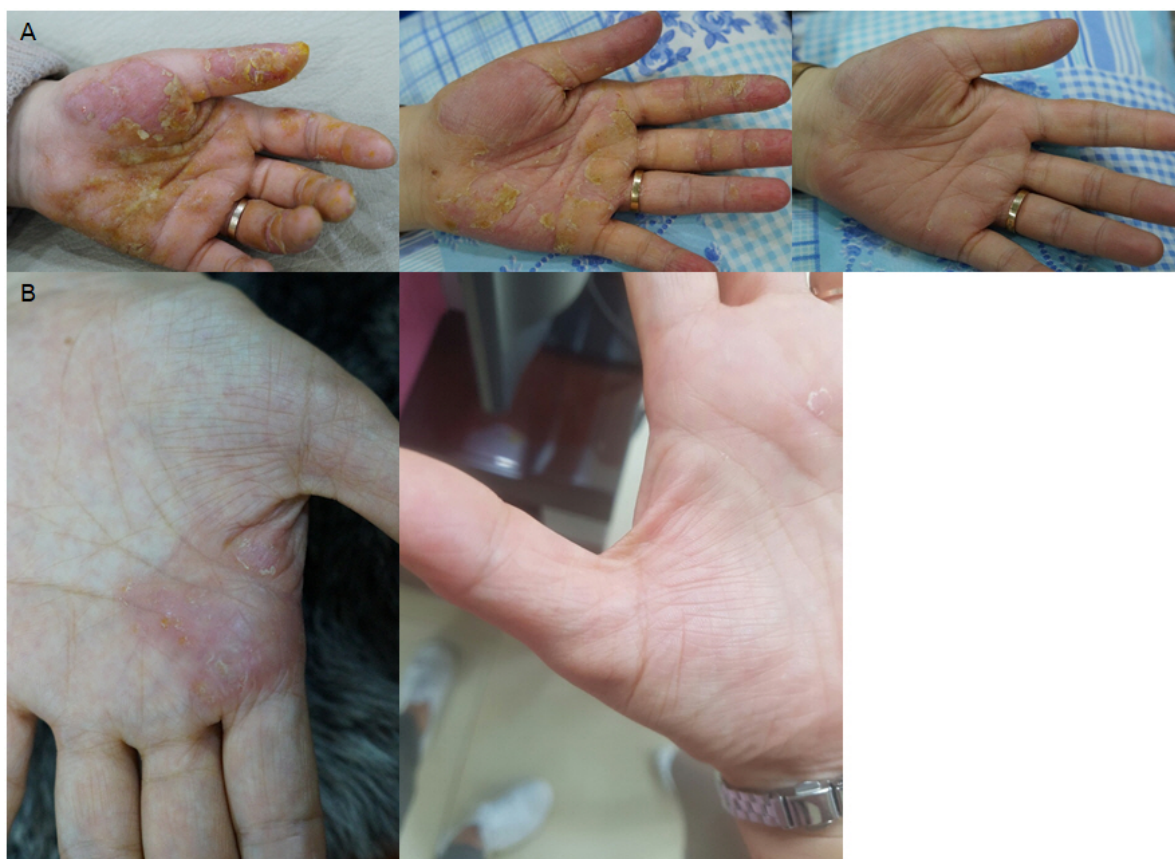

Figure 1. Hand eczema before and after treatment. (A) Case 1: before, 1 week after treatment, and after treatment; (B) Case 2: before and after treatment.

in case 1, but pruritic rash and blisters decreased after treatments (Fig. 1). The lesions completely improved after 1 month and 1 week of treatments, respectively, and did not recur at 1 year of follow-up (Fig. 2). One or two blisters were occasionally observed after case 1 consumed fried chicken but disappeared after food control.

DISCUSSION

This is the first case report of patients with hand eczema being treated by mesotherapy with SVP. Although the etiology remains unclear, previous studies have revealed that vesicle formation in hand eczema ultimately causes a disruption of the epidermal barrier and alters the skin-barrier function, allowing additional external noxious agents of microbial, chemical, or physical origin to enter the skin and aggravate and perpetuate the disease [10]. Accordingly, prevention or treatment of infection has become one of the treatment targets [1, 11]. Additionally, a steep imbalance in the osmotic gradient is a key factor driving skin dehydration in patients with hand eczema once the disease becomes chronic. Overexpression of water/glycerol channel proteins in keratinocytes may bridge the abundantly hydrated dermis and basal epidermis to the outer environment, allowing cutaneous water and glycerol to flow outward and alter cell permeability [3].

Although less than 0.01% of compounds in snake venom have been identified and characterized, snake venom is known

to alter the permeability of cell membranes or exert antimicrobial activity. Phospholipase A2 enzymes have important effects on cell membrane permeability by cleaving the *sn*-2 bond in glycerophospholipids to release free fatty acids and lysophospholipids [4]. In addition, numerous components in the snake venom have antibacterial properties, including L-amino acid oxidase and phospholipase A2, which hydrolyze phospholipids and may act on the bacterial cell surface. The antiparasitic effect may be linked to the activity of snake venom L-amino acid oxidase. SVP may enhance skin-barrier function and block secondary infections through its antimicrobial activity in the treatment of hand eczema. In addition, most of these components are peptides that affect a large number of targets, such as membrane receptors or ion channels with high selectivity and affinity; thus, they are expected to be highly efficacious [4]. SVP is a good candidate for treating skin diseases, such as hand eczema.

Mesotherapy enables direct trans-epidermal transport of substances in the dermis or deeper skin layers [7]. Even a small amount of drug can be dispersed and applied to the target intradermal area immediately with mesotherapy. Using mesotherapy, SVP can be injected through the lipid barrier and stratum corneum without chemical decomposition on the epidermis surface [7], particularly for treating a disease, such as hand eczema, in which the thicker epidermis and even thicker overlying horny layer must be bypassed. Additionally, this direct drug delivery method is inexpensive and requires minimal training for physicians [7]. Our patients did not show

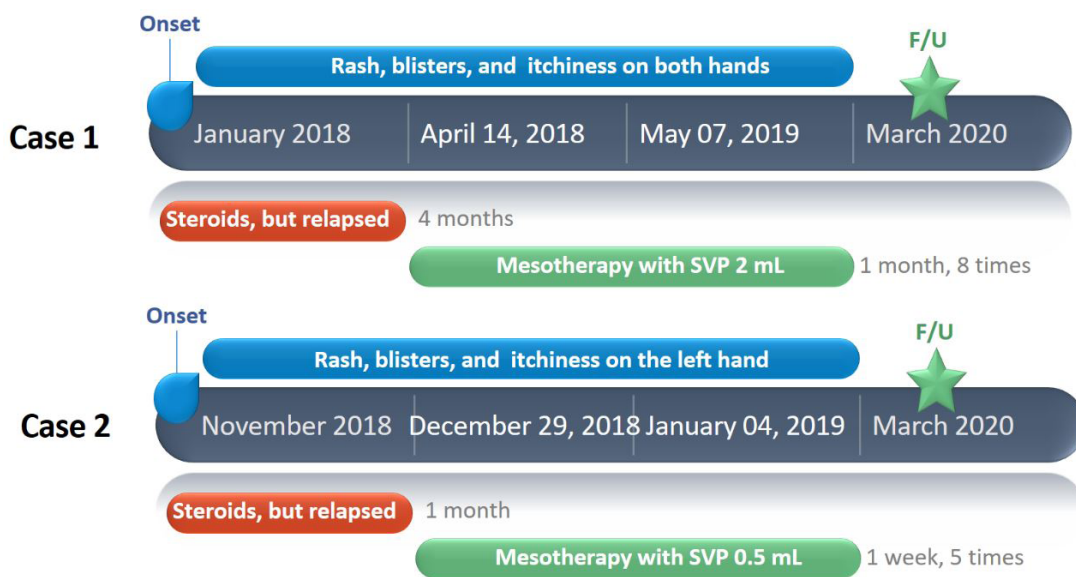


Figure 2. Flow chart depicting treatment in Case 1 and Case 2; SVP, snake venom pharmacopuncture.

recurrence of hand eczema following treatment. One of the major advantages of this treatment would be the prevention of relapses. In the cases described here, hand eczema, for which steroid treatment was previously ineffective, was successfully treated by mesotherapy with SVP. Mesotherapy with SVP can be an effective, safe, and simple treatment with no side effects. Further studies are needed to investigate whether mesotherapy with snake venom is efficient for treating hand eczema.

SUPPLEMENTARY MATERIALS

Supplementary data is available at <https://doi.org/10.3831/KPI.2020.23.4.273>.

Supplemental Video. Video showing the procedure of mesotherapy with snake venom pharmacopuncture for the treatment of hand eczema.

ACKNOWLEDGMENT

This work was supported by a grant from the Korea Institute of Oriental Medicine (KSN2013210).

CONFLICT OF INTEREST

The authors have no conflicts of interest to declare.

ORCID

Sungha Kim, <https://orcid.org/0000-0001-5542-3850>

Jinbok Lee, <https://orcid.org/0000-0003-2725-4062>

Minseop Shin, <https://orcid.org/0000-0002-1698-8987>

REFERENCES

1. Coenraads PJ. Hand eczema. *N Engl J Med*. 2012;367(19):1829-37.
2. Wollina U. Pompholyx: what's new? *Expert Opin Investig Drugs*. 2008;17(6):897-904.
3. Soler DC, Bai X, Ortega L, Pethukova T, Nedorost ST, Popkin DL, et al. The key role of aquaporin 3 and aquaporin 10 in the pathogenesis of pompholyx. *Med Hypotheses*. 2015;84(5):498-503.
4. Mohamed Abd El-Aziz T, Garcia Soares A, Stockand JD. Snake venoms in drug discovery: valuable therapeutic tools for life saving. *Toxins (Basel)*. 2019;11(10):564.
5. Song SY, Bae K, Shin KH, Yoo HS. A case series of snake venom pharmacopuncture for chemotherapy-induced peripheral neuropathy: a retrospective observational study. *J Pharmacopunct*. 2017;20(4):280-6.
6. Lee JS, Kwon GR. The study on the snake venom. *J Pharmacopunct*. 1999;2(1):73-91.
7. Plachouri KM, Georgiou S. Mesotherapy: safety profile and management of complications. *J Cosmet Dermatol*. 2019;18(6):1601-5.
8. Lee JC, Daniels MA, Roth MZ. Mesotherapy, microneedling, and chemical peels. *Clin Plast Surg*. 2016;43(3):583-95.
9. Gill J, Pratt M. A severe case of recalcitrant pompholyx. *J Cutan Med Surg*. 2015;19(5):494-7.
10. Schwarz T. No eczema without keratinocyte death. *J Clin Invest*. 2000;106(1):9-10.
11. Wollina U. Pompholyx: a review of clinical features, differential diagnosis, and management. *Am J Clin Dermatol*. 2010;11(5):305-14.