



Endogenous panophthalmitis in a patient with COVID-19 during hospitalization in an intensive care unit: A case report

Sinsucha Boontantrapiwat^a, Duangnate Rojanaporn^b, Weerawan Chokthaweesak^b, Naris Kitnarong^{c,*}

^a Krathumbaen Hospital, Thailand

^b Department of Ophthalmology, Faculty of Medicine Ramathibodi Hospital, Mahidol University, Thailand

^c Department of Ophthalmology, Faculty of Medicine Siriraj Hospital, Mahidol University, Thailand

ARTICLE INFO

Keywords:

COVID-19
Endogenous panophthalmitis
Enucleation
Endophthalmitis
Ocular manifestation
Salmonella septicemia

ABSTRACT

Purpose: To report a case of endogenous panophthalmitis in a patient with COVID-19 during treatment in an Intensive Care Unit.

Observation: A 64-year-old woman with COVID-19 and *Salmonella* septicemia presented with decreased visual acuity, ocular pain, and proptosis in her right eye after treatment with favipiravir, intravenous dexamethasone, and ceftriaxone. An ocular examination of her right eye revealed periorbital tenderness, exophthalmos, and corneal haze. The ultrasonography showed a subretinal abscess. Her right eye lost light perception vision and underwent enucleation. Microbiologic evaluation of the enucleated right eye was negative for organisms.

Conclusions and importance: Patients with COVID-19 may develop severe ocular involvement after COVID-19 due to a generalized reduction in immunity. Comorbidities and intensive care unit treatments can predispose COVID-19 patients to endogenous panophthalmitis.

1. Introduction

In March 2020, Thailand was the first country outside China to report patients with severe acute respiratory syndrome coronavirus 2 (SARS-CoV-2). By January 2022, 2 308 615 people had been infected with the novel coronavirus (COVID-19), and 21 898 had died from COVID-19 or its consequences.¹ The disease has been studied intensively. COVID-19 affects the respiratory system primarily and may have severe pulmonary and extra-pulmonary complications.

Ocular involvement has been reported in patients with COVID-19 infection during the condition and its recovery phase.²⁻⁴ Treatment of COVID-19 during hospitalization may increase the susceptibility of COVID-19 patients to several ocular consequences and complications. Endogenous panophthalmitis is a rare sight-threatening condition usually associated with patients with comorbidities such as diabetes mellitus, intravenous drug use, or a systemic immunocompromised state.^{5,6} Patients hospitalized with COVID-19 are vulnerable to endophthalmitis and panophthalmitis due to general predisposing risk factors of being in the intensive care unit and the use of immunocompromising

therapeutics such as corticosteroids. We report a case of endogenous panophthalmitis in a patient with COVID-19 during hospitalization in an intensive care unit in Thailand.

2. Case report

A 64-year-old, unvaccinated woman with COVID-19 (presumed to be the delta-serotype consistent with becoming infected during the second pandemic wave) was admitted to the intensive care unit with severe acute pneumonia and septicemia. Her underlying diseases were diabetes mellitus, essential hypertension, and a recent pons infarction. She had been treated with favipiravir, intravenous dexamethasone, oxygen cannula, and intravenous ceftriaxone as antibiotic prophylaxis. Once the hemoculture revealed *Salmonella* subgroup D, ceftriaxone was replaced by intravenous meropenem. COVID-19 was confirmed to be undetected 3 weeks after admission by real-time polymerase chain reaction (RT-PCT).

On the 29th day after admission, she developed fever, decreased vision, ocular pain, and proptosis in her right eye. An ocular

* Corresponding author. Department of Ophthalmology Faculty of Medicine Siriraj Hospital, Mahidol University 2 Prannok Road, Bangkoknoi, Bangkok, 10700, Thailand.

E-mail addresses: naris.kit@mahidol.ac.th, kitnarong.n@gmail.com (N. Kitnarong).

<https://doi.org/10.1016/j.ajoc.2022.101707>

Received 18 June 2022; Received in revised form 29 August 2022; Accepted 9 September 2022

Available online 16 September 2022

2451-9936/© 2022 Published by Elsevier Inc. This is an open access article under the CC BY-NC-ND license (<http://creativecommons.org/licenses/by-nc-nd/4.0/>).

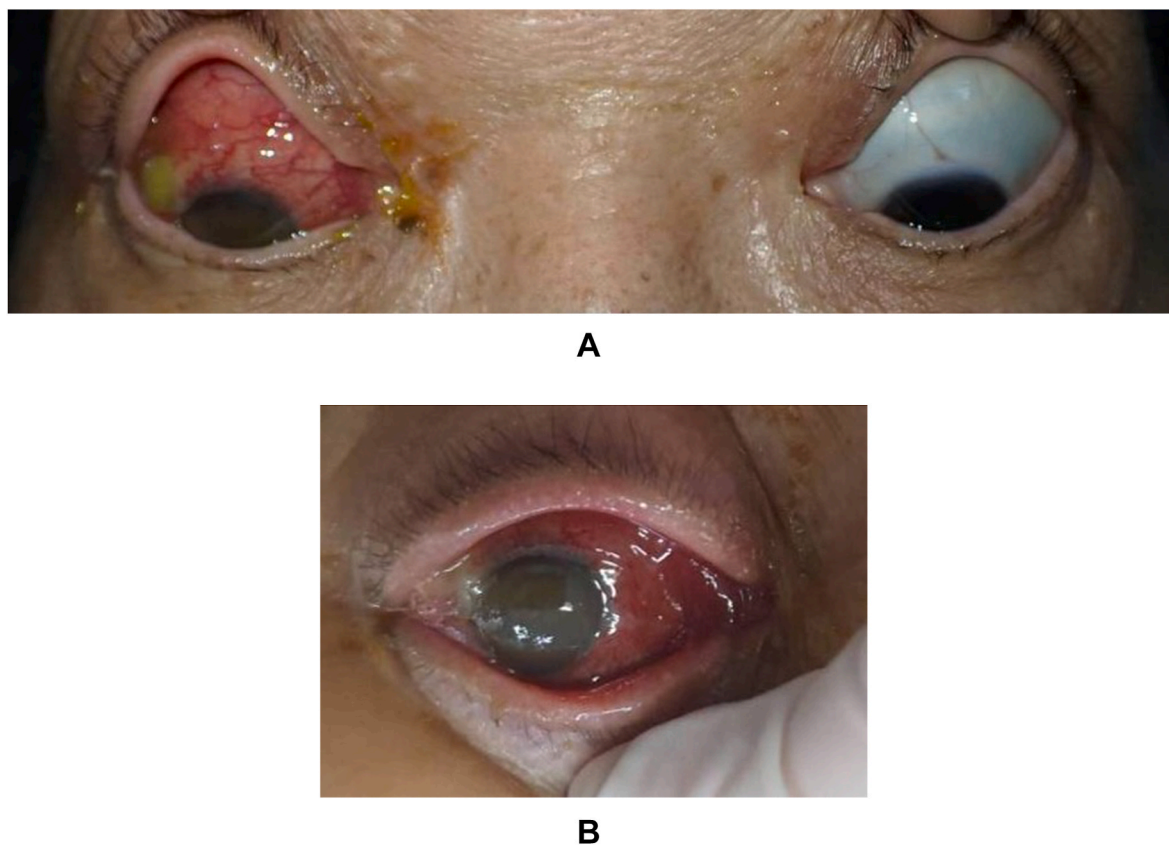


Fig. 1. A and 1B. Clinical presentation of Covid-19 patient with panophthalmitis in the right eye on the 29th day after admission to the intensive care unit for Covid-19 treatment.

examination revealed visual acuity (light perception in the right eye and 20/30 in the left eye); periorbital tenderness and swelling; mild exophthalmos; limited extraocular movement; marked chemosis; and a generalized corneal haze. Due to corneal opacity, the anterior chamber, pupil, lens and posterior segment of the right eye could not be evaluated. Her left eye was unremarkable. The ocular manifestations are illustrated in Fig. 1A and B.

A computed tomography (CT) scan of the orbit revealed exophthalmos, relatively thickened and enhanced right anterior periorbital soft tissue, minimal fat haziness of the right intra-extraconal fat, and suspected pre- and postseptal cellulitis. Fig. 2A, B, 2C, and 2D present the orbit CT scan. Ultrasonography of the right eye showed normal globe contour, heterogeneous vitreous debris (a), subretinal and choroidal abscess (b), and total retinal detachment (c) (Fig. 3A and B). A diagnosis of endogenous endophthalmitis was made. Topical antiglaucoma medications and moxifloxacin were administered, and intravenous ciprofloxacin was initiated.

The patient lost light perception vision with an uncontrolled ocular infection and subsequently underwent enucleation of the right eye. Microbiologic evaluation of the enucleated right eye was negative for organisms. No additional abscesses were detected systemically. The patient was discharged once COVID-19 was reconfirmed to be negative by RT-PCR and her medical condition stabilized.

3. Discussion

Since January 2020, several ocular manifestations have been reported in patients with COVID-19.² Ocular involvement may result from direct invasion of the COVID-19 virus and the immune-mediated effects it induces, which can be present at any stage of the disease.³ Furthermore, intensive management of COVID-19 during hospitalization predisposes patients to comorbidities and complications.⁷

Conjunctivitis is one of the most common ocular manifestations in COVID-19 patients.⁴ To our knowledge, this is the first case report of panophthalmitis in a patient with COVID-19. Endogenous endophthalmitis accounts for approximately 2%–8% of cases of endophthalmitis^{8,9} and can in rare circumstances lead to a more severe panophthalmitis. The causative organisms differ between Western and Asian countries. In Western countries, gram-positive organisms predominate, whereas gram-negative organisms are more common in Asian countries.^{5,6,10} Panophthalmitis can be exogenous (associated with ocular trauma, ocular surgery, or ocular infection) or endogenous (hematogenous spread of microorganisms from a primary location elsewhere in the body to the eye). Panophthalmitis is often found in immunocompromised patients or individuals with chronic debilitating illnesses.^{11,12} Its clinical signs include extensive intraocular inflammation with intraorbital tissue involvement.¹³ Although vitreous culture may be supportive, endogenous panophthalmitis is a clinical diagnosis in the setting of positive serum cultures.¹⁴

In general, intensive care and compromised immunity predispose patients to bacterial infection. Additionally, steroids can promote the development of bacterial and viral septicemia.¹⁵ The hypothesis of delayed organ infection in patients with COVID-19 is based on a generalized lowering of immunity by the disease itself, the use of immunosuppressants, and the multisystem inflammatory syndrome related to COVID-19.^{2,16} In our case, the patient had COVID-19 infection treated with corticosteroids, Salmonella septicemia and diabetes mellitus as predisposing risk factors for endogenous endophthalmitis.

Endogenous panophthalmitis is commonly bacterial. Unfortunately, we did not perform vitreous RT-PCR for COVID-19, and we could not document a bacterial or viral causative organism from the enucleated eye. The absence of a detectable causative organism may have resulted from the patient's previous treatment with intravenous antibiotics and anti-COVID-19 medications. Identifying infection's focus in endogenous

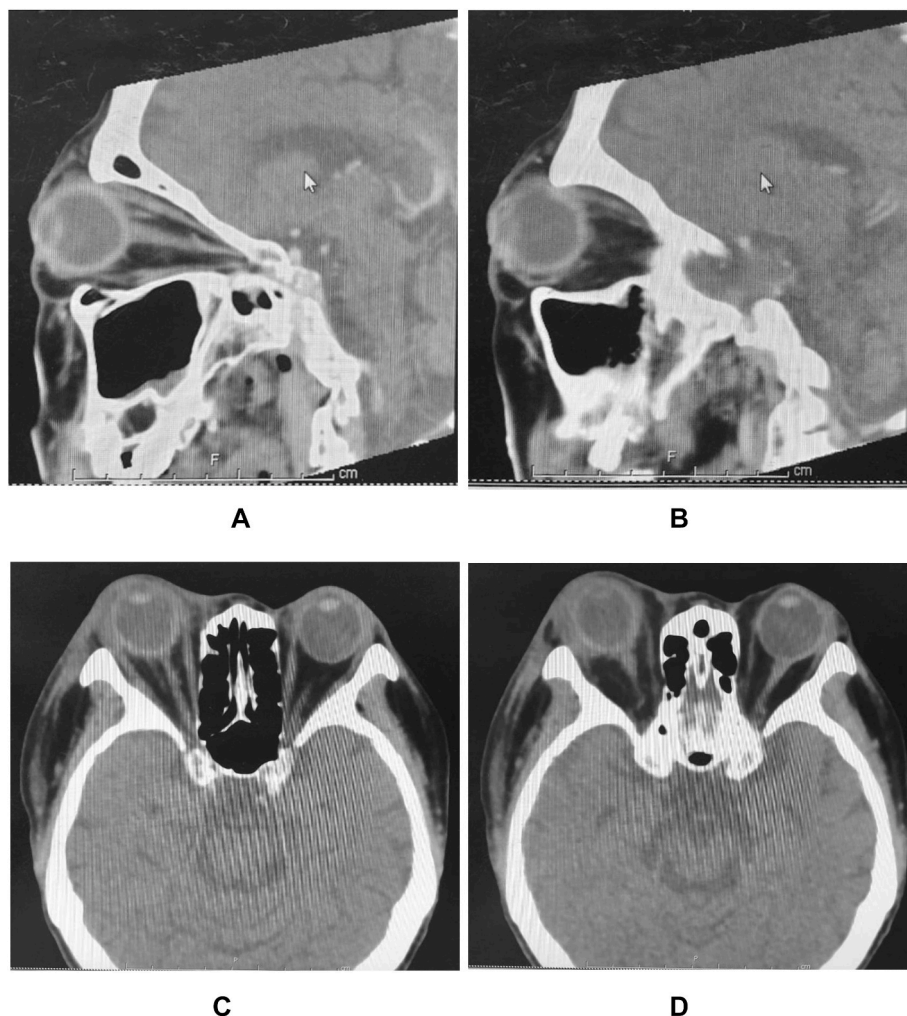


Fig. 2. A, 2B, 2C, and 2D: A computed tomography scan of the orbit revealed exophthalmos, thickened enhanced right anterior peri-orbital soft tissue, minimal fat haziness of right intra-extraconal fat, relatively thickened enhanced right anterior peri-orbital soft tissue, and suspected pre- and postseptal cellulitis.

panophthalmitis is typically challenging, especially in cases with COVID-19. The evidence strongly suggested that our patient had endogenous panophthalmitis due to *Salmonella* septicemia. *Salmonella* is a rod-shaped (bacillus) gram-negative Enterobacteriaceae bacterium. *Salmonella* serotypes can be divided into typhoidal and nontyphoidal subgroups. Some serotypes cause illness, most of which can be resolved without antibiotics.¹⁷ Endogenous panophthalmitis caused by *Salmonella* is rare.^{18,19} Early diagnosis and rapid systematic and local eye treatment are essential to reduce morbidity and mortality in panophthalmitis. Early systemic antibiotics in combination with intravitreal antibiotics are the mainstay of treatment in endogenous panophthalmitis.^{14,20}

The Endophthalmitis Vitrectomy Study recommended early vitrectomy as an alternative treatment for postoperative endophthalmitis in patients with poor visual acuity.²¹ Our patient received intravenous meropenem as a treatment for *Salmonella* septicemia. However, the meropenem was replaced by intravenous ciprofloxacin after the patient was diagnosed with endogenous panophthalmitis due to the superior ocular penetration of ciprofloxacin.²² We did not administer an intravitreal antibiotic injection or perform a vitrectomy, given that the patient's medical condition was so severe that she could not be moved out of the intensive care unit. Following intensive treatment, she lost light perception with evidence of total retinal detachment and subretinal abscess by ultrasonography. We did not consider vitrectomy but opted for enucleation despite an uncontrolled infection. However, most

endogenous endophthalmitis/panophthalmitis cases have been reported to have a poor prognosis despite appropriate treatment.²³ In many cases, evisceration or enucleation is required as empirical treatment, as with our patient.

4. Conclusions

Patients with COVID-19 may develop severe ocular involvement after COVID-19 due to a generalized reduction in immunity. Comorbidities, intensive care unit treatments, and immunosuppressants can predispose COVID-19 patients to endogenous endophthalmitis/panophthalmitis.

Patient consent

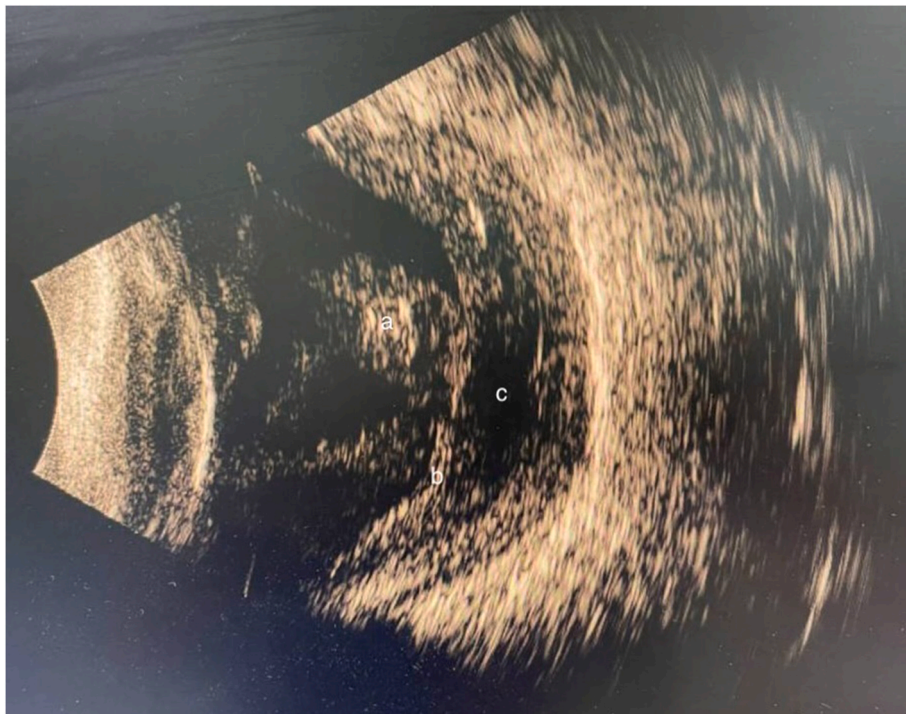Written informed consent for publication was given by the patient.

Conflict-of-interest declaration

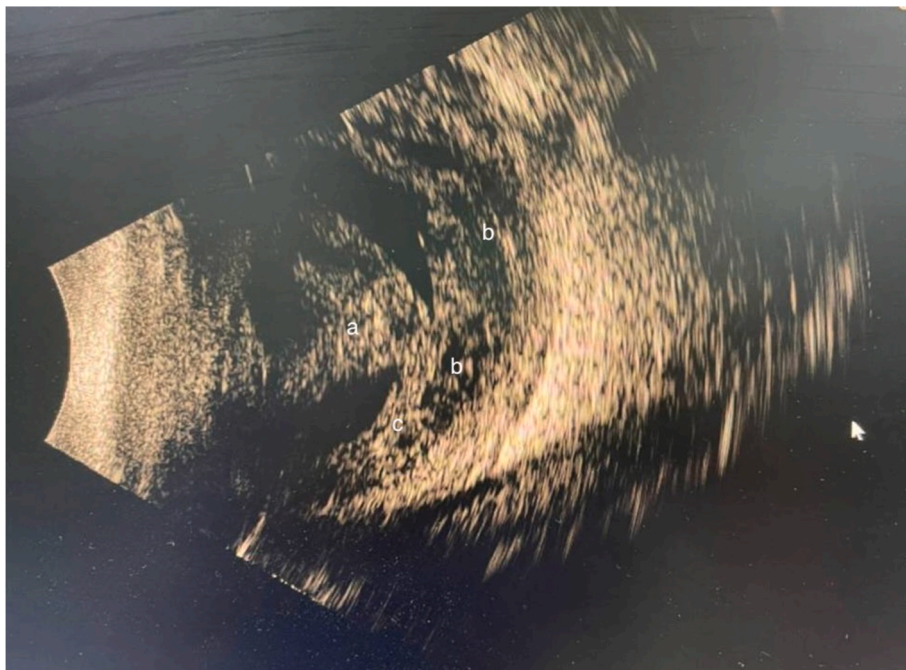
The authors declare there are no conflicts of interest related to this study.

Funding disclosure

This was an unfunded study.



A



B

Fig. 3. A and 3B. Ultrasonography of the right eye showed normal globe contour, heterogenous vitreous debris (a), subretinal and choroidal abscess (b), and total retinal detachment (c).

Authorship

All authors attest that they meet the current ICMJE criteria for Authorship.

Acknowledgments

We thank the patient for her contribution. We are also indebted to Mr David Park for English-language editing.

References

1. The department of disease control of Thailand. The coronavirus disease 2019 news release. "The Disease Situation in Thailand on January 7th, 2022". Available at: <http://ddc.moph.go.th/viralpneumonia/eng/file/situation/situation-no723-070165.pdf>. January 7, 2022.
2. Bertoli F, Veritti D, Danese C, et al. Ocular findings in COVID-19 patients: a review of direct manifestations and indirect effects on the eye. *J Ophthalmol*. 2020;2020, 4827304.
3. Hu K, Patel J, Swiston C, Patel BC. *Ophthalmic Manifestations of Coronavirus (COVID-19)*. StatPearls. Treasure Island (FL); 2022.
4. Sen M, Honavar SG, Sharma N, Sachdev MS. COVID-19 and eye: a review of ophthalmic manifestations of COVID-19. *Indian J Ophthalmol*. Mar 2021;69(3): 488–509.
5. Lee S, Um T, Joe SG, et al. Changes in the clinical features and prognostic factors of endogenous endophthalmitis: fifteen years of clinical experience in Korea. *Retina*. May 2012;32(5):977–984.
6. Wong JS, Chan TK, Lee HM, Chee SP. Endogenous bacterial endophthalmitis: an east Asian experience and a reappraisal of a severe ocular affliction. *Ophthalmology*. Aug 2000;107(8):1483–1491.
7. Shah KK, Venkatramani D, Majumder PD. A case series of presumed fungal endogenous endophthalmitis in post COVID-19 patients. *Indian J Ophthalmol*. May 2021;69(5):1322–1325.
8. Jackson TL, Eykyn SJ, Graham EM, Stanford MR. Endogenous bacterial endophthalmitis: a 17-year prospective series and review of 267 reported cases. *Surv Ophthalmol*. Jul-Aug 2003;48(4):403–423.
9. Greenwald MJ, Wohl LG, Sell CH. Metastatic bacterial endophthalmitis: a contemporary reappraisal. *Surv Ophthalmol*. Sep-Oct 1986;31(2):81–101.
10. Odouard C, Ong D, Shah PR, et al. Rising trends of endogenous Klebsiella pneumoniae endophthalmitis in Australia. *Clin Exp Ophthalmol*. Mar 2017;45(2): 135–142.
11. Budoff G, Thangamathesvaran L, Zarbin MA, Bhagat N. Bacterial endogenous endophthalmitis in bacteremic inpatients. *Ophthalmol retina*. Nov. 2019;3(11): 971–978.
12. Callegan MC, Engelbert M, Parke 2nd DW, Jett BD, Gilmore MS. Bacterial endophthalmitis: epidemiology, therapeutics, and bacterium-host interactions. *Clin Microbiol Rev*. Jan 2002;15(1):111–124.
13. Suwan Y, Preechawai P. Endogenous Klebsiella panophthalmitis: atypical presentation. *J Med Assoc Thai*. Jun 2012;95(6):830–833.
14. Durand ML. Bacterial and fungal endophthalmitis. *Clin Microbiol Rev*. Jul 2017;30(3):597–613.
15. Abdelkader M, Elshafei AMK, Nassar MM, Abu Elela MA, Abdallah RMA. Combined endophthalmitis and orbital cellulitis in patients with corona virus disease (COVID-19). *J Ophthalmic Inflamm Infect*. Sep 15 2021;11(1):27.
16. Huang C, Wang Y, Li X, et al. Clinical features of patients infected with 2019 novel coronavirus in Wuhan, China. *Lancet*. Feb 15 2020;395(10223):497–506.
17. Gal-Mor O, Boyle EC, Grassl GA. Same species, different diseases: how and why typhoidal and non-typhoidal Salmonella enterica serovars differ. *Front Microbiol*. 2014;5:391.
18. Rachitskaya AV, Flynn HW, Davis JL. Endogenous endophthalmitis caused by salmonella serotype B in an immunocompetent 12-year-old child. *Arch Ophthalmol*. Jun 2012;130(6):802–804.
19. Sinha MK, Jalali S, Nalamada S. Review of endogenous endophthalmitis caused by Salmonella species including delayed onset Salmonella typhi endophthalmitis. *Semin Ophthalmol*. May-Jul 2012;27(3-4):94–98.
20. Chai HX, Samsudin A, Jayaraman K, Chong MF. The noxious intruder of the eye: endogenous Klebsiella panophthalmitis. *Cureus*. Oct 2021;13(10), e18725.
21. Forster RK. The endophthalmitis vitrectomy study. *Arch Ophthalmol*. Dec 1995;113(12):1555–1557.
22. Madu AA, Mayers M, Perkins R, et al. Aqueous and vitreous penetration of ciprofloxacin following different modes of systemic administration. *Exp Eye Res*. Aug 1996;63(2):129–136.
23. Agarwal M, Sachdeva M, Pal S, Shah H, Kumar RM, Banker A. Endogenous endophthalmitis A complication of COVID-19 pandemic: a case series. *Ocul Immunol Inflamm*. May 19 2021;29(4):726–729.