

A Comparison of Endoscopic Ultrasound Guided Biopsy and Positron Emission Tomography with Integrated Computed Tomography in Lung Cancer Staging

S.S. LARSEN⁽¹⁾, P. VILMANN⁽¹⁾, M. KRASNIK⁽²⁾, ASGER DIRKSEN⁽³⁾,
P. CLEMENTSEN⁽³⁾, BIRGIT G. SKOV⁽⁴⁾, GRETE KRAG JACOBSEN⁽⁴⁾,
U. LASSEN⁽⁵⁾, ANNIKA EIGTVED⁽⁶⁾, ANNE KIIL BERTHELSEN⁽⁶⁾, J.
MORTENSEN⁽⁷⁾, LISELOTTE HOEJGAARD⁽⁷⁾

⁽¹⁾Department of Surgical Gastroenterology; ⁽²⁾Department of Cardio-Thoracic Surgery; ⁽³⁾Department of Pulmonology; ⁽⁴⁾Department of Pathology; Gentofte University Hospital, Copenhagen, Denmark.
⁽⁵⁾Department of Oncology, ⁽⁶⁾PET & Cyclotron Unit; ⁽⁷⁾Department of Clinical Physiology, Rigshospitalet, Copenhagen, Denmark.

ABSTRACT Background and study aims: Exact staging of patients with non-small-cell lung cancer (NSCLC) is important to improve selection of resectable and curable patients for surgery. Positron emission tomography with integrated computed tomography (PET/CT) and endoscopic ultrasound guided fine needle aspiration biopsy (EUS-FNA) are new and promising methods, but indications in lung cancer staging are controversial. Only few studies have compared the 2 methods. The aim of this study was to assess and compare the diagnostic values of PET/CT and EUS-FNA for diagnosing advanced lung cancer in patients, who had both procedures performed. **Patients and methods:** 27 patients considered to be potential candidates for resection of NSCLC underwent PET/CT and EUS-FNA. Diagnoses were confirmed either by open thoracotomy, mediastinoscopy or clinical follow-up. Advanced lung cancer was defined as tumour-stage \geq IIIA(N2), corresponding to T4- and/or N2-N3- and/or M1 disease. Diagnostic values of PET/CT and EUS-FNA, with regard to the diagnosis of advanced lung cancer, were assessed and compared. **Results:** The sensitivity of PET/CT and EUS-FNA were respectively 60% and 60% for T4 disease, 56% versus 100% for N2-N3 disease ($p=0.12$) and 100% versus 33% for M1 disease ($p=0.50$). For diagnosing advanced lung cancer PET/CT had a sensitivity of 79%, specificity of 61%, positive predictive value (PPV) of 69%, negative predictive value (NPV) of 73%, and an accuracy of 70%. EUS-FNA had a sensitivity of 79%, specificity of 100%, PPV of 100%, NPV of 81%, and an accuracy of 89% for advanced lung cancer. **Conclusions:** PET/CT and EUS-FNA had a comparable sensitivity and NPV for diagnosing advanced lung cancer, but EUS-FNA had superior specificity and PPV. The two methods seem to complement each other.

KEY WORDS EUS-FNA, PET, PET/CT, mediastinum, lung cancer

Introduction

Surgical resection is the best chance of cure for most patients with non-small-cell lung cancer (NSCLC). Up to 10% of lung cancer operations result in explorative thoracotomies without tumour resection, and an additional 25-35% of the operations are unsuccessful because of postoperative recurrent disease [1,2], apparently because the stage of the disease is more advanced than expected preoperatively. As a consequence of this, and with the introduction of stage-dependent multi-modality treatment of NSCLC, the importance of exact staging of the disease is stressed.

Chest computed tomography (CT) alone is not recognised as proof of advanced lung cancer, because of inadequate accuracy of this examination [3].

Positron emission tomography (PET) is a metabolic imaging modality utilising increased

uptake of the glucose analogue ^{18}F -fluoro-2-deoxy-D-glucose (FDG) in cancer cells. PET is non-invasive and offers the possibility of whole body scanning and therefore has the potential to detect distant metastases. Several studies have reported that PET in addition to CT increases the accuracy of lung cancer staging [3-5] and decreases the need for invasive procedures [6]. One multi-centre randomised trial (including 188 patients) concluded that the addition of PET to a conventional staging strategy prevented unnecessary surgery in one out of 5 patients with suspected NSCLC [7]. Concerning mediastinal staging the main value of PET is its high negative predictive value [3], suggesting that PET-negative patients might not need invasive mediastinal staging before surgery with curative intent. However, a considerable false positive rate of 10-30% [5,3,8,9] necessitates a tissue diagnosis of

mediastinal spread suggested by PET, before a patient can be rejected from surgery with curative intention.

The latest development in PET-technology is to integrate the functional imaging of PET with the anatomical imaging of CT in a PET/CT-scanner. A recent study reported a significantly improved diagnostic accuracy of lung cancer staging, when integrated PET/CT was compared with the 2 imaging methods separated [10].

During the past decade endoscopic ultrasound guided fine needle aspiration biopsy (EUS-FNA) has been introduced in respiratory medicine as a method for obtaining biopsy specimens from mediastinal structures. A number of small and medium sized original studies have been published [11-19], the majority presenting retrospective results of EUS-FNA performed in patients selected by CT. The diagnostic values for such patients are relatively uniform with a high sensitivity of around 90% for mediastinal malignancy. Very few complications have been reported.

PET/CT and EUS-FNA are both promising methods, but their final positions in an evidence based strategy for lung cancer staging are not yet defined. When each method is evaluated separately, a number of studies indicate that the routine use of each method in lung cancer staging seems reasonable. However, only few studies have compared PET and EUS-FNA in the same patients [12,13,20,21], and to our knowledge, no studies have compared PET/CT and EUS-FNA. Whether one of the methods obviates the need for the other, is unknown.

The aim of the present study was to assess and compare diagnostic values of PET/CT and EUS-FNA for diagnosing advanced lung cancer in a group of patients who were subjected to both procedures.

Material and methods

Patients

The patients were selected from a randomised controlled trial as those who had both PET/CT and EUS-FNA performed. The purpose of the randomised trial is to compare routine use of PET/CT and EUS-FNA in lung cancer staging with a conventional staging strategy. This study is still in progress. 27 patients admitted to the Department of Respiratory Diseases, Gentofte University Hospital, Copenhagen, had both PET/CT and EUS-FNA performed during a 2 year period (2002-2004). All patients had verified (n=25) or suspected (n=2) NSCLC and fulfilled the in- and exclusion criteria outlined in Table 1.

Table 1 Inclusion and exclusion criteria

1. Inclusion criteria	1. Patients with suspected or newly diagnosed NSCLC, who after CT, bronchoscopy, TBNAB, (TTNAB), lung function tests and general medical examination are candidates for invasive staging (mediastinoscopy or thoracotomy) prior to curative intended surgery.
2. Exclusion criteria:	1. Inoperability because of poor medical conditions 2. Refusal of surgery 3. Verified N2/3-, T4- or M1-disease or small-cell lung cancer 4. Pregnancy 5. Age < 18 years

NSCLC=Non-small-cell lung cancer; CT=computer tomography; TBNAB=trans-bronchial needle aspiration biopsy; TTNAB= trans-thoracal needle aspiration biopsy.

Prior to inclusion, all patients had undergone chest CT, bronchoscopy including trans-bronchial needle aspiration biopsy (TBNAB), clinical evaluation and lung function tests. Trans-thoracic needle aspiration biopsy (TTNAB) was performed, if indicated. After these examinations all patients were considered to be potential candidates for resection of NSCLC.

PET/CT and EUS-FNA were then offered prior to conventional invasive staging (mediastinoscopy and thoracotomy). During the study period mediastinoscopy was performed regardless of CT-findings prior to all lung cancer operations with curative intent.

Baseline characteristics including CT-stages are outlined in Table 2.

Table 2 Baseline characteristics of included patients

Basic characteristics of included patients (n=27)	
Age (years, mean, SD)	63 (7)
Sex	
women	13 (48%)
men	14 (52%)
Performance status	
0-1	26 (96%)
2-3	1 (4%)
Definite diagnosis of NSCLC	25 (93%)
CT stage (I-IV)	
IA	3 (11%)
IB	2 (7%)
IIIA	6 (22%)
IIIB	11 (41%)
IV	5 (19%)

Data are number of patients (%) unless otherwise stated. Performance status: 0=no symptoms; 1=symptoms, normal function; 2=symptoms, in bed < 50% of day-time; 3=symptoms, in bed > 50% of daytime. NSCLC=non-small-cell lung cancer; CT=computed tomography

All patients gave signed informed consent in accordance with the requirements set by The Ethical Committee of Copenhagen County, which had approved the study.

Procedures

PET/CT

The PET/CT scans were performed in the PET & Cyclotron Unit, Department of Clinical Physiology & Nuclear Medicine, Rigshospitalet, Copenhagen. After a fasting period of 6 hours, the patient was given an intravenous injection of approximately 400 MBq FDG (effective dose equivalent 8 mSv). Approximately one hour later a whole body PET/CT scan was performed on a GE Discovery LS PET/CT scanner (General Electric Medical Systems, Milwaukee, WI, USA). The actual time of FDG-administration and the time of the commencement of the scanning were recorded. The CT scan was performed first with the multidetector spiral CT scanner with 4 slices per rotation as a diagnostic CT scan with intravenous contrast media (100 ml Omnipaque 300 mg Iodine per ml, Amersham Health Denmark). Hereafter, the PET scan was performed with the patient lying in the same position with an emission scan of 3 minutes per bed position. PET data were reconstructed by filtered back projection and with the OS-EM iterative reconstruction method using the CT data for attenuation correction. Image fusion was done using the automatic algorithm of the GE eNTEGRA software.

PET/CT data were analysed visually and evaluated by a nuclear medicine physician and a radiologist in collaboration, with a mutual conclusion signed by both experts. The location of abnormalities in the mediastinum was recorded according to Mountain/Dresler Regional Nodal Stations for Lung Cancer Staging [22].

EUS-FNA Procedure

EUS-FNA was performed during the same general anaesthesia as the mediastinoscopy (EUS-FNA first), when possible. Otherwise EUS-FNA was performed on an outpatient basis with the patient in conscious sedation using Midazolam (Dormicum, Roche). The EUS examination was performed with a flexible echo-endoscope with a curved array transducer, an adjustable ultrasonic frequency of 5 or 10 MHz and a penetration depth of 7-8 cm (an Olympus ultrasonic endoscope (GF-UC160P-OL5) connected to an Olympus processor (EU-C60) or an Olympus (GF-UC140P-AL5) ultrasonic endoscope connected to an Aloka ultrasound processor (Prosound 5000) or a Pentax (EG 3830) ultrasonic endoscope connected to an Hitachi ultrasound processor (EUB 6000)). The left adrenal gland and left liver lobe were routinely inspected first, and if a mass was identified, it was sampled with FNA first. Lymph nodes were characterized according to criteria suggestive of malignancy (round shape, hypoechoic, sharp margin and size > 1cm). The location was classified according to

Mountain/Dresler Regional Nodal Stations for Lung Cancer Staging [22]. All lymph nodes with at least one criterion suggestive of malignancy were sampled (N3- before N2-lymph nodes). A 22 Gauge needle (GIP/MEDI-Globe, Sono-tipII) was used for the biopsy. EUS-FNA was performed via the oesophagus with 1-3 passes of the needle per lesion. The aspirated material was smeared onto glass slides, air-dried and stained for a cytological evaluation. The patients were observed for 1-2 hours at the hospital after the procedure. All EUS-FNA examinations were performed by one of the author's (PV). Possible complications were recorded up to one year after the procedure.

The cytological specimens were stained according to the May-Grünwald-Giemsa method. Microscopy was performed by 2 experienced cyto-pathologists. The aspirates were considered malignant only if definitely malignant cells were present.

Confirmation of PET/CT and EUS-FNA diagnoses

A histo-/cytology diagnosis from PET-positive lesions that would confer inoperability was required to confirm or refute, whether they were true positive for lung cancer.

The EUS-FNA diagnoses were confirmed or denied either by open thoracotomy, mediastinoscopy or clinical follow-up. In the patients having thoracotomy, histological proof of advanced disease was always obtained. If mediastinal or distant metastases were demonstrated by EUS-FNA, or if direct mediastinal organ invasion was demonstrated by EUS-FNA, a malignant diagnosis obtained by EUS-FNA was taken as final proof of advanced lung cancer, unless contradicted by the post staging clinical course.

At thoracotomy, histological tissue was taken from all available mediastinal lymph node stations.

Follow-up

A 100% complete follow-up included direct contact with all hospitals, where the patients had been admitted throughout the follow-up period, and with patients still alive, unless their hospital files revealed a definitive malignant post staging course. If patients were unable to report sufficiently, their general practitioner was contacted.

Study design and statistical analysis

For the purpose of this study diagnostic values with regard to the diagnosis of advanced lung cancer were assessed and compared for PET/CT and EUS-FNA. Advanced lung cancer was

defined as tumour stage T4 and/or lymph node stage N2-N3 and/or distant metastases stage M1. This definition was found clinically relevant, because verified advanced disease, according to this definition, normally excludes patients from initial surgery with curative intent at our institution. Such patients are usually referred for oncological treatment first.

The diagnostic values of PET/CT and EUS-FNA were calculated according to the following definitions: Sensitivity = true positive PET/CT or EUS-FNA diagnoses / total number of positive final diagnoses. Specificity = true negative PET/CT or EUS-FNA diagnoses / total number of negative final diagnoses. Positive predictive value (PPV) = true positive PET/CT or EUS-FNA diagnoses / total number of positive PET/CT or EUS-FNA diagnoses. Negative predictive value (NPV) = true negative PET/CT or EUS-FNA diagnoses / total number of negative PET/CT or EUS-FNA diagnoses. Accuracy = true negative PET/CT or EUS-FNA diagnoses + true positive PET/CT or EUS-FNA diagnoses / total number of final diagnoses.

All data were tabulated and analysed using SPSS version 11.5 (SPSS Inc., Chicago, IL, USA). Sensitivity, NPV and accuracy of the 2 methods were compared by chi-square test, Fishers exact test or McNemars test for correlated proportions where appropriate. By definition, specificity and PPV of EUS-FNA, for mediastinal malignancy, are 100%. Therefore p-values for specificity and PPV were not calculated. The level of statistical significance was 0.05.

Results

Yield of PET/CT

PET/CT was suggestive of advanced lung cancer in 16 patients: 5 patients had T4 disease; 3 patients had T4- and N2-N3 disease; 2 patients had only N2-N3 disease; 5 patients had N2-N3 and M1 disease; and 1 patient had only M1 disease considered by PET/CT.

Yield of EUS-FNA

EUS-FNA diagnosed advanced lung cancer in 11 patients: 2 patients had T4 disease; 1 patient had T4- and N2-N3 disease; 7 patients had only N2-N3 disease and 1 patient had M1- and N2 disease diagnosed by EUS-FNA.

Clinical course after PET/CT and EUS-FNA

The clinical course after PET/CT and EUS-FNA for all patients included is presented in Figure 1. All of 9 patients diagnosed with advanced disease by both PET/CT and EUS-FNA had a clinical course in accordance with advanced disease (progression or death from lung cancer during follow-up). Two patients with PET/CT not suggestive of advanced lung cancer (PET/CT-negative) had EUS-FNA conclusive of advanced disease (subcarinal lymph node metastases in both patients), and a malignant clinical course at follow-up. Two patients with PET/CT suggestive of advanced lung cancer (PET/CT-positive) and benign EUS-FNA (EUS-FNA-negative) were found at thoracotomy to have advanced disease (one patient had a lung metastasis resected in another lobe (M1) and the other patient had tumour-invasion into the left atrium of the heart). One PET/CT-negative and EUS-FNA-negative patient had advanced disease found at thoracotomy (mediastinal tumour invasion).

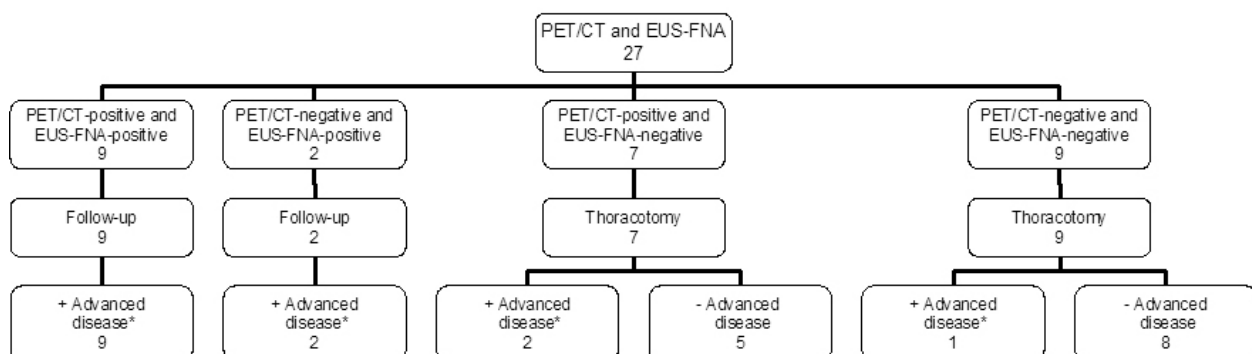


Figure 1 Clinical course of 27 patients included. Data are number of patients. PET/CT = integrated positron emission tomography and computed tomography; EUS-FNA = endoscopic ultrasound guided fine needle aspiration biopsy; advanced disease = lung cancer stage \geq IIIA(N2), PET/CT- or EUS-FNA-positive = PET/CT or EUS-FNA suggestive of advanced disease; PET/CT- or EUS-FNA-negative = PET/CT or EUS-FNA not suggestive of advanced lung cancer. * Progression or death from lung cancer during follow-up

No complications to EUS-FNA were recorded. The median follow-up time was 1.3 years (range 0.1-2.3 years). 4 patients (15% of patients included, 25% of patients undergoing thoracotomy) had futile or unnecessary thoracotomies (defined as either explorative thoracotomy without tumour resection (n=2) or postoperative recurrent disease during follow-up (n=2)).

Diagnostic values of PET/CT and EUS-FNA:

Tumour-stage (T):

Five patients had T4-disease as the final diagnosis: 3 of them were diagnosed by EUS-FNA and avoided thoracotomy; 2 patients were diagnosed by explorative thoracotomy and were unresectable. PET/CT was suggestive of T4 disease in 2 of the patients diagnosed by EUS-FNA and in one of the patients diagnosed by thoracotomy.

A comparison of PET/CT- and EUS-FNA results with final diagnoses, concerning T4-disease, is presented in Table 3.

Table 3 Comparison of diagnostic values of PET/CT and EUS-FNA for advanced tumour stage (T4), lymph node stage (N2-N3), distant metastases stage (M1) or any advanced stage (T4 or N2-N3 or M1)

Number of patients		PET/CT-pos. and EUS-FNA-pos.		EUS-FNA-pos. (and PET/CT-neg.)		PET/CT-pos. (and EUS-FNA-neg.)		PET/CT-neg. and EUS-FNA-neg.	
		True pos.	False pos.	True pos.	False pos.	True pos.	False pos.	True neg.	False neg.
Stage	T4	2	0	1	0	1	5	17	1
	N2/3	5	0	4	0	0	5	13	0
	M1	1	0	0	0	2	3	21	0
	T4 and/or N2/3 and/or M1	9	0	2	0	2	5	8	1

Data are number of patients. PET/CT = integrated positron emission tomography and computed tomography; EUS-FNA = endoscopic ultrasound guided fine needle aspiration biopsy; PET/CT- or EUS-FNA-pos. = PET/CT or EUS-FNA suggestive of advanced disease; PET/CT- or EUS-FNA-neg. = PET/CT or EUS-FNA not suggestive of advanced lung cancer; True = diagnosis confirmed at final diagnosing; False = diagnosis not confirmed at final diagnosing.

Diagnostic values of PET/CT and EUS-FNA for T4-disease are compared in Table 4.

Table 4 Comparison of diagnostic values of PET/CT and EUS-FNA for advanced tumour stage (T4), lymph node stage (N2-N3), distant metastases stage (M1) or any advanced stage (T4 or N2-N3 or M1)

	Sensitivity			Specificity		PPV		NPV			Accuracy		
	PET/CT	EUS-FNA	p-value	PET/CT	EUS-FNA	PET/CT	EUS-FNA	PET/CT	EUS-FNA	p-value	PET/CT	EUS-FNA	p-value
T4	0.60	0.60	1.00	0.77	1.00	0.38	1.00	0.89	0.92	1.00	0.74	0.93	0.14
N2-N3	0.56	1.00	0.12	0.72	1.00	0.50	1.00	0.76	1.00	0.05	0.67	1.00	0.004
M1	1.00	0.33	0.50	0.88	1.00	0.50	1.00	1.00	0.92	0.49	0.89	0.93	1.00
T4 and/or N2-N3 and/or M1	0.79	0.79	1.00	0.61	1.00	0.69	1.00	0.73	0.81	0.66	0.70	0.89	0.18

PET/CT = integrated positron emission tomography and computed tomography; EUS-FNA = endoscopic ultrasound guided fine needle aspiration biopsy; NPV = negative predictive value; PPV = positive predictive value

Mediastinal lymph node stage (N):

Nine patients had N2-N3 disease as the final diagnosis. PET/CT detected 5 of them, EUS-FNA diagnosed all of them. At thoracotomy no patients were found to have N2-N3 disease, but N1 disease was found in 4 patients. Mediastinoscopy was performed in 25 of the patients resulting in the diagnosis of N2-disease in 2 patients, who were also diagnosed by both PET/CT and EUS-FNA. In one of these patients EUS-FNA proved N3-disease as well. Two patients did not undergo mediastinoscopy because a previous EUS-FNA had proved inoperable disease.

A comparison of PET/CT- and EUS-FNA results with final diagnoses, concerning N2-N3 disease, is presented in Table 3.

Diagnostic values of PET/CT and EUS-FNA for N2-N3-disease are compared in Table 4.

Distant metastases stage (M):

Three patients had M1-disease as the final diagnosis. One had a lung metastasis, which was detected by PET/CT prior to resection; one patient had a liver-metastasis detected by PET/CT (not seen on CT) and proved by external ultrasound-guided biopsy, and the third patient had a left adrenal metastasis suggested by PET/CT and proved by EUS-FNA. In addition to M1-disease, the 2 latter patients had N2-N3 disease proved by EUS-FNA.

One patient had a PET/CT-positive lesion in the left mamma in addition to the lung tumour. Both were resected, and histological evaluation

revealed 2 primary tumours, and not M1-lung cancer.

A comparison of PET/CT- and EUS-FNA results with final diagnoses, concerning M1-disease, is presented in Table 3. Diagnostic values of PET/CT and EUS-FNA for M1-disease are compared in Table 4.

Advanced disease (T4 or N2-N3 or M1):

A comparison of PET/CT- and EUS-FNA results with final diagnoses, concerning advanced disease, is presented in Table 3. Diagnostic values of PET/CT and EUS-FNA for advanced disease are compared in Table 4.

Discussion:

PET/CT and EUS-FNA had a comparable sensitivity for advanced disease, while EUS-FNA had a superior specificity. This pattern is in agreement with other studies comparing PET with EUS-FNA in lung cancer patients considered for surgery [12,13,20,21]. The difference in specificity was caused by a considerable number of false positive PET results (Table 3).

Regarding T-staging, both methods had a relatively low sensitivity for T4 disease (60%) comparable to that of CT [3]. The differentiation between mediastinal tumour invasion and perineoplastic inflammatory tissue is probably a problem of all imaging methods. However, by integrating PET and CT a higher accuracy for T-staging was expected. In a previous and larger study of PET/CT in lung cancer staging, PET/CT resulted in a significantly increased T-stage accuracy, when compared with each of the separated imaging methods [10]. The present study was initiated shortly after installation of the new PET/CT-scanner in our PET-centre. The investigators were experienced PET- and CT-specialists, but the learning curve of integrated PET/CT is not well described. Further experience with the technique may increase the diagnostic accuracy.

Regarding mediastinal lymph node metastases EUS-FNA appeared significantly more accurate than PET/CT. Four of 17 patients (24%), with PET/CT not suggesting mediastinal lymph node involvement, had N2-N3 disease proved by EUS-FNA (Table 3). This also resulted in a relatively low NPV of PET/CT for N2-N3 disease (76%). In a recent review, PET had a pooled NPV of 93% for mediastinal disease, and in the following guidelines it was suggested, that PET negative patients could proceed to thoracotomy without invasive mediastinal staging [3,23]. In the included trials of this review, EUS-FNA was not a part of the invasive staging workup, and the

pooled prevalence of mediastinal disease, detected by mediastinoscopy and thoracotomy, was 32%. In our study, with comparable inclusion criteria, 48% of the patients had mediastinal disease detected by EUS-FNA, mediastinoscopy or thoracotomy. In addition, the rate of futile thoracotomies was relatively low in our study (25% of thoracotomies were either explorative- or followed by postoperative recurrent disease). In other comparable materials, without PET and EUS-FNA available in the staging workup, a rate of 40-50% such futile thoracotomies are common [1,2,7].

The combination of a high rate of confirmed mediastinal disease, a low rate of futile thoracotomies and a relatively low NPV of PET/CT in this study, may indicate that EUS-FNA detected PET/CT-negative mediastinal disease, which would not otherwise have been diagnosed. EUS-FNA might therefore be the cause of the low NPV of PET/CT in this study. In support of this, the 2 other trials, performing PET and EUS-FNA in lung cancer patients, also observed a relatively low NPV of PET (64 and 79% respectively) [12,13]. Consequently, the omission of invasive mediastinal staging in PET negative patients might not be recommended, when EUS-FNA is available.

The main advantage of PET/CT in this study seemed to be a high sensitivity and negative predictive value for M1 disease (with the reservation of the small number of patients with M1 disease proven in this study (n=3)). This finding is in agreement with former trials [5,7,24] and suggests that PET or PET/CT should be performed early in the course of staging to rule out distant metastases, which could obviate the need for further mediastinal staging. However, a PET/CT-scan suggesting M1 disease needs confirmation by a tissue diagnosis, or another imaging method, to change patient management. In this context EUS-FNA diagnosed 1 of 3 patients with M1 disease (and in 2 patients with M1 disease EUS-FNA detected N2 disease as well).

A precondition for EUS-FNA is the presence of a trained EUS-FNA operator and an experienced cyto-pathologist. The learning curve of EUS-FNA is relatively flat, and the application of routine EUS-FNA in centres with no former experience with the technique, might not initially result in the same yield as in this study.

At our centre we find it reasonable, and in agreement with general consensus [25,11-19], to accept a malignant diagnosis obtained by EUS-FNA as a final proof of advanced disease. A

possibility of “overstaging” by EUS-FNA can not be ruled out, because the exact location of malignancy obtained by EUS-FNA was not verified by open thoracotomy.

Concerning T-stage accuracy of EUS-FNA, a recent study has warranted caution when unresectability of lung cancer is based solely on tumour invasion into mediastinal soft tissue at EUS [26]. Overstaging occurred (in 3 of 10 patients), when tumour appeared to invade the pleural layer without mediastinal organ invasion. In our study only mediastinal organ invasion demonstrated by EUS-FNA was taken as final proof of T4-unresectability. Concerning N-staging, only one study of 107 patients have performed thoracotomy on patients with mediastinal malignancy suggested by EUS-FNA; and in 2 patients with centrally located left lower lobe tumours the tumour itself was misinterpreted by EUS-FNA as subcarinal lymph node metastases [27]. Therefore EUS-FNA results from lymph nodes located immediately adjacent to the primary tumour should also be interpreted with caution. In our material 2 patients with left lower lobe tumours had subcarinal malignancy by EUS-FNA, but both patients had malignant paratracheal lymph nodes diagnosed by EUS-FNA as well.

In conclusion, this small study confirms that PET/CT and EUS-FNA have a comparable sensitivity and NPV for diagnosing advanced lung cancer; but the superior specificity and PPV of EUS-FNA, allowing a considerable number of patients to be definitively classified as inoperable with a single minimal invasive procedure, suggests that EUS-FNA should have a high priority in lung cancer staging. The main advantage of PET or PET/CT, when EUS-FNA is also performed, seems to be a high sensitivity for the detection of distant metastases not found otherwise. The two methods seem to complement each other, and in combination they may decrease the need for more invasive staging procedures such as mediastinoscopy and explorative thoracotomy. However, larger and preferable randomised studies are needed to finally uncover the potential benefit of PET/CT and EUS-FNA in lung cancer staging.

References

- Herder GJ, Verboom P, Smit EF et al. Practice, efficacy and cost of staging suspected non-small cell lung cancer: a retrospective study in two Dutch hospitals. *Thorax* 2002;57:11-4.
- Canadian Lung Oncology Group. Investigation for mediastinal disease in patients with apparently operable lung cancer. *Ann Thorac Surg* 1995;60:1382-9.
- Tolozan EM, Harpole L, McCrory DC. Noninvasive staging of non-small cell lung cancer: a review of the current evidence. *Chest* 2003;123:137S-146S.
- Wahl RL, Quint LE, Greenough RL et al. Staging of mediastinal non-small-cell lung cancer with FDG PET, CT and fusion images: Preliminary prospective evaluation. *Radiology* 1994;191:371-377.
- Pieterman RM, van Putten JW, Meuzelaar JJ et al. Preoperative staging of non-small-cell lung cancer with positron emission tomography. *N Eng J Med* 2000;343:254-61.
- Gambhir SS, Hoh CK, Phelps ME et al. Decision tree sensitivity analysis for cost-effectiveness of FDG-PET in the staging and management of non-small-cell lung carcinoma. *J Nuclear Med* 1996;37:1428-36.
- van Tinteren H, Hoekstra OS, Smit EF et al. Effectiveness of positron emission tomography in the preoperative assessment of patients with suspected non-small-cell lung cancer: the PLUS multicentre randomised trial. *Lancet* 2002;359:1388-93.
- Graeter TP, Hellwig D, Hoffmann K et al. Mediastinal lymph node staging in suspected lung cancer: comparison of positron emission tomography with F-18-fluorodeoxyglucose and mediastinoscopy. *Ann Thorac Surg* 2003;75:231-6.
- Poncelet AJ, Lonneux M, Coche E. PET-FDG enhances but does not replace preoperative surgical staging in non-small cell lung cancer. *Eur J Cardio-Thorac Surg* 2001;20:468-75.
- Lardinois D, Weder W, Hany TF et al. Staging of non-small-cell-lung cancer with integrated positron-emission tomography and computed tomography. *N Engl J Med* 2003;348:2500-2507.
- Wallace MB, Ravenel J, Block MI et al. Endoscopic ultrasound in lung cancer patients with a normal mediastinum on computed tomography. *Ann Thorac Surg* 2004;77:1763-8.
- Fritscher-Ravens A, Davidson BL, Hauber HP et al. Endoscopic ultrasound, positron emission tomography, and computerized tomography for lung cancer. *Am J Respir Crit Care Med* 2003;168:1293-7.
- Fritscher-Ravens A, Bohuslavizki KH, Brandt L et al. Mediastinal lymph node involvement in potentially resectable lung cancer: comparison of CT, positron emission tomography, and endoscopic ultrasonography with and without fine-needle aspiration. *Chest* 2003;123:442-51.
- Larsen SS, Krasnik M, Vilmann P et al. Endoscopic ultrasound guided fine needle biopsy of mediastinal lesions has a major impact on patient management. *Thorax* 2002; 57: 98-103.
- Wiersema MJ, Vazquez-Sequeiros E, Wiersema LM. Evaluation of mediastinal lymphadenopathy with endoscopic US-guided fine-needle aspiration biopsy. *Radiology* 2001;219:252-7.
- Wallace MB, Silvestri GA, Sahai AV et al. Endoscopic ultrasound-guided fine needle aspiration for staging patients with carcinoma of the lung. *Ann Thorac Surg* 2001;72:1861-7.
- Fritscher-Ravens A, Sriram PV, Bobrowski C et al. Mediastinal lymphadenopathy in patients with or without previous malignancy: EUS-FNA based differential cytodiagnosis in 153 patients. *Am J Gastroenterol* 2000;95:2278-84.

18. Gress FG, Savides TJ, Sandler A et al. Endoscopic ultrasonography, fine-needle aspiration biopsy guided by endoscopic ultrasonography, and computed tomography in the preoperative staging of non-small-cell lung cancer: a comparison study. *Ann Intern Med* 1997;15:604-12.
19. Silvestri GA, Hoffman BJ, Bhutani MS et al. Endoscopic ultrasound with fine-needle aspiration in the diagnosis and staging of lung cancer. *Ann Thorac Surg* 1996;61:1441-6.
20. Annema JT, Hoekstra OS, Smit EF et al. Towards a minimally invasive staging strategy in NSCLC: analysis of PET positive mediastinal lesions by EUS-FNA. *Lung Cancer* 2004;44:53-60.
21. Kramer H, van Putten JWG, Post WJ et al. Oesophageal endoscopic ultrasound with fine needle aspiration improves and simplifies the staging of lung cancer. *Thorax* 2004; 59:596-601.
22. Mountain CF, Dresler CM. Regional lymph node classification for lung cancer staging. *Chest* 1997;111:1486-7.
23. Silvestri GA, Tanoue LT, Margolis ML et al. The noninvasive staging of non-small cell lung cancer, the guidelines. *Chest* 2003;123:147S-156S.
24. Weder W, Schmid RA, Bruchhaus H et al. Detection of extrathoracic metastases by positron emission tomography in lung cancer. *Ann Thorac Surg.* 1998;66:886-92.
25. Toloza EM, Harpole L, Detterbeck F et al. Invasive staging of non-small cell lung cancer: a review of the current evidence. *Chest* 2003;123:157S-166S.
26. Varadarajulu S, Schmulewitz N, Wildi SF et al. Accuracy of EUS in staging of T4 lung cancer. *Gastrointest Endosc* 2004;59:345-8.
27. Annema JT, Versteegh MI, Veselic M et al. Endoscopic Ultrasound Added to Mediastinoscopy for Preoperative Staging of Patients with Lung Cancer. *JAMA* 2005;294:931-6

Correspondence Adress: Soeren S. Larsen, Efteraarsvej 10, DK-2920 Charlottenlund, Denmark, Phone: +45 22 43 15 10, Fax: +45 39 77 76 44, E-mail: ssl@dadlnet.dk