



Original article

Clinical features of spontaneous spinal epidural hematoma

Fumihiko Eto¹, Masaki Tatsumura¹, Sho Iwabuchi¹, Takeshi Ogawa¹, Takeo Mammoto¹, and Atsushi Hirano¹

¹Department of Orthopaedic Surgery and Sports Medicine, Tsukuba University Hospital Mito Clinical Education and Training Center, Mito Kyodo General Hospital, Japan

Abstract

Objective: Spontaneous spinal epidural hematoma is rare and therefore difficult to diagnose. This study evaluated the clinical features of this condition in patients admitted to our hospital.

Patients and Methods: We evaluated 12 patients with spontaneous spinal epidural hematoma who were treated at our hospital. We investigated the following variables in these patients: underlying diseases, medications used, initial symptoms, spinal level affected, whether transported to the hospital by ambulance, department where first evaluated, mass lesion on computed tomography with soft tissue window settings, time interval between symptom onset and diagnosis, treatment received, and Frankel classification on arrival and when last observed.

Results: Five patients reported the use of antiplatelet or anticoagulant drugs. All patients in this study reported acute onset of severe pain as the initial symptom, and 10 patients reported some degree of paralysis accompanying the pain. With respect to the morbidity level, the cervical region was the most common site of involvement (n=7). Ten patients were transported to the hospital at night via ambulance. Five patients first visited the Department of Internal Medicine. Seven patients presented with a mass lesion on computed tomography with soft tissue window settings. The time interval between symptom onset and diagnosis ranged from 2 hours to 6 days. Three and 9 patients received conservative and surgical treatments, respectively. No patient showed worsening of Frankel classification.

Conclusion: Acute onset of severe pain was the most characteristic clinical symptom. Spontaneous spinal epidural hematoma should be included in the differential diagnosis. Computed tomography with soft tissue window settings may rule out cerebrovascular disease and cardiovascular disease, and specifically detect a hematoma. Subsequent magnetic resonance imaging can diagnose a spontaneous spinal epidural hematoma at an early stage.

Key words: spontaneous spinal epidural hematoma, acute onset of severe pain, computed tomography with soft tissue window settings

(J Rural Med 2019; 14(2): 206–210)

Introduction

Spontaneous spinal epidural hematoma (SSEH) is rare, with an incidence of 0.1 in 10 million individuals¹⁾. However, an increasing number of cases are being reported following

recent advances in diagnostic imaging. Magnetic resonance imaging (MRI) is useful to definitively diagnose SSEH; however, diagnosis is challenging because patients are often transported via ambulance during the night or present with various types of paralysis. Several reports have discussed the indications for surgical treatment of SSEH, with a few recommending conservative management. Regardless of the treatment selected, early diagnosis of SSEH is extremely important.

This study evaluated the clinical features of SSEH in patients admitted to our hospital.

Patients and Methods

We reviewed the data of 12 patients (5 men and 7 women) with SSEH who were treated at our hospital between April

Received: February 14, 2019

Accepted: May 31, 2019

Correspondence: Fumihiko Eto, MD, Department of Orthopaedic Surgery and Sports Medicine, Tsukuba University Hospital Mito Clinical Education and Training Center, Mito Kyodo General Hospital, 3-2-7 Miyamachi, Mito, Ibaraki 310-0015, Japan
E-mail: fumihiko.7279@gmail.com

This is an open-access article distributed under the terms of the Creative Commons Attribution Non-Commercial No Derivatives

(by-nc-nd) License <<http://creativecommons.org/licenses/by-nc-nd/4.0/>>.



2010 and September 2017. The mean age of patients was 68.6 years (range, 51–92 years), and the mean follow-up period was 10.2 months (range, 1–36 months). All patients were definitively diagnosed by MRI. We investigated the following variables in all patients: underlying diseases, medications used, initial symptoms, spinal level affected, whether transported to the hospital via ambulance, department where first examined, mass lesion on computed tomography (CT) with soft tissue window settings, time interval between symptom onset and diagnosis, treatment received, and Frankel classification on arrival and when last observed.

The study was approved by the institutional review boards of Mito Kyodo General Hospital (Permit Number: 19-19).

Results

The underlying diseases observed in patients included diabetes (n=3), cerebral infarction (n=2), heart disease (n=2), malignant tumor (n=1), and autoimmune disease (n=1). Antiplatelet and anticoagulant drug use was reported in 3 and 2 patients, respectively. The initial symptom was acute onset of severe pain in all patients, and paralysis accompanying pain was observed in 10 patients. Paralysis was categorized as hemiplegia (n=5), tetraplegia (n=3), and paraplegia (n=2). Following the initial symptom of pain, paralysis developed in 9 patients within 2 hours, and in 1 patient after 8 hours. Paralysis improved temporarily but recurred after 3 days in 1 patient. Morbidity levels included the cervical (n=7), cervicothoracic (n=1), and thoracolumbar regions (n=4). Ten patients were transferred to the hospital at night via ambulance, and 1 patient was transferred by a private car. One patient admitted to the Department of Internal Medicine developed SSEH during hospitalization. The department where patients were first evaluated included Internal Medicine (n=5), Neurosurgery (n=4), and Orthopaedic Sur-

gery (n=3). Cerebrovascular or cardiovascular disease was suspected in most patients owing to the typical presentation; therefore, patients were often first transferred to the Department of Internal Medicine or Neurosurgery. A mass lesion was detected on CT with soft tissue window settings in 7 patients. No mass lesion was detected in 2 patients, and CT was not performed in 3 patients. The time interval observed between symptom onset and diagnosis showed a wide range. A hospitalized patient was diagnosed within 2 hours, whereas a patient admitted to a nearby hospital was diagnosed in 6 days. Conservative and surgical treatments were performed in 3 and 9 patients, respectively. Surgery was performed within 24 hours in 6 patients. The Frankel classification upon arrival was grade A in 2, grade C in 8, and grade E in 2 patients. Two patients with Frankel grade A upon arrival underwent surgery within 24 hours, and paralysis improved to Frankel grade C postoperatively. No patient showed worsening of Frankel classification (Table 1).

Case Presentation

Case 7: A 51-year-old man with a history of diabetes and angina pectoris and aspirin use developed acute onset of severe cervical pain at night followed by gradual left hemiplegia. He was transferred to a nearby hospital via ambulance, and was hospitalized for observation. Sagittal CT performed the following day revealed a spindle-shaped mass lesion in the left portion dorsal to the dural sac at the C4–C6 level. SSEH was suspected, and he was referred to our hospital (Figure 1a, d). Clinical examination performed 12 hours after symptom onset showed left-sided cervical pain and paralysis with Brown-Sequard syndrome; manual muscle testing (MMT) revealed weakness of the left upper and lower extremities (grades 2 and 4, respectively), with hypesthesia of the right-sided trunk below (Frankel grade C). Mixed intensity on T1- and T2-weighted MRI indicated

Table 1 Case summary

Case	Age (years)	Sex	Levels of mass lesion	Ambulance	Department	Mass lesion (CT)	Time (hours)	Treatment	Frankel
1	58	F	C6–C7	Yes	NS	Unexamined	11	S	C→D
2	90	F	C6–T2	Yes	IM	No	6	S	C→C
3	58	M	T12–L3	Yes	OS	Yes	18	C	E→E
4	57	M	C3–C6	Yes	OS	Unexamined	13	C	C→D
5	65	F	T4–L5	No	IM	No	2	S	A→C
6	70	M	C3–C7	Yes	IM	Yes	72	S	C→D
7	51	M	C4–C6	Yes	NS	Yes	12	S	C→D
8	80	F	T8–L2	Yes	IM	Yes	144	S	C→D
9	70	M	C2–C6	Yes	NS	Yes	8	S	E→E
10	68	F	C3–C7	Yes	NS	Yes	3	S	C→E
11	92	F	C2–C6	Yes	IM	Yes	9	S	A→C
12	64	F	T12–L2	No	OS	Unexamined	96	C	C→D

Department: first examination department; NS: Neurosurgery; IM: Internal Medicine; OS: Orthopaedic Surgery; Time: time interval between symptom onset and diagnosis; S: surgical treatment; C: conservative treatment; Frankel: Frankel classification on arrival and when last observed.

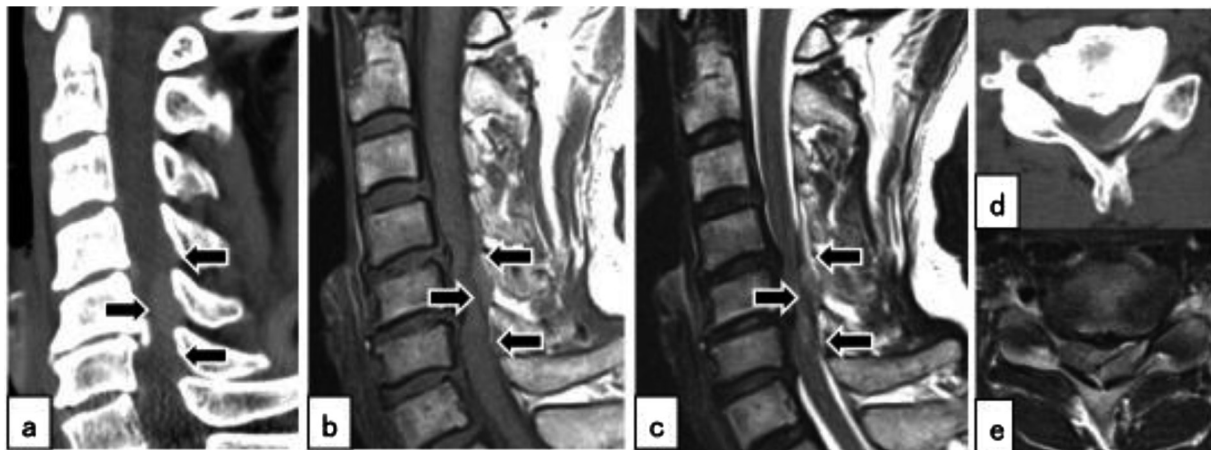


Figure 1 Case 7. (a) Computed tomography (CT) scan (sagittal view) showing a spindle-shaped mass lesion at the C4–C6 level (arrows). (b, c) Mixed intensity observed on T1- and T2-weighted magnetic resonance imaging (MRI) scans indicates a hematoma (arrows). (d, e) Axial CT and MRI scans showing an epidural hematoma at the left portion dorsal to the dural sac.

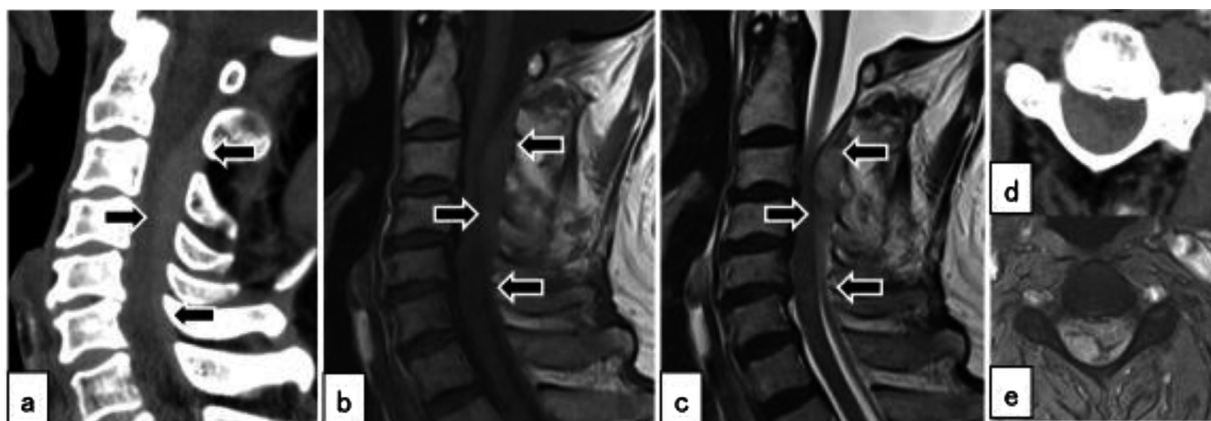


Figure 2 Case 9. (a, d) Computed tomography scan with soft tissue window settings showing a spindle-shaped mass lesion suspicious for hematoma at the C2–C6 level (arrows). (b, c, e) Spontaneous spinal epidural hematoma was diagnosed with magnetic resonance imaging, and surgical treatment was performed in the patient (arrows).

a hematoma, and he was thus diagnosed with SSEH (Figure 1b, c, e). Laminoplasty and hematoma removal were performed 24 hours after symptom onset. Clinical examination performed 3 months postoperatively showed improvement in paralysis of the left upper and lower extremities (MMT grade 5) with persistent hypesthesia (Frankel grade D). Case 9: A 70-year-old man with a history of cerebral infarction, as well as aspirin and ethyl icosapentate usage developed acute onset of severe cervical pain and was transferred to a nearby hospital via ambulance. CT revealed a spindle-shaped mass lesion in the portion dorsal to the dural sac at the C2–C6 level. SSEH was suspected, and he was referred to our hospital (Figure 2a, d). Clinical examination performed 10 hours after symptom onset showed no paralysis (Frankel grade E). He was diagnosed with SSEH based on MRI findings, and laminoplasty and hematoma removal

were performed 12 hours after symptom onset (Figure 2b, c, e). His cervical pain improved postoperatively, and no paralysis was observed (Frankel grade E).

Discussion

In the present study, all patients with SSEH were diagnosed based on MRI findings, and both conservative and surgical treatments were associated with favorable outcomes. Musha *et al.* propose the following indications for conservative treatment in patients with SSEH: no anticoagulant therapy, paralysis corresponding to Frankel grades C or D, and recovery within 15 hours of the event². These authors also recommend surgical treatment within 24 hours from the onset of paralysis. Shin *et al.* reported that patients with incomplete neurological injury who underwent surgery

within 12 hours showed excellent surgical outcomes³). In the present study, since there were some cases in which patients developed paralysis 8 hours after onset of pain, which improved temporarily but recurred after 3 days, we considered surgical treatment as soon as possible, regardless of the degree of paralysis.

Notably, the time interval between symptom onset and diagnosis showed a wide range from 2 hours to 6 days. Diagnosing SSEH is challenging because emergency MRI at night is difficult in Japan, and patients often present with various types of paralysis, which may lead to a suspicion of cerebrovascular and cardiovascular diseases in such cases. Acute onset of severe pain characterizes SSEH, and most patients are transferred via ambulance. Typically, patients develop paralysis after pain; however, previous reports have described a few patients with only pain without any neurological symptoms⁴). In the present study, a few patients experienced pain without paralysis or developed paralysis that improved temporarily. Thus, it is reasonable to conclude that SSEH should be considered in the differential diagnosis regardless of the type of paralysis or its absence. Differential diagnoses in patients presenting with acute onset of severe pain and neurological symptoms include disc herniation, cerebral infarction, spinal cord infarction, transverse myelitis, subarachnoid hemorrhage, aortic dissection, vertebral artery dissection, and acute myocardial infarction⁵), and CT is warranted in these cases. It is important to rule out cerebrovascular and cardiovascular diseases and perform CT with soft tissue window settings to accurately diagnose SSEH. In our opinion, it may be possible to detect a hematoma on CT with soft tissue window as opposed to bone window settings, and this imaging technique can detect spindle-shaped

mass lesions on sagittal views (Figure 3). Additionally, it may be easier to detect SSEH on CT using sagittal rather than axial views. Similarly, paramedian views are preferred over median views. Subsequent MRI can diagnose SSEH at an early stage. Prior to the advances in MRI technology, sagittal CT was useful for initial screening and follow-up of SSEHs⁶). It may also be helpful to evaluate the image of a hematoma, which is usually identified dorsal to the dural sac because of the tight adherence of the dural sac to the posterior longitudinal ligament⁷). Even if CT leads to a high index of suspicion for SSEH, MRI is superior in visualizing epidural lesions and is thus essential for definitive diagnosis.

In the present study, we observed that patients with pain or paralysis were more likely to visit the Department of Internal Medicine or Neurosurgery instead of Orthopaedic Surgery, and were usually transported to the hospital by an ambulance at night. Physicians from all departments involved in emergency medical care should be aware of SSEH and must consider this condition in the differential diagnosis in patients presenting with acute onset of severe pain regardless of the type of paralysis or its absence. CT with soft tissue window settings should be performed to enable accurate detection of a hematoma in such cases. We recommend that MRI be performed subsequently to diagnose SSEH at an early stage.

Conclusion

In the present study, we evaluated the clinical features of SSEH in patients admitted to at our hospital. Acute onset of severe pain was the most characteristic symptom in all patients. Paralysis was not present in all patients, and notably,

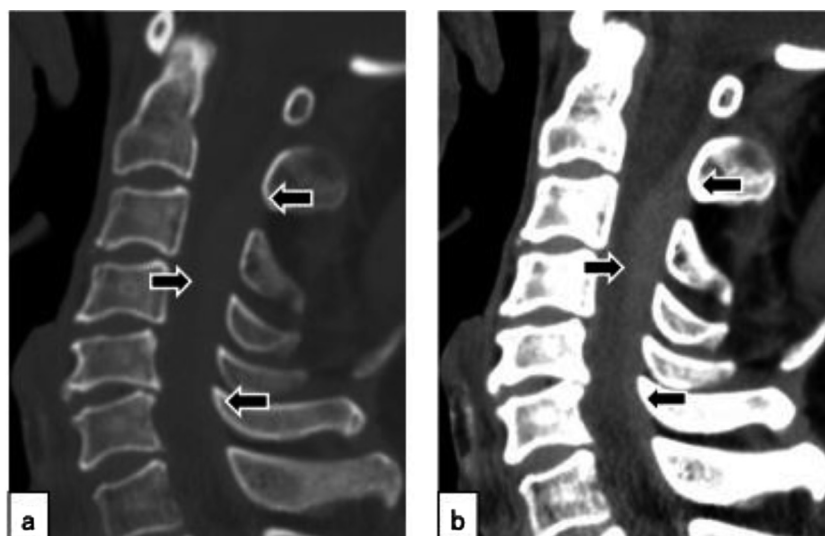


Figure 3 Comparison of computed tomography (CT) scans based on window settings (sagittal views). Epidural hematomas are easier to identify on CT scans with soft tissue window settings (b) rather than CT scans with bone window settings (a) (arrows).

the types of paralysis varied among those who presented with this complication. SSEH should be considered in the differential diagnosis in patients with this typical presentation, and CT should be performed for confirmation. It may be possible to rule out cerebrovascular and cardiovascular diseases, and detect a spindle-shaped hematoma on CT with soft tissue window settings. MRI performed subsequently can diagnose SSEH at an early stage.

Acknowledgment

We thank Miki Omori, medical clerk at Mito Clinical Education and Training Center, University of Tsukuba Hospital, and Mito Kyodo General Hospital, for her valuable contribution to data analysis.

References

1. Holtås S, Heiling M, Lönntoft M. Spontaneous spinal epidural hematoma: findings at MR imaging and clinical correlation. *Radiology* 1996; 199: 409–413. [[Medline](#)] [[CrossRef](#)]
2. Musha Y, Ito K, Sunakawa T, *et al.* Indication and timing for conservative treatment and surgical treatment in acute spinal epidural hematoma. *Spinal Surg* 2015; 29: 310–314 (in Japanese, Abstract in English). [[CrossRef](#)]
3. Shin JJ, Kuh SU, Cho YE. Surgical management of spontaneous spinal epidural hematoma. *Eur Spine J* 2006; 15: 998–1004. [[Medline](#)] [[CrossRef](#)]
4. Serizawa Y, Ohshiro K, Tanaka K, *et al.* Spontaneous resolution of an acute spontaneous spinal epidural hematoma without neurological deficits. *Intern Med* 1995; 34: 992–994. [[Medline](#)] [[CrossRef](#)]
5. Ikegami K, Inoue Y, Miyajima M, *et al.* Emergency diagnosis and treatment of spontaneous spinal epidural hematoma. *Nihon Kyukyu Igakukai Zasshi* 2016; 27: 107–113 (JJAAM).
6. Laissy JP, Milon P, Freger P, *et al.* Cervical epidural hematomas: CT diagnosis in two cases that resolved spontaneously. *AJNR Am J Neuroradiol* 1990; 11: 394–396. [[Medline](#)]
7. Liu Z, Jiao Q, Xu J, *et al.* Spontaneous spinal epidural hematoma: analysis of 23 cases. *Surg Neurol* 2008; 69: 253–260, discussion 260. [[Medline](#)] [[CrossRef](#)]