

# Clinical analysis of aortic dissection with sudden coma and paraplegia as the main symptoms

Journal of International Medical Research

48(3) 1–5

© The Author(s) 2020

Article reuse guidelines:

[sagepub.com/journals-permissions](https://sagepub.com/journals-permissions)

DOI: 10.1177/0300060519895843

[journals.sagepub.com/home/imr](https://journals.sagepub.com/home/imr)



Dongwei Zhang , Yinuo Lin, Yuehui Liu,  
Xinhong Zhang and Caixia Jiang

## Abstract

**Objective:** This study aimed to investigate the clinical characteristics of patients with aortic dissection presenting with neurological symptoms as the initial symptoms.

**Methods:** Clinical characteristics, radiological abnormalities, and prognosis were analyzed in two female patients with aortic dissection. The main clinical symptoms were sudden coma and paraplegia. A detailed clinical examination was performed and computed tomography scans were evaluated.

**Results:** The initial symptoms of the patients involved the nervous system. Chest and abdominal computed tomography scans were performed to confirm the diagnosis of aortic dissection. Both patients died.

**Conclusion:** Patients who present with nervous system symptoms as the first symptoms of aortic dissection, which lead to misdiagnosis and missing the diagnosis, are rare. Improvement in the understanding of this disease is required to ensure that patients receive a timely diagnosis in the early stages.

## Keywords

Aortic dissection, cerebral infarction, myelitis, neurological symptom, coma, paraplegia

Date received: 9 May 2019; accepted: 27 November 2019

## Introduction

Aortic dissection is characterized by rapid onset and progression, and a high mortality rate.<sup>1</sup> Patients with aortic dissection usually visit the Cardiology, General Surgery, or Gastroenterology Departments with the

Department of Neurology, Affiliated Hospital of Inner Mongolia University for the Nationalities, Tongliao, China

### Corresponding author:

Xinhong Zhang, MD, Department of Neurology, Affiliated Hospital of Inner Mongolia University for the Nationalities, No. 1742, HuoLinHe Street, Tongliao, Neimenggu 028050, China.

Email: [zhangdongwei969@sina.com](mailto:zhangdongwei969@sina.com)

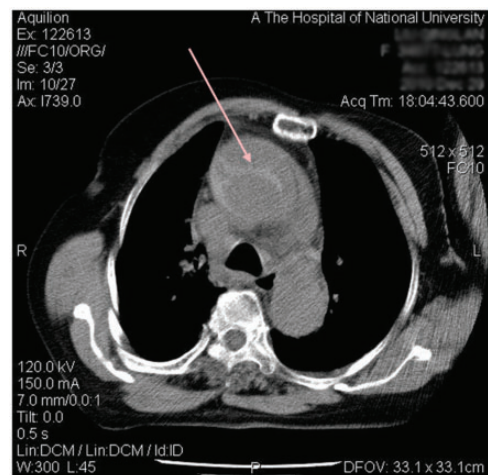


complaint of acute chest and abdominal pain. However, some patients are vulnerable to nervous system symptoms at the time of onset, and such symptoms require close attention by neurological physicians to ensure a correct diagnosis. In this study, we summarized the clinical characteristics of two female patients who were diagnosed with aortic dissection and presented with sudden coma or paraplegia.

## Case report

A 73-year-old female patient was admitted to the Department of Neurology on 29 December 2010 because of a 1-hour history of sudden-onset unconsciousness. The patient developed acute chest distress, pain in the head and neck, profuse perspiration, and unconsciousness 1 hour before the hospital visit. Electrocardiography showed myocardial ischemia and head computed tomography (CT) showed no abnormalities. The patient had a 7-year history of upper gastrointestinal bleeding (cured) and a 1-year history of untreated hypertension. A physical examination at admission showed a blood pressure of 133/69 mmHg, right arm blood pressure of 133/69 mmHg, left arm blood pressure of 112/58 mmHg, heart rate of 64 beats/minute, and a normal cardiac rhythm. This examination also showed a moderate coma, right pupil diameter of 3.8 mm, left pupil diameter of 2.5 mm, and positive light reaction. Additionally, there was a shallow left nasolabial groove, motionless limbs under stimuli, high muscle tension in the left limbs, positive bilateral Babinski sign, coarse respiratory murmur, and a soft abdomen. The patient's National Institute of Health Stroke Scale score was 21. An auxiliary examination showed a peripheral blood glucose level of 9.1 mmol/L and a white blood cell count of  $12.49 \times 10^9/L$ . Electrocardiography showed slight ST-segment elevation in lead III. A chest X-ray examination showed widening of the aorta, cardiac shadow enlargement,

and mediastinal widening. Carotid ultrasound showed that the left common carotid artery had a torn intima and a double lumen with hypoechoic filling in the false lumen, which suggested thrombosis and narrowing of the true lumen. Transthoracic echocardiography showed that the ascending aorta was widened, with a torn intima that floated and extended toward a distant direction. At rupture, the blood stream entered the false cavity from the true cavity and returned to the false cavity during the systolic period. True cavity blood flow velocity was fast with a bright color. False cavity blood flow velocity was slow with a dim color. Chest CT showed a large heart shadow, a widened ascending aorta with circular high density, high-density partitions (Figure 1), and a patchy shadow in the middle and lower fields of both lungs. The CT scan report described rupture and bleeding in the ascending aorta and the presence of an aneurysm, pericardial effusion, pleural effusion, and lung inflammation. At 50 minutes after admission, the patient became clearly conscious and was able to answer questions normally. She showed a bilateral



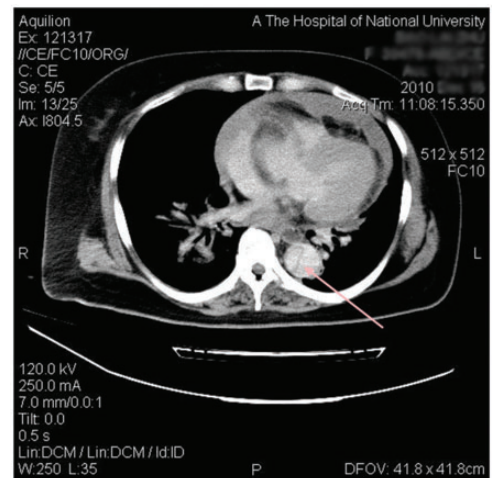
**Figure 1.** Chest computed tomography scan of Patient 1 shows a widened aorta with partitions (arrow).

pupil diameter of 3.0 mm, positive light reaction, shallow left nasolabial fold, grade 4 left limb muscle strength, grade 5 right limb muscle strength, positive left Babinski sign, anuria, and a National Institute of Health Stroke Scale score of 2. Her family members refused further treatment. She was discharged with abandonment of treatment and died 2 days later.

Another female patient, aged 43 years, was admitted to the Department of Neurology on 16 December 2010 with a 3-hour history of right lower limb numbness, back pain, and breath obstruction, all of which occurred after micturition. A physical examination at a local hospital showed that her blood pressure was 150/80 mmHg. She was treated with oral nifedipine and suxiao jiu xin, which is a Chinese traditional medicine, and transferred to the Department of Neurology in our hospital. The patient had a previous history of hypertension, type 2 diabetes mellitus, and coronary heart disease. No abnormalities were found on a head CT scan upon admission. A physical examination at admission showed a blood pressure of 150/94 mmHg and a heart rate of 104 beats/minute. This examination also showed a clear mind and fluent words, and normal cranial nerves. She had grade 5 upper limb muscle strength, grade 4 proximal lower limb muscle strength, grades 1–2 distal lower limb muscle strength, no muscle atrophy, pain and decreased tuning fork vibration under the waist level, and no pathological reflexes. Pulses in her bilateral femoral artery, popliteal artery, and dorsalis pedis artery were absent. Additionally, skin temperature in the lower limbs was considerably decreased. Her heart, lungs, and abdomen were normal. An auxiliary examination showed a peripheral blood glucose level of 31.4 mmol/L and a white blood cell count of  $12.01 \times 10^9/L$ . A blood biochemical test showed no abnormalities. Electrocardiography showed sinus tachycardia and thoracolumbar magnetic resonance

imaging did not show any obvious abnormalities in the spinal cord. Thoracic and abdominal CT showed a circular, low-density shadow from the descending aorta to the lower part of the inferior abdominal aorta, which was divided into two cavities (Figure 2) with different densities and smooth vessel walls. The upper abdominal aorta was widened and pericardial effusion was abundant. The progression of disease of the patient became exacerbated after admission. Her sensory level increased to thoracic 9, both lower limbs were evaluated as having grade 1 muscle strength, and her chest and back pain was aggravated. After treatment with hypoglycemic drugs, hypotensive drugs, oxygen inhalation, conscious sedation, and other symptomatic treatments, the patient's family elected to bring her to another hospital. Owing to the development of a sudden coma on the way to the other hospital, the patient returned to our hospital for rescue, but died.

The patients provided their informed consent for publication. This study was approved by the ethics committee of the Affiliated Hospital of Inner Mongolia University for the Nationalities.



**Figure 2.** Chest computed tomography scan of Patient 2 shows the aorta with partitions (arrow).

## Discussion

Aortic dissection, also known as aortic dissecting aneurysm, is a rare cardiovascular disease. Aortic dissection develops when aortic blood enters the middle layer of the aortic wall through intimal rupture openings, forms a hematoma, and extends and dissects along the longitudinal axis of the aorta. The main symptoms are acute, severe abdominal pain and hypertension.

The major risk factor of aortic dissection is hypertension (approximately 80% of cases). Additionally, atherosclerosis leads to thickening of the arterial intima, resulting in dystrophy of the tunica media of the arterial wall, which is regarded as an important causative factor of aortic dissection. Other causes of aortic dissection include idiopathic aortic medial degenerative change, congenital aortic valve abnormalities, Marfan syndrome, and trauma.<sup>2</sup> Aortic dissection is associated with the presence of dissection, rupture, or oppressive symptoms. The symptoms and signs in affected patients mainly depend on involvement of specific blood vessels and adjacent anatomical structures. Neurological sequelae occur in approximately one third of patients with DeBakey Types I and II dissection and less frequently in those with DeBakey Type III dissection.<sup>3</sup> The right carotid artery is more frequently involved than the left, and this often occurs in conjunction with innominate artery dissection. Poor visualization of the right internal common carotid artery is secondary to common carotid artery dissection, and cerebral severe hypoperfusion of the right hemisphere is shown by magnetic resonance imaging perfusion-weighted imaging.<sup>4</sup> The main neurological complications of aortic dissection are as follows: (i) major neurological deficit (coma or ischemic stroke), (ii) transient ischemic attack (TIA), (iii) spinal cord ischemia (paraparesis, paraplegia), (iv) ischemic neuropathy, and (v) hypoxic-ischemic encephalopathy. Among them, ischemic stroke is reported as the most frequent

complication because it affects up to one third of patients with aortic dissection. Other neurological consequences include syncope, generalized tonic-clonic seizures, somnolence, transient global amnesia, altered mental status, Horner's syndrome, vocal cord paralysis, hoarseness, and dysphagia due to organ displacement. In half of the patients with aortic dissection, neurological symptoms are transient. Rapid improvement in such cases is probably the result of transient arterial occlusion.<sup>5,6</sup>

Nervous system damage, such as cerebral stroke and spinal cord stroke, occurs when dissection involves aortic branch vessels. Some patients show transient symptoms, such as manifestations of hemiparesis, considerable TIA, dysarthria, and locked-in syndrome.<sup>7</sup> When a dissecting hematoma spreads along the innominate and carotid arteries or involves the subclavian and vertebral arteries, patients may develop dizziness, limb numbness, hemiplegia, paralysis, and coma. Compression of the cervical sympathetic ganglion induces Horner syndrome. When a dissecting hematoma involves the posterior intercostal artery and lumbar artery, paraplegia occurs as a result of transverse spinal cord injury. The above-described symptoms delay treatment because they are typically not associated with pain and only contribute to the diagnosis of nervous system disease. A previous study on anticoagulant therapy in patients with aortic dissection with brain stem infarction showed that some of these patients without pain symptoms presented with paraplegia or hemiplegia as the only clinical manifestation.<sup>8</sup> Therefore, thrombolytic therapy is suggested to be applied to patients with acute cerebral vascular disease before completion of a systematic examination. In our study, the first female patient showed symptoms of transient global cerebral ischemia that resulted from aortic dissection involving the arch vessels. The preliminary diagnosis at admission was brain stem infarction, and intravenous thrombolytic therapy was

proposed. The other patient showed paraplegia due to aortic dissection involving the spinal cord feeding artery, and her preliminary diagnosis was acute myelitis or anterior spinal artery occlusion.

The presence of nervous system symptoms has no significant effect on the overall mortality of patients with aortic dissection. Typical pain symptoms are apparent in 94% of patients with aortic dissection who present with no neurological symptoms.<sup>9</sup> Transient and persistent neurological symptoms can be found in 17% to 40% of patients with aortic dissection. Approximately two thirds of these patients have chest pain, and one third have no pain. These findings indicate that some patients with aortic dissection may be misdiagnosed because of the absence of pain symptoms, although nervous system symptoms are depicted as the onset symptom.<sup>10</sup> Imaging is the main approach to detecting aortic dissection. Thoracic and abdominal CT scans and CT angiography can determine the possibility of aortic dissection when patients develop nervous system symptoms, such as acute chest and abdominal pain or unexpected consciousness disturbance and paralysis.

### Declaration of conflicting interest

The authors declare that there is no conflict of interest.

### Funding

This research was supported by a grant from National Natural Science Foundation of China (no. 81641127).

### ORCID iD

Dongwei Zhang  <https://orcid.org/0000-0001-7814-1813>

### References

1. Dudzinski DM and Isselbacher EM. Diagnosis and management of thoracic aortic disease. *Curr Cardiol Rep* 2015; 17: 106. doi: 10.1007/s11886-015-0655-z.
2. Kolbel T, Diener H, Larena-Avellaneda A, et al. Advanced endovascular techniques for thoracic and abdominal aortic dissections. *J Cardiovasc Surg (Torino)* 2013; 54: 81–90.
3. Chen Y, Jeng J, Yip P, et al. Stroke in patients with common carotid artery dissection secondary to dissecting aortic aneurysm: an observational vascular imaging study. *J Med Ultrasound* 2002; 10: 20–25.
4. Matsubara S, Koga M, Ohara T, et al. Cerebrovascular imaging of cerebral ischemia in acute type A aortic dissection. *J Neurol Sci* 2018; 388: 23–27.
5. Sukockiene E, Lauckaite K, Jankauskas A, et al. Crucial role of carotid ultrasound for the rapid diagnosis of hyperacute aortic dissection complicated by cerebral infarction: a case report and literature review. *Medicina (Kaunas)* 2016; 52: 378–388.
6. Lin CM, Chang CH, Chen SW, et al. Direct neck exposure for rescue endovascular mechanical thrombectomy in a patient with acute common carotid occlusion concurrent with type A aortic dissection. *World Neurosurg* 2019; pii: S1878-8750(19)30179-2. doi: 10.1016/j.wneu.2019.01.081. [Epub ahead of print]
7. Nadour W, Goldwasser B, Biederman RW, et al. Silent aortic dissection presenting as transient locked-in syndrome. *Tex Heart Inst J* 2008; 35: 359–361.
8. Qin C and Tian D. Acute ischemic stroke due to painless long-segmental aortic dissection. *Neurology* 2019; 92: 484–485.
9. Bossone E, Corteville DC, Harris KM, et al. Stroke and outcomes in patients with acute type A aortic dissection. *Circulation* 2013; 128(11 Suppl 1): S175–S179.
10. Gaul C, Dietrich W and Erbguth FJ. Neurological symptoms in aortic dissection: a challenge for neurologists. *Cerebrovasc Dis* 2008; 26: 1–8.