


A Case of Symptomatic Myocardial Bridge Treated with Calcium Channel Blocker

Arash Nemat ¹⁻³, Atiqullah Majeedi², Abdul Wahed Sediqi^{2,4}, Qingchun Zeng¹

¹Department of Cardiology, Nanfang Hospital, Southern Medical University, Guangzhou, People's Republic of China; ²Department of Cardiology, Ariana Medical Complex, Kabul, Afghanistan; ³Department of Microbiology, Kabul University of Medical Sciences, Kabul, Afghanistan; ⁴Department of Cardiology, Ali Abad Teaching Hospital, Kabul University of Medical Sciences, Kabul, Afghanistan

Correspondence: Qingchun Zeng, Department of Cardiology, Nanfang Hospital, Southern Medical University, Guangzhou, 510515, People's Republic of China, Email qingchunzeng@smu.edu.cn; Arash Nemat, Department of Cardiology, Ariana Medical Complex, Kabul, Afghanistan, Email dr.arashnemat@yahoo.com

Abstract: Myocardial bridge (MB) is a congenital coronary anomaly in which a portion of the coronary artery courses intramyocardium instead of the normal trajectory on the epicardial surface. We report a case study with a 44-year-old man from Faryab Province in Afghanistan who presented chest pain and dizziness while suffering a common cold. After full investigation, the patient underwent coronary angiography which showed a myocardial bridge at the middle portion of the left anterior descending artery (LAD) with a significant stenosis causing ischemia. We treated the patient with a calcium channel blocker as initial treatment. The patient tolerated the medication well and remained asymptomatic during two years follow-up.

Keywords: myocardial bridge, coronary angiography, case report

Introduction

MB is a congenital coronary anomaly in which a portion of the coronary artery courses intramyocardium instead of the normal trajectory on the epicardial surface.¹ Usually MB does not cause significant clinical symptoms and, in rare cases, the coronary artery is affected under the overlying bridge muscle. If this occurs, more severe conditions may follow such as myocardial infarction, coronary spasm and even sudden cardiac death (SCD).^{2,3} The prevalence of MB varies based on tools used for its diagnosis. MB on coronary angiography ranges from 0.5% to 12%, and this range is lower for autopsy and coronary computed tomography angiography reporting 86% and 25%, respectively.⁴ Often MB remains silent but in symptomatic cases, medical management and surgical therapy are applied for revealing the symptoms regarding the severity of the anomaly.⁵ Due to minimal cases and fewer randomized trials on the treatment of MB, there was no certain pharmacological treatment options but generally the beta blockers and calcium channel blocker have been used as first line medical therapy for majority of symptomatic myocardial bridging cases.⁶⁻⁸

Herein we report a case of symptomatic MB in a 44-year-old man with compression of the anterior descending artery on each systole of the cardiac cycle that was treated successfully with a calcium channel blocker. To the best of our knowledge, this is the first case of myocardial bridging reported on a patient from Afghanistan.

Case Presentation

A 44-year-old pediatrician who works in Faryab Province in Afghanistan, presented with compressing chest pain and dizziness while suffering a common cold or sometimes during exertion. The patient had experienced the same symptoms previously when he had an upper respiratory infection and exertions. He had no history of heart disease and or smoking with blood pressure of 120/80 mm Hg, heart rate of 86 beats/minute with normal oxygen saturation (SpO₂=97%) and BMI of 30.4 and unremarkable physical examination. The patient tested negative for COVID-19, HIV and HBV and presented no abnormalities on abdominal ultrasonography. Chest x-ray, serial electrocardiography and cardiac enzymes were normal. Echocardiography revealed grade 1 left ventricular diastolic dysfunction with normal structural and valves of the heart (EF=60–65%). His blood examinations did not indicate any abnormalities. The patient underwent coronary

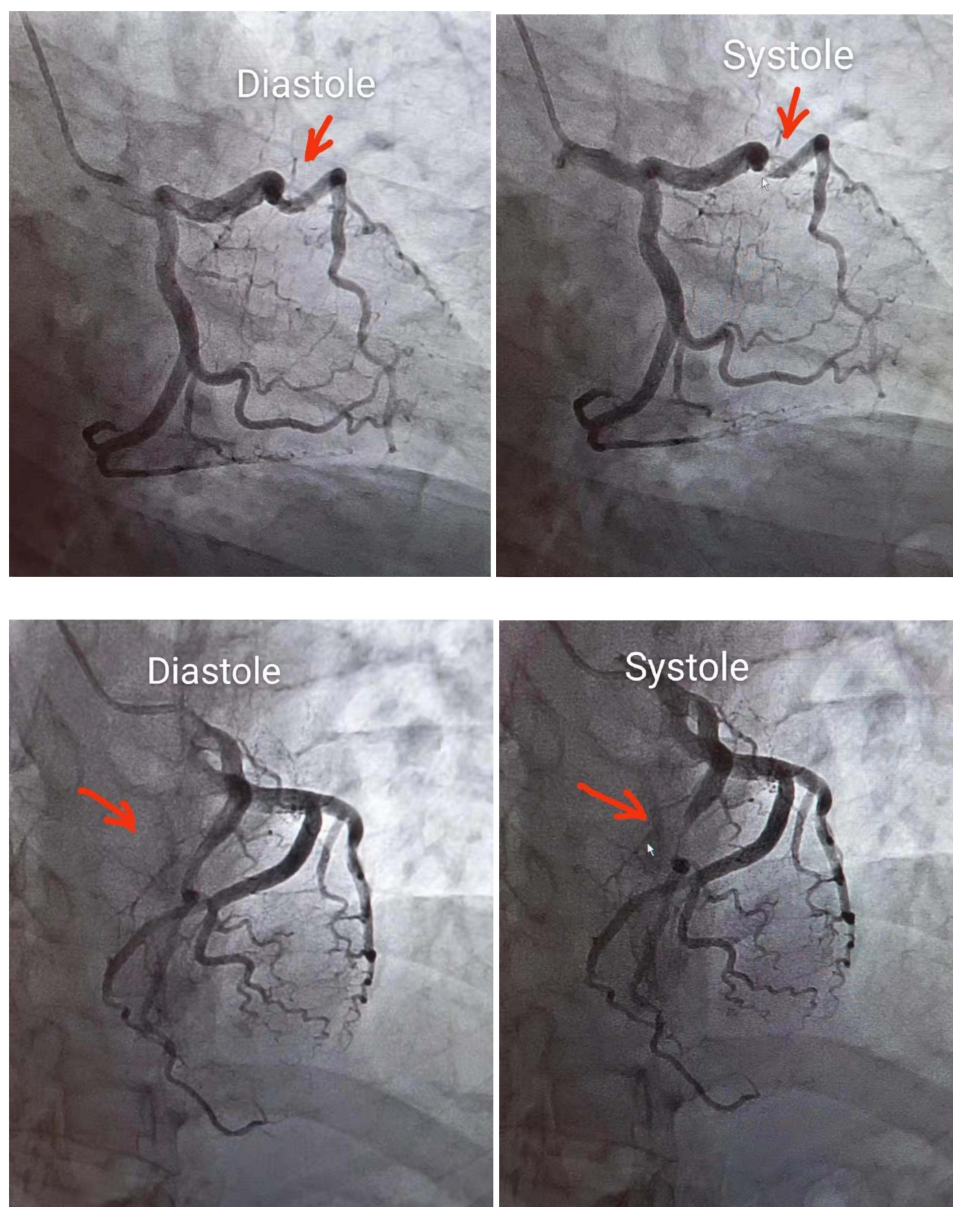


Figure 1 Coronary angiography showed systolic heavy compression at the middle portion of the left anterior descending artery.

angiography showing a MB at the mid-LAD with systolic compression with a significant stenosis. The milking effect, (ie, a systolic narrowing of the artery from a significant MB), was identified (Figure 1). To relieve the problem and prevent complications, we prescribed a calcium channel blocker, Diltiazem 60mg per day. The patient tolerated the medication well and remained asymptomatic during two years of follow-up.

Discussion

MB is a normally asymptomatic coronary anomaly which can exert an ischemic effect on the cardiac muscle with possible association with different cardiovascular pathologies including acute MI, hypertrophic cardiomyopathy, ventricular rupture, arrhythmias, and SCD.⁹ The rare presentation of coronary artery aneurysm combined with myocardial bridge was also reported by Ye et al.¹⁰ In addition, MB was reported with atrioventricular block which is a potential cause of repeated myocardial infarction and conduction abnormality.⁸ MB has mostly been reported at autopsy. MB-induced myocardial ischemia has rarely been reported in a live individual.

In this case presentation, we reported a patient with angiographic systolic compression of the middle portion of the LAD with subsequent control of symptoms with calcium channel blocker. Usually, MB remains asymptomatic without critical health conditions but rarely causes serious cardiovascular problems requiring medical or surgical care. The symptoms are caused by compression during systole on a portion of the coronary artery which tunneled intramyocardium leading to blood flow obstruction of the coronaries. This is particularly evident at elevated heart rates that shorten the diastolic filling time leading to increased flow obstruction during the cardiac cycle. Furthermore, increased contractility of the heart muscles can exacerbate the degree of vessel compression, further prolonging the obstructive effect. The severity of the MB is correlated with the risk of cardiovascular events such as atherosclerotic stenosis in the proximal part of the MB and may be affected by age, hypertension, Noble grade, and CRP level.¹¹ The middle portion of LAD (Mid-LAD) was predominantly the site for MB in most cases,^{12,13} which can be diagnosed through angiography demonstrating the milking effect on the overlying bridged segment.

Coronary angiography was performed showing a MB of the left anterior descending artery.¹⁴ The MB prevalence during coronary angiography varies, ranging from 0.5 to 16%.¹⁵ Matta et al, in a study of 35,000 patients referred for coronary angiography between June 2012 and June 2020, reported that MB of the LAD occurred in 1.42% of the study population.¹⁶ In Afghanistan, the incidence of MB among cardiovascular patients is unknown. Lack of official reports, shortage of diagnostic tools, and minimal specialized cardiac centers are the main reasons for undiagnosed MB cases in the country. MB incidence of 4.7% was reported in a large angiographic population in India, higher for males than females, and such anomaly involved predominantly compression on the mid part of LAD (61%).¹⁵

Afghanistan, due to regional similarity with India, may have a similar incidence of this congenital abnormality. As MB is reported to be one of the causes of SCD among healthy individuals, it is important to thoroughly evaluate each myocardial ischemic condition and treat MB-induced ischemia.

The treatment of MB consists of medical and surgical management.¹⁷ Pharmacological treatment with beta blockers or calcium channel antagonists is recommended as first-line therapy for patients with symptomatic MB.¹⁸ Cerrato et al indicated that patients with symptomatic isolated myocardial bridging generally have a good long-term prognosis and medical treatment alone is able to improve ischemia in most cases.⁷

In medical therapy, the first choice regards beta-blockers due to the fact that one of the main triggers for symptomatic patients is increased contractility of the myocardium and tachycardia with a reduction period for diastolic filling time which the beta-blockers can active negatively and prolong the diastolic perfusion intervals. Calcium channel blockers provide similar hemodynamic effects as beta-blockers and can be used as alternative to beta-blockers in symptomatic patients who cannot tolerate beta-blockers due to active bronchospasm or other contraindications to use of beta-blockers, and the Nitrates worsen the coronary compression in MB patients.^{5,19}

In this young patient who lives in one of the most challenging contexts globally, we preferred to prescribe the calcium channel blockers acting in a similar fashion as beta-blockers and preventing potential coronary spasm condition. Concomitantly, because the patient reported chest pain during the exertion and common colds experiences in the past, we avoided to prescribe the beta-blockers for relevant contraindication in bronchospasm or other worsening respiration conditions. Fortunately, our patient did not report any uncomfortable condition when he started our medication.

Conclusion

MB usually remains asymptomatic but rarely can cause mild ischemia to serious cardiovascular problems which require medical or surgical management. Medical therapy for MB-induced ischemia should be considered an optimal choice for most symptomatic patients.

Ethical Approval and Consent for Publication

The study was approved by the Kabul University of Medical Sciences Ethical Committee (KUMS-EC-1118-21). Written informed consent was obtained from the patient for publication of this case report and accompanying images.

Disclosure

The authors report no conflicts of interest in this work.

References

1. Maaliki N, Omar M, Ali AA, et al. Myocardial bridging unmask as an acute coronary syndrome from dehydration. *Case Rep Cardiol.* 2021;2021:5589776. doi:10.1155/2021/5589776
2. Ki Y-J. Myocardial bridging presenting as myocardial ischaemia induced cardiac arrest: a case report. *BMC Cardiovasc Disord.* 2021;21(1):1–6. doi:10.1186/s12872-021-01975-x
3. Kwan B, Singh A. Acute coronary syndrome caused by myocardial bridging. *Am J Emerg Med.* 2021;52:272.e1–272.e3. doi:10.1016/j.ajem.2021.08.080
4. Kawai H, Ohta M, Motoyama S, et al. Computed tomographic angiography–verified myocardial bridge and invasive angiography–verified left anterior descending coronary artery vasospasm. *JACC.* 2020;13(1):144–146. doi:10.1016/j.jcin.2019.08.023
5. Murtaza G, Mukherjee D, Gharacholou SM, et al. An updated review on myocardial bridging. *Cardiovasc Revasc Med.* 2020;21(9):1169–1179. doi:10.1016/j.carrev.2020.02.014
6. Lee MS, Chen C-H. Myocardial bridging: an up-to-date review. *J Invasive Cardiol.* 2015;27:521.
7. Cerrato E, Barbero U, D’Ascenzo F, et al. What is the optimal treatment for symptomatic patients with isolated coronary myocardial bridge? A systematic review and pooled analysis. *J Cardiovasc Med.* 2017;18(10):758–770. doi:10.2459/JCM.0000000000000551
8. Lin C, Lai C, Lin W, Lin C. Severe myocardial bridge presenting as paroxysmal atrioventricular block. *J Postgrad Med.* 2021;67:171. doi:10.4103/jpgm.JPGM_1027_20
9. Hostiuc S, Rusu MC, Hostiuc M, Negoii RI, Negoii I. Cardiovascular consequences of myocardial bridging: a meta-analysis and meta-regression. *Sci Rep.* 2017;7:1–13. doi:10.1038/s41598-017-13958-0
10. Ye Z, Dong XF, Yan YM, Luo YK. Coronary artery aneurysm combined with myocardial bridge: a case report. *World J Clin Cases.* 2021;9:3996–4000. doi:10.12998/wjcc.v9.i16.3996
11. Zhang J, Duan F, Zhou Z, et al. Relationship between different degrees of compression and clinical symptoms in patients with myocardial bridge and the risk factors of proximal atherosclerosis. *Evid Based Complement Alternat Med.* 2021;2021:2087609. doi:10.1155/2021/2087609
12. Mavi A, Sercelik A, Ayalp R, et al. The angiographic aspects of myocardial bridges in Turkish patients who have undergone coronary angiography. *Ann Acad Med Singapore.* 2008;37(1):49–53.
13. Şenöz O, Yapan Emren Z. Is myocardial bridge more frequently detected on radial access coronary angiography? *BMC Cardiovasc Disord.* 2021;21(1):564. doi:10.1186/s12872-021-02382-y
14. Piccione MC, Zito C, Trio O, et al. The diagnostic challenge of dipyridamole-atropine stress echocardiography in a patient with myocardial bridge. *J Cardiovasc Echogr.* 2016;26(4):120–122. doi:10.4103/2211-4122.192175
15. Karna SK, Chourasiya M, Parikh RP, Chaudhari T, Patel U. Prevalence of myocardial bridge in angiographic population-A study from rural part of western India. *J Family Med Prim Care.* 2020;9:1963–1966. doi:10.4103/jfmpe.jfmpe_1075_19
16. Matta A, Canitrot R, Nader V, et al. Left anterior descending myocardial bridge: angiographic prevalence and its association to atherosclerosis. *Indian Heart J.* 2021;73(4):429–433. doi:10.1016/j.ihj.2021.01.018
17. Zhang JZ, Zhu GY, Zhang Y, Bai LJ, Wang Z. Myocardial bridge bypass graft: a novel surgical procedure for extensive myocardial bridges. *Ann Thorac Surg.* 2021;112:e115–e117. doi:10.1016/j.athoracsur.2020.11.055
18. Teragawa H, Oshita C, Ueda T. The myocardial bridge: potential influences on the coronary artery vasculature. *Clin Med Insights Cardiol.* 2019;13:1179546819846493. doi:10.1177/1179546819846493
19. Duymun S, Misodi E. Myocardial bridging: a case presentation of atypical chest pain syndrome in a Young Woman. *Am J Case Rep.* 2020;21:e923075–e923071. doi:10.12659/AJCR.923075

International Medical Case Reports Journal

Dovepress

Publish your work in this journal

The International Medical Case Reports Journal is an international, peer-reviewed open-access journal publishing original case reports from all medical specialties. Previously unpublished medical posters are also accepted relating to any area of clinical or preclinical science. Submissions should not normally exceed 2,000 words or 4 published pages including figures, diagrams and references. The manuscript management system is completely online and includes a very quick and fair peer-review system, which is all easy to use. Visit <http://www.dovepress.com/testimonials.php> to read real quotes from published authors.

Submit your manuscript here: <https://www.dovepress.com/international-medical-case-reports-journal-journal>