

Oncology

A Rare Intrascrotal Metastases From Renal Cell Carcinoma: A Case Report



Essa Adawi*

Department of Urology, Charité University Hospital, Berlin, Germany

ARTICLE INFO

Article history:

Received 6 September 2015

Received in revised form

28 September 2015

Accepted 29 September 2015

Available online 23 October 2015

Keywords:

Renal cell carcinoma

Clear cell type

Testicular metastasis

Radical nephrectomy

Radical orchiectomy

ABSTRACT

Metastatic renal cell carcinoma is potentially a lethal disease with in some cases aggressive behavior. The given fact that the patterns of metastases from RCC are not clearly identified, which may involve some rare metastatic locations. We present a case of 58 years old male presented with painless left scrotal mass, which was discovered to be an intrascrotal metastases appeared 3 years after nephrectomy for ipsilateral renal cell carcinoma. We believe that the rarity of the metastatic site and the intriguing possible mechanism of spread make an interesting case for clinicians and could add more follow-up measures for patients treated from renal cell carcinoma.

© 2016 The Author. Published by Elsevier Inc. This is an open access article under the CC BY-NC-ND license (<http://creativecommons.org/licenses/by-nc-nd/4.0/>).

Background

Almost 30% of renal cell carcinoma can metastasize to various organs at the time of diagnosis.¹ The common organs of metastasis are the lungs 50%, bones 49%, lymph nodes 32%, skin 11%, liver 8%, and brain 3%.¹ To date there are only 33 published cases in the literature of metastatic RCC to the testis.¹ To date there are only 33 published cases in the literature of metastatic RCC to the testis.² This report presented the second case in the literature of pathologically proven scrotal metastasis from RCC with out testicular or epididymal invasion.

Case report

A 58-years old male was presented with localized pain and swelling in the left hemi-scrotum for 2 months. He had a past history of renal clear cell carcinoma pT3c G3 with adrenal metastasis and renal vein thrombosis from the left kidney after radical nephrectomy with adenectomy and renal vein thrombus removal 3 years prior to the current symptoms (Fig. 1). The final histopathology showed a negative tumor margins but with positive intrarenal lymph and blood vessels invasion. After surgery no adjuvant systemic therapy

was given. The routine follow-up imaging for the last 3 years did not show any relapse or metastases. The physical examination revealed a non-tender firm mass in the left hemi-scrotum. The left testis was not attached to of the mass. The blood work-up was within the normal range in clouding the testicular tumor markers (AFP 4.7 µg, LDH 4.3 U/l, β-HCG <0.1 IU/l). Ultrasound of the abdomen and the Scrotum revealed a 3 × 4 × 5 cm hyperdense mass with no evidence of testicular invasion.

Surgery was preformed through midline scrotal incision. The tumor was intravaginal with three blood vessel connection, one lateral vessel originated from the left testis and tow superior vessels were from the epididymis. There was no testicular invasion. The tumor was resected with safe margins and was sent for histopathological examination. No orchiectomy was preformed. Macroscopically it was 8 × 4 × 3.5 cm firm specimen. There was no involvement to the testis, tunicas, paratesticular soft tissue, or spermatic cord. Microscopically revealed partial eosinophilia partial clear cell solid neoplasia in a fibrous soft tissue with microscopic capillary networks. The tumor cells contain eosinophilic cytoplasm. The nuclei were prominent and parts of the nuclear pleomorphism were matching a Fuhrman nuclear grade 4. The tumor cells did not expressed vitamins, alkaline phosphatase and were CD10 negative (Fig. 2). Because of the unusual presentation, an immunopathological phenotype examination of the mass was compared with the one of the renal cell tumor diagnosed 3 years earlier that showed a good match. Thus the final impression was a scrotal metastasis of clear cell renal carcinoma.

* Corresponding author. Charité Universitätsklinikum, Campus Benjamin Franklin, Hindenburgdamm 30, 12200 Berlin, Germany.

E-mail addresses: Essa.adawi@charite.de, dr.adawi@gmail.com.

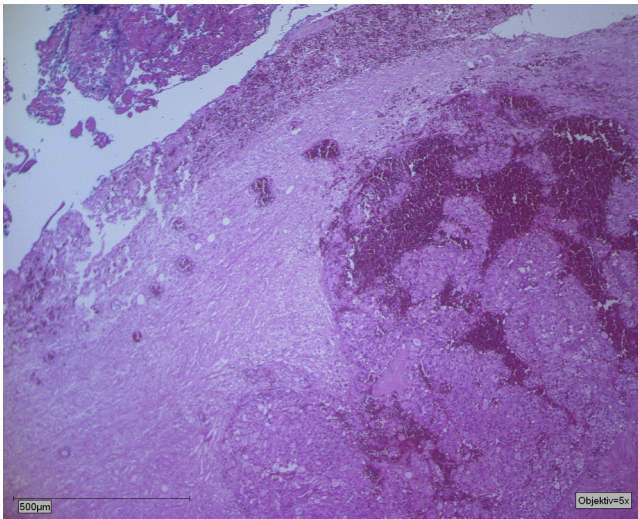


Figure 1. Scrotal metastasis from renal cell carcinoma (RCC).

Three weeks post operatively the patient was readmitted with scrotal abscess, which was treated with surgical evacuation and drainage. Again the testis was also spared from removal. Three, six and 12 months follow-up MRI showed no evidence of recurrence or metastases. The patient is doing well and till the date of this report no adjuvant systemic therapy was given.

Discussion

Metastases to the testis are rare because of low temperature in the scrotum that theoretically might reduce the tumor cells growth.³ Furthermore, the fact that the testis has a blood testis barrier formed by Sertoli cells adds another defense mechanism that inhibits tumor growth.³ Prostate cancer is considered the most frequent primary tumor that can metastasize to the testis, probably because orchiectomy is a modality of treating metastatic prostate cancer that could lead to isolating more testicular metastases.¹

Renal cell carcinoma commonly results in metastasis to different organs, yet rarely to the testis.³ Looking to the literature, using PubMed and Google scholar, the previous reported 33 cases described an intratesticular invasion of the metastasis from the renal cell carcinoma. The feature of the presented case is twofold: first we report the second case known in the literature of extra-testicular invasion,⁴ and the presence of renal vein thrombosis suggests the retrograde descent of tumor cells through the testicular veins as the mechanism of the metastases.¹

As it is extremely rare for renal cell carcinoma to metastasize to the testes, patients are incorrectly assumed to have independent testicular mass.⁵ The given fact that our patient was 58 years old and because of the ultrasound findings which exclude a direct testicular invasion the probability of a germ or non-germ cell tumors was unlikely. Non-Hodgkin lymphoma remains the most suspected diagnoses in patients older than 50⁵; however, in our patient the past history of relatively advanced Renal cell carcinoma with renal vein invasion raise the possibility of metastatic disease and directed the therapy plan.

Many previous attempts tried to understand the mechanisms of spread of renal cell carcinoma to the testis but it remained unclear. In many reports they suggest one of two mechanisms. The first is through retrograde descent of tumor cells through the testicular veins.³ This theory might be justified in the left ipsilateral renal tumor. However, given the differences in both sides anatomy, it is difficult to implement the same theory to the right side. Researchers argued that right side or bilateral testicular metastases are observed via Batson venous complex.¹ In our case the primary kidney and the scrotal metastasis are in the same left side, and therefore the spread through the testicular vein is more acceptable. It is, therefore, directing us to include scrotal ultrasound to the routine follow-up protocol for patient with left renal vein thrombosis.

Conclusion

This case represents a rare pattern of metastatic renal cell carcinoma to the Scrotum. Nonetheless, it gives the first evidence to including a routine scrotal ultrasound examinations in our follow-up plans for renal cell carcinoma patients with renal vein thrombosis, especially in the left side. Although this review is based on case report, it highlights the significance of case reporting especially in rare oncological scenarios where clinic trials or even case series are not possible.

Conflict of interest

There is no conflict of interest to declare.

References

- Steiner G, Heimbach D, Pakos E, Muller S. Simultaneous contralateral testicular metastasis from a renal cell carcinoma. *Scand J Urol Nephrol.* 1998;33:136–137.
- Moriyama S, Takeshit H, Adachi A, et al. Simultaneous bilateral testicular metastases from renal clear cell carcinoma: a case report and review of the literature. *Oncol Lett.* 2014;7:1273–1275.
- Birfari F, Risi O, Pino P. Secondary tumor of the testis: two cases and a review of the literature. *Urol Int.* 1992;48:469–470.
- Selli C, Woodard B, Paulson D. Late intrascrotal metastasis from renal cell carcinoma. *Urology.* 1982;20:423–425.
- Ulbricht T, Mills S, Greenson J, Oberman H. *Testicular and Paratesticular Tumors. Sternberg's Diagnostic Surgical Pathology.* 4th ed. Philadelphia: Lippincott Williams & Wilkins; 2004:2168–2190.

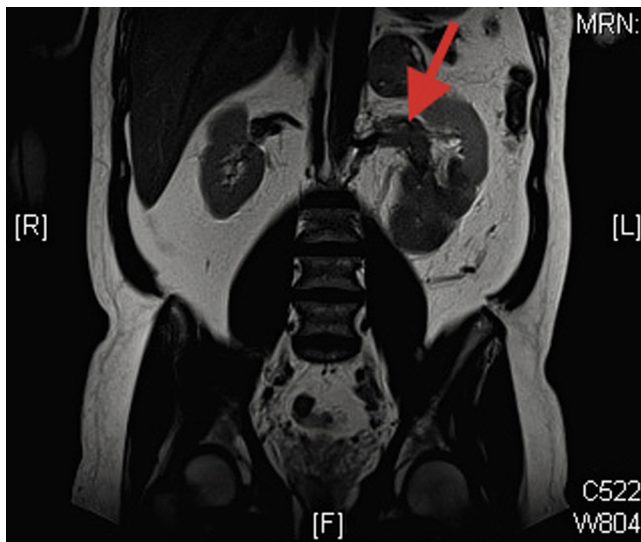


Figure 2. Abdominal MRI showing a left renal mass, (arrow) renal vein thrombosis.