

Received: 2014.12.14
Accepted: 2015.01.27
Published: 2015.05.22

ISSN 1941-5923
© Am J Case Rep, 2015; 16: 305-309
DOI: 10.12659/AJCR.893300

A Mass in the Junction of the Body and Tail of the Pancreas with Negative IgG4 Serology: IgG4-Related Disease with Negative Serology

EF **Eduardo A. Rodriguez**
F **Frederick K. Williams**

Department of Internal Medicine, University of Miami Palm Beach Regional Campus, Atlantis, FL, U.S.A.

Authors' Contribution:
Study Design A
Data Collection B
Statistical Analysis C
Data Interpretation D
Manuscript Preparation E
Literature Search F
Funds Collection G

Corresponding Author: Eduardo A. Rodriguez, e-mail: erodrigu18@yahoo.com
Conflict of interest: None declared

Patient: Female, 55
Final Diagnosis: Autoimmune pancreatitis
Symptoms: Abdominal pain • weight loss
Medication: Prednisone
Clinical Procedure: Admitted to the hospital
Specialty: Gastroenterology and Hepatology

Objective: Challenging differential diagnosis

Background: Autoimmune pancreatitis is an IgG4-related fibroinflammatory condition often associated with obstructive jaundice, as most lesions are located at the head of the pancreas. IgG4 level can help in the diagnosis, but it is normal in nearly 30% of affected patients.

Case Report: A 55-year-old woman presented with a 5-month history of 20-pound unintentional weight loss and intermittent abdominal pain. She had an unremarkable abdominal exam and significant findings included a small, non-mobile rubbery left axillary lymph node.

Complete blood count, complete metabolic panel, amylase, anti-smooth muscle antibody, antimitochondrial antibody, carcinoembryonic antigen, Ca 19-9, complement C3 and C4, antinuclear antibody, anti-Smith double-strand antibody, and IgG4 were all within normal limits.





CT of the abdomen showed a mass in the junction of the body and tail of the pancreas and endoscopic ultrasound showed it as encasing the splenic artery. Fine-needle aspiration cytology demonstrated follicular hyperplasia, obliterative phlebitis, storiform fibrosis, and negative staining for IgG4 and malignancy. Left axillary lymph node biopsy demonstrated follicular hyperplasia. PET scan revealed hypermetabolic uptake of the pancreas tail, bone marrow, and spleen, as well as diffuse lymphadenopathy. Bone marrow biopsy showed follicular hyperplasia and was negative for malignancy.

The patient was started on 40 mg of oral prednisone for possible autoimmune disease. During follow-up, she reported progressive improvement and a repeat PET scan 6 months later showed marked improvement.

Conclusions: A normal IgG4 value should not decrease the clinical suspicion of IgG4-related disease. If clinical, histological, and radiological findings coincide, glucocorticoids should be initiated with subsequent follow-up to evaluate for a response.

MeSH Keywords: Immunoglobulin G • Pancreas • Pancreatitis

Full-text PDF: <http://www.amjcaserep.com/abstract/index/idArt/893300>

 2020  —  2  33



Background

IgG4-related disease (IgG4RD) is a fibroinflammatory condition characterized by tumefactive lesions, a dense lymphoplasmacytic infiltrate rich in IgG4-positive plasma cells, storiform fibrosis, and often, but not always, elevated serum IgG4 concentrations [1]. The involvement of several organs has been well described [2–6], such as pancreas and lacrimal/salivary glands (Mikulicz's disease) and they all seem to share similar histopathological features.

Autoimmune pancreatitis (AIP) type 1 is a possible clinical presentation of this condition. It is usually characterized by a chronic onset, with classic imaging findings of a focal mass, especially in the head of the pancreas, or sausage-shaped enlargement of the pancreas with homogeneous attenuation, moderate enhancement, and peripheral rim of a hypoattenuating halo.

A lymphoplasmacytic infiltrate rich in IgG4 and a "periductal collar" that consists of lymphocyte and plasma cells, as well as obliterative phlebitis, are all considered typical of type 1 AIP.

Type 2 AIP is characterized by another histopathological pattern, termed idiopathic duct-centric pancreatitis (IDCP) or AIP with granulocytic epithelial lesion. Whereas type 1 AIP is classified as a pancreatic manifestation of IgG4RD, type 2 AIP is regarded more as a specific pancreatic disease [7].

The differential diagnosis for tumefactive masses and lymphoplasmacytic infiltrates should raise concern for possible IgG4RD [8]. Greater awareness of this condition and correct preoperative diagnosis could spare patients from major surgeries and other procedures. The following case emphasizes the importance of clinical correlation and histopathological findings in IgG4-related disease, as serology at times may not be a dependable marker.

Case Report

A 55-year-old Hispanic woman with a history of hypertension, on daily oral lisinopril 40 mg and hydrochlorothiazide 50 mg, presented with a 5-month history of unintentional 20-pound weight loss and an intermittent non-radiating abdominal pain that worsened after eating, and associated with nausea, vomiting, diaphoresis, and anorexia.

On physical exam, the patient was in no acute distress, with vitals in the normal range. The abdomen had active bowel sounds, and was soft, non-distended, non-tender, and without notable organomegaly. Left axillary exam revealed a small, non-mobile, rubbery lymph node within the deep tissue.

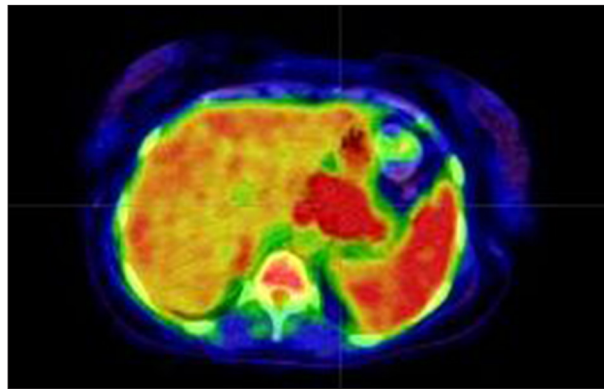


Figure 1. PET scan before initiation of steroids.

Hemoglobin, white count, complete metabolic panel, amylase, anti-smooth muscle antibody, antimitochondrial antibody, carcinoembryonic antigen, Ca 19-9, complement C3 and C4, antinuclear antibody, anti-Smith double-strand antibody, and IgG4 were all within normal limits.

CT of the abdomen showed a mass in the junction of the body and tail of the pancreas, measuring approximately 4 cm in size, without pancreatic duct dilatation. Endoscopic ultrasound (EUS) was performed to further characterize the findings and demonstrated a 48 mm by 38 mm mass encasing the splenic artery. Color Doppler did not reveal significant vascular structures within it and fine-needle aspiration cytology demonstrated follicular hyperplasia, with increased reactive lymphomatotic infiltrate, obliterative phlebitis, storiform fibrosis, and negative markers for IgG4 and no evidence of malignancy. Left axillary lymph node biopsy demonstrated follicular hyperplasia and interfollicular expansion by immunoblasts and plasma cells. Flow cytometry was negative for malignancy. A PET scan (Figure 1) revealed hypermetabolic uptake in the tail of the pancreas, bone marrow, and spleen, as well as mesentery, axillary, iliac, and inguinal lymphadenopathy. Subsequent bone marrow biopsy also revealed follicular hyperplasia, with flow cytometry negative for malignancy.

The patient was started on 40 mg of oral prednisone for possible autoimmune infiltrative disease and a weekly dose of 70 mg of alendronate and vitamin D supplementation.

During the following months, the patient began to report progressive decrease of symptoms, and a follow-up PET scan (Figure 2) 6 months later showed marked improvement. Ultimately, a prednisone tapering dose was completed, alendronate was discontinued, and DXA showed no osteopenia. The patient has been followed for almost a year as an outpatient since then, and has been asymptomatic, without any recurrence to date.

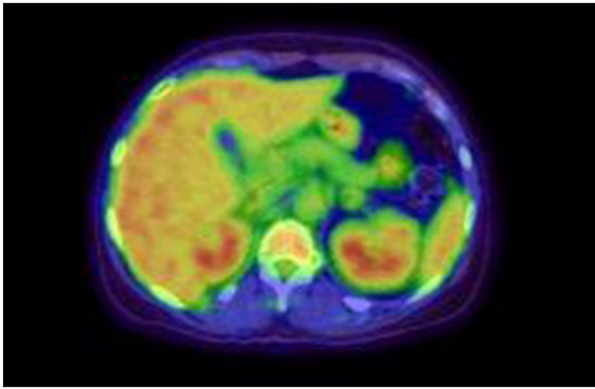


Figure 2. PET scan 6 months after initiation of steroids.

Discussion

IgG4RD usually presents subacutely, with patients not obviously appearing ill. Some patients present with symptoms confined to a single organ, while others present with multi-organ disease. Disease course tends to be indolent; however, local tissue destruction can also occur. There is a predilection to mass formation within organs, often misdiagnosed as malignancies. These masses are common in the orbital region, salivary glands, lung, biliary system, kidney, lymph nodes, and pancreas [1]. Our patient presented with an insidious course of gastrointestinal symptoms and was found to have a pancreatic tumoral lesion associated with widespread lymphadenopathy.

AIP pancreatitis was first described in 1961 by Sales et al. [9]. Yoshida et al. [10] first proposed the term AIP in 1995 when they reported the case of a patient with chronic pancreatitis, who had hyperglobulinemia, was autoantibody-positive, and responded to corticosteroid therapy. Clinical diagnostic criteria were established for the first time in 2002 by the Japan Pancreas Society (JPS) and have been revised frequently since then [11]. The International Consensus Diagnostic Criteria (ICDC) for AIP were developed taking into consideration various criteria available in order to safely diagnose AIP and to avoid misdiagnosis of pancreatic cancer. It was developed after reviewing the Mayo Clinic, Korean, Asian, JPS, Mannheim, and Italian criteria [12].

AIP is often associated with obstructive jaundice, as most of the lesions are found at the head of the pancreas, but our patient presented with a mass located at the junction of the body and tail, which is an atypical clinical presentation [13]. AIP can also present with mild abdominal pain and elevated pancreatic enzymes, which may also signal acute pancreatitis, or jaundice with proximal bile duct involvement, which must be differentiated from other causes such as cholangiocarcinoma. Sugumar [14] described possible pancreatic atrophy and steatorrhea in the later stages, resembling chronic pancreatitis. Less frequent manifestations include allergy such as atopy, eczema, asthma, and chronic sinusitis, which are present in 40%

of patients with IgG4-related disease [15]. Lymphadenopathy in IgG4RD generally takes 2 forms. In the first, there is localized involvement of lymph nodes adjacent to a specific affected organ; 80% of cross-sectional imaging studies of patients with AIP present with this finding (16, 17). In the second type of presentation, generalized lymphadenopathy is the sole component of the clinical presentation.

The imaging appearance of AIP can be diverse, dependent on multiple factors, including the degree of fibrosis and inflammatory infiltrate. Nevertheless the cardinal features of AIP are a focal or diffuse pancreatic enlargement with distortion and/or loss of the lobular architecture, known as sausage-shaped pancreas, a low-density rim surrounding the pancreas, and delayed pancreatic enhancement in the late arterial phase [18–20].

Pancreatic duct imaging with endoscopic retrograde pancreatography (ERP) can also be helpful, especially in patients with nonclassic CT abdominal features for AIP. ERP features of AIP include the presence of a long, narrow stricture (more than one-third of the main pancreas duct), the lack of upstream dilation from the stricture, side branches arising from the strictured portion of the duct, and multiple noncontiguous strictures [14].

Although PET has not been described as part of the routine workup for AIP, it is useful when looking for other possible organ involvement. In the present case, a CT of the abdomen was initially ordered, with the subsequent finding of a pancreatic mass. Concomitantly, a PET scan was done to evaluate potential affected organs that for possible biopsy. A repeat PET scan was conducted to evaluate treatment efficacy.

Most patients have elevated serum IgG4 concentrations. Strehl et al. [21] reported that serum IgG4 level >135 mg/dl resulted in high sensitivity and specificity (97%) in distinguishing autoimmune pancreatitis from pancreatic cancer. However, in recent studies, its sensitivity was as low as 68% [22,23]. Elevated IgG4 in tissue and serum are helpful in the diagnosis, but are not specific markers and are insufficient to make a diagnosis [24]. Although an elevated ratio of IgG4 to total IgG-positive plasma cells in tissue can confirm the diagnosis [25], approximately 30% of patients have normal values [1], as did our patient. Serum IgG4 concentrations tend to be higher in patients with multiple organ involvement [26], while patients in the last stages of the disease, which are characterized by prominent sclerosis, tend to have lower concentrations. Other diseases such as atopic dermatitis, parasitic infections, pemphigus vulgaris, pemphigus foliaceus, and pancreatic carcinoma, can also be associated with elevated levels of IgG4 [27].

Tissue biopsy findings include dense lymphoplasmacytic infiltrates, organized in a matted and irregularly whorled pattern (storiform), obliterative phlebitis, and mild-to-moderate

eosinophil infiltrate. This histologic subgroup is often known as type 1. Type 2, or IDCP, presents with granulocyte epithelial lesions [28–30] and does not generally stain for IgG4-positive cells. Both types of AIP respond well to steroid therapy, but type 2 AIP has a lower relapse rate than type 1 AIP and is not considered as part of the IgG4RD disease spectrum.

The patient we described most likely had type 1 AIP. The ICDC indicates that imaging and response to corticosteroids do not help in distinguishing type 1 from type 2 AIP. Typical serological abnormalities and other organ involvement are seen only in type 1, although inflammatory bowel disease has also been described in type 2. However the absence of serological abnormality does not necessarily imply the diagnosis of type 2, as type 1 also can be seronegative [12]. Shimosegawa et al. [12] reported that definite IDCP requires histological confirmation, and this histological pattern was not found in our patient.

Inappropriate operative resection for AIP is well described in the literature. Yadav et al. [31] reported that in their series 11% of patients who underwent pancreatic head resection for benign pancreatic disease were subsequently determined to have AIP.

Gardner et al. [32] stated that appropriate imaging studies and biopsy are essential for proper diagnosis. In patients with obstructive jaundice and diffusely enlarged pancreas without pancreatic ductal dilatation, AIP is highly likely. However, if typical pancreatic cancer findings are present (e.g., low-density mass and/or pancreatic dilatation), these patients should be considered as having pancreatic cancer unless the workup for cancer is negative.

In our patient, the pancreatic mass did not have the typical capsule-like rim, but also did not have a pancreatic duct cut-off, and had negative Ca 19-9. Patients without features typical of AIP or pancreatic cancer should first be investigated for pancreatic cancer [12,33]. To rule-out possible malignancy, tissue was obtained and this was negative for cancer.

Before starting corticosteroids, it is essential to obtain an objective marker to be followed over a defined period [32]. Our

patient was seen first once a week and then once every 2 weeks, always showing clinical improvement. A PET scan was repeated 6 months after initiation of corticosteroids, with remarkable improvement. However, if even after a short trial of corticosteroids the diagnosis remains in doubt, operative evaluation is reasonable [33].

The starting corticosteroid dose for remission is defined as prednisone 0.6–1 mg/kg per day with reassessment of imaging and serologic marker after 2 weeks of treatment [12,33]. An improvement in imaging abnormalities such as biliary strictures and pancreatic enlargement would be expected in AIP [12]. Elevated serum IgG4 levels can also decrease in patients with pancreatic cancer who are inappropriately treated with corticosteroids. However, a drop in Ca 19-9 would also be expected and a rise would suggest a different diagnosis [12,32].

There is still no consensus on the duration of the induction therapy and tapering schedule. Whether a maintenance therapy should be given to all patients with AIP or only restricted to those who relapse needs to be resolved. The Japanese groups recommend maintenance therapy with a low dose of prednisone for an extended period after induction of remission. The Mayo group, in contrast, suggests that not all patients should receive maintenance therapy, but the choice of medication, either steroid or immunomodulator, needs to be standardized. Larger randomized controlled studies are needed to form conclusions based on statistically significant results [33].

Conclusions

AIP typically presents as a mass within the pancreas, with typical obstructive jaundice. In the presence of elevated IgG4 and typical radiological findings, corticosteroid therapy can be started, with subsequent follow-up to evaluate for a response. However, in the absence of typical imaging findings, a thorough workup, including histology study and serology, should be ordered to rule-out malignancy. A normal IgG4 value should not decrease the clinical suspicion, as it is normal in up to 30% of patients.

References:

1. Stone JH, Zen Y, Deshpande V: Review article Mechanisms of disease IgG4-Related disease. *N Engl J Med*, 2012; 366: 539–51
2. Kamisawa T, Funata N, Hayashi Y et al: A401-9 new clinicopathology entity of IgG4-related autoimmunity disease. *J Gastroenterol*, 2003; 38: 982–84
3. Stone JH, Khosroshahi A, Hilgenberg A et al: IgG4-related systemic disease and lymphoplasmacytic aortitis. *Arthritis Rheum*, 2009; 60: 3139–45
4. Dahlgren M, Khosroshahi A, Nielsen GP et al: Riedel's thyroiditis and multifocal fibrosclerosis are part of the IgG4-related systemic disease spectrum. *Arthritis Care Res (Hoboken)*, 2010; 62: 1312–18
5. Saeki T, Saito A, Hiura T et al: Lymphoplasmacytic infiltration of multiple organs with immunoreactivity for IgG4: IgG4-related systemic disease. *Intern Med*, 2006; 45: 163–67
6. Kamisawa T, Takuma K, Egawa N et al: Autoimmune pancreatitis and IgG4-related sclerosing disease. *Nat Rev Gastroenterol Hepatol*, 2010; 7: 401–9
7. Okazaki K, Uchida K, Koyabu M et al: Recent advances in the concept and diagnosis of autoimmune pancreatitis and IgG4-related disease. *J Gastroenterol*, 2011; 46(3): 277–88
8. Deshpande V, Gupta R, Sainani NI et al: Subclassification of autoimmune pancreatitis: a histologic classification with clinical significance. *Am J Surg Pathol*, 2011; 35: 26–35

9. Sales H, Sarles JC, Muratore R et al. Chronic inflammatory sclerosis of the pancreas – an autonomous pancreatic disease? *Am J Dig Dis*, 1961; 6: 688–98
10. Yoshida K, Toki F, Takeuchi T et al: Chronic pancreatitis caused by an autoimmune abnormality. Proposal of the concept of autoimmune pancreatitis. *Dig Dis Sci*, 1995; 40: 1561–68
11. Kamisawa T, Okazaki K, Kawa S et al: Research Committee for Intractable Pancreatic Disease and Japan Pancreas Society. Japanese consensus guidelines for management of autoimmune pancreatitis. III. Treatment and prognosis of AP. *J Gastroenterol*, 2010; 45: 471–77
12. Shimosegawa T, Chari ST, Frulloni L et al: International consensus diagnostic criteria for autoimmune pancreatitis: guidelines of the International Association of Pancreatology. *Pancreas*, 2011; 40(3): 352–58
13. Ochoa M, Lopez B, Cabello R et al: IgG4-related multiorgan disease: report of the first autopsy case. *BMJ Case Rep*, 2013; 2013: pii: bcr2013009636
14. Sugumar A: Diagnosis and management of autoimmune pancreatitis. *Gastroenterol Clin N Am*, 2012; 41: 9–22
15. Kamisawa T, Anjiki H, Egawa N, Kubota N: Allergic manifestations in autoimmune pancreatitis. *Eur J Gastroenterol Hepatol*, 2009; 21: 1136–39
16. Stone JH: IgG4-related disease: nomenclature, clinical features, and treatment. *Semin Diagn Pathol*, 2012; 29(4): 177–90
17. Hamano H, Arakura N, Muraki T et al: Prevalence and distribution of extra-pancreatic lesions complicating autoimmune pancreatitis. *J Gastroenterol*, 2006; 41: 1197–205
18. Finkelberg D, Sahani D, Deshpande V et al: Review articles Current Concepts Autoimmune pancreatitis. *N Engl J Med*, 2006; 355: 2670–76
19. Takahashi N, Fletcher JG, Hough DM et al: Autoimmune pancreatitis: differentiation from pancreatic carcinoma and normal pancreas on the basis of enhancement characteristics at dual-phase CT. *Am J Roentgenol*, 2009; 193: 479–84
20. Ishigami K, Tajima T, Nishie A et al: MRI findings of pancreatic lymphoma and autoimmune pancreatitis: a comparative study. *Eur J Radiol*, 2010; 74: 22–28
21. Strehl JD, Hartmann A, Agaimy A: Numerous IgG4-positive plasma cells are ubiquitous in diverse localized non-specific chronic inflammatory conditions and need to be distinguished from IgG4-related systemic disorders. *J Clin Pathol*, 2011; 64: 237–43
22. Ryu JK, Chung JB, Park SW et al: Review of 67 patients with autoimmune pancreatitis in Korea. A multicenter nationwide study. *Pancreas*, 2008; 37: 377–85
23. Chari ST, Takahashi N, Levy MJ et al: A diagnostic strategy to distinguish autoimmune pancreatitis from pancreatic cancer. *Clin Gastroenterol Hepatol*, 2009; 10: 1097–103
24. Sah RP, Chari ST: Serologic issued in IgG4-related systemic disease and autoimmune pancreatitis. *Curr Opin Rheumatol*, 2011; 64: 237–43
25. Deshapande V, Zen Y, Chan JK et al: Consensus statement on the pathology of IgG4-related disease. *Mod Pathol*, 2012; 25: 1181–92
26. Kamisawa T, Okamoto A, Funata N: Clinicopathological features of autoimmune pancreatitis in relation to elevation of serum IgG4. *Pancreas*, 2005; 31: 28–31
27. Levy MJ, Wiesema MJ, Chari ST: Chronic pancreatitis: focal pancreatitis or cancer? Is there a role for FNA/biopsy? *Autoimmune pancreatitis. Endoscopy*, 2006; 38(Suppl.1): S30–35
28. Notohara K, Burgart LJ, Yadav D et al: Idiopathic chronic pancreatitis with periductal lymphoplasmacytic infiltration. Clinicopathologic features of 35 cases. *Am J Surg Pathol*, 2003; 2: 1119–27
29. Zamboni G, Luttgies J, Capelli P et al: Histopathological features of diagnostic and clinical relevance in autoimmune pancreatitis: a study on 53 resection specimens and 9 biopsy specimens. *Virchows Arch*, 2004; 445: 552–63
30. Sugumar A, Kloppel G, Chari ST: Autoimmune pancreatitis: pathologic subtypes and their implications for its diagnosis. *Am J Gastroenterol*, 2009; 104: 2308–10
31. Yadav D, Notahara K, Smyrk TC et al: Idiopathic tumefactive chronic pancreatitis: clinical profile, histology, and natural history after resection. *Clin Gastroenterol Hepatol*, 2003; 1: 129–35
32. Gardner TB, Levy MJ, Takahashi N et al: Misdiagnosis of autoimmune pancreatitis: a caution to clinicians. *Am J Gastroenterol*, 2009; 104(7): 1620–23
33. Kamisawa T, Chari ST, Lerch MM et al: Recent advances in autoimmune pancreatitis: type 1 and type 2. *Gut*, 2013; 62(9): 1373–80