

Tympanic Plexus Neurectomy for Intractable Ootalgia

Daniel S. Roberts, MD, PhD; Alisa Yamasaki, MD; Ahmad R. Sedaghat, MD, PhD; Daniel J. Lee;
Edward Reardon, MD

Objective: The goal of this study was to analyze whether tympanic plexus neurectomy is a successful surgical option in patients with intractable otalgia.

Study Design: A retrospective single institution study from the experience of two surgeons was conducted.

Methods: Records of adult patients with intractable unilateral otalgia of likely glossopharyngeal origin were reviewed, with institutional review board approval. Patients who responded to a tympanic plexus block were considered for tympanic neurectomy. Twelve patients (13 ears) underwent the procedure. Surgical outcomes and the presence of persistent otalgia were evaluated.

Results: Persistent otalgia was present for 16.7 months \pm 8.6 standard-error-of-the-mean months prior to an intervention. Narcotic medication was used in 41.7% of patients prior to surgery. Patients received tympanic plexus blocks (median: 1, range 1–3) prior to tympanic neurectomy to evaluate candidacy for surgery. Intractable otalgia resolved in six of 13 ears (46.2%) after one surgery, with an average follow-up of 25.5 months. A significant reduction in pain occurred in two of 13 ears (15.4%) after an initial surgery. One patient received no benefit from the initial procedure. Revision surgery occurred in four ears, resulting in pain relief in three of four cases. All together, nine of 13 ears received complete resolution of pain, and an additional two of 13 ears received partial benefit using our algorithm for treatment of intractable otalgia of tympanic plexus origin.

Conclusion: Intractable otalgia treated with tympanic neurectomy is a viable treatment option in cases of failed medical management. These findings provide important information that will aid clinicians in counseling chronic otalgia patients.

Key Words: Tympanic neurectomy, tympanic neuralgia, glossopharyngeal neuralgia, tympanic nerve, otalgia.

Level of Evidence: NA.

INTRODUCTION

Tympanic neurectomy was first proposed by Lempert in 1946 for the treatment of tinnitus and was named *tympanosympathectomy*.¹ Because this procedure failed to relieve tinnitus, it was not further considered. In 1962, Golding-Wood revived this technique, changing its name to the current *tympanic neurectomy*.² The procedure was used to relieve “paroxysms of agonizing and unbearable pain . . . felt deep in the ear.” This operation relieved pain in three of the four patients treated.

Tympanic plexus neuralgia is characterized by excruciating deep aural pain and was initially described by Reichert in 1933.³ Similar to trigeminal neuralgia, otalgia may be associated with a trigger area or with constant dull pain. In 1952, Rosen elicited the pain in two patients by stimulating Jacobson’s nerve with an electrode.⁴ Resection of the tympanic plexus in both patients led to

complete resolution of their symptoms. An additional series supported the success of this technique.⁵

The tympanic plexus is an arborization of nerves on the promontory of the middle ear. It is formed by the tympanic branch of the glossopharyngeal nerve, also known as Jacobson’s nerve, and the caroticotympanic branch of the internal carotid plexus. Jacobson’s nerve sends branches to the middle ear mucosa, Eustachian tube, and mastoid air cells—and sensory branches are distributed to the oval and round window area with branches to the tympanic membrane.^{5,6} Tympanic neurectomy is more widely described for the surgical management of chronic parotitis, chronic parotid sialiectasis, and Frey syndrome.^{7–9} In this study, we evaluate the long-term outcomes following tympanic plexus neurectomy for a cohort of patients with intractable otalgia.

MATERIALS AND METHODS

This study was approved by the Human Studies Committee of the Massachusetts Eye and Ear Infirmary (546787-2, PI: E. Reardon, MD). We performed a retrospective review of the medical and surgical records of patients over the period 2006 to 2015. Patients were included if they had 1) intractable otalgia of likely tympanic plexus origin, 2) failed medical management, and 3) responded to a tympanic plexus block with temporary improvement of otalgia. Patients were then offered tympanic plexus neurectomy. Ootalgia was considered to be likely of glossopharyngeal origin (i.e., originating from the tympanic plexus) based on a detailed history of the pain quality and severity (deep lancinating ear pain, usually in the range of 7–10 out of 10) and was present for months to years. Pain originating from the temporomandibular joint (TMJ) was ruled out through physical examination in all patients by palpation of the

This is an open access article under the terms of the Creative Commons Attribution-NonCommercial-NoDerivs License, which permits use and distribution in any medium, provided the original work is properly cited, the use is non-commercial and no modifications or adaptations are made.

From the University of Connecticut (D.S.R.), Division of Otolaryngology; the Department of Otolaryngology, Massachusetts Eye and Ear Infirmary (A.Y., A.R.S., D.J.L., E.R.); and the Department of Otolaryngology and Laryngology, Harvard Medical School (A.Y., A.R.S., D.J.L., E.R.), Boston, Massachusetts, U.S.A.

Editor’s Note: This Manuscript was accepted for publication 14 July 2016.

The authors have no funding, financial relationships, or conflicts of interest to disclose.

Send correspondence to Daniel Roberts, MD, PhD, 263 Farmington Avenue, Farmington, CT 06030. E-mail: droberts@uchc.edu

DOI: 10.1002/liv.2.31

TABLE I.
Patient Demographics.

	N	Average	SE	%
Age	12 (13 ears)	38.5	3.7	–
Female	7	–	–	58.3
Other pain syndrome	3	–	–	25.0
Duration of otalgia (months)	–	16.7	8.2	–
Known prior narcotic use	5	–	–	41.7
Etiology				
Spontaneous	6 (7 ears)	–	–	50%
Ear surgery	3	–	–	25%
Neck surgery	2	–	–	16.7%
Sudden hearing loss	1	–	–	8.3%

E = standard error.

TMJ—while the patient opened and closed the mandible—assessing for pain, crepitus, and inhibition of movement. A dental consultation was utilized in six of 12 patients, confirming the absence of TMJ disease. Imaging studies consisting of computed tomography (CT) of the temporal bone (10 of 12 patients) and magnetic resonance imaging (MRI) of the brain (7 of 12 patients) were performed as part of the evaluation in order to rule out other causes of otalgia. All patients were unsuccessfully treated with a medication targeting chronic neuropathic pain (i.e., gabapentin), and eight of 12 patients received an equivocal exam for determining the cause of pain from a neurologist. Patients were further deemed as surgical candidates based on their clinical response to a nerve block, which was created by injecting Xylocaine (AstraZeneca, Wilmington, DE) 1% with epinephrine 1:100,000 into the inferior aspect of the external ear canal, with vasoconstriction visualized medially along the tympanic membrane. If intractable otalgia improved, tympanic plexus neurectomy was offered. Demographic and medical data, which included age, sex, history of otologic surgery, duration of otalgia, and history of narcotic use, were accessed.

Surgical Procedure

Under general anesthesia after injecting the ear canal with Xylocaine (AstraZeneca, Wilmington, DE) 1% with epinephrine 1:100,000, the operative microscope was used to raise a tympanomeatal flap, and Jacobson's nerve was identified in all cases. A section of Jacobson's nerve was removed using cold steel microinstruments beginning at the inferior tympanic canaliculus, which extended superiorly to the area above the round window with adjacent nerves of the tympanic plexus; this procedure was termed *simple neurectomy*. The tympanomeatal flap was returned to the posterior canal, and gelfoam packing moistened with Ciprodex drops (Alcon Laboratories, Fort Worth, TX) was placed.

A more extensive surgical approach, termed *wide field tympanic neurectomy*, was developed for revision cases (four cases). An otologic endoscope was used in addition to microscopic visualization. Revision cases involved patients who had complete resolution of pain for several months, but the pain returned to preoperative levels. In these cases, there was visible regrowth of the nerve from the inferior tympanic canaliculus. All vestiges of the nerve and the plexus were removed from the hypotympanum and middle ear up to the point where Jacobson's nerve exited the mesotympanum. An argon laser was also used to ablate the plexus (Figure 1). In these cases, OtoMimix Bone Cement (Olympus, Germany) was used to occlude the

inferior tympanic canaliculus and the superior opening of the nerve tract.

RESULTS

A total of 12 patients fulfilled our inclusion criteria after responding to tympanic plexus block and underwent tympanic plexus neurectomy in 13 ears. Patients received tympanic nerve blocks (median: 1, range 1–3) prior to being offered tympanic neurectomy.

Table I shows the demographic characteristics of our patient cohort. The average age of the patients was 38.5 years. Female patients represented 58.3% (7 of 12) of the patients. Prior chronic pain conditions (chronic abdominal pain, interstitial cystitis, migraine) were present in three of 12 (25.0%) of the patients. The average duration of otalgia prior to surgical intervention was 16.7 months. Known prior narcotic use for otalgia occurred in five (41.6%) of the patients.

Patients were stratified into four categories based on clinical history: 1) No precipitating causes were categorized as spontaneous otalgia and represented 50% of patients (6 patients, 7 ears); 2) three patients (25%) had undergone prior ear middle surgery with no other symptoms other than persistent otalgia; 3) two patients developed recalcitrant otalgia after deep neck space infections with surgical drainage; and 4) one patient had otalgia after a history of sudden sensorineural hearing loss.

Spontaneous Otalgia

Spontaneous otalgia with no other identifiable etiologies occurred in six patients (7 ears) who underwent surgery. All patients had imaging studies (MRI and/or CT), with two cases showing sclerosis of the mastoid air space. Tympanic membranes and hearing was normal in these cases. All patients had neurological evaluations and failed medical management for persistent otalgia. For cases with a sclerotic mastoid (2 cases), a simple mastoidectomy was also performed at the time of tympanic plexus neurectomy. Otalgia completely resolved in six of seven ears, and one ear had partial improvement. However, over a 1-year period, otalgia recurred in four of six ears. All four patients had revision surgery that included a wide field approach, removing all visible neural tissue with endoscopes, laser ablation of the tympanic plexus on the promontory, and closing the inferior and superior canaliculi with Otomimix (Olympus). Of the revision cases, three had complete control of persistent otalgia (follow-up 20 months to 7 years). One patient did not benefit from revision surgery. Overall, five of seven ears ultimately had complete control; one patient had a partial response; and one patient did not benefit from revision surgery.

Prior Ear Surgery

Three ears had a history of ear surgery for chronic otitis media. Two patients had a history of tympanomastoidectomy, and one patient previously had a tympanoplasty. Two patients had complete control of otalgia with simple neurectomies (follow-up 2 years for both

TABLE II.
Treatment and Success Rate for 12 Patients (13 Ears).

	N	Average	SE	%
Primary Surgery				
Complete responders	6	-	-	46.2
Follow-up (m)	-	25.5	10.7	-
Partial responders	2	-	-	15.4
Follow-up (m)		37.1	24.6	
Initial total responder, otalgia recurred	4	-	-	30.7
No improvement	1	-	-	8.3
Revision Surgery				
Revision surgery rate	4	-	-	30.7
Complete responders	3	-	-	23.1
Follow-up (m)		15.7	4.6	-
No improvement	1	-	-	7.6

SE = standard error.

patients). One patient had a self-reported 50% improvement of persistent otalgia.

Otalgia Following Neck Surgery

Two patients underwent tympanic plexus neurectomy with a history of neck surgery for the indication of a deep neck space infection. Persistent otalgia occurred in one patient after a level II deep neck space abscess that required surgical drainage. Simple tympanic plexus neurectomy resulted in complete control of the pain (follow-up 5.5 years). A second patient, with a history of mandibular split for mucoepidermoid cancer of the base of tongue and radiation 30 years prior, developed a deep neck infection resulting in intractable otalgia. Simple tympanic neurectomy resulted in the resolution of otalgia (follow-up 6 years).

Otalgia After Sudden Hearing Loss

A single patient developed persistent otalgia after sudden hearing loss. The otalgia had no other identifiable causes. No improvement was noted after tympanic plexus neurectomy.

Cumulative surgical outcomes are presented in Table II. A single surgical procedure resulted in resolution of otalgia in six of 13 (46.2%) ears, with a mean

TABLE III.
Tympanic Plexus Neurectomy for the Indication of Otalgia.

	Resolution of Otalgia (Ears Treated)		
	Complete	Partial	None
Rosen, 1952. ⁴	2	0	0
Golding-Wood, 1962. ²	3	0	1
Friedman et al., 1974. ⁵	1	0	0
Cook, 1990. ¹⁷	2	0	0
Roberts et al., 2016*	9	2	2
Total	17	2	3

*Current study includes data from revision surgery when indicated.

postoperative follow-up time of 25.5 months. Pain was noticeably reduced in two of 13 patients (15.4) after one surgery at a mean follow-up time of 37.1 months, and these patients elected for no further interventions. Four patients elected for revision tympanic plexus neurectomy due to worsening otalgia after initial complete benefit, and three of these patients subsequently received full resolution of otalgia after a second surgery. One patient received no benefit from revision tympanic plexus neurectomy, and no further interventions for tympanic neuralgia were performed. One patient received no benefit from single tympanic plexus neurectomy. Overall, nine of 13 ears received complete resolution of pain; two of 13 ears received partial benefit; and two ears had no improvement, using our algorithm for treatment of intractable otalgia of tympanic plexus origin (Table III).

There was no significant morbidity associated with the procedure. Notably, no patients described chronic dry mouth following surgery. No tympanic membrane perforations occurred following surgery. One patient reported self-limited bleeding following surgery. Audiometric performance was unchanged postoperatively after tympanic plexus neurectomy for all patients.

An additional four patients were identified as having clinical symptoms of glossopharyngeal neuralgia but did not undergo surgery after undergoing tympanic plexus block. One patient with a history of idiopathic otalgia did not respond to the tympanic plexus block. Further workup identified causes for otalgia in two patients (pituitary adenoma, ear canal cholesteatoma); therefore, tympanic plexus neurectomy was not offered. One patient with a history of multiple previous ear surgeries was treated biannually with tympanic plexus blocks to control persistent otalgia.

DISCUSSION

Tympanic plexus neurectomy is a surgical procedure that ablates the tympanic plexus with the goal of relieving persistent ear pain. In this study, we examined the outcomes of tympanic neurectomy, illustrating the largest series of patients undergoing the surgery for chronic intractable otalgia. To our knowledge, these data represent the first report of this surgical modality in 25 years.

Glossopharyngeal neuralgia is a rare condition and is estimated to be present in 0.2 to 0.7 per 100,000 people per year.¹⁰ Classic symptoms include severe chronic pain of the ear, base of tongue, tonsillar fossa, and angle of the jaw. Glossopharyngeal neuralgia of tympanic plexus origin is a diagnosis of exclusion. Primary otologic disease must be ruled out with physical exam and imaging. Imaging should include CT temporal bone without contrast; CT neck with contrast, if there is a concern for malignancy; and MRI of the head with gadolinium, focusing on the root exit of cranial nerves IX and X, to rule out microvascular compression. Flexible endoscopy must rule out upper aerodigestive lesions before consideration of a tympanic plexus source. Neurologic and dental evaluations may be considered in cases of atypical pain syndromes or concern for TMJ syndrome. When

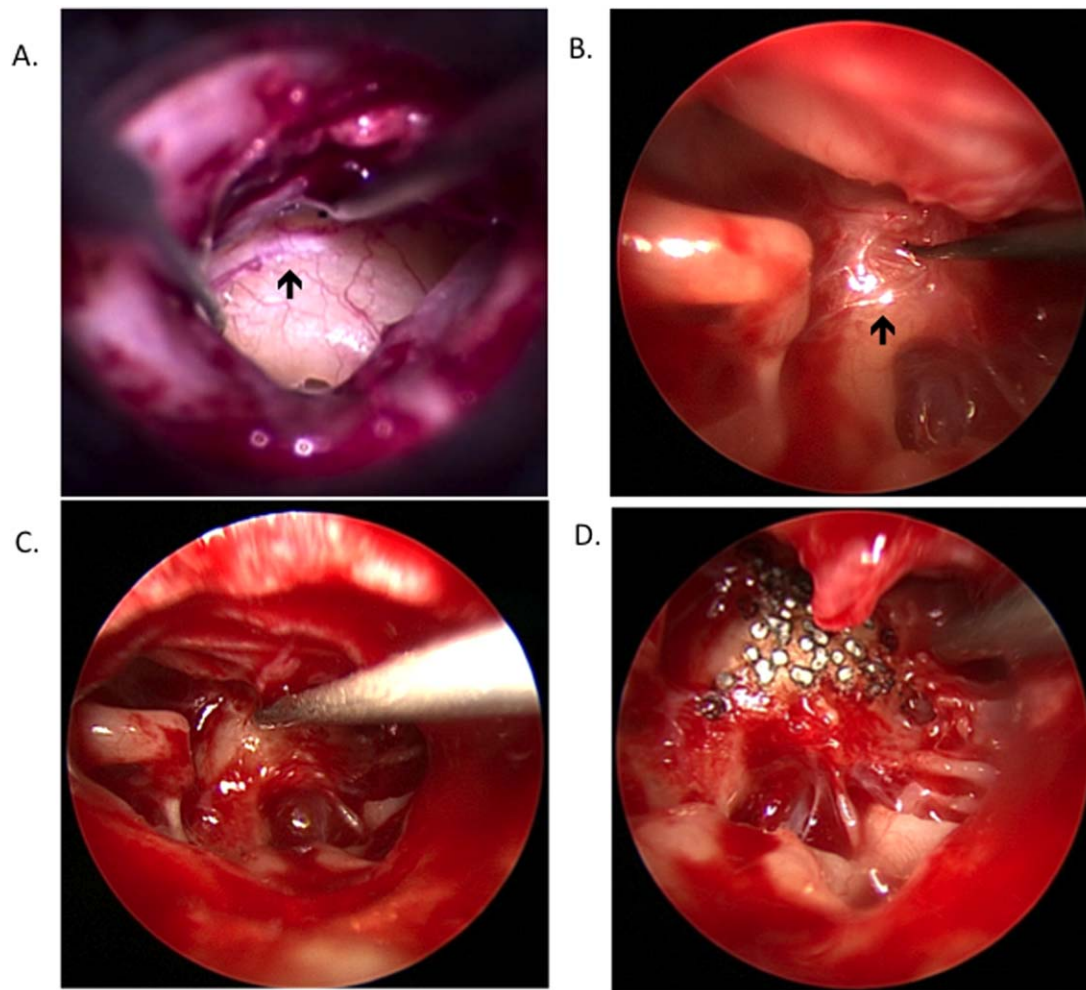


Fig. 1. Tympanic neurectomy for intractable otalgia. (A–B) Examples of the tympanic plexus over the cochlear promontory of the middle ear. (C) Sharp dissection to ablate the neural tissue along the promontory. (D) Argon laser used to ablate the tympanic plexus.

possible, an injection of local anesthetic into the inferior ear canal, with blanching of the skin to the tympanic membrane, may be utilized. The nerve block is nonspecific, and a positive response is consistent with glossopharyngeal neuralgia but is not pathognomonic. Symptoms must be differentiated clinically from other forms of otologic neuropathic pain originating from the Arnold's nerve or sensory auricular branch of the facial nerve, which is characterized by external auditory canal (EAC) or conchal bowl symptomatology.¹¹ In cases of EAC or conchal bowl pain, ablation of these nerves could also be considered.

Neurosurgical management is indicated in refractory cases with rhizotomy and microvascular decompression at the level of the root exit of cranial nerves IX and X. For these procedures, pain control rates range from 85% to 96%, with permanent cranial neuropathy rates of 6% to 18%. Here, we report the outcomes of patients with isolated ear pain, a subset of patients representing 11.3% of patients with glossopharyngeal neuralgia.¹⁰ Our findings show complete resolution of otalgia in 69.2% of cases, with a 15.4% rate of partial benefit suggesting that tympanic plexus neurectomy may be a

reasonable surgical modality in appropriately selected patients with minimal morbidity. These findings are consistent with those of several smaller series (Table III).

Partial responders or failures may represent patients experiencing otalgia due to other causes, for example, from Arnold's nerve or from referred pain or a different etiology. Our diagnostic algorithm utilizes canal injection of Xylocaine (AstraZeneca, Wilmington, DE) into the inferior external ear canal, with vasoconstriction visualized at the tympanic membrane. Such an approach is capable of targeting sensory fibers of the tympanic plexus, which extend to the medial tympanic membrane and middle ear but also are capable of reaching sensory fibers of auriculotemporal nerve, sensory branches of the facial nerve, and Arnold's nerve.^{6,11} The complex sensory innervation of the ear canal presents the possibility of false positives, possibly accounting for our rate of partial responders and failures. Further, evaluation included both CT of the temporal bone and MRI of the brain in the majority of patients; however, both imaging modalities were not used in all cases. It is possible that an alternative disease process was missed in partial responder or failure cases. Both imaging

modalities are advocated because CT will show lesions with bone involvement, whereas MRI is best suited for the identification of vascular loops at the root exit of cranial nerves IX and X.

It is also possible that the tympanic plexus was not adequately ablated in our partial responders or failure cases due to the known complexity of tympanic plexus arborization to include variable hypotympanic branching.¹² For our failure cases, simple neurectomy was utilized as an initial modality. Subsequent complete resolution of symptoms occurred after wide field tympanic neurectomy in three of four cases, possibly illustrating the benefit of the wide field approach. Anatomical studies also indicate that Jacobson's nerve may be entirely encased in a bony canal in the middle ear identified in two of 16 cases, possibly leading to surgical failure.¹³ Regrowth of the tympanic plexus has not been studied, but our case series illustrates possible regrowth requiring revision surgery. Indeed, presumed regrowth was visualized with the aid of an endoscope. In our revision cases, (Olympus) was placed in the proximal and distal bony canal openings for Jacobson's nerve, and the Argon laser was used to ablate all visible fibers. Such use of the laser is supported by experimental evidence, showing that CO2 laser may be utilized to perform tympanic plexus neurectomy by means of obliterating Jacobson's nerve in the promontory region without sensorineural hearing loss.¹⁴ Laser-assisted tympanic plexus neurectomy with an argon laser appears to be safe in our small cohort. All future tympanic plexus neurectomy procedures will use wide field tympanic neurectomy approach due to our success with revision cases and no added morbidity.

An alternative modality to test for otalgia of tympanic plexus nerve origin is middle ear injection of a local anesthetic described by W. H. Slattery and D. E. Brackmann (oral communication, September, 2015).¹⁵ This modality has an added level of specificity by circumventing anesthesia of the Arnold's nerve, which is also targeted by a canal injection. However, the added specificity of intratympanic anesthesia must be balanced with a possible risk of temporary facial nerve paralysis in the case of a dehiscent facial nerve; vertigo, which may occur in some cases; or temporary impairment of auditory function, previously illustrated by alterations in transiently evoked otoacoustic emissions.¹⁶

Several limitations of our study are acknowledged. Because this is a retrospective study, there is the risk of bias from this type of evaluation. We also did not use pain or quality-of-life surveys in the assessment of

outcomes. Rather, the subjective interpretations of two clinicians were utilized. Three patients received tympanic plexus neurectomy at the time of surgery for chronic otitis media, introducing the possibility for selection bias. A prospective study at our institution with a larger number of patients will incorporate such instruments. Finally, these data represent two surgeons' experience with tympanic plexus neurectomy.

CONCLUSION

Tympanic plexus neurectomy appears to be a safe and efficacious procedure in properly selected patients with chronic otalgia. These observations provide useful guidance for clinicians counseling patients with chronic otalgia who are considering tympanic neurectomy.

Acknowledgment

We would like to acknowledge Dr. Saamil Merchant and Dr. Robert Lofgren, who provided guidance for our first tympanic neurectomy cases.

BIBLIOGRAPHY

1. Lempert J. Tympanosympathectomy; a surgical technic for the relief of tinnitus aurium. *Arch Otolaryngol* 1946;43:199-212.
2. Golding-Wood PH. Tympanic neurectomy. *J Laryngol Otol* 1962;76:683-693.
3. Reichert FL. Tympanic plexus neuralgia. *JAMA* 1933;100:1744-1746.
4. Rosen S. Surgery and neurology of Meniere's disease. I. Role of the chorda tympani nerve in tinnitus, vertigo, and deafness. *Arch Otolaryngol* 1952;56:152-160.
5. Friedman WH, Swerdlow RS, Pomarico JM. Tympanic neurectomy: a review and an additional indication for this procedure. *Laryngoscope* 1974;84:568-577.
6. Arslan M. The innervation of the middle ear. *Proc R Soc Med* 1960;53:1068-1074.
7. Motamed M, Laugharne D, Bradley PJ. Management of chronic parotitis: a review. *J Laryngol Otol* 2003;117:521-526. Review.
8. Daud AS, Pahor AL. Tympanic neurectomy in the management of parotid sialectasis. *J Laryngol Otol* 1995;109:1155-1158. Review.
9. Hays LL. The Frey syndrome: a review and double blind evaluation of the topical use of a new anticholinergic agent. *Laryngoscope* 1978;88:1796-1824.
10. Rey-Dios R, Cohen-Gadol AA. Current neurosurgical management of glossopharyngeal neuralgia and technical nuances for microvascular decompression surgery. *Neurosurg Focus* 2013;34:E8.
11. Eshraghi AA, Buchman CA, Telischi FF. Sensory auricular branch of the facial nerve. *Otol Neurotol* 2002;23:393-396.
12. Donaldson. Surgical anatomy of the tympanic nerve. *J Laryngol Otol* 1980;94:163-168.
13. Tekdemir I, Aslan A, Tuccar E, et al. An anatomical study of the tympanic branch of the glossopharyngeal nerve (nerve of Jacobson). *Ann Anat* 1998;180:349-352.
14. Lima JA, Wilpizeski CR. Effectiveness of the CO2 laser in experimental tympanic neurectomy. *Laryngoscope* 1980;90:414-422.
15. Slattery WH, Brackmann, D. Use of intratympanic lidocaine to identify glossopharyngeal neuralgia. *Personal Communication to DSR*. 2016.
16. Laurikainen EA, Johansson RK, Kileny PR. Effects of intratympanically delivered lidocaine on the auditory system in humans. *Ear Hear* 1996; 17:49-54.
17. Cook JA, Irving RM. Role of tympanic neurectomy in otalgia. *J Laryngol Otol* 1990;104:114-117.