

Contents lists available at [ScienceDirect](https://www.sciencedirect.com)

International Journal of Surgery Case Reports

journal homepage: www.casereports.com

Psoas abscess masquerading as a prosthetic hip infection: A case report

Muhammad Atif, Azeem Tariq Malik*, Shahryar Noordin

Section of Orthopaedic Surgery, Department of Surgery, Aga Khan University, Karachi, Pakistan



ARTICLE INFO

Article history:

Received 30 October 2017

Received in revised form

26 November 2017

Accepted 28 November 2017

Keywords:

Psoas abscess

Prosthetic hip infection

Pyelonephritis

Case report

ABSTRACT

INTRODUCTION: Psoas abscess is an unusual condition and is defined as a collection of pus in the iliopsoas compartment. Due to the unique anatomy of psoas muscle it forms a conduit for spread of infection from upper part of body to hip joint in neglected cases.

CASE PRESENTATION: A 67 year old lady presented with left groin pain for three weeks. She underwent an uncemented unipolar hemiarthroplasty eight years back. Currently, she developed fever and was unable to do any active left hip range of motion. Passive motion of the left hip was restricted to 30° flexion, no internal rotation, 5° external rotation, and 10° abduction. Lab workup showed raised serum infective markers and radiographs of pelvis were normal with no evidence of any radiolucency. Ultrasound guided aspiration of left hip joint showed *E. coli*. Arthrotomy revealed clear fluid in hip joint but pus was drained at psoas insertion. Later on, culture reported presence of *E. coli* and biopsy confirmed psoas abscess. Post-operatively CT scan abdomen showed pyelonephritis. Antibiotics were given for three months. Twenty months later, she remains asymptomatic without evidence of infection with normal gait.

DISCUSSION: Psoas abscess is a rare clinical entity that may mimic symptoms of a primary prosthetic hip infection. Treatment outcomes are directly related to early detection with adequate dissection of the psoas muscle up to sites of attachment and complete eradication of infection.

CONCLUSION: This case highlights importance of thorough initial clinical examination, lab workup and radiological assessment to rule out rare causes of hip joint pain.

© 2017 Published by Elsevier Ltd on behalf of IJS Publishing Group Ltd. This is an open access article under the CC BY-NC-ND license (<http://creativecommons.org/licenses/by-nc-nd/4.0/>).

1. Introduction

Psoas abscess is considered as a collection of pus in iliopsoas compartment. It was first described by Mynter in 1881 who described this condition as Psoitis [1]. It is a rare presentation with studies showing an incidence of 0.4/100 000 in UK [2]. Moreover, the diagnosis is complicated by nonspecific clinical presentations. It can occur primarily via hematogenous or lymphatic spread due to conditions such as diabetes, intravenous drug abuse, renal failure and immunosuppressive causes. It can also occur secondarily as a result of a direct spread from adjacent infected structures. Abscesses can be associated with Crohn's disease, appendicitis, complicated pancreatitis and osteomyelitis of vertebral bodies, diverticulitis, ulcerative colitis, urinary tract infection, post-partum infection, spondylodiscitis, or an infection of sacroiliac joint. Because of its unique anatomical location with origins from the lateral borders of 12th thoracic vertebra to 5th lumbar vertebrae and insertion as a conjoint tendon with the iliacus into the lesser trochanter [3], the psoas muscle forms a 'conduit' for

spread of infection from upper part of body to hip joint in neglected cases.

Dauchy et al. reported a 12% association between a psoas abscess and prosthetic joint infection [4]. Modern aseptic techniques have been instrumental in reducing the primary prosthetic joint infection rate to 0.3% to 2% and as high as 20% in revision surgery [5,6]. A prompt diagnosis and immediate effective treatment against the offending agent is imperative in order to prevent the devastating effects of prosthetic joint infection. A delay in management may result in removal of prosthesis, multiple wound debridements, prolonged hospital stay, long term antibiotic therapy and revision surgery. This study has been reported in line with the SCARE guidelines [7]. In accordance with the declaration of Helsinki, this study has also been registered at [Researchregistry.com](http://www.researchregistry.com)(researchregistry3204).

2. Presentation of case

A 67 year old diabetic lady presented with left groin pain for three weeks off and on associated with fever to the Orthopedic Clinic at the Aga Khan University Hospital, an academic tertiary care hospital in Karachi, Pakistan. She underwent un-cemented unipolar hemiarthroplasty of the left hip 8 years back. On examination,

* Corresponding author at: 11 – Tariq Block, New Garden Town, Lahore, Pakistan.
E-mail address: azeemtariq94@gmail.com (A.T. Malik).

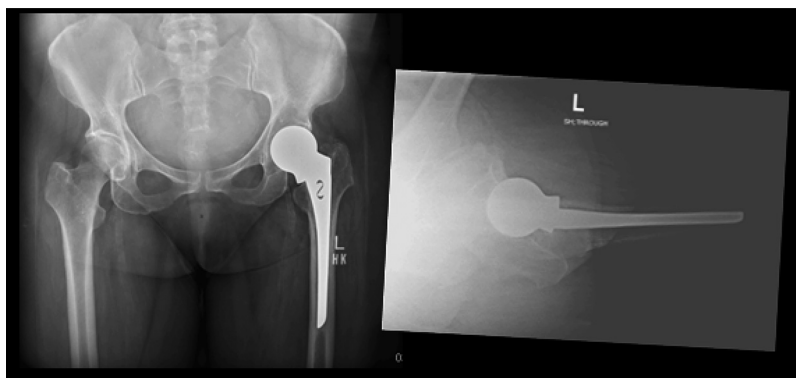


Fig. 1. Preoperative radiograph showing the Uncemented Hemiarthroplasty with no obvious lysis or loosening of hip prosthesis.

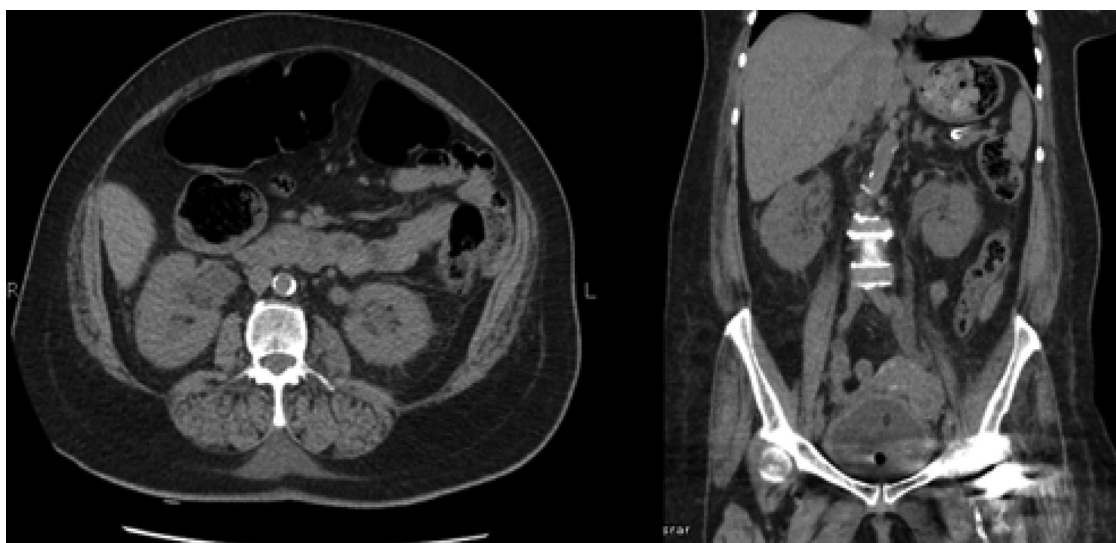


Fig. 2. CT Abdomen showing Bilateral perinephric fat stranding with dilated ureters and bladder wall thickening suggestive of pyelonephritis.

she was unable to elicit active movements at left hip. Personal and family history was negative for tuberculosis and wound infection at the index hip surgery. There was no relevant drug, family and genetic and psychosocial history.

Lab workup was done which showed raised serum infective markers. White cell count was $11.9 \times 10^9/L$, erythrocyte sedimentation rate was 118 mm/h (0–20) and CRP was 13.45 mg/dl (0–0.5). Urine culture was negative. Chest radiograph was normal. Hip radiographs demonstrated uncemented unipolar left hip arthroplasty with no evidence of any radiolucency or prosthetic loosening (Fig. 1). Moderate degenerative changes were found on radiograph of lumbosacral spine more marked at L4–L5 and L5–S1 level. Ultrasound of hip joint was performed before proceeding with surgery. Two ml pus was aspirated and culture showed growth of *E. coli*. Due to left groin pain, markedly elevated ESR and CRP and positive culture from hip aspiration, patient was planned for left hip arthro-tomy. The surgery was performed by a consultant orthopaedic surgeon. The previous Moore approach was used for left hip arthro-tomy. Hip joint appeared normal and implant was noted to be well fixed. Clear fluid was noted in hip joint at the level of psoas muscle. Pus was debrided at the lesser trochanter. Tissue sample was sent for culture and sensitivity which showed *E coli* and histopathology reported with psoas abscess. Computed tomography scan of abdomen was performed showing bilateral perinephric fat standing with dilated ureters suggestive of Pyelonephritis (Fig. 2).

Patient was seen by infectious disease service. Patient tolerated the procedure well and there were no postoperative complica-

tions. Post operatively she was started on antibiotics which were continued for three months. She was mobilized weight bearing as tolerated with support postoperatively. The range of motion was restored with normal gait, initially ambulating with support followed by progressive improvement in her range of motion to 70° flexion, 30° abduction, 10° internal rotation and 15° external rotation within two weeks.

ESR and CRP returned to normal limits. Twenty months later, she remains asymptomatic without evidence of infection.

3. Discussion

Psoas abscess is a rare presentation with non-specific clinical signs and symptoms that make the diagnosis a challenging task. The rate of mortality between primary and secondary abscess is 2.4% and 19% respectively [8] with studies showing mortality in untreated patients approaching up to 100% [1]. Though it originates in the paraspinal area, due to anatomic attachments often times the abscess spreads to the hip/thigh region with devastating effects if not recognized early in the course of the disease. Diagnosing the pathology consists of the use of a combination of modalities.

Ultrasonography is less expensive, easily available but operator dependent and less accurate than CT scan. A CT scan with soft tissue window is helpful to determine location and dimensions of abscess. This method can be diagnostic in 95% to 100% of cases [1]. Moreover it can also be used for collection of sample for culture and sensitivity, drainage of pus and placement of catheter (drain). Past

studies have indicated the potential of the use of a point-of-care ultrasound for identification of abscesses, followed by confirmation using CT scan if required [9]. Magnetic resonance imaging (MRI) has been projected better than CT scan because of better discrimination for soft tissue and ability of visualization of abscess wall and surrounding structures. It has added advantage of differentiating a hematoma, a neoplasm and a psoas abscess. The disadvantages include a higher cost and the lack of availability in small volume and rural hospitals. In addition, it is also contraindicated in the presence of metallic implants such as the case of prosthetic joints.

It is imperative to also discuss how a psoas abscess secondary to pyelonephritis can extend to the hip joint. The hip joint consists of a capsule with interspersed bursa. There is a weak area present between the iliofemoral and pubofemoral ligaments of the capsule, which allows close contact between the synovial membrane of the hip joint and the iliopsoas bursa. In cases of inflammation secondary to acute infection, the bursa becomes enlarged and increases intraarticular pressure which may allow communication and spread of infection to the hip joint. With its large size, the iliopsoas bursa may serve as a potential source of bacterial spread into the hip.

Our patient had significant left hip pain, elevated ESR and CRP with positive ultrasound guided aspirated left hip fluid culture. We did arthrotomy which revealed no pus in joint. However necrotic tissue was debrided from psoas tendon insertion at lesser trochanter which grew *E. coli*. Due to perioperative findings, a CT scan of abdomen to evaluate retroperitoneal pathology which revealed pyelonephritis. This explained the possibility of a hematogenous etiology of psoas abscess. As no large collection was noted on CT scan, infectious disease service managed the patient on intravenous antibiotics for three months.

In our case, the primary psoas abscess presented as groin pain in patient with a previously well-functioning left hip un cemented unipolar hemiarthroplasty. The infection originated in the psoas muscle secondary to pyelonephritis as diagnosed by CT. The infection then spread down the iliopsoas muscle and bursa into the hip capsule. Postoperatively patient was diagnosed to have a psoas abscess. We strongly recommend that patients with a previously well-fixed and functioning prosthesis should be thoroughly investigated for both intra and peri-articular causes of hip pain. Radiological evaluation of the retroperitoneum in such cases preoperatively should be considered as an adjunct.

4. Conclusion

Though rare in incidence, the diagnosis and management of psoas abscess still remains vague. The management of choice for psoas abscess is initially an accurate diagnosis followed by formal drainage (in case of collection) and antibiotic according to culture and sensitivity. In our patient though clear fluid was found in the hip joint at the level of the psoas muscle, necrotic tissue containing *E. Coli* was debrided at the insertion site on the lesser trochanter. We recommend exploration of the iliopsoas muscle up to the sites of the attachment when performing an arthrotomy for an infected hip joint to rule out possible causes of intrapelvic spread of infection.

This case highlights the importance of a thorough clinical examination, lab workup and radiological assessment to rule out rare causes of hip joint pain.

Conflicts of interest

None.

Funding

No funding was required.

Ethical approval

Since this was a case report, approval was granted from the Ethical Review Committee of Aga Khan University.

Consent

Written informed consent was obtained from the patient for publication of this case report and accompanying images. A copy of the written consent is available for review by the Editor-in-Chief of this journal on request.

Author contribution

Muhammad Atif was involved in study design, data collection and writing of the paper. Azeem Tariq Malik was involved in editing and reviewal of manuscript. Shahryar Noordin was involved in study design and reviewal of the manuscript.

Guarantor

Azeem Tariq Malik.

References

- [1] M.A. Ricci, F.B. Rose, K.K. Meyer, Pyogenic psoas abscess: worldwide variations in etiology, *World J. Surg.* 10 (5) (1986) 834–842.
- [2] D. Bartolo, S. Ebbs, M. Cooper, Psoas abscess in Bristol: a 10-year review, *Int. J. Colorectal Dis.* 2 (2) (1987) 72–76.
- [3] J.A. Van Dyke, H.C. Holley, S.D. Anderson, Review of iliopsoas anatomy and pathology, *Radiographics* 7 (1) (1987) 53–84.
- [4] F.-A. Dauchy, M. Dupon, H. Dutronc, B.D. Barbeyrac, S. Lawson-Ayayi, V. Dubuisson, et al., Association between psoas abscess and prosthetic hip infection: a case-control study, *Acta Orthop.* 80 (2) (2009) 198–200.
- [5] J.R. Lentino, Prosthetic joint infections: bane of orthopedists, challenge for infectious disease specialists, *Clin. Infect. Dis.* 36 (9) (2003) 1157–1161.
- [6] T.N. Joseph, A.L. Chen, P.E. Di Cesare, Use of antibiotic-impregnated cement in total joint arthroplasty, *J. Am. Acad. Orthop. Surg.* 11 (1) (2003) 38–47.
- [7] R.A. Agha, A.J. Fowler, A. Saeta, I. Barai, S. Rajmohan, D.P. Orgill, et al., The SCARE statement: consensus-based surgical case report guidelines, *Int. J. Surg.* 34 (2016) 180–186.
- [8] N.H. Qureshi, D.P. O'Brien, D.A. Allcutt, Case report psoas abscess secondary to discitis: a case report of conservative management, *J. Spinal Disord. Tech.* 13 (1) (2000) 73–76.
- [9] J.K. Deanehan, Point-of-care ultrasound identification of a psoas abscess in a child presenting with hip pain, *Pediatr. Emerg. Care* 33 (6) (2017) 437–439.

Open Access

This article is published Open Access at [sciencedirect.com](https://www.sciencedirect.com). It is distributed under the [IJSCR Supplemental terms and conditions](#), which permits unrestricted non commercial use, distribution, and reproduction in any medium, provided the original authors and source are credited.