


## Case Report

# Prehospital extracorporeal cardiopulmonary resuscitation for cardiac arrest patients in rural areas: a case report of two patients

Kensuke Fujita,<sup>1,2</sup>  Akihide Konn,<sup>1</sup> Takayuki Ogura,<sup>2</sup> Yuri Kon,<sup>3</sup> Eiji Kondo,<sup>1</sup> Shingo Konno,<sup>1</sup> and Tatsuya Nodagashira<sup>1</sup>

<sup>1</sup>Department of Emergency and Critical Care Medicine, Hachinohe City Hospital, Hachinohe, <sup>2</sup>Department of Emergency Medicine and Critical Care Medicine, Tochigi Prefectural Emergency and Critical Care Center, Imperial Foundation Saiseikai Utsunomiya Hospital, Utsunomiya, and <sup>3</sup>Department of Emergency and Critical Care Medicine, Division of Emergency and Trauma Radiology, St. Marianna University School of Medicine, Kawasaki, Japan

**Background:** The prognosis of out-of-hospital cardiac arrest remains poor, especially for cardiopulmonary arrest patients in rural areas with longer transport duration to hospitals.

**Case Presentation:** In June 2016, we began providing prehospital extracorporeal life support using a mobile operating room for emergency surgery. We report two patients who survived after receiving prehospital extracorporeal cardiopulmonary resuscitation and were discharged. A patient with cardiopulmonary arrest from accidental hypothermia due to drowning survived with good neurological outcomes after on-site extracorporeal cardiopulmonary resuscitation immediately after rescue. The other patient who survived experienced cardiopulmonary arrest at his workplace, which was approximately 90 min from the center. Prehospital extracorporeal cardiopulmonary resuscitation shortened the cardiopulmonary arrest time by an estimated 30 min, and the patient survived until the hospital.

**Conclusion:** Prehospital extracorporeal cardiopulmonary resuscitation has the potential to save lives in rural areas by reducing low-flow time.

**Key words:** Emergency mobile unit, mobile operating room for emergency surgery, OHCA, prehospital ECPR

## INTRODUCTION

EXTRACORPOREAL CARDIOPULMONARY RESUSCITATION (ECPR) is a time-dependent therapy. A short low-flow time contributes to favorable neurological outcomes (cerebral performance categories 1 and 2).<sup>1</sup> Furthermore, in out-of-hospital cardiac arrest (OHCA) patients who undergo CPR for  $\geq 21$  min, ECPR contributes to better outcomes than conventional cardiopulmonary

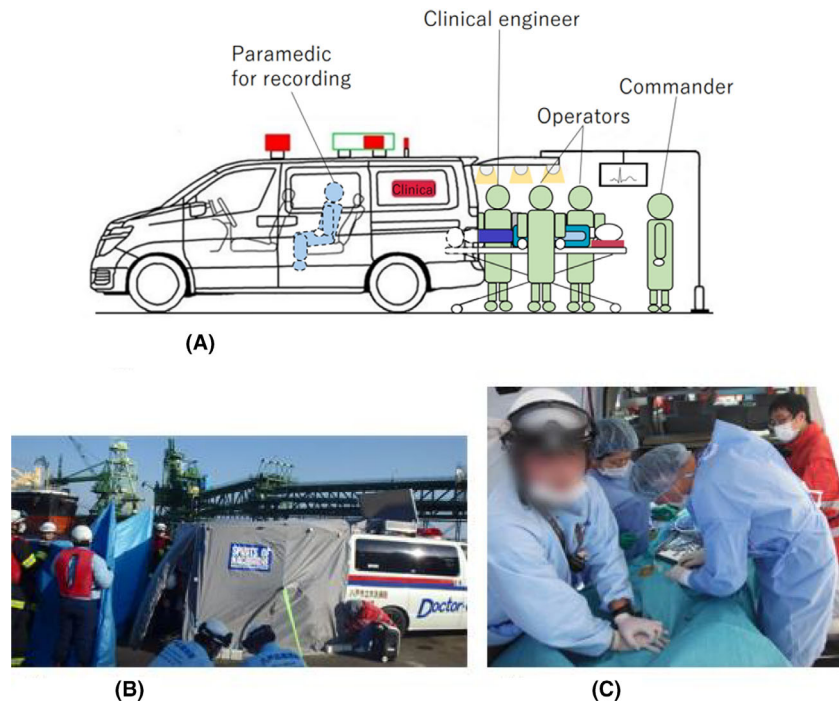
resuscitation.<sup>2</sup> Additionally, extracorporeal life support (ECLS) should be introduced within 60 min of cardiopulmonary arrest (CPA) to achieve favorable neurological outcomes and acceptable survival rates.<sup>3</sup> In urban centers, traffic jams are major factors leading to delays in initiating extracorporeal membrane oxygenation (ECMO). In 2012, Lamhaut *et al.* reported for the first time that carrying out prehospital ECPR could save OHCA patients<sup>4</sup> and later reported that carrying out prehospital ECLS based on indications and strict protocols dramatically improved survival rates.<sup>5</sup> Although Lamhaut *et al.* reported the efficacy of prehospital ECPR in urban centers, there have been few reports on the usefulness of prehospital ECPR in rural areas. In June 2016, we began providing prehospital ECPR using a mobile operating room for emergency surgery (MOREs; Fig. 1A). Here, we report the cases of two OHCA patients in a rural area who survived after receiving prehospital ECPR in a MOREs (Fig. 2).

**Corresponding:** Kensuke Fujita, MD, Department of Emergency and Critical Care Medicine, Tochigi Prefectural Emergency and Critical Care Center, Imperial Foundation Saiseikai Utsunomiya Hospital, 911-1 Takebayashi-cho, Utsunomiya, Tochigi, Japan. E-mail: fujitak.727@gmail.com.

Received 25 May, 2020; accepted 3 Sep, 2020

### Funding information

No funding information provided.



**Fig. 1.** A, Image of a mobile operating room for emergency surgery (MOREs). A MOREs opens in the back to create a tent where extracorporeal membrane oxygenation (ECMO) is carried out. Two operators, one resuscitation commander, one clinical engineer, and one physician (playing the role of an assistant) undertake the main procedures inside this tent. B, Successful set-up of an operating room before patient arrival. A tent is set up before the patient's rescue. The patient was carried into the tent immediately after rescue, and ECMO was initiated. Even in public places where there are many people, MOREs can facilitate prehospital extracorporeal cardiopulmonary resuscitation while allowing privacy and security. C, ECMO for Case 1 in MOREs. Mechanical cardiopulmonary resuscitation was not possible because the patient was petite. Therefore, manual cardiopulmonary resuscitation was carried out.

## CASE REPORT

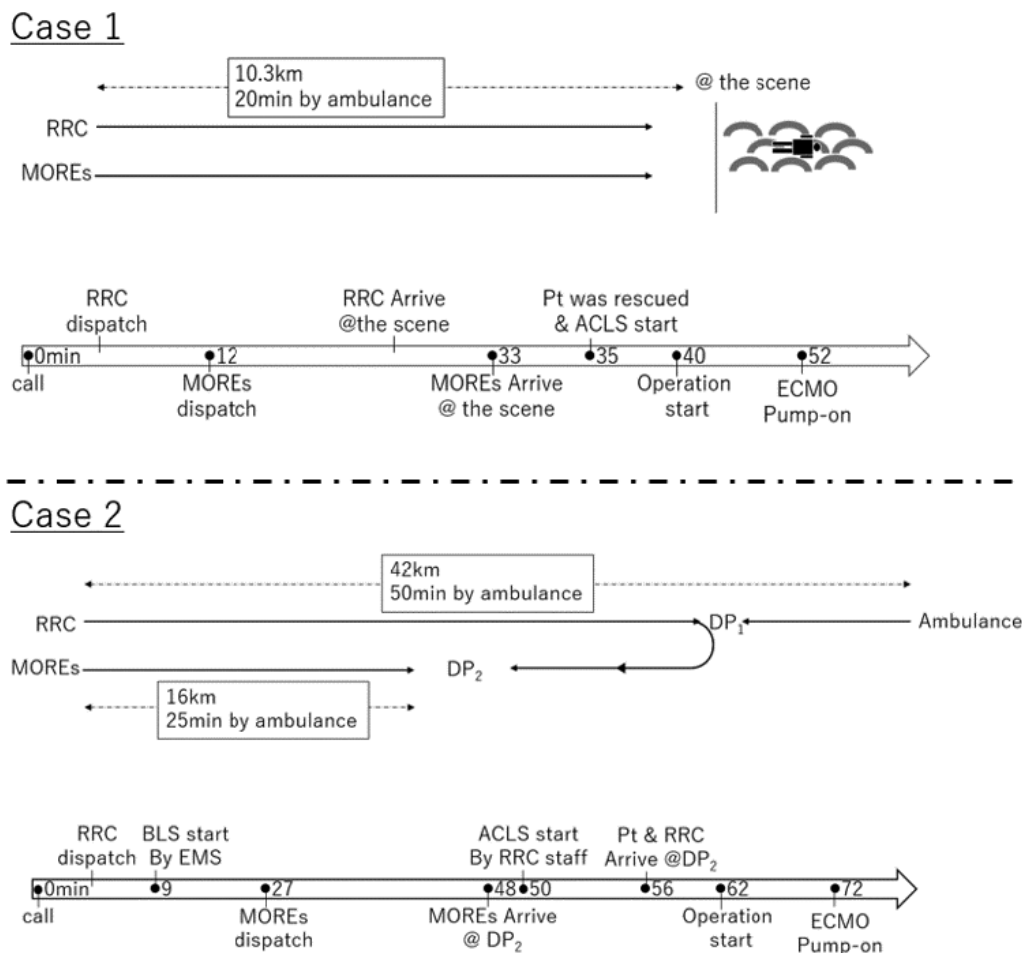
### Case 1

A 45-YEAR-OLD WOMAN with no significant medical history fell into a river and was found floating by a passer-by who reported the emergency. The scene was 10.3 km from our hospital, and transportation would require approximately 20 min by car. The water temperature that day was 2°C. The patient was confirmed to be alive but unconscious when she was found. The risk of experiencing CPA during the time it took to rescue her was considered, and the MOREs was dispatched to facilitate rapid ECMO initiation if it was medically necessary. The MOREs reached a pier near the scene, and in 5 min, it was successfully set up before the patient's arrival (Fig. 1B). When she was pulled out on a rescue boat 35 min after the call, she showed pulseless electrical activity and was considered to be in CPA owing to accidental hypothermia. The emergency physician who arrived first with the rapid response car (RRC) initiated advanced cardiac life support

(ACLS), and the patient was brought to the MOREs for venoarterial ECMO initiation (Fig. 1C). Approximately 5 min after she was rescued, ECMO was initiated using the cut-down technique. The ECMO pump was started 12 min after beginning the operation with a 17-min low-flow time. The first core temperature measured at the site was 26°C. Return of spontaneous circulation was achieved 72 min after rescue with a body temperature of 30.6°C. On the same day, her body temperature completely recovered to 36°C. The patient was admitted to the intensive care unit (ICU), where her cardiac function steadily recovered. She was taken off the ECMO on the second day in the ICU. She showed no complications and was discharged from the hospital with cerebral performance category 1.

### Case 2

A 66-year-old man with a history of chronic heart failure collapsed at work, and his colleagues contacted the emergency medical service (EMS). Our hospital's RRC was requested and dispatched to the scene at the same time.



**Fig. 2.** Time-course of two cases of prehospital extracorporeal cardiopulmonary resuscitation for cardiac arrest patients. Case 1: Rapid response car (RRC) and mobile operating room for emergency surgery (MOREs) were dispatched to the scene for the patient’s rescue from the water. Case 2: The docking point (DP) is where the RRC or MOREs meet with ambulances. The RRC first departed the hospital to resuscitate the patient, and the departed MOREs then prepared and waited for ECPR at DP<sub>2</sub>, 16 km away from the hospital. ACLS, advanced cardiovascular life support; ECMO, extracorporeal membrane oxygenation; Pt, patient.

The EMS arrived at the scene 8 min after the call and confirmed CPA with ventricular fibrillation (VF) as an initial rhythm and immediately initiated chest compressions. The first defibrillation was initiated 9 min after the call, but VF persisted. Cardiopulmonary arrest was diagnosed, and persistent VF was considered. Because this is an indication for prehospital ECPR, EMS requested for MOREs. The EMS immediately started resuscitation using mechanical CPR and transferred the patient from the scene. Eight minutes after the EMS started ACLS, RRC joined the EMS on the way to the hospital and confirmed that VF persisted. The RRC staff decided to carry out prehospital ECPR and transferred the patient to the MOREs docking point 16 km from the hospital

(26 min by car). On patient arrival at the MOREs docking point, cannulation was carried out (56 min after the call). The ECMO cannulas were percutaneously inserted, and ECMO was initiated 10 min after the operation with a 63-min low-flow time. Return of spontaneous circulation was achieved when the patient arrived at the hospital. The pupillary light reflex was absent, but he showed miosis and spontaneous breathing. An emergency percutaneous coronary intervention was carried out, and the patient was admitted to the ICU. On day 3 of the ICU, although he was in a comatose state, he was taken off the ECMO. Computed tomography showed signs of cerebral hypoxia; although the patient survived, he sustained severe neurological impairment.

## DISCUSSION

OUR HOSPITAL IS the only tertiary emergency medical facility in a large medical zone that covers the northern coastal region of Japan, extending >50 km. Transport duration by road can sometimes exceed 60 min. Therefore, transport by helicopter emergency medical services (HEMS) is priority for OHCA patients in distant areas, then ECPR is undertaken at the hospital. However, during long-distance transport using HEMS, the low-flow time commonly exceeds 21 min from initiation of resuscitation, and over 60 min passes before patient arrival at the hospital. Typical outcomes are unsatisfactory. Transporting prehospital ECPR teams and ECMO devices to remote sites and undertaking prehospital ECPR using MOREs can improve patient prognosis.

Prehospital ECPR inclusion criteria of our center are: (i) initial rhythm, VF/ventricular tachycardia, (ii) possibly in Cardiac cause, (iii) witnessed arrest, (iv) arrest with bystander CPR, (v) cannot reach the hospital within 40 min.

A good indication for MOREs is when OHCA patients are over 40 min away from the hospital by ambulance transport or when adverse weather conditions prevent HEMS transport.

We also consider accidental hypothermia to be an indication for prehospital ECPR using MOREs, as in case 1, although not included in the inclusion criteria above. In our hospital, we treat seven to eight cases of accidental hypothermia annually. For grade III or higher severity of accidental hypothermia, there is an increased risk of CPA during rescue or transport by helicopter due to the difficulty of loading and unloading patients and flight turbulence. The risks and benefits of transporting patients to institutions where ECMO or cardiopulmonary bypass can be carried out must be weighed, particularly in areas with long transport duration.<sup>6</sup>

## CONCLUSION

WE CARRIED OUT the first prehospital ECPR in Japan to save two OHCA patients. However, we have encountered only a few cases thus far, limiting our findings. More cases need to be assessed to better understand the procedure outcomes.

## ACKNOWLEDGMENTS

WE WOULD LIKE to thank Associate Professor Takukatsu Asakawa and his colleagues at The Hachinohe Institute of Technology for their cooperation in the development of MOREs and the illustrations in this paper.

## DISCLOSURE

Approval of the research protocol: N/A.

Informed consent: Informed consent was obtained from the subjects and their families.

Registry and the registration no. of the study/trial: N/A.

Animal studies: N/A.

Conflict of interest: None.

## REFERENCES

- 1 Yu HY, Wang CH, Chi NH *et al.* Effect of interplay between age and low-flow duration on neurologic outcomes of extracorporeal cardiopulmonary resuscitation. *Intensive Care Med.* 2019; 45: 44–54.
- 2 Kim SJ, Jung JS, Park JH, Park JS, Hong YS, Lee SW. An optimal transition time to extracorporeal cardiopulmonary resuscitation for predicting good neurological outcome in patients with out-of-hospital cardiac arrest: a propensity-matched study. *Crit. Care.* 2014; 18: 535.
- 3 Chen YS, Yu HY, Huang SC *et al.* Extracorporeal membrane oxygenation support can extend the duration of cardiopulmonary resuscitation. *Crit. Care Med.* 2008; 36: 2529–35.
- 4 Lamhaut L, Jouffroy R, Kalpodjian A *et al.* Successful treatment of refractory cardiac arrest by emergency physicians using pre-hospital ECLS. *Resuscitation* 2012; 83: e177–8.
- 5 Lamhaut L, Hutin A, Puymirat E *et al.* A Pre-Hospital Extracorporeal Cardio Pulmonary Resuscitation (ECPR) strategy for treatment of refractory out hospital cardiac arrest: an observational study and propensity analysis. *Resuscitation* 2017; 117: 109–17.
- 6 Brown DJ, Brugger H, Boyd J, Paal P. Accidental hypothermia. *N. Engl. J. Med.* 2012; 367: 1930–8.