

Hyperostosis in Combination With Low Skull Density Ratio: A Potential Contraindication for Magnetic Resonance Imaging–Guided Focused Ultrasound Thalamotomy

Jason Yuen, MSci, BM, BCh; Kai J. Miller, MD, PhD; Bryan T. Klassen, MD; Vance T. Lehman, MD; Kendall H. Lee, MD, PhD; and Timothy J. Kaufmann, MD, MS

Abstract

Since its approval in treating a number of movement disorders, magnetic resonance imaging–guided focused ultrasound (MRgFUS) has been adopted rapidly as one of the standard treatment modalities internationally. However, the efficiency of the energy delivered by the ultrasonic waves is largely determined by the highly variable bone morphology and density characteristics of the skull. One of the widely accepted indices used to facilitate patient selection is the skull density ratio (SDR). Earlier literature suggested that an SDR of less than 0.4 would be unfavorable for MRgFUS treatment. Some prior studies have excluded patients with hyperostosis. However, there is little published data regarding the impact of other skull features such as hyperostosis on treatment success. We present the case of a 66-year-old man with medically refractory essential tremor who had an SDR of 0.38 and extensive hyperostosis frontalis interna and underwent attempted MRgFUS thalamotomy treatment. However, intraoperatively the treatment was unsuccessful in generating sufficiently elevated temperature to create a lesion of the usual desired volume, and as expected, there was minimal clinical improvement. For comparison, we also summarize a case series of 4 other patients with an SDR of less than 0.4 who had successful outcomes. We believe that SDR should not be used as the only means of selecting patients for MRgFUS. Instead, important factors such as hyperostosis should be taken into consideration for patient selection and pre-treatment counseling.

© 2021 Mayo Foundation for Medical Education and Research. Published by Elsevier Inc. This is an open access article under the CC BY-NC-ND license (<http://creativecommons.org/licenses/by-nc-nd/4.0/>) ■ Mayo Clin Proc Inn Qual Out 2022;6(1):10-15



From the Department of Neurologic Surgery (J.Y., K.J.M., K.H.L.), Department of Neurology (B.T.K.), and Department of Radiology (V.T.L., T.J.K.), Mayo Clinic, Rochester, MN.

BACKGROUND AND IMPORTANCE

Since its approval by the US Food and Drug Administration and other similar government organizations, magnetic resonance (MR) imaging–guided focused ultrasound (MRgFUS) thalamotomy has been widely adopted as an alternative treatment option for movement disorders (particularly medically refractory essential tremor [ET]), in addition to the established deep brain stimulation (DBS) and ablation techniques.¹⁻³ In general, DBS is contraindicated in patients with poor general status and those who are receiving antiplatelet and/or anticoagulation treatment (in which temporary withdrawal cannot be tolerated).⁴ In contrast, the

minimally invasive nature of MRgFUS not only allows patients who are not medically fit for surgical intervention a highly effective therapy but also provides an additional option for all patients, particularly those opposed to indwelling hardware.

In brief, using preoperative imaging with or without diffusion tensor imaging (DTI) tractography, a target such as the ventral intermediate nucleus of the thalamus (VIM) is first identified. Then, the therapeutic sonication generates a lesion stereotactically using up to 1024 individual transducers, the temperature of which can be monitored via MR thermometry (or thermography). The optimal temperature for thermal ablation is 55 °C to 60 °C,

although the time of tissue exposed to a given temperature also influences the permanent lesion size.⁵ However, in order to deliver sufficient energy to generate the lesion, a favorable skull morphology and density characteristics are highly critical. One commonly used measure is the skull density ratio (SDR) metric, which largely reflects the density differences of the calvarium and their likelihood of attenuating ultrasound energy passing through the skull. Using preoperative computed tomography (CT), the SDR, which is defined as the ratio between the mean values in Hounsfield units for marrow and cortical bone, is calculated with specialized software and averaged over the calvarium.⁶ In an earlier study, both the skull volume and SDR were found to be correlated with the maximum temperature achieved.⁶ Lower SDR values indicate increasing differences between the Hounsfield units (and hence density) of the cortical bone and marrow, and the authors postulated that this difference led to more attenuation and reflection of the ultrasonic energy and hence lower energy transmission. Based on this study and others, the US Food and Drug Administration and many physicians generally consider an SDR of less than 0.4 to be unfavorable for MRgFUS treatments.^{1,5,7} However, this factor is not the only characteristic of the skull that may be considered. Calvarial shape, for instance, potentially contributes to the likelihood of MRgFUS treatment success, and there are likely other factors that have not been well described to date.

One such factor that seems to be important in relevant cases is hyperostosis frontalis interna. We present the case of a patient with an SDR of 0.38 (ie, considered “unfavorable”) as well as extensive and marked hyperostosis frontalis interna who underwent MRgFUS treatment that was unfortunately unsuccessful in creating a sufficient lesion to alleviate the patient’s ET. The study proposal was reviewed by the Mayo Clinic Institutional Review Board and was determined to be exempt from the requirement for approval. Patients consented to their clinical details being used in research.

REPORT OF CASE

A 66-year-old man presented with medically refractory ET, predominantly in his right

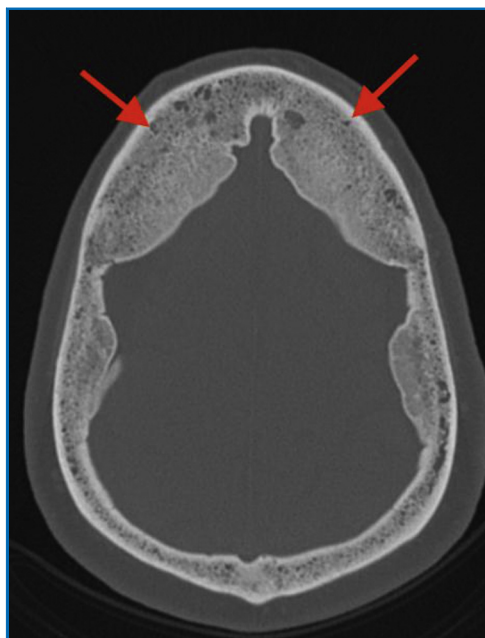


FIGURE 1. Axial computed tomographic bone window image depicting advanced calvarial hyperostosis, worst at the frontal regions (arrows) but also involving the parietal calvaria.

(dominant) upper limb. Examination also revealed a subtle vocal tremor on sustained phonation. The Fahn-Tolosa-Marín tremor rating scale score was 5, and the patient-rated Bain tremor rating scale score was 71. A movement disorders neurophysiologic study confirmed a 5- to 6-Hz postural kinetic tremor consistent with an organic etiology. Neuropsychometric testing revealed mild deterioration in cognition. The patient had a history of rheumatoid arthritis and also venous thromboembolism that was being treated with apixaban until it was withheld prior to MRgFUS treatment. Radiologic investigation revealed no brain abnormalities of concern, but CT identified extensive hyperostosis interna, predominantly of the frontal but also the parietal cranium (Figure 1), and a total calvarial calculated SDR of 0.38.

After being discussed at the routine multidisciplinary meeting used at our institution to assess and approve patients for such procedures, the patient was offered both DBS and MRgFUS thalamotomy, but he opted for the latter. It was discussed with the patient prior to the procedure that his skull was unfavorable

for MRgFUS and that this factor could make the treatment difficult. For the procedure, the left VIM was targeted using indirect, atlas-based measurements, as well as DTI tractography of the dentatorubrothalamic tract, at a point anterior from the posterior commissure by 25% of the anterior commissure-posterior commissure distance and 11 mm lateral from the wall of the third ventricle and 1.5 mm superior to the anterior commissure-posterior commissure plane. The left corticospinal tract and the sensory tracts of the left medial lemniscus and spinothalamic tract were also located with DTI tractography in order to avert thermal injury to these tracts. A stereotactic head frame was placed. A head-focused ultrasound device (Exablate Neuro, software version 7.33; Insightec) was used in conjunction with a 750w 3-T MR imaging scanner (General Electric Company). The skull surface area was 380 cm², and 969 ultrasound elements (of 1024) were usable. Following the usual lower-energy alignment sonications, multiple high-energy sonications were delivered in order to increase temperature at the VIM target. Approximately 195 kJ of energy were delivered in total over 7 sonications, using up to 60.7 kJ in 1 pulse (for treatment parameter details, see [Supplemental Table](#), available online at <http://www.mayoclinicproceedings.org>).

The patient was interviewed and examined by a neurologist at multiple points throughout the procedure, including after each high-energy (>20 kJ) sonication. He remained motivated to continue treatment, and he agreed to moderate sedation for the last planned sonication because such high energies were being used. Despite using the maximal energy possible of the Exablate system (60,000 J), the average temperature at the VIM target could not be raised higher than 50 °C, and there was only minimal improvement in tremor. Follow-up imaging reviewed a small (approximately 2-mm diameter) lesion with restricted diffusion on diffusion-weighted imaging (DWI) and diffuse subgaleal edema ([Figure 2](#)). For comparison, [Figure 3](#) shows the DWI of another patient, demonstrating a larger, more typically sized cytotoxic lesion in the acute phase following MRgFUS thalamotomy. Bright signal on DWI with corresponding low apparent diffusion coefficient

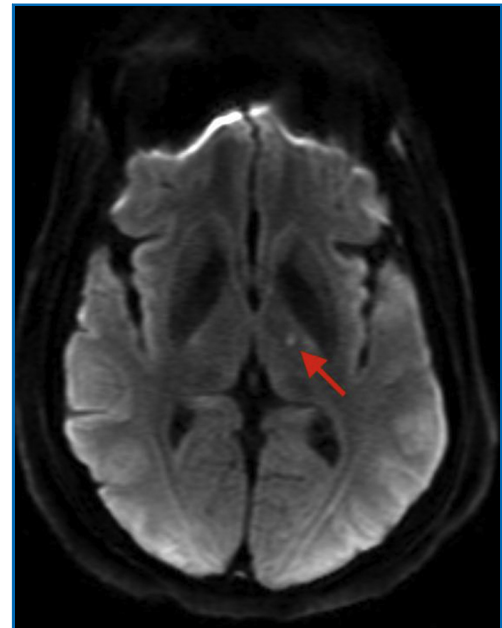


FIGURE 2. Postoperative diffusion-weighted image showing the smaller than optimal cytotoxic lesion generated by the focused ultrasound treatment (arrow).

represents restricted water diffusion, is seen with cytotoxic edema, and represents the zone of cell death in the acute phase following thermal ablation.⁸ The subgaleal edema

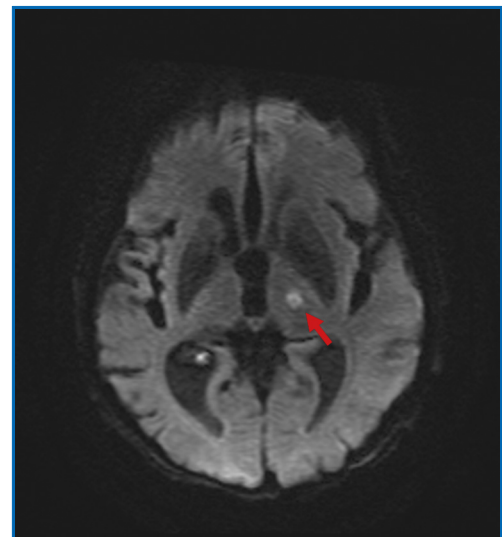


FIGURE 3. Diffusion-weighted image from another patient showing a larger, more typically sized cytotoxic lesion (arrow) in the acute phase following MRgFUS thalamotomy.

suggested a temporary inflammatory response to substantial scalp heating, which is not usually seen following routine MRgFUS thalamotomy. There were no other intraoperative complications. At 1-month follow-up, the patient continued to have some persisting headache and tremor similar to the pretreatment level but declined DBS because of the high surgical risks secondary to his comorbidities (anticoagulation for previous venous thromboembolism, rheumatoid arthritis).

DISCUSSION

We present a case in which the MRgFUS procedure could not produce the temperature required for ablation, which was reflected in the lack of symptom improvement. The patient had a slightly lower SDR compared with the 0.4 threshold cited in the literature. Although this difference certainly may be a contributing factor, the marked hyperostosis frontalis interna, as seen in Figure 1, may have dominated the reasons for failure. The Table summarizes the results of MRgFUS thalamotomy in 4 other patients (of a total of 63) with SDRs lower than 0.4 who were treated at our institution between September 2017 and July 2021. Despite their borderline SDRs, they did not have notable hyperostosis and all attained satisfactory lesioning temperatures intraoperatively, which correlated with expected permanent lesions in the ventral thalamus and with their immediate clinical improvement.

In a case series of 98 patients reported by Boutet et al,⁷ 17 had an SDR of less than 0.4; although this factor did not influence the clinical outcome, the maximum energy required to obtain a therapeutic brain lesion was inversely correlated with the SDRs. The investigators in this study also decided to not offer MRgFUS to 4 patients because of hyperostosis. They did perform MRgFUS in one patient with hyperostosis frontalis interna and borderline SDR (0.4), which failed to produce a lesion, similar to our findings. In addition, another study that focused on psychiatric diseases actually excluded patients with hyperostosis.⁹

Hyperostosis frontalis interna is a morphological pattern characterized by benign sessile or nodular thickening of the inner table of predominantly the frontal calvarium with poorly understood but potentially multiple etiologic

TABLE. Results of Magnetic Resonance Imaging–Guided Focused Ultrasound Thalamotomy in 4 Patients With Borderline Skull Density Ratio but No Hyperostosis^{a,b}

Case, age (y)	Medical history	Notable preoperative radiologic findings	SDR	Intraoperative findings	Total energy delivered, max energy delivered, max temp (No. of sonications)	Outcome
1, 62	T2DM, IHD with CABG (on aspirin)	None	0.36	Transient headache and dizziness during procedure; nearly complete clinical improvement	128.3 kJ, 26.4 kJ, 61 °C (14)	Patient's tremor remained well controlled at 6 mo
2, 83	Cervical spondylosis, left shoulder injury, mild balance issues	Brain atrophy	0.38	Uncomplicated, nearly complete clinical improvement	53.6 kJ, 15.2 kJ, 57 °C (6)	Patient died 2 mo after treatment, considered unrelated
3, 74	None	None	0.39	Nearly complete clinical improvement	134.7 kJ, 27.5 kJ, 55 °C (9)	Out of area; not followed up
4, 88	PE (anticoagulated), colon cancer	None	0.37	Nearly complete clinical improvement	36.9 kJ, 13.6 kJ, 57 °C (5)	Patient's tremor remained well controlled at 5 mo

^aCABG, coronary artery bypass graft; IHD, ischemic heart disease; max, maximum; PE, pulmonary embolism; SDR, skull density ratio; T2DM, type 2 diabetes mellitus; temp, temperature.

^bAll patients were men with medically refractory essential tremor treated at our institution between 2017 and 2021. Despite subthreshold SDR values (<0.4), they all had good clinical outcomes.

contributors.¹⁰ It presents on a spectrum of thickness of severity from minimal to quite advanced but is usually considered to be of no clinical importance. It is typically bilateral and relatively symmetric. Hyperostosis frontalis interna can also involve the parietal calvarium in more extensive cases. According to one postmortem study, it occurs in approximately 12.5% of the population, most commonly in postmenopausal females.¹⁰ If cerebral compression and atrophy occur, it could potentially present with cognitive impairment or neuropsychiatric symptoms.¹¹ Hyperostosis frontalis interna has been classified by Hershkovitz et al^{12,13} into 4 grades of severity and has also been classified with CT, but it remains uncertain how it would best be classified with regard to its impact on the likelihood of MRgFUS success.

Hyperostosis frontalis interna is anecdotally associated with low SDR, as SDR is currently calculated. However, our experience and that of others suggest that it also contributes independently to the likelihood of failure of MRgFUS. Particularly as some have also suggested that with application of focused ultrasound, hyperostosis can lead to an undesirable spread of the thermal lesion being created at MRgFUS, one could consider avoiding the thickened inner table during treatment through segmenting out all of it as a “no-pass zone” for ultrasound energy.⁵ However, this approach could also lead to insufficient energy reaching the target from the fewer remaining ultrasound elements for lesion generation. In addition, the presence of hyperostosis may also exacerbate the presence of “sidelobes,”¹⁴ causing further unequal deposition of power from the different transducer elements in the array at the focus.

Therefore, although SDR is readily calculated and is widely used as a key measure in patient selection, it does not alone fully predict the likelihood of a successful thermal ablation, as seen in our case. Hence, it is important to consider other factors, such as hyperostosis frontalis, in patient selection. Also, clinicians should counsel patients that the likelihood of success with MRgFUS may be reduced in such situations. Although there are ongoing

investigations into other, more complicated, aspects of skull density and morphology than the SDR that may be helpful in the future, at least a qualitative assessment of the severity of hyperostosis frontalis interna should factor prominently in predicting the likelihood of MRgFUS success.

CONCLUSION

Our case report documents that although an SDR lower than 0.4 may not be considered an absolute contraindication to MRgFUS thalamotomy, the presence of substantial hyperostosis frontalis interna in the setting of a low SDR may lead to suboptimal or failed treatment. Skull characteristics other than SDR, as yet incompletely delineated, will almost certainly be useful to aid patient selection for this procedure.

ACKNOWLEDGMENTS

Author contributions: All authors were involved in the conceptualization of the study. Dr Yuen collected the data and wrote the first draft of the submitted manuscript. Drs Miller, Klassen, Lehman, Lee, and Kaufmann critically reviewed and revised the manuscript. Drs Lee and Kaufmann supervised all aspects of this work. All authors accepted the final version of the submitted manuscript.

SUPPLEMENTAL ONLINE MATERIAL

Supplemental material can be found online at <http://www.mayoclinicproceedings.org>. Supplemental material attached to journal articles has not been edited, and the authors take responsibility for the accuracy of all data.

Abbreviations and Acronyms: **CT**, computed tomography; **DBS**, deep brain stimulation; **DTI**, diffusion tensor imaging; **DWI**, diffusion-weighted imaging; **ET**, essential tremor; **MR**, magnetic resonance; **MRgFUS**, MR imaging–guided focused ultrasound; **SDR**, skull density ratio; **VIM**, ventral intermediate nucleus of the thalamus

Potential Competing Interests: The authors report no competing interests.

Correspondence: Address to Timothy J. Kaufmann, MD, MS, Department of Radiology, Mayo Clinic, 200 First St SW, Rochester, MN 55905 (kaufmann.timothy@mayo.edu).

ORCID

Jason Yuen:  <https://orcid.org/0000-0002-6988-388X>;
 Timothy J. Kaufmann:  <https://orcid.org/0000-0001-7483-1569>

REFERENCES

1. US Food and Drug Administration. *Summary of safety and effectiveness data (SSED); magnetic resonance guided focused ultrasound surgery system (MRgFUS)*. MD: Silver Spring; 2016. Available at: https://www.accessdata.fda.gov/cdrh_docs/pdf15/P150038B.pdf. Accessed December 17, 2021.
2. Dallapiazza RF, Lee DJ, De Vloo P, et al. Outcomes from stereotactic surgery for essential tremor. *J Neurol Neurosurg Psychiatry*. 2019;90(4):474-482.
3. Elias WJ, Lipsman N, Ondo WG, et al. A randomized trial of focused ultrasound thalamotomy for essential tremor. *N Engl J Med*. 2016;375(8):730-739.
4. Lang AE, Houeto J-L, Krack P, et al. Deep brain stimulation: pre-operative issues. *Mov Disord*. 2006;21(suppl 14):S171-S196.
5. Wang TR, Bond AE, Dallapiazza RF, et al. Transcranial magnetic resonance imaging-guided focused ultrasound thalamotomy for tremor: technical note. *Neurosurg Focus*. 2018;44(2):E3.
6. Chang WS, Jung HH, Zadicario E, et al. Factors associated with successful magnetic resonance-guided focused ultrasound treatment: efficiency of acoustic energy delivery through the skull. *J Neurosurg*. 2016;124(2):411-416.
7. Boutet A, Gwun D, Gramer R, et al. The relevance of skull density ratio in selecting candidates for transcranial MR-guided focused ultrasound. *J Neurosurg*. 2019;132(6):1785-1791.
8. Wintermark M, Druzgal J, Huss DS, et al. Imaging findings in MR imaging-guided focused ultrasound treatment for patients with essential tremor. *AJNR Am J Neuroradiol*. 2014;35(5):891-896.
9. Davidson B, Hamani C, Huang Y, et al. Magnetic resonance-guided focused ultrasound capsulotomy for treatment-resistant psychiatric disorders. *Oper Neurosurg (Hagerstown)*. 2020;19(6):741-749.
10. Raikos A, Paraskevas GK, Yusuf F, et al. Etiopathogenesis of hyperostosis frontalis interna: a mystery still. *Ann Anat*. 2011;193(5):453-458.
11. Smith S, Hemphill RE. Hyperostosis frontalis interna. *J Neurol Neurosurg Psychiatry*. 1956;19(1):42-45.
12. Hershkovitz I, Greenwald C, Rothschild BM, et al. Hyperostosis frontalis interna: an anthropological perspective. *Am J Phys Anthropol*. 1999;109(3):303-325.
13. May H, Peled N, Dar G, et al. Identifying and classifying hyperostosis frontalis interna via computerized tomography. *Anat Rec (Hoboken)*. 2010;293(12):2007-2011.
14. Hughes A, Huang Y, Pulkkinen A, Schwartz ML, Lozano AM, Hynynen K. A numerical study on the oblique focus in MR-guided transcranial focused ultrasound. *Phys Med Biol*. 2016;61(22):8025-8043.