

## Open Access

# A Case of Guide Wire Fracture With Remnant Filaments in the Left Anterior Descending Coronary Artery and Aorta

Young-Min Hong, MD and Sang-Rok Lee, MD

Department of Internal Medicine, Chonbuk National University Medical School, Jeonju, Korea

**ABSTRACT**

Guide wire fractures during percutaneous coronary intervention (PCI) are very rare, but when they do occur they may lead to life-threatening complications, such as embolization, thrombus formation and perforation. In cases when percutaneous retrieval has failed, surgical extraction of the remnant fragments is recommended. We present a case of remnant guide wire filaments that remained in place without complications, over a one-year clinical follow up period. (**Korean Circ J 2010; 40:475-477**)

**KEY WORDS:** Percutaneous transluminal coronary angioplasty; Coronary artery disease.

## Introduction

The increasing incidence of complex percutaneous coronary intervention (PCI) is accompanied by risks of device fracture or dislodgement. Guide wire fractures during PCI are very rare, but in such cases, life-threatening complications such as embolization, thrombus formation and perforation may occur. Although, in most cases, percutaneous retrieval techniques of fractured guide wires are recommended, there have been several reports of fragments being left in place without complications.<sup>1-4)</sup>

We present the case of a 78-year-old female patient who was diagnosed with non-ST segment elevation myocardial infarction (NSTEMI) and treated with PCI. The patient had remnant guide wire filaments in the left anterior descending artery (LAD) and aorta but did not experience any serious complications during a one-year follow up period.

## Case

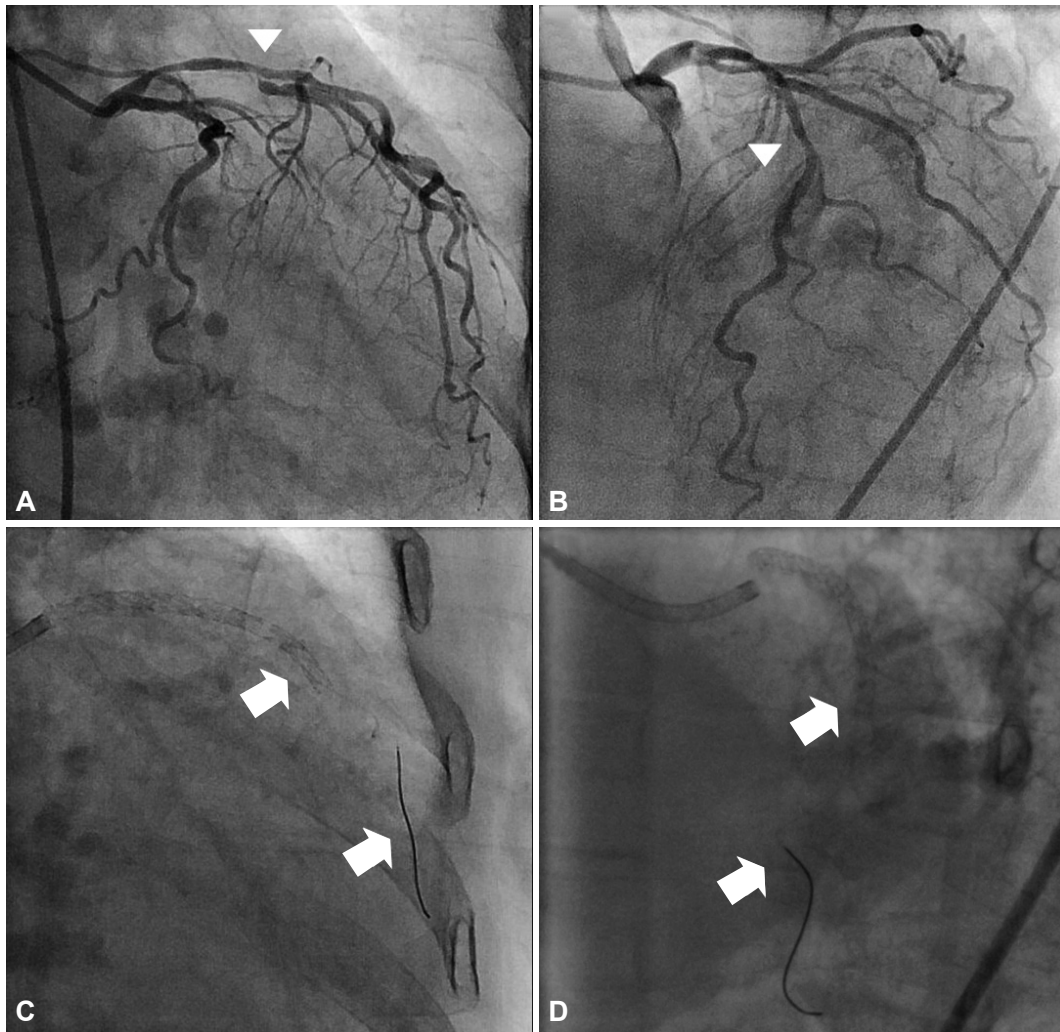
A 78-year-old woman presented with NSTEMI. Echocardiography showed decreased left ventricular systolic function (ejection fraction 45%). A diagnostic coronary angiogram showed diffuse significant stenosis from the proximal to middle LAD and first diagonal branch (D1) (Fig. 1). There was total thrombotic obstruction at the middle right coronary artery. We initially treated the patient with a single paclitaxel-eluting stent (2.75×32 mm Taxus<sup>®</sup>, Boston Scientific, Natick, MA, USA). Four days later, two coronary angioplasty 0.014 guide wires were inserted {one hi-torque Balance Middleweight (BMW) universal coronary guide wire (Abott Vascular, Santa Clara, CA, USA) into the LAD, and one high-torque Whisper coronary guide wire (Abott Vascular) into the D1}. An intravascular ultrasound after predilatation with a 2.5×20 mm Voyager<sup>®</sup> balloon (Abott Vascular) revealed a large plaque burden at both the LAD and the D1. We deployed two overlapped sirolimus-eluting stents at the proximal and middle LAD: a 2.75×33 mm Cypher<sup>®</sup> at the middle LAD and a 2.75×18 mm Cypher<sup>®</sup> at the proximal LAD (Cordis Corporation, Miami Lakes, FL, USA). When we exchanged the guide wires to perform kissing balloon angioplasty, a fracture occurred at the distal tip of the BMW guide wire (Fig. 1). Another guide wire was inserted to perform a beaded wire rotation, and distal balloon inflation retrieval was attempted, in order to remove the fractured guide wires. This attempt, however, was ineffective. Finally, we used a goose neck loop-snare (Microvena Corporation, St. Paul, MN, USA) to remove the fractured guide wires. Multiple forward and backward

Received: January 27, 2010

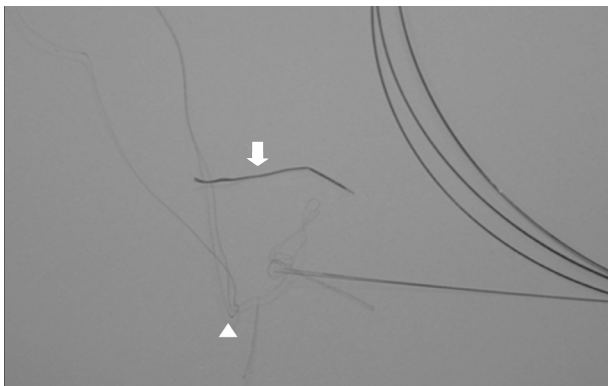
Accepted: February 19, 2010

Correspondence: Sang-Rok Lee, MD, Division of Cardiology, Department of Internal Medicine, Chonbuk National University Medical School, 42 Wonjam 5-gil, Deokjin-gu, Jeonju 561-712, Korea  
Tel: 82-63-250-2418, Fax: 82-63-250-1680  
E-mail: medorche@jbnu.ac.kr

© This is an Open Access article distributed under the terms of the Creative Commons Attribution Non-Commercial License (<http://creativecommons.org/licenses/by-nc/3.0>) which permits unrestricted non-commercial use, distribution, and reproduction in any medium, provided the original work is properly cited.



**Fig. 1.** A diagnostic coronary angiogram showed diffuse and significant stenosis from the proximal to middle LAD (arrow head) and first diagonal branch (arrow head) (A and B). After deployment of two sirolimus-eluting stents over the LAD, a fracture occurred at the distal tip of the BMW guide wire (arrow) (C and D). LAD: left anterior descending coronary artery, BMW: Balance Middleweight.



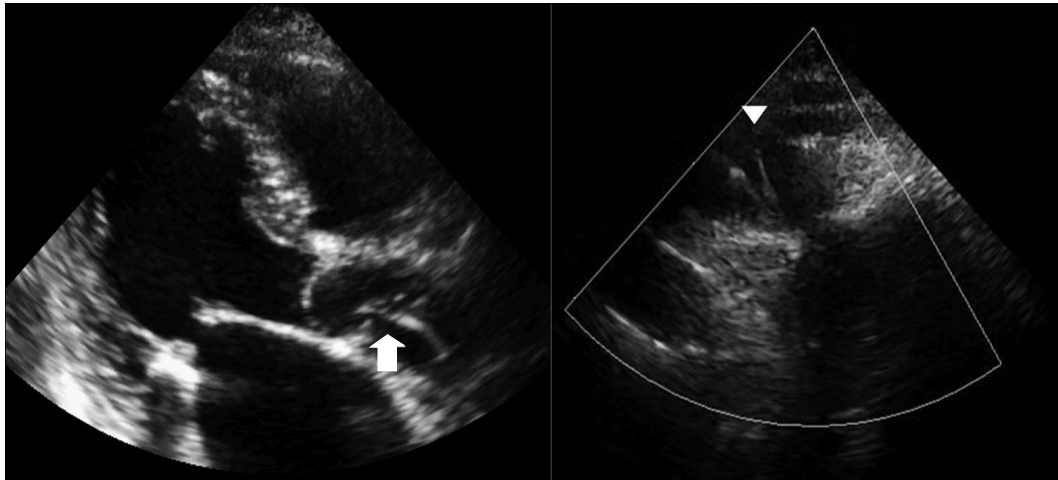
**Fig. 2.** A fracture occurred at the distal tip of the BMW guide wire (white arrow). In addition, un-coiled filaments of the BMW guide wire were left *in situ* (arrow head). BMW: Balance Middleweight.

movements of the snare, combined with distal balloon inflation retrieval, successfully removed most of the fractured guide wires (Fig. 2) but we later observed retained filaments during echocardiography (Figs. 3 and 4). The patient declined surgical

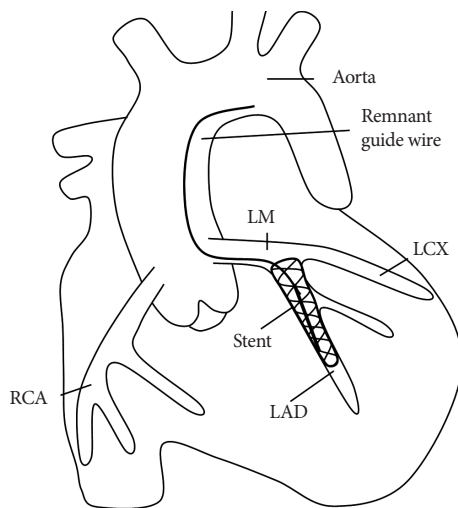
intervention for removal of these stray filaments and was discharged from our hospital, with triple anti-platelet medication and no complications. The patient did not experience any thrombotic or embolic events and did not suffer from any subjective symptoms over the one year of clinical follow up.

## Discussion

Guide wire fractures during PCI are very rare, occurring in approximately 0.1-0.2% of cases.<sup>5)</sup> Guide wire remnants could lead to life threatening complications such as thrombosis, emboli, and perforation. Therefore, in the event of failed percutaneous retrieval and persistent signs of ischemia, patients should be urgently referred for surgical intervention. There are several methods recommended for the management of fractured guide wires, including emergent surgery, loop snare removal, two- or three-wire rotation, stenting over the retained wire, and conservative treatment.<sup>6-8)</sup> Surgical extraction is strongly recommended in cases of protrusion of the guide wire



**Fig. 3.** Two-dimensional echocardiography showed string-like echogenicity from the ascending aorta (arrow) to the aortic arch (arrow head).



**Fig. 4.** Remnant guide wire filaments were located from the coronary artery to the aortic arch. LAD: left anterior descending coronary artery, LCX: left circumflex coronary artery, LM: left main coronary artery, RCA: right coronary artery.

into the ascending aorta.<sup>9-11)</sup> However, guide wire segments retained within the coronary circulation may remain benign for a long time, particularly if they are entrapped within a distal part of the vessel and do not have accompanying total coronary occlusions.<sup>3)</sup> Vascular endothelial cell covering over the guide wire fragments may render them immobile and non-thrombogenic.

Hi-torque BMW guide wires consist of a distal core and a stainless proximal shaft, facilitating treatment of multiple lesions and tortuous vessels. However, guide wire fractures may occur if the distal core and stainless proximal shaft are separated by either the trapping of the distal tip or by vascular resistance. Because the fracture in the LAD developed after stent deployment at the main branch, we could not determine the mechanism of fracture in this particular case. However, trapping of the distal tip of the BMW wire, or stent deployment over a severely angulated guide wire are two possible expla-

nations.

In conclusion, even though the most ideal management option for remnant guide wires is their removal, conservative treatment with the fragments left *in situ* may be successful in cases in which patients remain asymptomatic and hemodynamically stable. However, life-long administration of intensive anti-platelet medications and close observation are recommended for these patients.

## REFERENCES

- 1) Cafri C, Rosenstein G, Ilia R. Fracture of a coronary guidewire during graft thrombectomy with the X-sizer device. *J Invasive Cardiol* 2004; 16:263-5.
- 2) Doorey AJ, Stillabower M. Fractured and retained guide-wire fragment during coronary angioplasty: unforeseen late sequelae. *Cathet Cardiovasc Diagn* 1990;20:238-40.
- 3) van Gaal WJ, Porto I, Banning AP. Guide wire fracture with retained filament in the LAD and aorta. *Int J Cardiol* 2006;112:e9-11.
- 4) Lee HJ, Son MS, Ju KT, et al. An unusual case of guide wire fracture during coronary artery stenting for bifurcation lesion. *Korean Circ J* 2001;31:1200-2.
- 5) Khonsari S, Livermore J, Mahrer P, Magnusson P. Fracture and dislodgment of floppy guidewire during percutaneous transluminal coronary angioplasty. *Am J Cardiol* 1986;58:855-6.
- 6) Woodfield SL, Lopez A, Heuser RR. Fracture of coronary guidewire during rotational atherectomy with coronary perforation and tamponade. *Cathet Cardiovasc Diagn* 1998;44:220-3.
- 7) Collins N, Horlick E, Dzavik V. Triple wire technique for removal of fractured angioplasty guidewire. *J Invasive Cardiol* 2007;19:E230-4.
- 8) Chang CP, Lin JJ, Hung JS, Pai PY, Hsu CH. Retrieval of dislodged coronary intravascular ultrasound catheter with embolic protection device. *Int Heart J* 2009;50:121-5.
- 9) Alexiou K, Kappert U, Knaut M, Matschke K, Tugtekin SM. Entrapped coronary catheter remnants and stents: must they be surgically removed? *Tex Heart Inst J* 2006;33:139-42.
- 10) Hartzler GO, Rutherford BD, McConahay DR. Retained percutaneous transluminal coronary angioplasty equipment components and their management. *Am J Cardiol* 1987;60:1260-4.
- 11) Kilic H, Akdemir R, Bicer A. Rupture of guide wire during percutaneous transluminal coronary angioplasty, a case report. *Int J Cardiol* 2008;128:e113-4.