

Dengue virus: A global human threat: Review of literature

Shamimul Hasan, Sami Faisal Jamdar¹, Munther Alalowi²,
Sadun Mohammad Al Ageel Al Beajji³

Department of Oral Medicine and Radiology, Jamia Millia Islamia, New Delhi, ¹Department of Oral and Maxillofacial Surgery, Teerthankar Mahaveer Dental College, Teerthankar Mahaveer University, Moradabad, Uttar Pradesh, India, ²Buraydah College of Dentistry and Pharmacy, Al Qassim, ³Department of Conservative Dentistry and Endodontics, Specialist Dental Center, Hafer Al Batin, Saudia Arabia

Corresponding author (email: <shamim0571@gmail.com>)

Dr. Shamimul Hasan, C/O Mohd. Javed Khan, C-4, Duplex Quarters, New Sir Syed Nager, Aligarh, Uttar Pradesh, India.

Abstract

Dengue is an acute viral illness caused by RNA virus of the family Flaviviridae and spread by *Aedes* mosquitoes. Presenting features may range from asymptomatic fever to dreaded complications such as hemorrhagic fever and shock. A cute-onset high fever, muscle and joint pain, myalgia, cutaneous rash, hemorrhagic episodes, and circulatory shock are the commonly seen symptoms. Oral manifestations are rare in dengue infection; however, some cases may have oral features as the only presenting manifestation. Early and accurate diagnosis is critical to reduce mortality. Although dengue virus infections are usually self-limiting, dengue infection has come up as a public health challenge in the tropical and subtropical nations. This article provide a detailed overview on dengue virus infections, varied clinical manifestations, diagnosis, differential diagnosis, and prevention and treatment.

Key words: Breakbone fever, cutaneous rash, dengue virus, dental and public health, hemorrhagic diathesis, oral manifestations

INTRODUCTION

The dengue virus, a member of the genus *Flavivirus* of the family Flaviviridae, is an arthropode-borne virus that includes four different serotypes (DEN-1, DEN-2, DEN-3, and DEN-4).^[1,2] The World Health Organization (WHO) consider dengue as a major global public health challenge in the tropic and subtropic nations. Dengue has seen a 30-fold upsurge worldwide between 1960 and 2010, due to increased population growth rate, global warming, unplanned urbanization, inefficient mosquito control, frequent air travel, and lack of health care facilities.^[3-5] Two and a half billion people

reside in dengue-endemic regions^[5] and roughly 400 million infections occurring per year, with a mortality rate surpassing 5–20% in some areas.^[6] Dengue infection affects more than 100 countries, including Europe and the United States (USA).^[7] The first reported case of dengue like illness in india was in Madras in 1780, the first virologically proved epidemic of DF in India occurred in Calcutta and Eastern Coast of India in 1963-1964.^[8] Dengue virus infection presents with a diverse clinical picture that ranges from asymptomatic illness to DF to the severe illness of dengue hemorrhagic fever/dengue shock syndrome (DHF/DSS).^[4] Oral mucosal involvement

Access this article online	
Quick Response Code:	Website: www.jispcd.org
	DOI: 10.4103/2231-0762.175416

This is an open access article distributed under the terms of the Creative Commons Attribution-NonCommercial-ShareAlike 3.0 License, which allows others to remix, tweak, and build upon the work non-commercially, as long as the author is credited and the new creations are licensed under the identical terms.

For reprints contact: reprints@medknow.com

How to cite this article: Hasan S, Jamdar SF, Alalowi M, Al Ageel Al Beajji SM. Dengue virus: A global human threat: Review of literature. *J Int Soc Prevent Communit Dent* 2016;6:1-6.

is seen in approximately 30% of patients, although oral features are more frequently associated with DHF than with DF.^[9] Dengue virus infection exhibit varied clinical presentation, hence, accurate diagnosis is difficult and relies on laboratory confirmation. The condition is usually self-limiting and antiviral therapy is not currently available. Supportive care with analgesics, hydration with fluid replacement, and sufficient bed rest forms the preferred management strategy.

ETIOPATHOGENESIS

DF is a severe flu-like infection that involves individuals of all age groups (infants, children, adolescents, and adults).^[9] Transmission among human beings occurs by the mosquito *Aedes aegypti* and chiefly occurs during the rainy season.^[10] The proposed etiologies for dengue virus infection are:

- Viral replication, primarily in macrophages^[11]
- Direct skin infection by the virus^[12]
- Immunological and chemical-mediated mechanism induced by host-viral interaction.^[12]

Dengue virus gains entry into the host organism through the skin following an infected mosquito bite. Humoral, cellular, and innate host immune responses are implicated in the progression of the illness and the more severe clinical signs occur following the rapid clearance of the virus from the host organism. Hence, the most severe clinical presentation during the infection course does not correlate with a high viral load.^[13] Alterations in endothelial microvascular permeability and thromboregulatory mechanisms lead to an increased loss of protein and plasma. Proposed theories suggest that endothelial cell activation caused by monocytes, T-cells, the complement system, and various inflammatory molecules mediate plasma leakage. Thrombocytopenia may be related to alterations in megakaryocytopoiesis, manifested by infection of human hematopoietic cells and compromised progenitor cell growth. This may cause platelet dysfunction, damage, or depletion, leading to significant hemorrhages.^[14,15]

Figure 1 depicts a diagrammatic representation of the pathogenesis of dengue.

CLASSIFICATION

The WHO classifies DF into two groups: Uncomplicated and severe.^[16,17] Severe cases are linked to excessive hemorrhage, organ impairment, or severe plasma escape, and the remaining cases are considered uncomplicated.^[17]

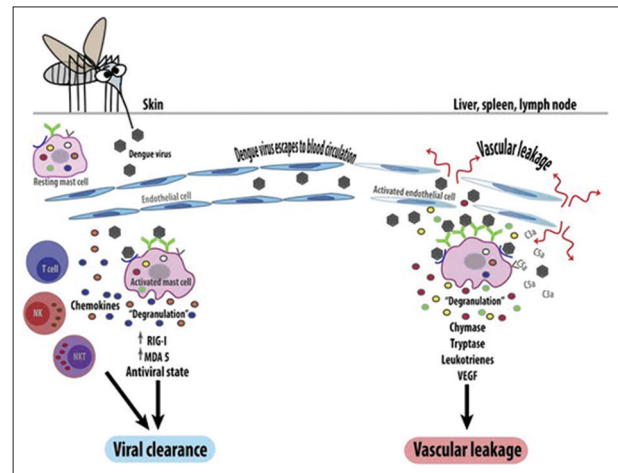


Figure 1: Pathogenesis of dengue virus infection

According to the 1997 classification, dengue can be divided into undifferentiated fever, DF, and DHF.^[18] DHF was further subdivided into grades I-IV.

- Grade I: Only mild bruising or a positive tourniquet test
- Grade II: Spontaneous bleeding into the skin and elsewhere
- Grade III: Clinical sign of shock
- Grade IV: Severe shock - feeble pulse, and blood pressure cannot be recorded.^[19]

Here, grades III and IV comprise DSS.^[17]

CLINICAL MANIFESTATIONS

Undifferentiated fever

This stage is seen mostly in the primary infection but may also occur following the initial secondary infection. Clinically, it is difficult to differentiate from numerous other viral diseases and often remains undiagnosed.

Dengue fever

DF follows both primary and secondary infections, and is most frequently encountered in adults and older children. Onset of symptoms is characterized by a biphasic, high-grade fever lasting for 3 days to 1 week.^[20,21] Severe headache (mainly retrobulbar), lassitude, myalgia and painful joint, metallic taste, appetite loss, diarrhea, vomiting, and stomachache are the other reported manifestations. Dengue is also known as breakbone fever because of the associated myalgia and pain in joints.^[16,22] Of patients with DF, 50-82% report with a peculiar cutaneous rash.^[23,24] The initial rash is the result of capillary dilatation, and presents as a transient facial flushing erythema, typically occurring before or

during the first 1–2 days of fever. The second rash is seen at 3 days to 1 week following the fever, and presents as a asymptomatic maculopapular or morbilliform eruption. Sometimes, individual lesions may merge and present as widespread confluent erythematous areas with pinpoint bleeding spots and rounded islands of sparing, giving a typical appearance of “white islands in a sea of red.”^[23,25] The cutaneous rash is usually asymptomatic, and pruritis is reported only in 16–27% cases.^[9,26] Bleeding episodes are infrequently seen in DF, although epistaxis and gingival bleeding, substantial menstruation, petechiae/purpura, and gastrointestinal tract (GIT) hemorrhage can occur.^[20,27]

Dengue hemorrhagic fever

DHF is frequently seen during a secondary dengue infection. However, in infants it may also occur during a primary infection due to maternally attained dengue antibodies.^[28] The proposed diagnostic criteria for DHF includes:^[29]

- a. Clinical parameters: Acute-onset febrile phase – high-grade fever lasting from 2 days to 1 week. Hemorrhagic episodes (at least one of the following forms): Petechiae, purpura, ecchymosis, epistaxis, gingival and mucosal bleeding, GIT or injection site, hematemesis and/or melena

Positive tourniquet and hepatomegaly.

- b. Laboratory parameters: Thrombocytopenia (platelet count <100,000/cu mm)

The hemorrhagic episodes in DHF are associated with multifactorial pathogenesis. Vasculopathy, deficiency and dysfunction of platelets and defects in the blood coagulation pathways are the attributed factors.^[30] Decreased production of platelets^[31,32] and increased destruction of platelets may result in thrombocytopenia in DHF.^[33] The impaired platelet function causes the blood vessels to become fragile and this results in hemorrhage.^[34]

The clinical course of DHF is characterized by three phases: Febrile, leakage, and convalescent phase. High-grade fever of acute onset along with constitutional signs and facial erythema characterizes the commencement of the febrile illness.^[21] The initial febrile illness is marked by a morbilliform rash and hemorrhagic tendencies.^[35] The fever persists for 2 days to 1 week and then drops to normal or subnormal levels when the patient either convalesces or advances to the plasma leakage phase.^[36] High plasma escape cases are marked by frank shock with

low pulse pressure, cyanosis, hepatomegaly, pleural and pericardial effusions, and ascites. Severe ecchymosis and gastrointestinal bleeding followed by epistaxis may also be noted in a few cases. Bradycardia, confluent petechial rashes, erythema, and pallor are seen during this phase.

Dengue shock syndrome

DSS is defined as DHF accompanied by a unstable pulse, narrow pulse pressure (<20 mmHg), restlessness, cold, clammy skin, and circumoral cyanosis. Progressively worsening shock, multiorgan damage, and disseminated intravascular coagulation account for a high mortality rate associated with DSS. The shock persists for a short span of time and the patient promptly recovers with supportive therapy.^[37,38]

OROFACIAL FEATURES

Oral features are infrequently seen in dengue virus infection and are more commonly associated with DHF. Erythema, crusting of lips, and nontongue and soft palatal vesicles constitute the prominent oral features in dengue virus infection. Chadwick *et al.*^[26] reported higher cases involving the mucosa with scleral injection (90%), whereas Sanford noticed vesicular eruptions of the soft palate (>50%).^[39] Byatnal *et al.*, reported numerous hemorrhagic bullae on the sublingual mucous membrane, lateral surface of the tongue, and floor of the mouth. Brown-colored plaque-like lesions with a rough surface were seen on the buccal mucosa that showed bleeding on touch along with spontaneous bleeding from the gingiva and the tongue. Petechiae, purpura, ecchymoses, and nasal bleeding have also been reported.^[40] Mitra *et al.* reported bleeding gums, hemorrhagic plaques, and inflamed tonsils in a dengue-infected patient.^[41] Isolated hypoglossal nerve palsy following dengue infection is a rare occurrence.^[42] Taste alteration, conjunctival redness, and lymphadenopathy may also be reported in DF.^[3] Table 1 depicts the reported orofacial features of dengue.

DIAGNOSIS

Cautious attention should be directed at DF if a patient suffers from high fever within 2 weeks of being in the tropics or subtropics.^[43] A decreased number of white blood cells (leukopenia), accompanied by a decreased number of platelet count (thrombocytopenia) and metabolic acidosis are the initial changes on laboratory examinations. Microbiological laboratory testing confirms the diagnosis of DF. Virus segregation in cell

cultures, nucleic acid demonstration by polymerase chain reaction (PCR), and serological detection of viral antigens (such as NS1) or particular antibodies are the preferred microbiological assays.^[5] Viral segregation and nucleic acid demonstration provide precise diagnosis, although the high cost limits the availability of these tests.

DIFFERENTIAL DIAGNOSIS

Broad differential diagnosis is considered in a patient presenting with fever and a rash similar to that seen in DF. Tables 2 and 3 present the varied clinical conditions that mimic the febrile and critical phase of dengue infection.

MANAGEMENT OF DENGUE INFECTION

Fluid replacement and antipyretic therapy with paracetamol is the preferred therapy following the febrile phase. Care should be taken not to use other nonsteroidal antiinflammatory drugs.

Judicious fluid administration forms the mainstay of treatment during the critical phase of the infection. Normal saline, Ringer’s Lactate, and 5% glucose diluted 1:2 or 1:1 in normal saline, plasma, plasma substitutes, or 5% albumin are the routinely administered fluids.

WHO guidelines summarize the following principles of fluid therapy:^[44]

- Oral fluid supplementation must be as plentiful as possible. However, intravenous fluid administration is mandatory in cases of shock, severe vomiting, and prostration (cases where the patient is unable to take fluids orally)
- Crystalloids form the first-line choice of intravenous fluid (0.9% saline)
- Hypotensive states that are unresponsive to boluses of intravenous crystalloids, colloids (e.g., dextran) form the second-line measures
- If the patient remains in the critical phase with low platelet counts, there should be a serious concern for bleeding. Suspected cases of bleeding are best managed by transfusion of fresh whole blood.

DENTAL MANAGEMENT

Oral lesions are infrequently seen and are often misguided as platelet defects.^[25] Significant hemorrhagic manifestations need platelet transfusions. In general, there is no need to give prophylactic platelets even at <20,000/cu mm. Prophylactic platelets may be given at a level of <10,000/cu mm in absence of bleeding manifestations. In case of systemic massive

Table 1: Summary of reported orofacial features in dengue^[4]

Author(s) and year	Reported orofacial features
Chadwick D, Arch B, Wilder-Smith A, Paton N. 2006	Mucosal involvement with scleral injection
Sanford JP, 1986	Vesicles on soft palate
Byatnal A et al. 2013	Hemorrhagic bullae on sublingual mucous membrane, lateral surface of the tongue, and floor of the mouth Brown-colored plaquelike lesions with a rough surface on the buccal mucosa Spontaneous bleeding from the gingiva and the tongue Petechiae, purpura, ecchymoses, and nasal bleeding
Mithra R, Baskaran P, Sathyakumar M, 2013	Bleeding gums, hemorrhagic plaques, and inflamed tonsils
Jaganathan S, Raman R 2014	Isolated hypoglossal nerve paralysis
Gubler DJ 1998	Taste alteration, conjunctival redness, and lymphadenopathy

Table 2: Conditions that mimic the febrile phase of dengue infection^[4]

Flu-like syndromes	Influenza, measles, chikungunya, infectious mononucleosis, HIV seroconversion illness
Illnesses with a rash	Measles, scarlet fever, rubella, meningococcal infection, chikungunya, drug reactions
Diarrheal diseases	Rotavirus, other enteric infections
Illnesses with neurological manifestations	Meningoencephalitis febrile seizures

HIV-Human Immunodeficiency Virus.

Table 3: Conditions that mimic the critical phase of dengue infection^[4]

Infections	Acute gastroenteritis, leptospirosis, malaria, typhoid, typhus, viral hepatitis, acute HIV seroconversion illness, bacterial sepsis, septic shock
Malignancies	Acute leukemia and other malignancies
Miscellaneous conditions	Acute abdomen - Acute appendicitis Acute cholecystitis Perforated viscus Diabetic ketoacidosis Lactic acidosis Leukopenia and thrombocytopenia±bleeding; platelet disorders Renal failure Respiratory distress (Kussmaul breathing), systemic lupus erythematosus

bleeding, platelet transfusion may be needed along with red cell transfusion. Liver functions should be monitored.

ADVANCED RESEARCHES

Control of mosquito (vector) transmission, development of dengue vaccine, and antiviral drugs constitute future directions with an aim to prevent and treat dengue infection.

Control of mosquito (vector) transmission can be done by keeping guppies (*Poecilia reticulata*) or copepods (*doridicola agilis*) in standing water, and infecting the mosquito population with bacteria of the *Wolbachia* genus.^[43]

Due to the progressing transmission and enhancing severity of dengue infection, the necessity to develop a dengue vaccine has gained considerable importance. There is a worldwide public health need for a safe, effective, and economic tetravalent dengue vaccine. Complex pathology, the prerequisite to control four virus serotypes, and inadequate investment by vaccine designers have hindered vaccine advancement.^[45]

Scrupulous attempts are aimed to develop antiviral drugs that can be used to manage DF and avoid the life-threatening episodes.^[46,47]

CONCLUSION

Dengue has evolved as a global life-threatening public health concern, affecting around 2.5 billion individuals in more than 100 countries. The physician should be aware about the varied clinical manifestations of this condition and ensure an early and adequate treatment plan. Future directions to combat this dreadful disease aim at methods of mosquito control, development of vaccine, and antiviral drug regimen.

Financial support and sponsorship

Nil.

Conflicts of interest

There are no conflicts of interest.

REFERENCES

1. Halstead SB. Pathogenesis of dengue: Challenges to molecular biology. *Science* 1988;239:476-81.
2. Kurane I. Dengue hemorrhagic fever with special emphasis on immunopathogenesis. *Comp Immunol Microbiol Infect Dis* 2007;30:329-40.
3. Gubler DJ. Dengue and dengue Hemorrhagic fever. *Clin Microbiol Rev* 1998;11:480-96.
4. World Health Organization (WHO). Dengue- Guidelines for Diagnosis, Treatment, Prevention and Control. New ed. Geneva, Switzerland: World Health Organization; 2009.

5. Guzman MG, Halstead SB, Artsob H, Buchy P, Farrar J, Gubler DJ, *et al.* Dengue: A continuing global threat. *Nat Rev Microbiol* 2010;8(Suppl):S7-16.
6. Linares EM, Pannuti CS, Kubota LT, Thalhammer S. Immunospot assay based on fluorescent nanoparticles for dengue fever detection. *Biosens Bioelectron* 2013;41:180-5.
7. San Martin JL, Brathwaite O, Zanbrano B, Solorzano JO, Bouckennooghe A, Dayan GH, *et al.* The epidemiology of dengue in the Americas over the last three decades: A worrisome reality. *Am J Tropical Med Hyg* 2010;82:128-35.
8. Gupta N, Srivastava S, Jain A, Chaturvedi UC. Dengue in India. *Indian J Med Res* 2012;136:373-90.
9. Thomas EA, John M, Bhatia A. Muco-Cutaneous manifestations of dengue viral infection in Punjab. *Int J Dermatol* 2007;46:715-19.
10. Arshad I, Malik FA, Hussain A, Shah SA. Dengue fever: Clinico-pathologic correlations and their association with poor outcome. *Professional Med J* 2011;18:57-63.
11. Wu SJ, Grouard-Vigel G, Sun W, Mascola JR, Brachel E, Putvatana R, *et al.* Human skin langerhans cells are targets of dengue virus infection. *Nat Med* 2000;6:816-20.
12. Bhamarapravati N. Pathology and Pathogenesis of DHF. New Delhi: WHO Meeting; 1980.
13. Whitehorn J, Simmons CP. The pathogenesis of dengue. *Vaccine* 2011;29:7221-8.
14. Guzman MG, Kouri G. Dengue and dengue hemorrhagic fever in the Americas: Lessons and challenges. *J Clin Virol* 2003;27:1-13.
15. World Health Organization. Comprehensive Guidelines for Prevention and Control of Dengue and Dengue Haemorrhagic Fever. Revised and Expanded ed. New Delhi: WHO; 2011.
16. Whitehorn J, Farrar J. Dengue. *Br Med Bull* 2010;95:161-73.
17. WHO. Dengue: Guidelines for Diagnosis, Treatment, Prevention and Control. Part 1.1.6: Dengue case classification. Geneva, Switzerland: World Health Organization; 2009. p. 10-2.
18. Ranjit S, Kissoon N. Dengue hemorrhagic fever and shock syndromes. *Pediatr Crit Care Med* 2011;12:90-100.
19. WHO. Clinical diagnosis. Chapter 2. Dengue Haemorrhagic Fever: Diagnosis, Treatment, Prevention and Control. 2nd ed. Geneva (Switzerland): World Health Organization; 1997. p. 12-23.
20. Ahmed FU, Mahmood CB, Sharma JD, Hoque SM, Zaman R, Hasan MH. Dengue fever and dengue haemorrhagic fever in children the 2000 outbreak in Chittatong, Bangladesh. *Dengue Bulletin* 2001;25:33-9.
21. Narayanan M, Aravind MA, Thilothammal N, Prema R, Sargunam CS, Ramamurthy N. Dengue fever epidemic in Chennai-a study of clinical profile and outcome. *Indian Pediatr* 2002;39:1027-33.
22. Chen LH, Wilson ME. Dengue and chikungunya infections in travelers. *Curr Opin Infect Dis* 2010;23:438-44.
23. Waterman SH, Gubler DJ. Dengue fever. *Clin Dermatol* 1989;7:117-22.
24. Itoda I, Masuda G, Suganuma A, Imamura A, Ajisawa A, Yamada K, *et al.* Clinical features of 62 imported cases of dengue fever in Japan. *Am J Trop Med Hyg* 2006;75:470-4.
25. Radakovic-Fijan S, Graninger W, Müller C, Hönigsman H, Tanew A. Dengue hemorrhagic fever in a British travel guide. *J Am Acad Dermatol* 2002;46:430-3.
26. Chadwick D, Arch B, Wilder-Smith A, Paton N. Distinguishing dengue fever from other infections on the basis of simple clinical and laboratory features: Application of logistic regression analysis. *J Clin Virol* 2006;35:147-53.

27. Kabra SK, Juneja R, Madhulika, Jain Y, Singhal T, Dar L, *et al.* Myocardial dysfunction in children with dengue haemorrhagic fever. *Natl Med J India* 1998;11:59-61.
28. Halstead SB, Lan NT, Myint TT, Shwe TN, Nisalak A, Kalyanarooj S, *et al.* Dengue hemorrhagic fever in infants: Research opportunities ignored. *Emerg Infect Dis* 2002;8:1474-9.
29. National Institute of Communicable Diseases. Investigation and Control of Outbreaks: Dengue and Dengue Hemorrhagic Fever. 1997.
30. Chiu YC, Wu KL, Kuo CH, Hu TH, Chou YP, Chuah SK, *et al.* Endoscopic findings and management of dengue patients with upper gastrointestinal bleeding. *Am J Trop Med Hyg* 2005;73:441-4.
31. La Russa VF, Innis BL. Mechanisms of dengue virus-induced bone marrow suppression. *Baillieres Clin Haematol* 1995;8:249-70.
32. Rosenfeld SJ, Young NS. Viruses and bone marrow failure. *Blood Rev* 1991;5:71-7.
33. Phanichyakarn P, Pongpanich B, Israngkura PB, Dhanamitta S, Valyasevi A. Studies on dengue hemorrhagic fever. III. Serum complement (C3) and platelet studies. *J Med Assoc Thai* 1977;60:301-6.
34. World Health Organization. Dengue and dengue haemorrhagic fever. Chapter 6. WHO Report on Global Surveillance of Epidemic Prone Infectious Diseases. Geneva: World Health Organization; 2001.
35. Richards AL, Bagus R, Baso SM, Follows GA, Tan R, Graham RR, *et al.* The first reported outbreak of dengue hemorrhagic fever in Irian Jaya, Indonesia. *Am J Trop Med Hyg* 1997;57:49-55.
36. Srikiatkachorn A, Krautrachue A, Ratanaprakarn W, Wongtapradit L, Nithipanya N, Kalayanarooj S, *et al.* Natural history of plasma leakage in dengue hemorrhagic fever: A serial ultrasonographic study. *Pediatr Infect Dis J* 2007;26:283-90.
37. Gurugama P, Garg P, Perera J, Wijewickrama A, Seneviratne SL. Dengue viral infections. *Indian J Dermatol* 2010;55:68-78.
38. Shivpuri A, Shivpuri A. Dengue-An overview. *Dent Med Probl* 2011;48:153-6.
39. Sanford JP. Harrison's Principles of Internal Medicine. 12th ed., Vol. 1. New York: McGraw-Hill; 1986.
40. Byatnal A, Mahajan N, Koppal S, Ravikiran A, Thriveni R, Parvathi Devi MK. Unusual yet isolated oral manifestations of persistent thrombocytopenia – A rare case report. *Braz J Oral Sci* 2013;12:233-6.
41. Mithra R, Baskaran P, Sathyakumar M. Oral presentation in dengue hemorrhagic fever: A rare entity. *J Nat Sci Biol Med* 2013;4:264-7.
42. Jaganathan S, Raman R. Hypoglossal nerve palsy: A rare consequence of dengue fever. *Neurol India* 2014;62:567-8.
43. Simmons CP, Farrar JJ, Nguyen V, Wills B. Dengue. *N Engl J Med* 2012;366:1423-32.
44. World Health Organization. Dengue: Guidelines for Diagnosis, Treatment, Prevention and Control. Available from: http://whqlibdoc.who.int/publications/2009/9789241547871_eng.pdf. [Last accessed on 2012 Jun 13].
45. Hombach J. Vaccines against dengue: A review of current candidate vaccines at advanced development stages. *Rev Panam Salud Pública* 2007;21:254-60.
46. Sampath A, Padmanabhan R. Molecular targets for flavivirus drug discovery. *Antiviral Res* 2009;81:6-15.
47. Noble CG, Chen YL, Dong H, Gu F, Lim SP, Schul W, *et al.* Strategies for development of dengue virus inhibitors. *Antiviral Res* 2010;85:450-62.