



# An innovative method of pilot balloon capping for submental intubation

Molli Kiran, Sri Rama Ananta Nagabhushanam Padala, Preeti Preeti, Seema Seema, Koovakattil Akhil Kuttan

Department of Anaesthesiology, All India Institute of Medical Sciences (AIIMS), Bhopal, India

**Keywords:** Bone Fracture; Capping; Oral and Maxillofacial Surgeons; Pilot Balloon; Submental Intubation; Tracheostomy.

This is an Open Access article distributed under the terms of the Creative Commons Attribution Non-Commercial License (<http://creativecommons.org/licenses/by-nc/4.0/>) which permits unrestricted non-commercial use, distribution, and reproduction in any medium, provided the original work is properly cited.

Dear Editor,

Panfacial fractures pose a challenge for anesthesiologists performing airway management. Submental intubation (SMI) has emerged as an alternative to tracheostomy, particularly for oromaxillofacial surgeries, in which there is a shared airway between the surgeon and anesthesiologist [1]. Here, we report a novel method to address the problems encountered during SMI.

A 27-year-old male patient (weight, 63 kg; height, 171 cm) involved in a road traffic accident was referred to our hospital following initial care at another institution. He sustained panfacial fractures and was scheduled for intermaxillary fixation. Our plan for anesthesia was general endotracheal anesthesia with SMI, which aimed to provide a clear and unobstructed operative field for the surgeons. Nasotracheal intubation was contraindicated in this patient because of fractures of the nasal bones and base of the skull.

During pre-anesthetic assessment, airway examination revealed Mallampati grade 2 with a mouth opening of three fingers. Standard anesthesia monitors were attached in the operating theatre. Anesthesia was induced by

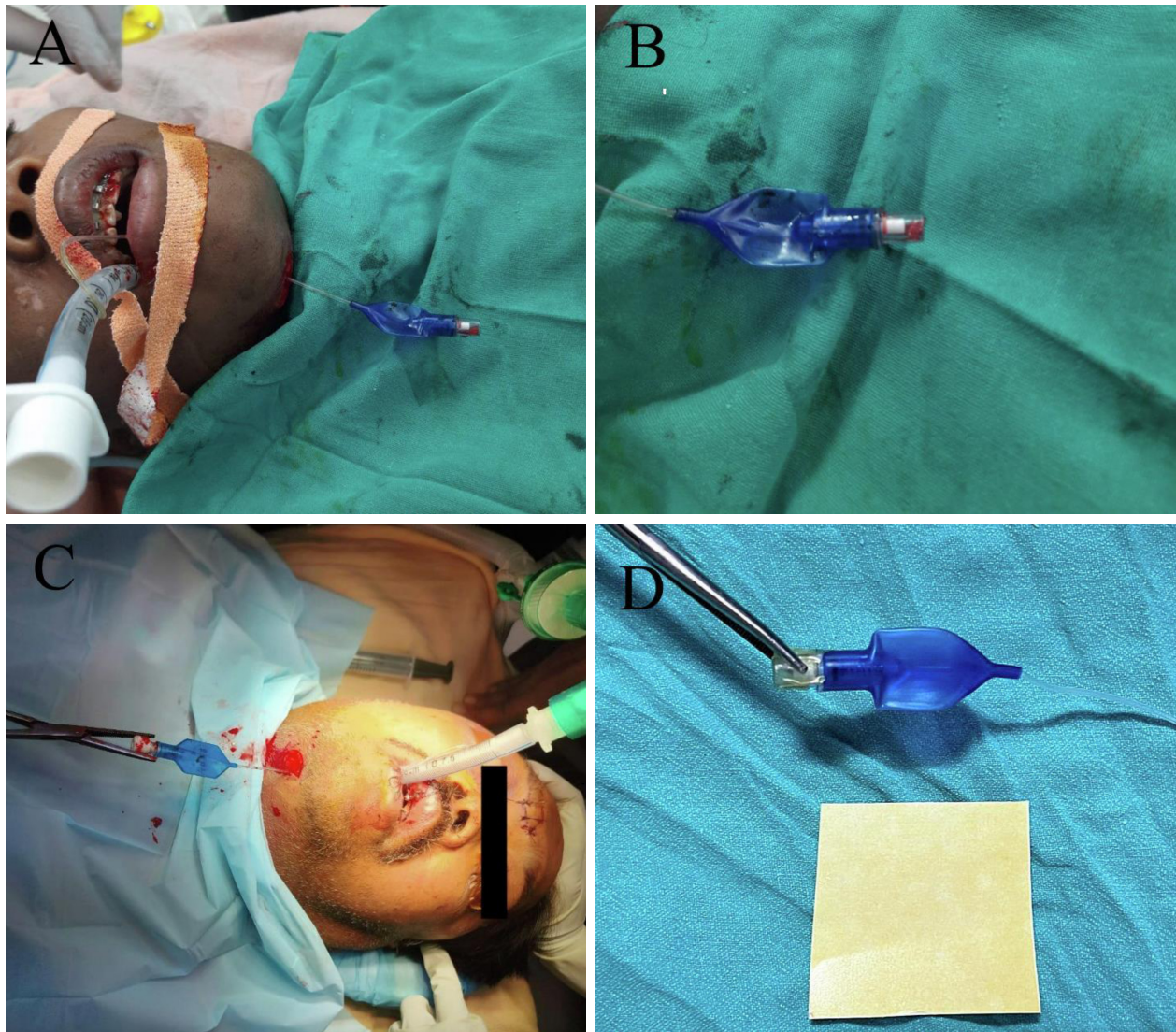
administration of intravenous midazolam 1 mg, fentanyl 150 µg, propofol 100 mg, and vecuronium bromide 7 mg, after which the trachea was intubated with standard orotracheal intubation with a 7-mm internal diameter reinforced endotracheal tube (ETT). A small incision was made in the submental region, and hemostatic forceps were passed through the mylohyoid muscle following blunt dissection. Another small incision was made parallel to the gingival margin inside the oral cavity to facilitate the entry of the hemostatic forceps. Initially, we extracted the deflated pilot balloon tube extraorally with the help of hemostatic forceps, and found that the one-way valve at the tip of the pilot balloon was obstructed by blood and tissue debris (Fig. 1A, 1B). The balloon could not be reinflated because of the high resistance of the one-way valve. The blockage was removed through the use of a 24 gauge needle and forceful installation of saline. A similar method of exteriorization was later used for the ETT, and the proper position of the ETT was confirmed by a capnography trace and bilateral symmetrical air entry on chest auscultation. The perioperative course was uneventful, and the patient was

Received: February 23, 2024 • Revised: March 3, 2024 • Accepted: March 5, 2024

Corresponding Author: Sri Rama Ananta Nagabhushanam Padala (MD, DM), Assistant Professor, Department of Anaesthesiology, All India Institute of Medical Sciences (AIIMS), Bhopal, 462020, India

Mobile: +91-7893562302 E-mail: padala72@gmail.com

Copyright© 2024 Journal of Dental Anesthesia and Pain Medicine



**Fig. 1.** (A) The patient with the exteriorized pilot balloon following submental incision, (B) Blockage of the pilot balloon one-way valve with blood and tissue debris, (C) The pilot balloon was extracted through submental incision after its tip was capped with universal intravenous cannula cap, (D) The pilot balloon tip covered with sterile adhesive plaster.

discharged on postoperative day four.

Following management of a similar case in our operating theatre, we developed this innovative method to prevent this complication. Once the hemostatic forceps reached the oral cavity, the tip of the deflated pilot balloon was occluded using a universal intravenous cannula cap. This system was then held with forceps to externally pull it out through the orocutaneous fistula (Fig. 1C), thus preventing the entry of blood or tissue debris into the pilot balloon tip, which blocks the one-way valve. The intravenous cap was removed and the ETT

cuff was inflated without difficulty. The same benefit was achieved by covering the pilot balloon tip with a sterile adhesive plaster before exteriorizing the pilot balloon (Fig. 1D).

We were unable to find any information regarding pilot balloon blockage during SMI in a literature search. However, several studies and case reports have previously proposed modifications to facilitate SMI and submandibular intubation without blood or soft tissue entering the ETT. These include use of a blue cap on the end of the thoracic catheter, a surgical glove finger,

a tracheostomy dilator of the percutaneous tracheostomy set, a laparoscopic trocar, a Nelaton catheter, a suction connector, a dental needle cap, a nasal speculum, a camera cable drape, etc. [2-7].

We believe that our innovative method of pilot balloon capping using either an intravenous cannula cap or adhesive plaster before exteriorizing the pilot balloon will certainly help anesthesiologists prevent this complication during SMI.

#### AUTHOR ORCIDs

**Molli Kiran:** <https://orcid.org/0000-0002-0771-5223>

**Sri Rama Ananta Nagabhushanam Padala:**

<https://orcid.org/0000-0003-0292-1084>

**Preeti Preeti:** <https://orcid.org/0009-0006-2248-3738>

**Seema Seema:** <https://orcid.org/0000-0002-4812-3128>

**Koovakattil Akhil Kuttan:** <https://orcid.org/0000-0001-6235-8719>

#### AUTHOR CONTRIBUTIONS

**Molli Kiran:** Conceptualization, Data curation, Supervision

**Sri Rama Ananta Nagabhushanam Padala:** Conceptualization, Data curation, Software, Writing - original draft, Writing - review & editing

**Preeti Preeti:** Conceptualization, Data curation, Writing - original draft

**Seema Seema:** Conceptualization, Data curation

**Koovakattil Akhil Kuttan:** Conceptualization, Data curation, Writing - review & editing

**CONFLICTS OF INTEREST:** None

## REFERENCES

1. Mishra R, Yadav D, Tripathi S, Kandel L, Baral PP, Shubham S, et al. Submental intubations in panfacial fractures. *Clin Cosmet Investig Dent* 2020; 12: 41-8.
2. Lim HK, Kim IK, Han JU, Kim TJ, Lee CS, Song JH, et al. Modified submental orotracheal intubation using the blue cap on the end of the thoracic catheter. *Yonsei Med J* 2003; 44: 919-22.
3. Lima SM Jr, Asprino L, Moreira RW, de Moraes M. A retrospective analysis of submental intubation in maxillofacial trauma patients. *J Oral Maxillofac Surg* 2011; 69: 2001-5.
4. Ujam A, Perry M. Minimally traumatic submental intubation: a novel dilational technique. *Eur J Trauma Emerg Surg* 2017; 43: 359-62.
5. Jung I, Yoo BH, Ju JY, Choi S, Yon JH, Kim KM, et al. Novel alternative for submental intubation - a case report. *Anesth Pain Med* 2020; 15: 247-50.
6. Jeon YG, Lee C, Hong D, Jin Y, Lim HK. Modified submental intubation techniques for maxillofacial surgery - a report of five cases. *Anesth Pain Med* 2022; 17: 331-7.
7. Yun HJ, Rhee SH, Park JY, Chae YS, Han JH, Ryoo SH, et al. A novel technique of submandibular intubation with a camera cable drape: a case report. *J Dent Anesth Pain Med* 2020; 20: 155-60.