



Contents lists available at ScienceDirect

## International Journal of Surgery Case Reports

journal homepage: [www.casereports.com](http://www.casereports.com)

# Multicystic peritoneal mesothelioma treated with complete cytoreductive surgery, peritonectomy and hyperthermic intra-peritoneal chemotherapy—A case report

Naveen Padmanabhan<sup>a,b,c</sup>, Haruaki Ishibashi<sup>b,c</sup>, Kazuro Nishihara<sup>b,c</sup>, Shouzou Sako<sup>b,c</sup>, Kanji Katayama<sup>b,c</sup>, Satoshi Wakama<sup>b,c,d</sup>, Yasuyuki Kamada<sup>b,c,d</sup>, Yutaka Yonemura<sup>b,c,d,\*</sup>

<sup>a</sup> Department of Surgical Oncology, Apollo Cancer Institutes, Chennai, India

<sup>b</sup> NPO to Support Peritoneal Surface Malignancy Treatment, Japanese/Asian School of Peritoneal Surface Oncology, Kyoto, Japan

<sup>c</sup> Department of Regional Cancer Therapies, Peritoneal Surface Malignancy Center, Kishiwada Tokushukai Hospital, Kishiwada, Japan

<sup>d</sup> Department of Surgery, Graduate School of Medicine, Kyoto University, Kyoto, Japan

## ARTICLE INFO

## Article history:

Received 26 April 2020

Received in revised form 26 July 2020

Accepted 26 July 2020

Available online 8 August 2020

## Keywords:

Mesothelioma

Cystic

Cytoreductive surgery

HIPEC

Neoplasm recurrence

Local

Case report

## ABSTRACT

**BACKGROUND:** Multicystic Peritoneal mesothelioma is a rare and distinct variety of peritoneal mesothelioma with borderline malignant potential. Conventional Tumor bulking has been associated with recurrence of 45–50 %. Hence a comprehensive treatment with Complete cytoreductive surgery with involved field peritonectomy (CRS) and Hyperthermic Intra-peritoneal chemotherapy (HIPEC) is being increasingly adopted for MCPM.

**CASE PRESENTATION:** A 47 year old lady evaluated for peri-menopausal disturbance was diagnosed to have a multicystic lesion in the pelvis. With a preoperative suspicion of diagnosis of pseudomyxoma peritonei, CRS with HIPEC was planned. On exploration a diffuse multicystic mass was found in omentum and pouch of Douglas with typical morphological features of MCPM. Complete cytoreduction was achieved with anterolateral and sub-diaphragmatic peritonectomy, omentectomy and panhystrectomy. HIPEC was performed with cisplatin 50 mg/m<sup>2</sup> for 40 min. Pathological examination revealed MCPM of omentum and uterine surface with focal clusters of mesothelial proliferation. However there was low proliferative activity 1–2 %.

**DISCUSSION:** MCPM presents with wide spread peritoneal spread but with relative sparing of visceral invasion. Literature review suggests the disease spread is similar to PMP and treatment with CCRS and HIPEC has yielded long term survivals in MCPM.

**CONCLUSIONS:** This patient with voluminous disease burden in abdomen required surgical management and HIPEC for her condition. Whether CCRS alone without HIPEC can be an alternative for limited disease will be interesting research for future clinical reports.

© 2020 Published by Elsevier Ltd on behalf of IJS Publishing Group Ltd. This is an open access article under the CC BY-NC-ND license (<http://creativecommons.org/licenses/by-nc-nd/4.0/>).

## 1. Introduction

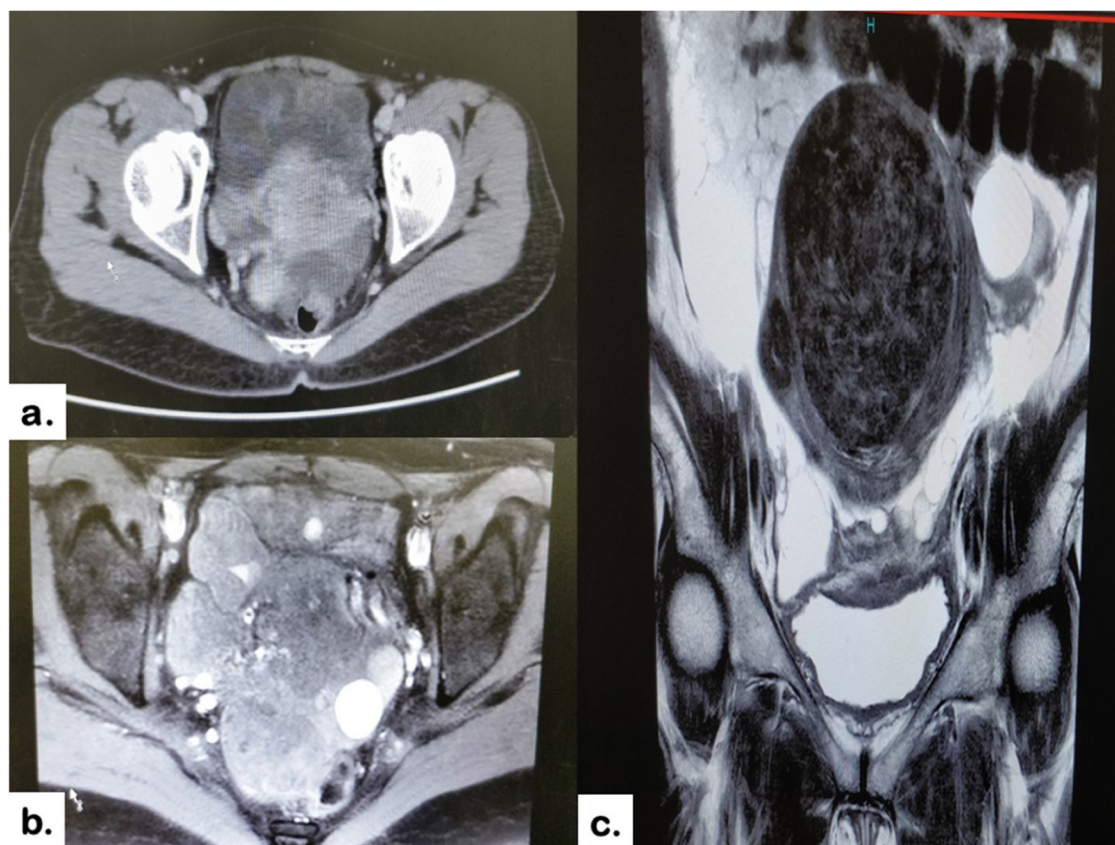
Mesothelioma is a rare tumor arising from the serous membrane of pleural, peritoneal or pericardial cavities. Peritoneal mesothelioma (PM) accounts for about one third of all mesotheliomas and has varied biological aggressiveness depending on the subtype.

Peritoneal adenomatoid mesothelioma is usually localized and has low biological aggressiveness whereas at the other end of the spectrum is diffuse malignant mesothelioma involving multiple quadrants of parietal and visceral peritoneal surfaces and has a high potential for local recurrence.

\* Corresponding author at: NPO to support Peritoneal surface Malignancy Treatment, Japanese/Asian School of Peritoneal Surface Oncology, Kyoto, Japan.  
E-mail address: [yonemu2402@gmail.com](mailto:yonemu2402@gmail.com) (Y. Yonemura).

Multicystic Peritoneal mesothelioma (MCPM) is rare and distinct variety of PM with low to intermediate malignant potential with reported long-term survival after aggressive therapy. It is common in women of reproductive age group and is unrelated to asbestos exposure. It is thought to arise from chronic peritoneal inflammation secondary to prior surgery, endometriosis or pelvic inflammatory disease, though conclusive evidence is unavailable [1,2]. Evidence suggests that it arises from fluid secretion of ovary due to peritoneal irritation and consequent trapping of this fluid in peritoneal adhesions [3].

Several authors insist that this type of tumor is not benign but a borderline malignancy that can rarely coexist with diffuse malignant mesothelioma [4,5]. Hence a comprehensive treatment with Complete cytoreductive surgery with involved field peritonectomy (CRS) and Hyperthermic Intra-peritoneal chemotherapy (HIPEC) has been advocated for MCPM [2,6]. We present our experience



**Fig. 1.** a. CT picture of Uterus surrounded with multiple cysts b. MRI T 2 sequences showing multiple cysts around the uterus, c. MRI coronal section showing uterus surrounded by cysts.

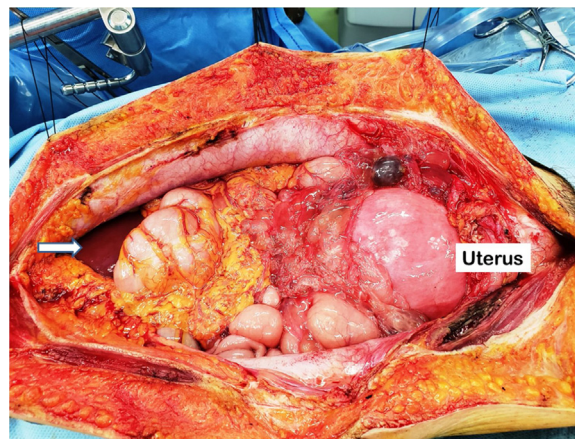
of managing a 47 year old lady with MCPM in a teaching hospital. This case is reported in line with the SCARE criteria [7] and informed consent was obtained from patient for publication of case report.

## 2. Presentation of case

Our patient, a 47 year lady reported to her gynecologist with complaints of peri-menopausal menorrhagia, dysmenorrhea and pallor in December 2019. Her past medical, drug and social history was unremarkable. Lab evaluation showed anemia and Magnetic Resonance Imaging (MRI) of pelvis revealed fibroma of the uterus. In addition, MRI showed multiple cystic areas in the pelvis and right iliac fossa (Fig. 1). Tumor markers levels were marginally elevated-Serum CA 125 – 55 IU/mL (Normal -25-35) and CA 19-9 – 6 IU/mL (Normal - <25). Provisional diagnosis of Pseudomyxoma Peritonei (PMP) originating from Ovary was made by her gynecologist and she was referred to us further therapy.

After evaluating her, our decision was to perform Exploratory laparotomy, cytoreduction and HIPEC as she had good performance status and limited spread of disease amenable for complete cytoreduction (CCR -0).

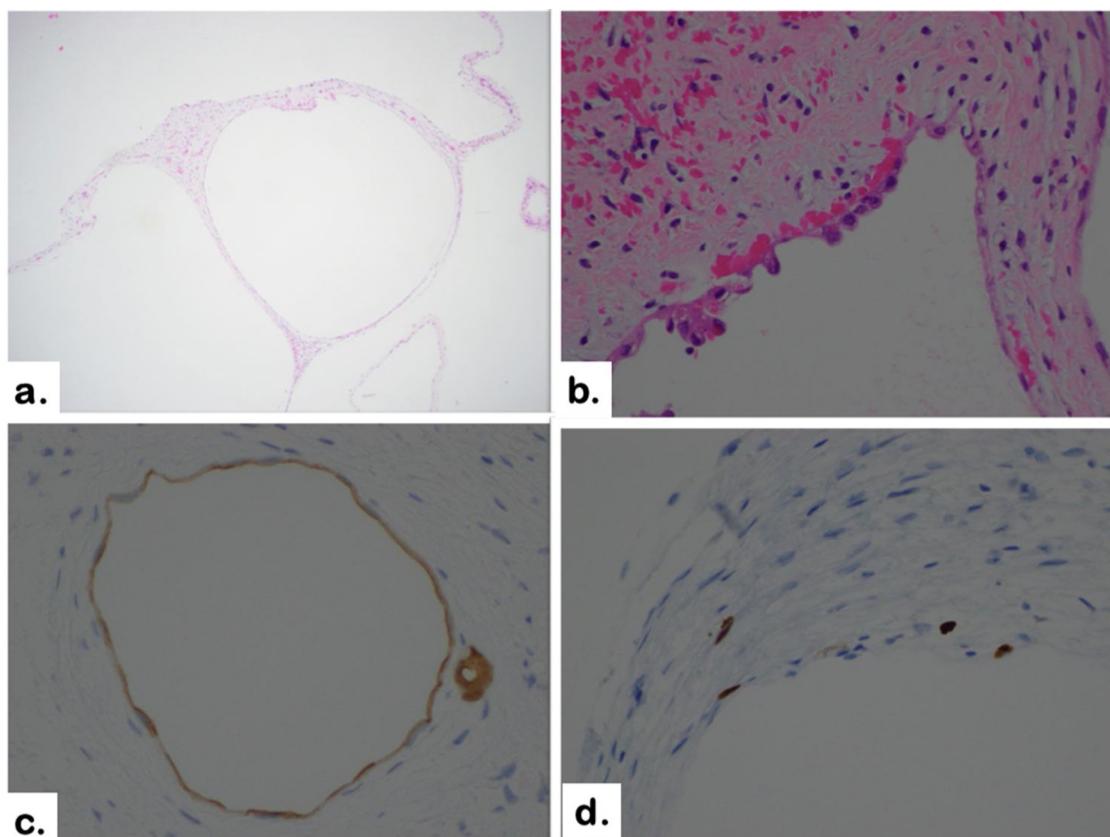
In March 2019, she underwent open surgical exploration through a Xiphopubic laparotomy by the senior author (YY). A large multicystic lesion was found in omentum and right paracolic gutter. Similar cystic lesion was found in pouch of douglas adjacent to the uterus (Fig. 2). Cysts were filled with clear to turbid fluid and were non-invasive in nature. The surgical Peritoneal carcinomatosis Index (PCI) was 6 (Lesion Size score (LS)- 3 in omentum and LS-2 in pouch of douglas, LS-1 in right paracolic gutter) and



**Fig. 2.** Intra-operative picture showing omental cystic lesion. Uterus enlarged due to fibroma and Arrow marking the liver for identification.

the adjacent structures- bowel, rectum and bladder were free of tumor. Extensive Intraperitoneal lavage (EIPL) was performed with ten liters of physiological saline and a complete cytoreduction was obtained by performing total anterolateral peritonectomy, Pelvic peritonectomy with enbloc extrafascial hysterectomy (bladder and rectum preserving), total omentectomy and excision of falciform and umbilical round ligament. She then received HIPEC with Cisplatin 50 mg/m<sup>2</sup> for 40 min.

Pathological examination showed multiple cysts lined with a layer of cuboidal mesothelial cells with no atypia (Fig. 3). There



**Fig. 3.** Microscopic Picture a. 4x- Cysts lined by cuboidal mesothelial cells, b. Cuboidal mesothelial cells in 10X view, c. IHC depicting mesothelin positivity in cystic space lining, d. Ki-67 positive in few cells.

are focal areas of proliferation of mesothelial cells in the omentum (Fig. 5). Sections of uterus showed a benign fibroma. Immunohistochemically the cells were positive for mesothelin, calretinin and negative CEA, CD-31, p 53 and D-2 40 (Fig. 3c–d). Ki-67 was low 1–2%. She recovered well after surgery and her postoperative course was uneventful. No further adjuvant therapy was indicated.

### 3. Discussion

MCPM (variably called as Peritoneal inclusion cysts, Inflammatory cysts of peritoneum, postoperative peritoneal cysts and benign papillary cystosis) is extremely rare tumor with about 200 cases reported in literature hitherto. It commonly affects young and middle age women and is associated with a prior history of abdominal surgery, endometriosis or pelvic inflammatory [8]. The disease process mainly involves omentum peritoneal surfaces, pelvic visceral surfaces like uterus, fallopian tubes, ovaries and pouch of douglas.

Preoperative diagnosis can be challenging as the symptoms are non-specific like diffuse abdominal pain, abdominal mass or pressure symptoms like dyspareunia, dysuria and disturbance of bowel habits. Imaging shows a multicystic lesion but there is no characteristic sign to clinch the diagnosis of MCPM. However MRI can characterize the nature of cyst fluid and extent of the mass. Presence of serous fluid in MCPM appears hypointense on T1 and hyperintense on T2 sequences in contrast hemorrhagic cysts appear hyperintense on T1 and hypointense on T2 sequences [9,10].

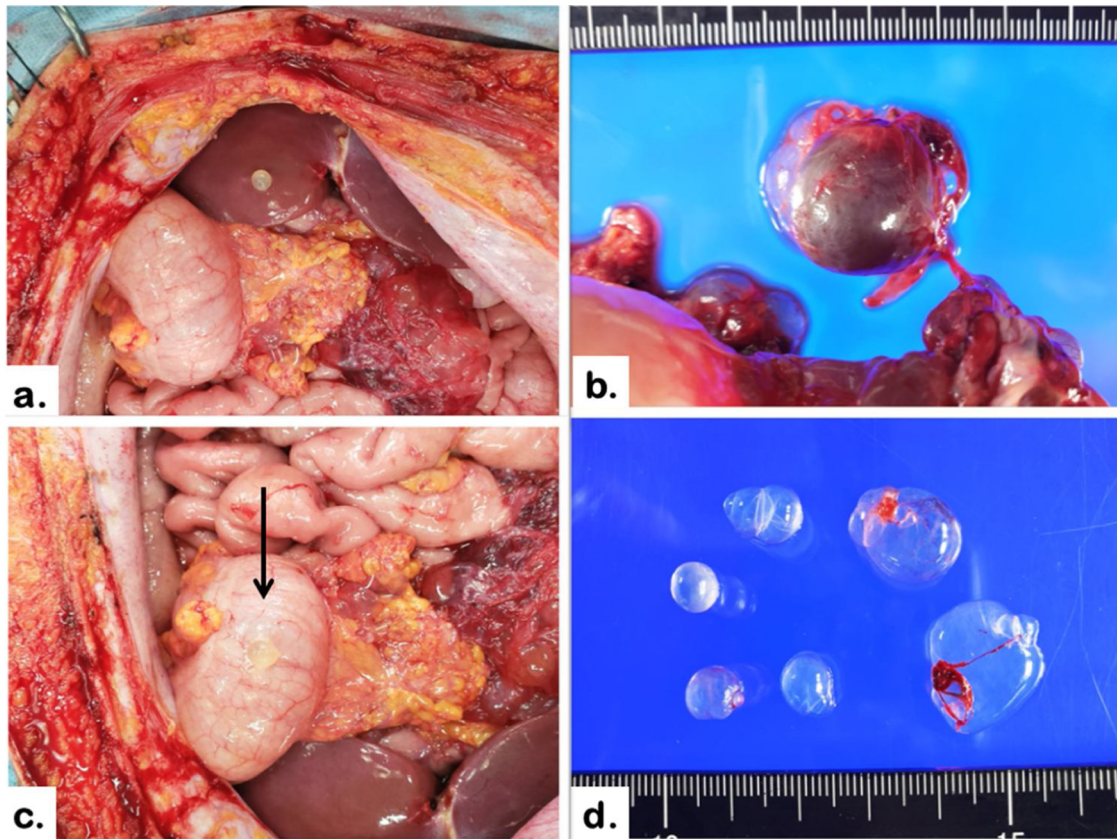
The differential diagnosis (DD) of MCPM includes cystic lesions of abdomen such as adenomatoid tumors, lymphangiomas, loculated ascites, pseudomyxoma peritonei, Diffuse malignant peritoneal mesothelioma (DMPM). Lymphangiomas commonly occurs in children and cyst is filled with chylous fluid and immunostaining of cyst wall with factor VIII is specific. DMPMs are extensive

and patients present with weight loss, abdominal distension due to ascites, multiple bulky intraabdominal masses and invasion of adjacent structures like bowel wall, pancreas and spleen [11]. MCPM has characteristic gross appearance with multiple grape like cystic lesions filled with clear to yellowish fluid attached to peritoneal surfaces and omentum. Eventually definitive diagnosis of MCPM is made by the pathologist after histopathological examination of excised specimen.

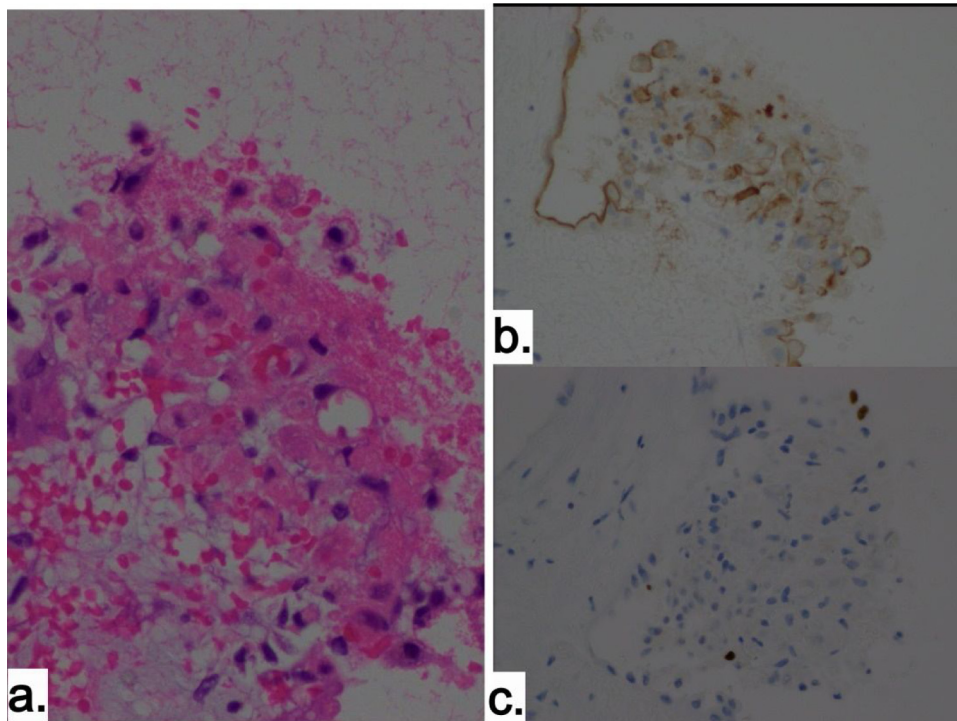
Though MCPM is reported to be a benign etiology by some, several others have reported instances of malignant transformation and co-existent DMPM in these patients [4,12–14]. In general, MCPM pathologically has multicystic or unilocular cystic lesions lined by single layer of cuboidal or flat mesothelial cells with no atypia. But in agreement to the above theory we noticed found focal areas of mesothelial proliferation which indicates there are areas of increased cellular activity (Fig. 5). Ki-67 staining was increased at this area compared to others. Similar findings has been noted by others and these areas may suggest points of ongoing transformation with higher proliferative activity [3].

Another interesting pathological finding we observed was the presence of Peritoneal free floating cysts (PFFC) in the peritoneal cavity. Yonemura et al. has reported these Peritoneal free floating cysts (PFFC) in 8/9 MCPM patients in their series [13]. Some of the cysts attached to the main mass through a thin stalk and can disintegrate easily (Fig. 4). Disintegrated cysts can be free floating and migrate to other areas in peritoneal cavity and continue to deposit on other areas to establish multicystic lesions. Due care should be taken to thoroughly examine the peritoneal cavity and remove free floating cysts. EIPL with ten liters of saline assists in mechanical washing and removal of PFFC.

Regarding the management of MCPM, considerable debate exists as there is conflicting theories regarding the nature of disease.



**Fig. 4.** Peritoneal Free floating cells a. On Liver surface, b. On colon surface, c. PFFC attached to a thin stalk, d. Specimen picture of PFFCs filled with clear watery fluid.



**Fig. 5.** a. Focal proliferation of mesothelial cells, b. corresponding IHC positivity of mesothelin in these cells, c. Ki-67 -3 % in this focal cluster.

Some authors have advocated surveillance or non-operative methods in small and asymptomatic lesions while most others regard surgery as the main stay of treatment in MCPM. With 45–50 % recurrence and potential for future transformation to invasive phenomenon, optimal surgery should include cytoreduction to remove

gross disease and HIPEC for the treatment of microscopic residue [15–17].

Several centers have reported their successful results with peritonectomy, complete cytoreduction and HIPEC for MCPMs and summary of these studies are in the Table 1 [1,2,18]. Recently group

**Table 1**  
Summary of studies of MCPM treated with Cytoreductive surgery and HIPEC.

| Center and Year                    | Patients           | PCI         | CC-0   | HIPEC           | Survival                              | Recurrence     |
|------------------------------------|--------------------|-------------|--|-----------------|---------------------------------------|----------------|
| Sugarbaker PH et al. [20]          | 5                  | –           | 4  | Cis + Dox       | 4 (NED)                               | 1 <sup>a</sup> |
| Lyon Fr [21]                       | 3                  | –           | 3  | Cis + Mitomycin | 3 (NED)                               |                |
| Multi-institutional, Chua 2010 [2] | 26                 | 14 (6–39)   | CC-0 – 19 patients<br>CC-1 – 5 patients<br>CC-2 – 2 patients | Cis + Dox       | 25 (NED)<br>1 (AWD)                   | 1              |
| NCI, Milan Nizri et al. [1]        | 19 (20 procedures) | 15.5 (6–24) | CC-0 – 17 patients<br>CC-1 – 3 patients                      | Cis + Dox       | 15 (NED)<br>4 (AWD)<br>RFS 159 months | 4              |

AWD - Alive with Disease; NED - No evidence of disease; RFS - Recurrence free survival.

<sup>a</sup> One patient had transformation to malignant mesothelioma.

from Milan, Italy reported an impressive mean recurrence free survival (RFS) of 159 months (13.2 years) and 79% RFS at 10 years with CRS and HIPEC. Such robust long term data is unavailable in studies with conservative measures or debulking surgery.

Our patient had diffuse multi cystic disease involving the omentum, pelvic and right paracolic gutter peritoneum. Her surgical PCI was 6 whereas most studies report a median PCI of 10–15 [1,2]. We performed cytoreduction and involved field peritonectomy as described above. Due to the presence of giant fibroid in the uterus a panhystrectomy was performed. However in young women, tumor excision with uterus and ovary conservation for purpose of future pregnancy has been reported [19]. These findings reflect the borderline invasive nature of the disease and support visceral preservation in appropriate cases. HIPEC was performed to eradicate the microscopic residue in the peritoneum.

In addition to existing literature, we have observed two distinctive pathological features in this case. One is the presence of free floating cysts in peritoneum with potential to deposit in other areas and second areas of increased proliferation in the background of benign mesothelial cells.

**4. Conclusion**

MCPM is borderline tumor with potential for recurrence and transformation to invasive mesothelioma. Complete cytoreduction with HIPEC appears to be the optimal treatment to eradicate the disease process. Uterus and ovarian preservation can be offered with caution in women desirous of fertility preservation.

**Conflicts of interest**

No Conflicts of Interest.

**Sources of funding**

No Funding received.

**Ethical approval**

The procedure-specific consent, patient data and material of this study had reviewed and approved by the ethical review bodies of Kishiwada Tokushukai hospital with ethic number 19–35 dated 11th November 2019.

**Consent**

Written informed consent was obtained from the patient for publication of this case report and accompanying images. A copy of the written consent is available for review by the Editor-in-Chief of this journal on request.

**Author contribution**

Naveen Padmanabhan – Study conceptualization, Data collection, drafting manuscript.  
 Haruaki Ishibashi- Data collection and analysis.  
 Kazuou Nishihara- Data collection and analysis.  
 Shouzou Sako- Data collection and analysis.  
 Kanji Katayama- Data collection and analysis.  
 Satoshi Wakama- Data collection and analysis.  
 Yasuyuki Kamada- Data collection and analysis.  
 Yutaka Yonemura Study conceptualization, Data collection and review and finalization of manuscript.  
 All members have been reviewed the final version of manuscript.

**Registration of research studies**

Not required as it is single case report and not first in human study.

**Guarantor**

Yutaka Yonemura.  
 Naveen Padmanabhan.

**Provenance and peer review**

Not commissioned, externally peer-reviewed.

**Acknowledgement**

Author Naveen Padmanabhan was supported by a Union for International Cancer Control (UICC, Geneva Switzerland) Link of fellows awarded in 2020 Technical Fellowship for visiting Kishiwada Tokushukai Hospital.

**References**

- [1] E. Nizri, D. Baratti, M. Guaglio, S. Sinukumar, A. Cabras, S. Kusamura, M. Deraco, Multicystic mesothelioma: operative and long-term outcomes with cytoreductive surgery and hyperthermic intra peritoneal chemotherapy, *Eur. J. Surg. Oncol.* 44 (2018) 1100–1104, <http://dx.doi.org/10.1016/j.ejso.2018.03.004>.
- [2] T.C. Chua, T.D. Yan, M. Deraco, O. Glehen, B.J. Moran, P.H. Sugarbaker, Multi-institutional experience of diffuse intra-abdominal multicystic peritoneal mesothelioma, *Br. J. Surg.* 98 (2011) 60–64, <http://dx.doi.org/10.1002/bjs.7263>.
- [3] C. hao Zhang, J. wei Yu, M. Luo, Multicystic peritoneal mesothelioma: a short review, *Curr. Probl. Cancer* 41 (2017) 340–348, <http://dx.doi.org/10.1016/j.cuprocancer.2017.03.002>.
- [4] S.W. Weiss, F.A. Tavassoli, Multicystic mesothelioma. An analysis of pathologic findings and biologic behavior in 37 cases, *Am. J. Surg. Pathol.* 12 (1988) 737–746, <http://dx.doi.org/10.1097/0000478-198810000-00001>.
- [5] R. Hutchinson, G.S. Sokhi, Multicystic peritoneal mesothelioma: not a benign condition, *Eur. J. Surg.* 158 (1992) 451–453.

- [6] D. Baratti, S. Kusamura, A. Sironi, A. Cabras, L. Fumagalli, B. Laterza, M. Deraco, Multicystic peritoneal mesothelioma treated by surgical cytoreduction and hyperthermic intra-peritoneal chemotherapy (HIPEC), *In Vivo (Brooklyn)* 22 (2008) 153–158.
- [7] R.A. Agha, M.R. Borrelli, R. Farwana, K. Koshy, A.J. Fowler, D.P. Orgill, H. Zhu, A. Alsawadi, A. Noureldin, A. Rao, A. Enam, A. Thoma, M. Bashashati, B. Vasudevan, A. Beamish, B. Challacombe, R.L. De Wilde, D. Machado-Aranda, D. Laskin, D. Muzumdar, A. D'cruz, T. Manning, D. Healy, D. Pagano, P. Goel, P. Ranganathan, P.S. Pai, S. Raja, M.H. Ather, H. kadioažlu, I. Nixon, I. Mukherjee, J. Gómez Rivas, K. Raveendran, L. Derbyshire, M. Valmasoni, M. Chalkoo, N. Raison, O. Muensterer, P. Bradley, C. Roberto, R. Afifi, D. Rosin, R. Klappenbach, R. Wynn, S. Giordano, S. Basu, S. Surani, P. Suman, M. Thorat, V. Kasi, The SCARE 2018 statement: updating consensus surgical CAse REport (SCARE) guidelines, *Int. J. Surg.* 60 (2018) 132–136, <http://dx.doi.org/10.1016/j.ijvsu.2018.10.028>.
- [8] A.M. Vallerie, J.P. Lerner, J.D. Wright, L.V. Baxi, Peritoneal inclusion cysts, *Obstet. Gynecol. Surv.* 64 (2009) 321–334, <http://dx.doi.org/10.1097/OGX.0b013e31819f93d4>.
- [9] V. Mehta, V. Chowdhary, R. Sharma, J.S. Golia Pernicka, Imaging appearance of benign multicystic peritoneal mesothelioma: a case report and review of the literature, *Clin. Imaging* 42 (2017) 133–137, <http://dx.doi.org/10.1016/j.clinimag.2016.10.008>.
- [10] T.B. Wang, W.G. Dai, D.W. Liu, H.P. Shi, W.G. Dong, Diagnosis and treatment of benign multicystic peritoneal mesothelioma, *World J. Gastroenterol.* 19 (2013) 6689–6692, <http://dx.doi.org/10.3748/wjg.v19.i39.6689>.
- [11] B. Noiret, F. Renaud, G. Piessen, C. Eveno, Multicystic peritoneal mesothelioma: a systematic review of the literature, *Pleura Peritoneum* 4 (2019) 0–4, <http://dx.doi.org/10.1515/pp-2019-0024>.
- [12] D.B. Destephano, J.R. Wesley, K.P. Heidelberg, R.J. Hutchinson, C.E. Blane, A.G. Coran, Primitive cystic hepatic neoplasm of infancy with mesothelial differentiation: report of a case, *Fetal Pediatr. Pathol.* 4 (1985) 291–302, <http://dx.doi.org/10.3109/15513818509026902>.
- [13] Y. Yonemura, E. Canbay, S. Sako, S. Wakama, H. Ishibashi, M. Hirano, A. Mizumoto, K. Takeshita, N. Takao, M. Ichinose, K. Noguchi, Y. Liu, Y. Li, K. Taniguchi, Multicystic mesothelioma has malignant potential: its grounds and mechanisms of peritoneal metastasis, *J. Peritoneum (and Other Serosal Surfaces)* 2 (2017), <http://dx.doi.org/10.4081/joper.2017.52>.
- [14] S. González-Moreno, H. Yan, K.W. Alcorn, P.H. Sugarbaker, Malignant transformation of “Benign” cystic mesothelioma of the peritoneum, *J. Surg. Oncol.* 79 (2002) 243–251, <http://dx.doi.org/10.1002/jso.10081>.
- [15] K. Y. M. K. S. SG, Cystic mesothelioma of the peritoneum: a report of five cases and review of the literature, *Cancer* 50 (1982), [http://dx.doi.org/10.1002/1097-0142\(19821015\)50:8<1615::AID-CNCR2820500826>3.0.CO;2-K](http://dx.doi.org/10.1002/1097-0142(19821015)50:8<1615::AID-CNCR2820500826>3.0.CO;2-K).
- [16] R. MJ, W. WR, S. RE, Multilocular peritoneal inclusion cysts (so-called cystic mesotheliomas), *Cancer* 64 (1989), [http://dx.doi.org/10.1002/1097-0142\(19890915\)64:6<1336::AID-CNCR2820640628>3.0.CO;2-X](http://dx.doi.org/10.1002/1097-0142(19890915)64:6<1336::AID-CNCR2820640628>3.0.CO;2-X).
- [17] R.N. Sawh, A. Malpica, M.T. Deavers, J. Liu, E.G. Silva, Benign cystic mesothelioma of the peritoneum: a clinicopathologic study of 17 cases and immunohistochemical analysis of estrogen and progesterone receptor status, *Hum. Pathol.* 34 (2003) 369–374, <http://dx.doi.org/10.1053/hupa.2003.31>.
- [18] D. Baratti, M. Vaira, S. Kusamura, S. D'Amico, M.R. Balestra, T. Cioppa, E. Mingrone, M. De Simone, M. Deraco, Multicystic peritoneal mesothelioma: outcomes and patho-biological features in a multi-institutional series treated by cytoreductive surgery and Hyperthermic Intraperitoneal Chemotherapy (HIPEC), *Eur. J. Surg. Oncol.* 36 (2010) 1047–1053, <http://dx.doi.org/10.1016/j.ejso.2010.08.130>.
- [19] D. Baratti, S. Kusamura, D. Nonaka, G.D. Oliva, B. Laterza, M. Deraco, Multicystic and well-differentiated papillary peritoneal mesothelioma treated by surgical cytoreduction and hyperthermic intra-peritoneal chemotherapy (HIPEC), *Ann. Surg. Oncol.* 14 (2007) 2790–2797, <http://dx.doi.org/10.1245/s10434-007-9475-8>.
- [20] K. Sethna, F. Mohamed, P. Marchettini, D. Elias, P.H. Sugarbaker, Peritoneal cystic mesothelioma: a case series, *Tumori* 89 (2003) 31–35.
- [21] G. Passot, E. Cotte, C. Brigand, A.C. Beaujard, S. Isaac, F.N. Gilly, O. Glehen, Mésotéliome péritonéal: traitement par l'association chirurgie de cytoréduction et chimiothérapie hyperthermique intrapéritonéale, *J. Chir. (Paris)* 145 (2008) 447–453, [http://dx.doi.org/10.1016/S0021-7697\(08\)74654-4](http://dx.doi.org/10.1016/S0021-7697(08)74654-4).

#### Open Access

This article is published Open Access at [sciencedirect.com](https://www.sciencedirect.com). It is distributed under the [IJSCR Supplemental terms and conditions](#), which permits unrestricted non commercial use, distribution, and reproduction in any medium, provided the original authors and source are credited.