



Case report

Paranasal transposition flap in facial soft tissue reconstruction of facial cleft Tessier type 3 & ADAM complex: A case report

Hardisiswo Soedjana^{*}, Arif Tri Prasetyo, Caroline Dewi

Division of Plastic Reconstructive and Aesthetic Surgery, Department of Surgery, University of Padjajaran - Hasan Sadikin General Hospital Bandung, Bandung, Jawa Barat, Indonesia

ARTICLE INFO

Keywords:

Paranasal flap
Alar nasal
Facial cleft
Head neck
Local flap

ABSTRACT

Introduction: Craniofacial Tessier Cleft type 3 as a common craniofacial cleft with nasolabial region soft tissue defect, forced surgeons to find their ways of reconstructing using local/regional flaps to provide defect closure. The cleft may occur in existence with other constriction band syndrome entity such as the ADAM complex. The effort to repair and give back the basic function for daily activity, put surgeons to find ways and one among them are soft tissue reconstruction using most reliable are forehead and melolabial flaps. However, many cases may limit their usages.

Case presentation: A four-month-old boy presented with ADAM complex syndrome with bilateral facial cleft Tessier 3 was done soft tissue reconstruction to repair the bilateral cleft lips using a combination of the paranasal flap. No early treatment approach such as molding was used. Although the cleft was wide enough, with limitation in flap modality, the wound healing was remarkable with no dehiscence.

Clinical discussion: This patient nasal/glabellar flap was not feasible due to glabellar region defect. Some functional and aesthetic limitations of those flaps highlight situations in which the inferior-based interpolated paranasal flap (IPNF) offers an advantageous alternative.

Conclusion: Thus, an alternative flap from inferiorly based paranasal flap proven to be good flap modalities for alar nasal area. This case report shows the good result of design, lacks, and benefit in using paranasal flap.

1. Introduction

Craniofacial clefts consist of broad-spectrum malformations at a frequency of 1 to 5 per 100,000 live birth [1]. Tessier in 1967 had assigned numbers to postulate the anatomy-based classification system for craniofacial clefts according to the position relative to the sagittal midline and the orbit. As the common craniofacial malformations, the Tessier type 3 cleft extends from the philtrum of the upper lip, the wing of the nostril, and extends to the medial canthus of the eye [2–5]. The first move was to do some soft-tissue reconstruction to ensure the proper feeding of the child [6,7]. These clefts are sometimes accompanied by combinations of amputation, secondary syndactyly, and constriction band at extremities such as amniotic deformities, adhesions, and mutilations (ADAM) complex syndrome. The features of ADAM complex include constriction rings, finger or limbs amputation, and the presence of amniotic band [8]. Constriction ring syndrome or amniotic band syndrome, is a widely known disorder. It primarily affects the extremities compared to the face. This disorder is not inherited from familial

history and is a sporadic disorder. The overall incidence rate is 1 in 15,000 births, with various degree of severity from minor to severe [4].

There are various ways to close nasal defects to provide aesthetically good proportion and functionality, including the local regional flap. Vast knowledge of local flap design is necessary for the reconstruction of alar defects to avoid distortion and potential complications [7]. Although the melolabial flap still is the workhorse for nasal defect area [9], the paranasal flap emerged as an alternative to facilitate with lesser limitations than other local flaps. This case report is aimed to report the usage of paranasal flap in the management of complete bilateral cleft lips in facial cleft Tessier 3.

2. Case report

A four-month-old boy presented to Hasan Sadikin General Hospital Plastic Surgery Outpatient Clinic due to a mouth deformity that occurred since birth. During the first visit, he was alert active, with a cleft at bilateral lips and cleft palate, hypertelorism with intercanthal distance

^{*} Corresponding author.

E-mail address: hardisiswo.soedjana5@gmail.com (H. Soedjana).

<https://doi.org/10.1016/j.ijscr.2021.106432>

Received 22 July 2021; Received in revised form 16 September 2021; Accepted 16 September 2021

Available online 22 September 2021

2210-2612/© 2021 Published by Elsevier Ltd on behalf of IJS Publishing Group Ltd. This is an open access article under the CC BY-NC-ND license

(<http://creativecommons.org/licenses/by-nc-nd/4.0/>).

35 mm, fusion at his 3rd-4th digits at the right hand, and mutilation at 3rd-4th digits DIP of the right hand, the fusion of 2nd-3rd digits of left hand and mutilation of 2nd-4th digits at middle phalange of the left hand, the fusion of 3rd-4th digits of the left foot. The patient was born in spontaneous labor and was aterm. The past medical and family history was unknown. The medical condition was not diagnosed prenatally as no ultrasound nor other radiology and further advanced test was done before labor. The patient's family was low educated and financially poor. Therefore, it is difficult to reach for treatment and better health facility. He was diagnosed with ADAM complex syndrome with bilateral facial cleft Tessier 3 (Fig. 1).

The first soft tissue reconstruction was done to repair the bilateral cleft lips using a combination of the paranasal flap to accommodate a shortage in vertical left alar nasal, and the option to use nasal flap from glabella was not feasible. The glabellar flap was not an option because there was a defect in the frontal lobe. The cleft was quite wide to complicate the approximating movement during labioplasty soft tissue reconstruction, although it was not troublesome enough to stop the surgery (Fig. 2). This was done by plastic surgeon at Hasan Sadikin Hospital Bandung.

On the upper lip, an incision was made along the philtrum column. A subperiosteal flap was elevated on both sides of the cleft. The blood supply (inferior labial artery) was preserved to reconstruct the soft-tissue defect at the lateral nasal wall and create an upper lip. Incision was made on the junction of left upper and lower alar cartilage, dissection was made to release the connective tissue between them. After get released, the lower alar cartilage was repositioned. A left paranasal flap was raised and transpositioned from the left lateral alar to close the defect at one left side of the nose after approximating the edge.

The flap was undermined widely into the lateral and medial cheek, trimmed necessarily, and secured into place using deep vertical mattress sutures. The muscle, subcutaneous, and mucosal were sutured using PGA 5-0 and skin with nylon 6-0 (Fig. 3).

The patient was discharged on day 3 post-surgery and instructed for wound treatment using chloramphenicol eye ointment 4-6 times daily at the sutured area and food intake using an orogastric tube. Follow-up was done after 5 days to remove sutures and further evaluation. The wound healing was remarkable with no dehiscence (Figs. 4 & 5). Patient was satisfied with the result.

After 3 months, the paranasal flap re-shaped the left alar nasal quite nicely so that both of the alars looked similar with a small vertical discrepancy. This showed that the paranasal flap did a decent job in reconstructing small defects in soft tissue in the alar area (Fig. 6).

This case report has been reported in line with the SCARE 2020 criteria [10] and has been approved by our IRB. Written informed consent was obtained from the patient for publication of this case report and accompanying images. A copy of the written consent is available for review by the Editor-in-Chief of this journal on request.

3. Discussion

Facial Tessier Cleft type 3 as one of the craniofacial malformations involves many structures as the vermilion border of the upper lip and the nasal wing, resulting in the lack of an oral vestibule in this area. Then, the cleft fissure goes through the sidewall of the nose up to the medial angle of the eye, and medially in relation to the lower lacrimal point; accompanied by a slit in the lower eyelid, a downward dislocation of the medial angle of the eye, microphthalmia, hypertelorism, improperly

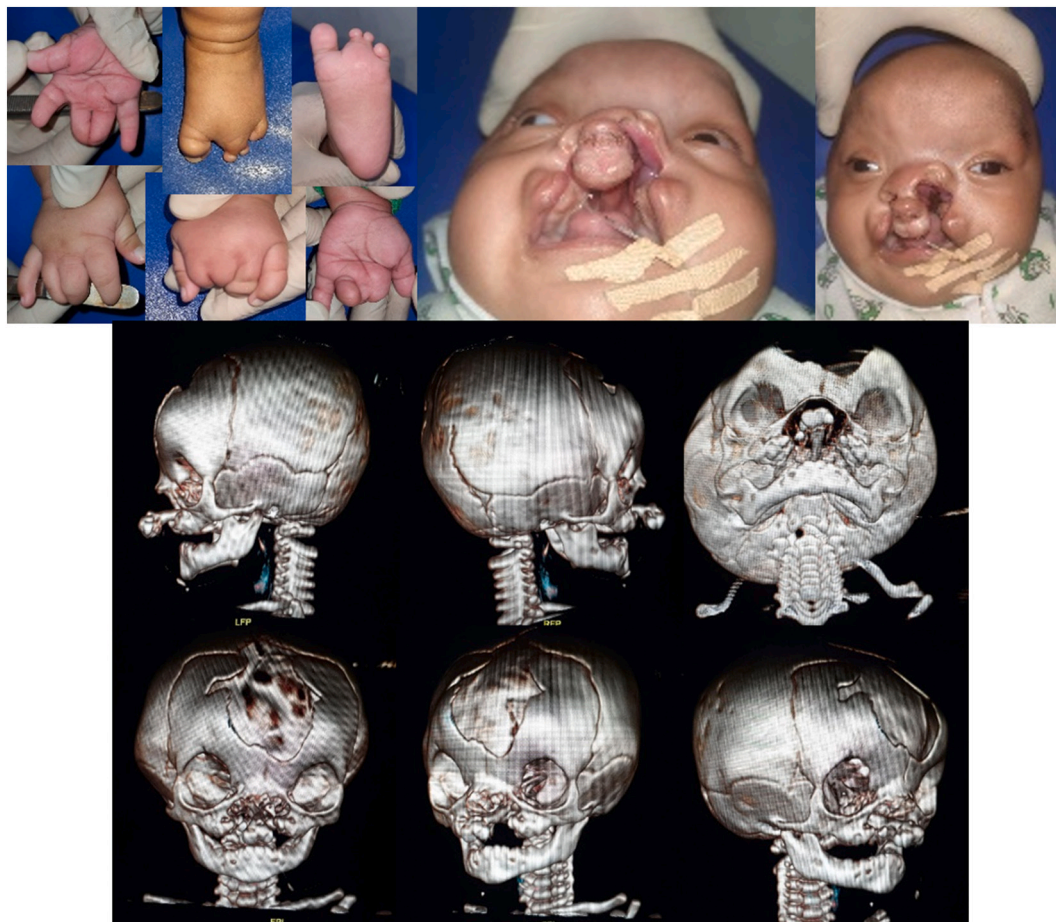


Fig. 1. Clinical examination and radiologic findings at early visit.

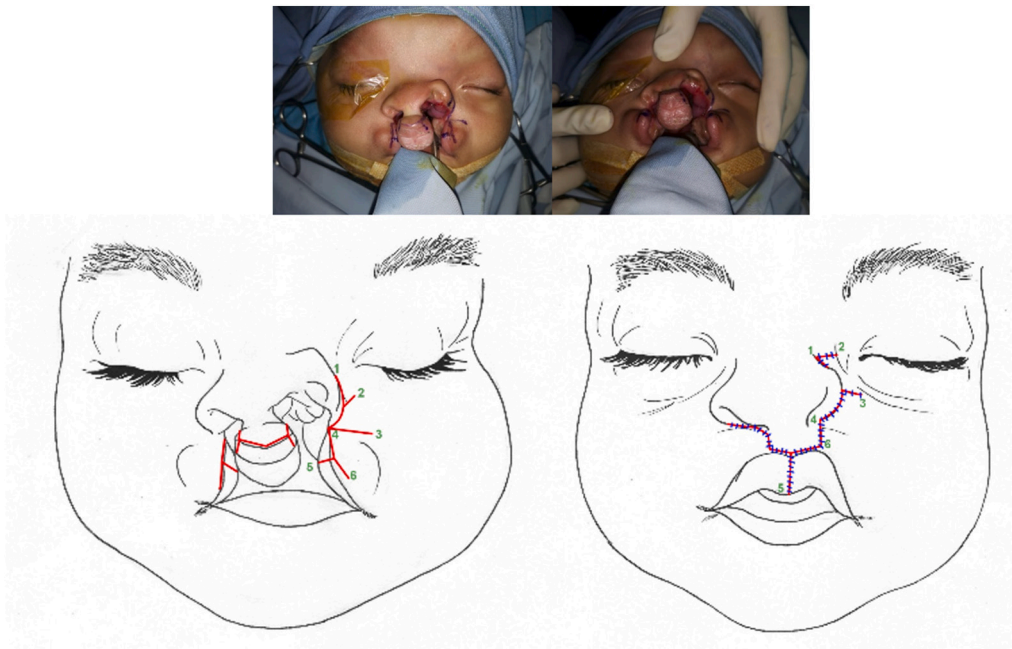


Fig. 2. Flap design using modification Millard technique and paranasal flap.

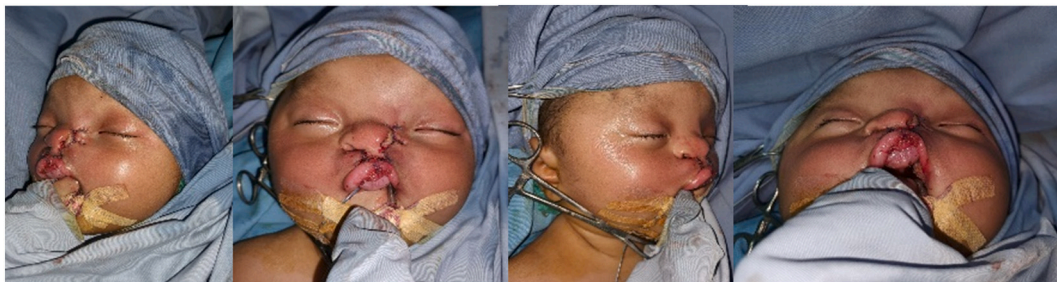

Fig. 3. Immediate post operation result, flap was vital, and no-tension at edge of the wound.

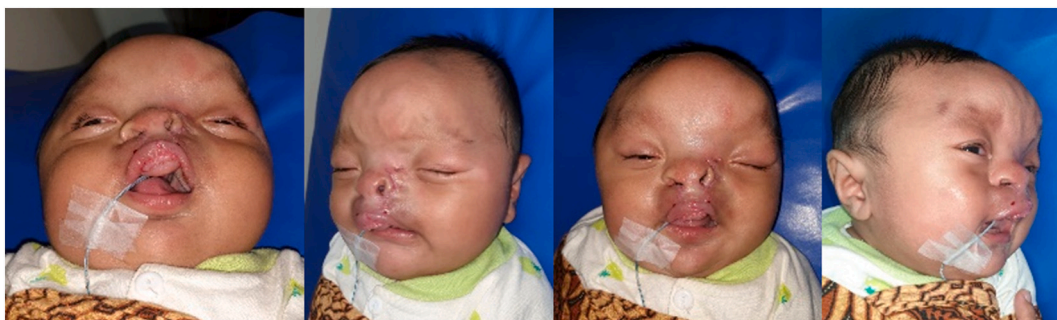

Fig. 4. Post operation day 8, aff stiches. No dehiscence, flap was vital.

formed nasopharyngeal tract, a cleft of the medial orbital wall, as well as a cleft of the hard palate and the maxillary alveolar process [2,3].

Accompanied by the constriction rings, fingers or limbs amputation and the presence of the amniotic band affect the extremities far more frequently than the face. ADAM complex causes a significant deformity that needs further soft tissue reconstruction and staged reconstruction [4,6]. Deficiency of tissue between the alar base and lower eyelid on the affected side results in a shortened shape of the nose [11]. The first step is to ensure proper feeding, minimize social stigmatization, support speech development, and minimize recurrent infections. This can be

done by closing the soft-tissue defect by reconstructing the lateral part of the nose, alar, and upper lip [12].

In our case, the cleft face malformation that caused food intake difficulties was also prone to repeat recurrent infections. Thus, it led to psychological problems for both parents and the child due to appearance and functional speech difficulties. The problem was further emphasized in marginalized societies and potentialized stigmatization areas [2]. The facial deformity was not diagnosed prenatally owing to several factors stated before in this paper. As a preventative measure, examination using 2D or better 3D ultrasound would be valuable [1]. The

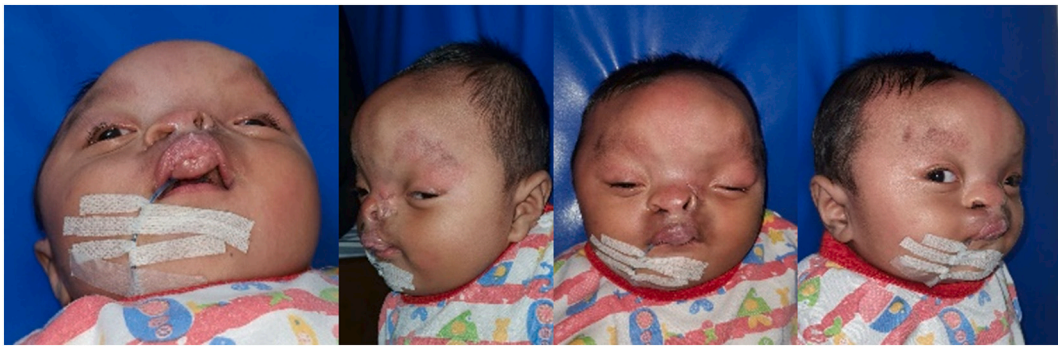

Fig. 5. Post operation day-12. The wound healed nicely, and the flap was vital.

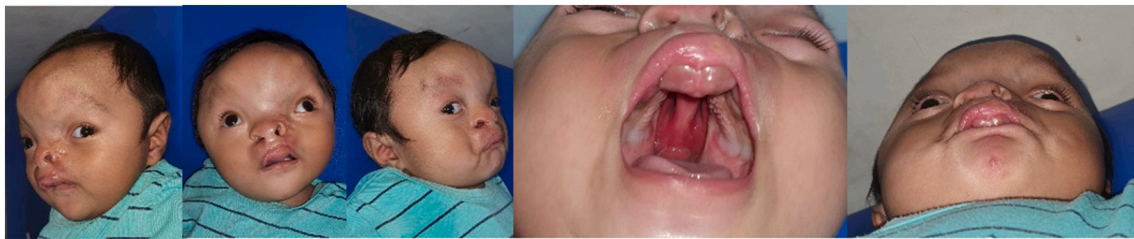

Fig. 6. At 3 months after operation.

malformation also showed a short distance between medial canthi to nasion and a wide cleft state. The skin was lax enough with no scar/wound.

During soft tissue reconstruction, Flap tissue is necessary for coverage of full-thickness defects of the nose or when bone or cartilage are exposed. Medially, superiorly, and laterally based flaps are best used for reconstruction of the nose, while inferiorly based flaps lend themselves to transfer to the upper lip and nasal floor [9]. The more cephalad portion is best covered by the forehead tissue and the alar subunit replacement by interpolated melolabial flap (IMLF) undoubtedly [12]. Maintaining a lymphatic drainage route through the pedicle is the advantage of the flap, which remains continuously to the cheek skin. Circumferential scar may also be avoided, which in part account for the trap-door deformity [9]. In certain situations, the use of a nasal flap was impossible due to a significant defect of the lateral nose [13]. However, this patient was in a condition in which nasal/glabellar flap was not feasible due to a defect at the glabellar region. Some functional and aesthetic limitations of those flaps highlight situations in which the inferior-based interpolated paranasal flap (IPNF) offers an advantageous alternative [11,13]. The groove at the lateral alar must be preserve; thus, the paranasal flap shall be used in an interpolation manner [9,14]. Local flaps should be designed in a manner that they do not cross the borders that separate aesthetic regions, especially if the border's topography is concave similar to the alar facial sulcus [15].

Small to medium-sized defects within the alar subunit may not be optimally repaired using alternative reconstructive options due to hair-bearing donor site in men or older patients and its resultant facial asymmetry may occur after melolabial interpolation flaps, which is aesthetically troubling for some demanding patients [7].

The paranasal flap donor site has texture, contour, and composition that match the ala and lacks terminal hairs; which is a good option as a donor site. Furthermore, considering that this flap is a highly vascularized area and has axis rotation of 90° or less, it allows for a shorter flap size and less torsional constriction on the flap's vascular pedicle [13].

The main indications and considerations that need to be taken into place are:

- The vertical height of the alar wound must be equal to the horizontal distance of the flap's design in the paranasal region.
- The mobility of the medial cheek and native eyelid position and tone must be carefully assessed.
- Facilitate a good donor closure
- Relative contraindications: excessive lower lid laxity or lack of adequate donor site reserves, who have had recent surgery in the area of the flap donor site, poor mental status who may be prone to disassembling interpolation flaps

In one paper, it was mentioned that they excised skin and subcutis medial to the defect. The medial incision of the flap was started immediately, lateral to the alar margin, then further cephalad in the melolabial fold, and to the nasofacial sulcus. The lateral flap incision essentially paralleled the medial incision. Approximately 2 to 3 mm of the lateral alar subunit may be left intact at the time of the initial flap inset. This was done to maintain the convexity of nasolabial sulcus. Preserving the pedicle, care for the rotation is necessary so that the pedicle does not kink. Ensure that there is no cartilage damage caused by the wrong suture technique and that the knots of sutures are carefully hidden lateral or deep to the cartilage graft [13].

This paranasal random-pattern flap derives its vascular supply from branches of the angular arterial branch of the facial artery. Thinning to the dermis has been successful, however meticulous acts must be done to prevent skin necrosis. The closing act must also assure neutral lid position, and preventive measures of ectropion must be considered [13,14].

This present case started the incision following the earlier paper by measuring the defect closure and trimming the excess skin. The thinning was done carefully until almost to the dermis, and then the flap was inserted in an advancement manner. Although there is a risk to a blunt in the facial sulcus, proper measure and positioning in this case had lessened the probability. The result showed a vital flap, an insignificant difference between right and left alar nasal vertical height, and a normal scar due to no tension sutures.

The patient was subjected to a long-term medical treatment plan for further soft tissue reconstruction. The goal was to repair and maximize function for daily activities and improve quality of life. Refinement for cleft, bone graft, syndactyly in the bilateral hand and left foot, etc. are

included as well.

The use of passive acrylic plate or known as naso-alveolar mold (NAM) may help this patient. It works in expansion theory, elongate soft tissue and add modality for soft tissue reconstruction, especially since he had a wide cleft. However, this acrylic plate was not covered by national health insurance. Financially troubled and difficult to reach health facility which able to provide acrylic plate, made this patient reluctant to pursue the benefit of NAM. Patients with cleft are necessary to have several steps of reconstruction. Patient with cleft such as in Tessier type 3 clefts, may benefit from the use of bone graft. It provides stability, eliminate cleft, good occlusal status, prevent contracture, and improve aesthetic outcome [5,11,16].

As the world has grown a vast medical advancement in knowledge and technology, the treatment for ADAM complex will be better and hopefully made easier to access especially for those troubled but in need. Thus, provide a better quality of life for the patient and their family.

4. Conclusion

There are many local flap designs for alar nasal area defects with melolabial as the main workhorse flap. However, the paranasal flap is a good option as an alternate local flap for small soft-tissue reconstruction in the ADAM complex's facial cleft with a vertical discrepancy in the alar nasal area.

Sources of funding

None.

Ethical approval

Obtained.

Consent

Written informed consent was obtained from the patient for publication of this case report and accompanying images. A copy of the written consent is available for review by the Editor-in-Chief of this journal on request.

Author contribution

First author as concept master, data collector, operator, analysis, and editing; second author as concept master, data collector, analysis, and editing; third author as data collector, analysis, and editing.

Registration of research studies

Not applicable.

Guarantor

Dr.dr.Hardiswo Soedjana, SpBP-RE(K).

Provenance and peer review

Not commissioned, externally peer-reviewed.

Declaration of competing interest

There is no conflict of interest.

References

- [1] H.K. Kawamoto Jr., The kaleidoscopic world of rare craniofacial clefts: order out of chaos (Tessier classification), *Clin. Plast. Surg.* 3 (4) (1976 Oct) 529–572.
- [2] P. Tessier, Anatomical classification facial, cranio-facial and latero-facial clefts, *J. Maxillofac. Surg.* 4 (1976) 69–92.
- [3] M.A. Darzi, N.A. Chowdri, Oblique facial clefts: a report of Tessier numbers 3, 4, 5, and 9 clefts, *Cleft Palate Craniofac.* 30 (4) (1993) 414–441.
- [4] Charles H. Thorne, Grabb and Smith's Plastic Surgery, 7th ed., LWW, Philadelphia, 2014.
- [5] Peter C. Nelligan, Plastic Surgery. Chapter 33: Craniofacial Cleft, 3rd Ed., Elsevier, China, 2013.
- [6] S.M. Balaji, Two-stage corrections of rare facial Tessier's cleft - 3,4,5,6,7, *Ann. Maxillofac. Surg.* 7 (2) (2017) 287–290.
- [7] G.H. Fisher, J.W. Cook, The interpolated paranasal flap, *Dermatol. Surg.* 35 (4) (2009) 656–661.
- [8] H. Keller, G. Neuhauser, M.V. Durkin-Stamm, E.G. Kaveggia, A. Schaaff, F. Sitzmann, L.B. Holmes, "ADAM complex" (amniotic deformity, adhesions, mutilations)—A pattern of craniofacial and limb defects, *Am. J. Med. Genet.* 2 (1) (1978) 81–98.
- [9] Shan R. Baker, Chapter 12: Melolabial Flap in Local Flaps in Facial Reconstruction, 2nd Ed., Elsevier, China, 2007.
- [10] for the SCARE Group, R.A. Agha, T. Franchi, C. Sohrabi, G. Mathew, The SCARE 2020 guideline: updating consensus Surgical Case REport (SCARE) guidelines, *Int. J. Surg.* 84 (2020) 226–230.
- [11] Charles H. Thorne, Grabb and Smith's Plastic Surgery, 7th Ed., LWW, China, 2014.
- [12] J.L. Cook, The undesirable influence of reconstructive procedures on the symmetry of the nasolabial folds, *Dermatol. Surg.* 31 (11 Pt 1) (2005) 1409–1416.
- [13] O. Cizmeci, S.V. Kuvat, Tessier no.3 incomplete cleft reconstruction with alar transposition and irregular Z-plasty, *Plast. Surg. Int.* 3 (2011).
- [14] Berish Strauss, Luis O. Vasconez, Charles K. Herman, Bernard T. Lee, Grabb Encyclopedia of Flaps Head and Neck Volume One, 4th Ed., LWW, 2015.
- [15] S.R. Baker, T.M. Johnson, B.R. Nelson, The importance of maintaining the alar facial sulcus in nasal reconstruction, *Arch. Otolaryngol. Head Neck Surg.* 101 (1995) 617.
- [16] G. Captier, M. Bigorre, L. Mattei, C. Delestan, P. Montoya, La greffe osseuse secondaire dans les fentes labio-maxillo-palatines totales: modalités techniques et indications à propos de 62 greffes [The secondary bone grafting in cleft lip and palate: technical notes and indications about 62 cases], *Ann. Chir. Plast. Esthet.* 48 (1) (2003 Feb) 20–30.