

Water Can Make the Clearest Ultrasonographic Image During Reduction of Nasal Fracture

Yuka Shigemura, MD
Jun Akamatsu, MD, PhD
Naoya Sugita, MD
Takashi Nuri, MD, PhD
Koichi Ueda, MD, PhD

Department of Plastic and Reconstructive Surgery
Chikamori Hospital
Kōchi, Kochi Prefecture
Japan
Department of Plastic and Reconstructive Surgery
Osaka Medical College
Takatsuki, Osaka
Japan

Sir:

Ultrasonography is now a very popular noninvasive imaging technique. It has been reported to be useful in the diagnosis and assessment of reduction in nasal bone fracture.¹⁻³ Ultrasonography can detect local and superficial fractures. However, it is difficult to see the whole nasal bone and the neighboring facial bones because the probe cannot be applied to such a complicated 3D structure.⁴

Various media are used to solve the problem.⁴ Ultrasound signals are attenuated by passing through the medium. The attenuation rate can be calculated by the following relationship: Attenuation volume (dB) = Attenuation index (dB/cm/MHz) × Depth (cm) × Frequency (MHz).

The larger the attenuation index of the medium, the more signals are absorbed as they pass through the medium. The greater the depth of the medium, the more ultrasound is absorbed. The higher the frequency of the ultrasound, the greater is the absorption as it passes through the medium.

The attenuation index of water is the lowest in the various media (Table 1). Therefore, a clear ultrasonographic image can be obtained if water can be utilized as the medium. We used saline as the coupling medium for ultrasonography in nasal bone fracture.

Copyright © 2014 The Authors. Published by Lippincott Williams & Wilkins on behalf of The American Society of Plastic Surgeons. PRS Global Open is a publication of the American Society of Plastic Surgeons. This is an open-access article distributed under the terms of the Creative Commons Attribution-NonCommercial-NoDerivatives 3.0 License, where it is permissible to download and share the work provided it is properly cited. The work cannot be changed in any way or used commercially.

Plast Reconstr Surg Glob Open 2014;2:e203; doi:10.1097/GOX.000000000000132; Published online 14 August 2014.

To keep saline on the face, the outer frame of a snorkeling mask made of thermoplastic elastomer was used (Fig. 1). To prevent saline from entering the nasal cavity, we sealed the nostrils with medical tape. The ultrasound probe could be applied through the pool of saline without adding pressure to the nasal bone fracture site. The ethical committees of Chikamori Hospital and Osaka Medical College approved this method before it was performed.

The ultrasonographic images in the 4 different directions (axis, sagittal, inclining views from the right and left side) were scanned routinely before and after reduction.

The probe (Venue 40, GE healthcare; 12-MHz linear array) was used under general anesthesia.

Table 1. Attenuation Index of Various Media

Medium	Attenuation Index (dB/cm/MHz)
Water (20°C)	0.002
Sonagel (coupling medium, Takiron)	0.05*
Blood	0.2
Fatty tissue	0.6
Liver	0.9
Brain	0.9
Muscle	2.3
Air	12.3
Bone	13.0

*Taniguchi, M. 2014, personal communication.

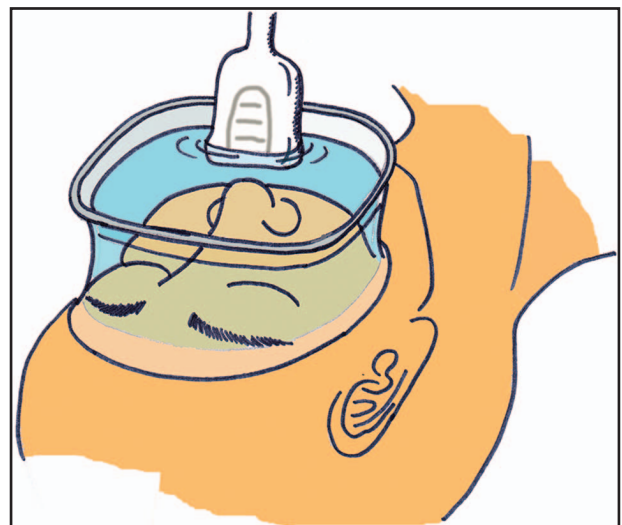


Fig. 1. Saline was used as coupling medium for ultrasonography. The outer frame of a snorkeling mask made of thermoplastic elastomer was used to keep saline on the face. To prevent saline from entering the nasal cavity, the nostrils were sealed with medical tape.

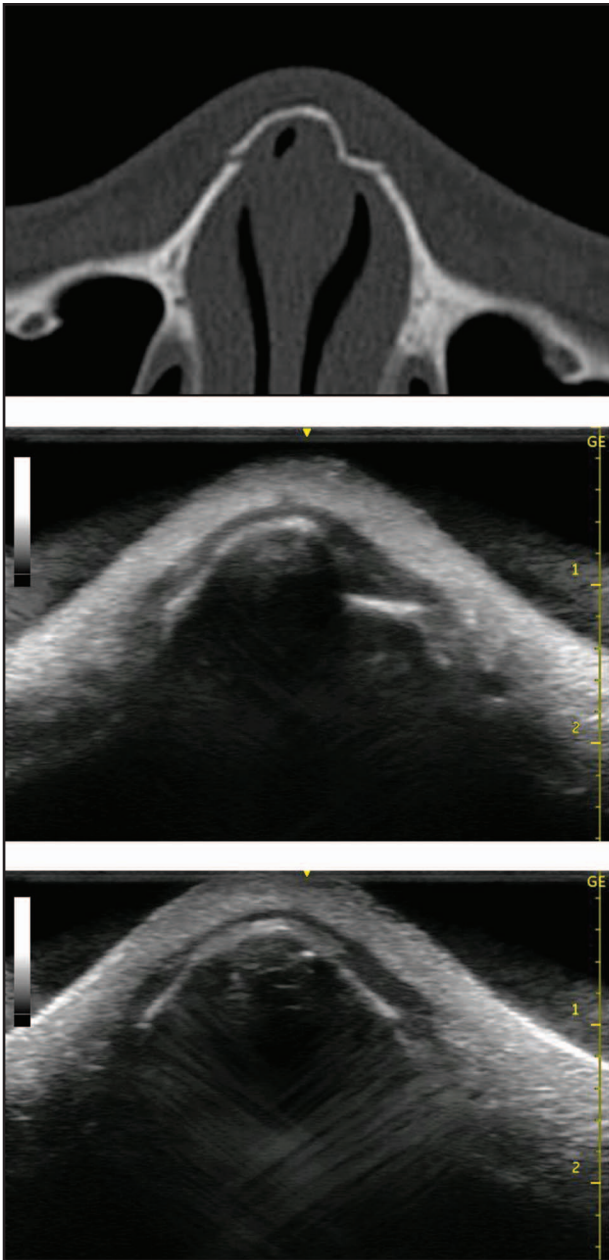


Fig. 2. Case. A, A preoperative computed tomography scan image of a 16-year-old girl who had nasal bone fracture. B and C, Preoperative and postoperative ultrasound images with saline used as a coupling medium.

This method was applied in the treatment of a nasal bone fracture of a 16-year-old girl. In comparison with a preoperative computed tomography scan, we could obtain clearer ultrasonographic images and demonstrate successful reduction during operation (Fig. 2).

For ultrasonography, a gel is most commonly used medium. However, with a gel it is often difficult to see the whole nose. A gel pad as a coupling medium has been reported (Sonagel).⁴ It is useful, but there is a contact problem with the nose and attenuation during scanning because of heaviness, shape, size, and thickness. It is difficult to avoid pressure on the fracture site when applying the probe on the gel pad.⁴

Water has a better attenuation index than a gel pad (Table 1) and does not add pressure on the fracture site during probe scanning; and the clearest image can be obtained.

We believe our method is simple and very useful in evaluating reduction of nasal bone fractures. This method can be refined to provide a simpler procedure.

Correspondence to Dr. Ueda
 Department of Plastic and Reconstructive Surgery
 Osaka Medical College
 Takatsuki, Osaka 569-8686
 Japan
 pla007@poh.osaka-med.ac.jp

DISCLOSURE

The authors have no financial interest to declare in relation to the content of this article. The Article Processing Charge was paid for by the authors.

REFERENCES

1. Hong HS, Cha JG, Paik SH, et al. High-resolution sonography for nasal fracture in children. *AJR Am J Roentgenol.* 2007;188:W86-W92.
2. Lee MH, Cha JG, Hong HS, et al. Comparison of high-resolution ultrasonography and computed tomography in the diagnosis of nasal fractures. *J Ultrasound Med.* 2009;28:717-723.
3. Park CH, Joung HH, Lee JH, et al. Usefulness of ultrasonography in the treatment of nasal bone fractures. *J Trauma.* 2009;67:1323-1326.
4. Ishisaka T, Tanaka K. A study on the concomitant use of acoustic coupling medium for intraoperative diagnosis ultrasound during reduction of facial bone fractures. *J Jpn Cranio-Max-Fac Surg.* 2013;29:55-63.