

Available online at [www.sciencedirect.com](http://www.sciencedirect.com)

ScienceDirect

journal homepage: [www.elsevier.com/locate/radcr](http://www.elsevier.com/locate/radcr)

## Case Report

# Combined surgical and interventional radiological treatment for biliary leakage following iatrogenic biliary obstruction<sup>☆</sup>

Paladini Andrea<sup>a,\*</sup>, Borzelli Antonio<sup>b</sup>, Beomonte Zobel Daniela<sup>a</sup>, Paladini Luigi<sup>c</sup>, Corvino Fabio<sup>b</sup>, Silvestre Mattia<sup>b</sup>, Frauenfelder Giulia<sup>d</sup>, Giurazza Francesco<sup>b</sup>, Niola Raffaella<sup>b</sup>

<sup>a</sup> Università Cattolica del Sacro Cuore, Roma – Fondazione Gemelli - Dipartimento di Bioimmagini e Scienze Radiologiche, Rome, Italy

<sup>b</sup> AORN “A.Cardarelli”, Napoli – UOSC Radiologia Vascolare ed Interventistica, Napoli, Italy

<sup>c</sup> Università Cattolica del Sacro Cuore, Roma – Fondazione Gemelli, Rome, Italy

<sup>d</sup> Policlinico Universitario Campus Biomedico – Roma, – UOC di Diagnostica per Immagini e Radiologia Interventistica, Rome, Italy

## ARTICLE INFO

## Article history:

Received 2 April 2018

Revised 25 April 2018

Accepted 30 April 2018

## Keywords:

Biliary leakage

Combined treatment

Complication

Laparoscopic cholecystectomy

## ABSTRACT

Biliary leakage is a challenging complication when managing the bile duct strictures. The etiology of benign strictures of the biliary tree may have different etiologies but iatrogenic is the most common, with relevant increase after introduction of laparoscopic procedures.

Interventional radiologist plays a key role, both in diagnosis and treatment of biliary strictures and leakage.

We report on a case of a 39-year-old woman affected by abdominal pain and jaundice after laparoscopic cholecystectomy; jaundice was caused by surgical clipping of the common bile duct. The combined management by surgeon and interventional radiologist, consisting of removal of surgical clip and percutaneous management of biliary leakage, successfully resolved the leakage with clinical success.

© 2018 The Authors. Published by Elsevier Inc. on behalf of University of Washington.

This is an open access article under the CC BY-NC-ND license.

(<http://creativecommons.org/licenses/by-nc-nd/4.0/>)

## Introduction

The treatment of bile duct strictures is challenging from both a surgical and interventional point of view, due to the difficult technical coefficient and the high complication rate.

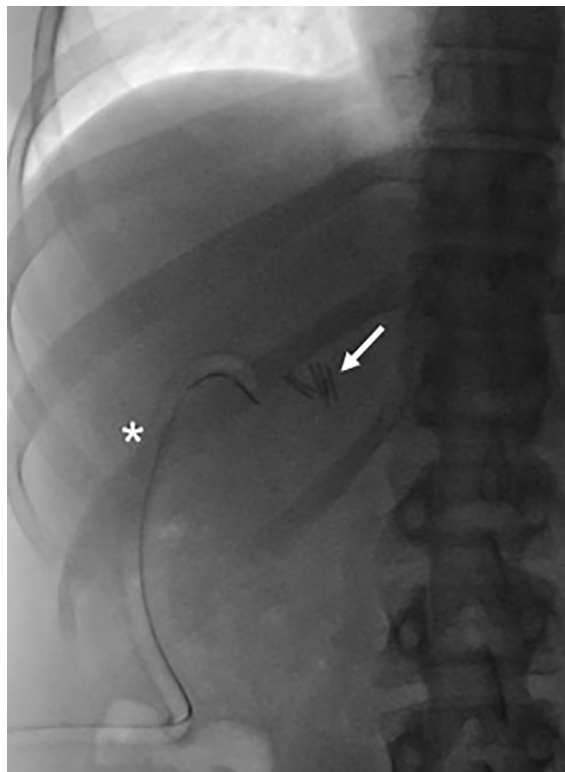
The interventional radiologist is involved both in diagnosis and treatment of patients affected by post-surgical biliary tract stenosis or biliary leakage. The etiology of benign strictures of the biliary tract is: iatrogenic, outcome of sclerosing cholangitis, liver transplantation or chronic pancreatitis [1].

<sup>☆</sup> Conflict of interest: The authors have declared that no competing interests exist.

\* Corresponding author.

E-mail addresses: [andreapaladini1988@gmail.com](mailto:andreapaladini1988@gmail.com) (P. Andrea), [antonio.borzelli@libero.it](mailto:antonio.borzelli@libero.it) (B. Antonio), [luigipaladini2006@libero.it](mailto:luigipaladini2006@libero.it) (P. Luigi), [g.frauenfelder@unicampus.it](mailto:g.frauenfelder@unicampus.it) (F. Giulia), [raffaellaniola@tiscali.it](mailto:raffaellaniola@tiscali.it) (N. Raffaella).  
<https://doi.org/10.1016/j.radcr.2018.04.029>

1930-0433/© 2018 The Authors. Published by Elsevier Inc. on behalf of University of Washington. This is an open access article under the CC BY-NC-ND license. (<http://creativecommons.org/licenses/by-nc-nd/4.0/>)



**Fig. 1** – The abdomen x-ray before treatment showed the presence of a surgical drainage (asterisk) tube and surgical clips in right hypochondrium. Two clips (arrow) caused iatrogenic and pathological occlusion of the common bile duct.

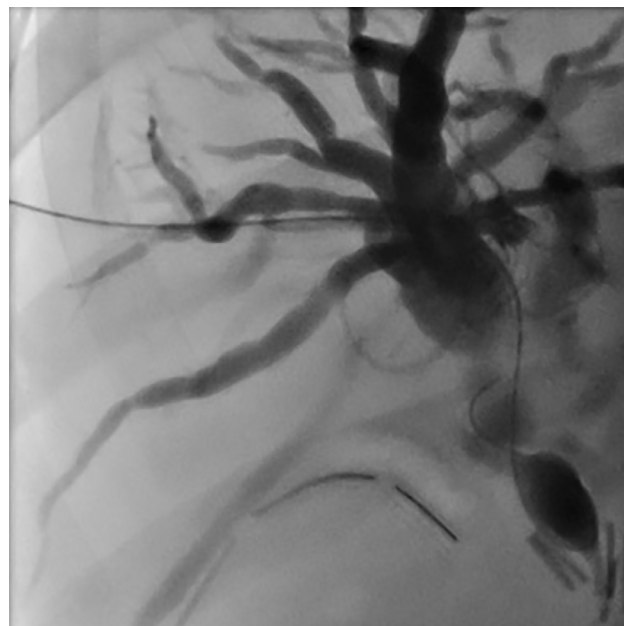
The last 3 causes, however, are less common and do not need an interventional radiological treatment.

Historically, the incidence of iatrogenic lesions in the biliary ducts increased significantly after the introduction of laparoscopic procedures, mainly laparoscopic cholecystectomy [2]. In literature, the complication rate ranges between 0% and 4% with an average of 0.5%. In 75% of cases, the lesions occur in correspondence of the main ducts and the main confluences; in 25% of cases the cystic duct or minor ducts are involved.

The main causes of iatrogenic lesions are [3]: poor visualization of the hepatic pedicle, anatomical variants of the gallbladder, technical error.

## Case

A 39-year-old woman was referred to our center for abdominal pain, fever, and severe jaundice (bilirubin level: 15 mg/dl) 7 days after laparoscopic cholecystectomy for lithiasis. Any intraprocedural complication was documented during surgery. As first level diagnostic imaging, the radiologist performed a liver ultrasound (US) which revealed dilatation of intrahepatic bile ducts and free fluid collection in the abdomen. US-guided fluid drainage was conducted, resulting in biliary fluid collection; a percutaneous drainage was so positioned.

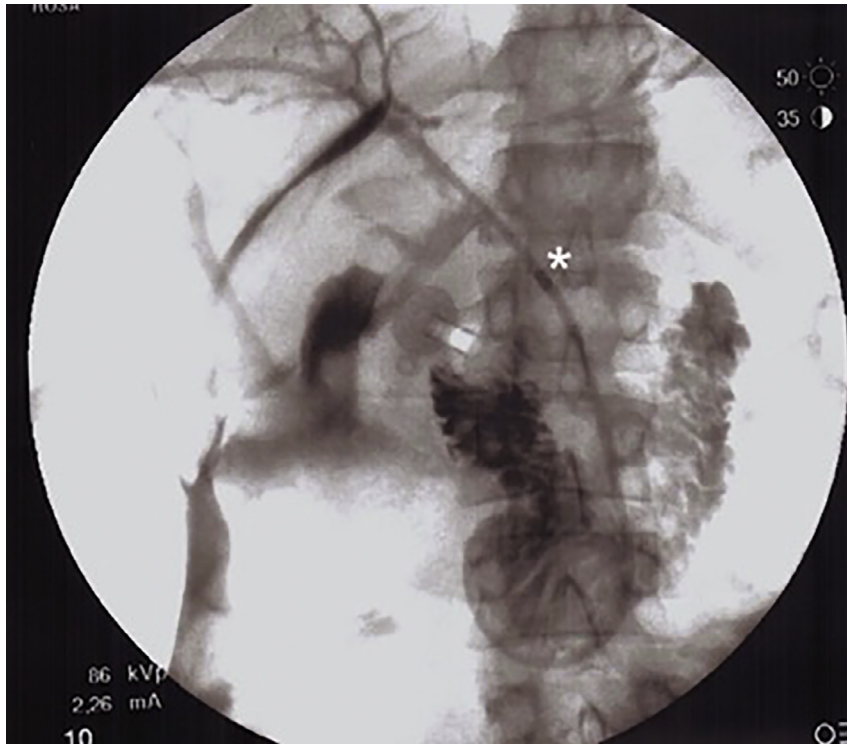


**Fig. 2** – Intrahepatic biliary hemisystems were dilated with complete occlusion of the common bile duct. At the cholangiogram passage of contrast medium in duodenum was not appreciated. The interventional radiologist tried unsuccessfully to overcome the iatrogenic occlusion (surgical clips: arrow) with a 0.018-inch hydrophilic wire. As a consequence, the interventional radiologist positioned an external biliary drainage (8.5 Fr).

The radiologist decided to perform a magnetic resonance cholangiography which revealed severe enlargement of the intrahepatic biliary tree and occlusion of the middle segment of common bile duct caused by 2 surgical clips, this documented an accidental surgical clipping of the common bile duct after laparoscopic cholecystectomy.

A percutaneous drainage of the biliary system was so agreed.

Before treatment, abdomen x-ray confirmed the presence of surgical clips in right hypochondrium (Fig. 1). The right bile ducts were accessed from the midaxillary line under fluoroscopic guidance. The entry site was at the level of the inferior portion of the right hepatic lobe and along the superior margin of the rib in order to reduce complications risk, as pleural involvement or intercostal neurovascular injury. Left bile ducts were spared because right and left biliary main ducts were in physiological communication. A micropuncture kit (Neff Percutaneous Access Set, Cook Medical) was adopted to access the right biliary ducts; under fluoroscopic guidance, a micropuncture 21 gauge needle was advanced into the liver and slowly withdrawn, while iodinated contrast agent was slowly injected to opacify the bile duct. When bile ducts were evident, a 0.018-inch wire was advanced, after the wire was passed to a secure position in the biliary tree, the needle was removed and a coaxial system was passed over the wire; the 2 inner components (wire and inner coaxial dilator) were removed to accept the larger wire (0.035 inches). The interventional radiologist tried to overcross the obstruction, but the surgical clip



**Fig. 3** – In the hybrid-room, the interventional radiologist is able to advance a wire in the duodenum after the removal of clips. Then an internal-external biliary drainage catheter (8.5 Fr) was positioned (asterisk).

precluded the passage of the 0.035-inch guidewire into the common bile duct. So an external biliary drainage (Fig. 2) was left in situ for a few days to decompress the biliary system.

Four days later, another approach was attempted by combining percutaneous and surgical strategies: through video-laparoscopic approach, the surgeon removed the surgical clips from the common bile duct. Meanwhile, the interventional radiologist performed a percutaneous transhepatic cholangiography (PTC) through the external biliary drainage which documented a biliary leakage from the common bile duct, caused by removal of clips.

As a consequence, the interventional radiologist decided to exchange the external biliary drainage with an internal-external biliary drainage. A hydrophilic guidewire (0.035 inch, Glidewire, Terumo, Japan) was advanced to the duodenum and then exchanged with a stiff one (Amplatz Super Stiff, Boston Scientific). A 8 Fr internal-external biliary drainage catheter (Flexima, Boston Scientific) was positioned (Fig. 3) for 21 days. Meanwhile, the interventional radiologist controlled the biliary leakage by transhepatic cholangiography (Fig. 4), whereas the surgeon checked up patient with clinical examination, blood cell count, and bilirubin level once per week.

Sixty days after internal-external biliary drainage placement, the patient did not show any significant improvement from a clinical and laboratory point of view (persistence of high bilirubin level: > 8 mg/dl). Moreover, there was evidence of persistence of biliary leakage in the PTC (Fig. 5). As a consequence, the interventional radiologist together with the surgeon decided to position a fully covered stent graft (10 × 80

mm, Wallflex, Boston Scientific) (Fig. 6A and B) to definitely resolve the leakage.

This choice was supported by the idea to subsequently remove the graft through an endoscopic approach.

However, in the following magnetic resonance imaging (MRI) performed 4 weeks after the last procedure, there was no evidence of stent-graft in common bile duct, spontaneously migrated in the duodenum and expelled by the patient, unconsciously.

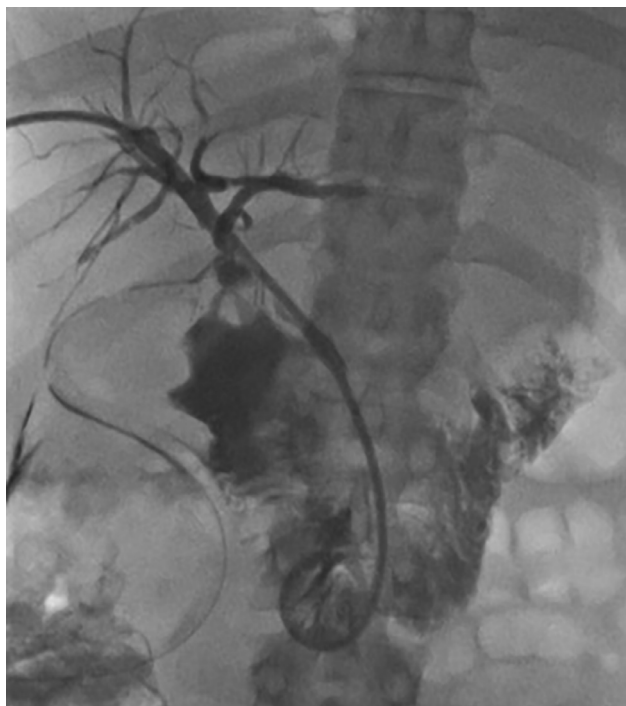
The interventional radiologist performed abdomen US that did not document biliary dilatation. Furthermore, there was an improvement from a clinical and laboratory point of view (bilirubin level < 2 mg/dl). The following abdominal MRI confirmed the resolution of the biliary leakage without dilatation of the biliary system (Fig. 7).

The surgical-radiological combined treatment permitted not only the reconstruction of the bilious tree from an anatomical and physiological point of view, but also avoided major surgery (such as biliary-jejunal anastomosis) in a young patient.

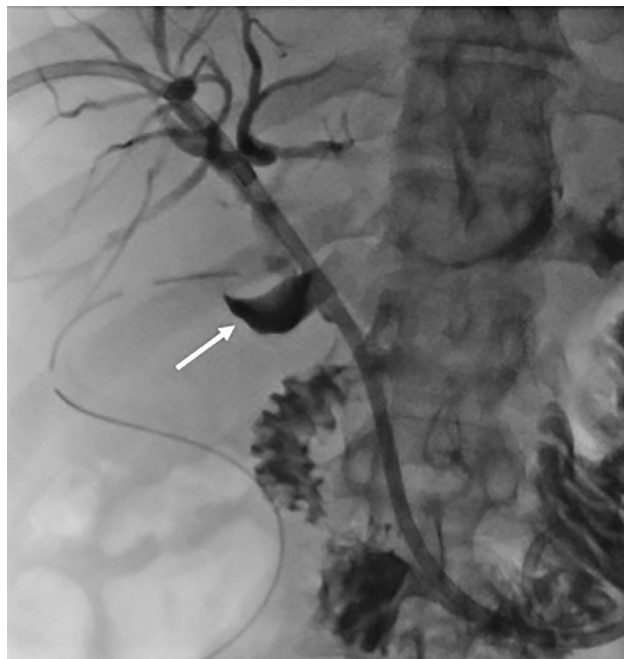## Discussion

Biliary leakages and/or bile duct strictures are challenging complications of the cholecystectomy treated with laparoscopic approach [4] or biliary-enteric anastomosis.

Biliary strictures often require a surgical reconstruction with severe perioperative morbidity and mortality and good but not excellent long term outcomes.



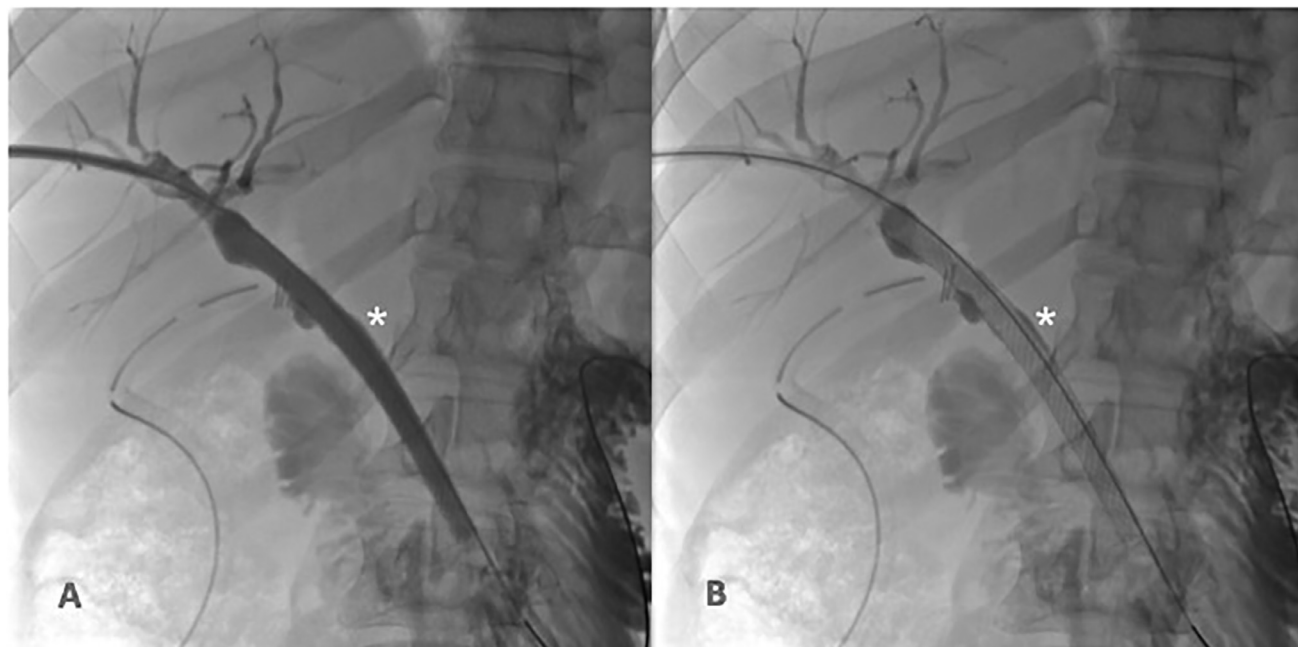
**Fig. 4 – Cholangiographic control after placement of internal-external biliary drainage (10 Fr).**



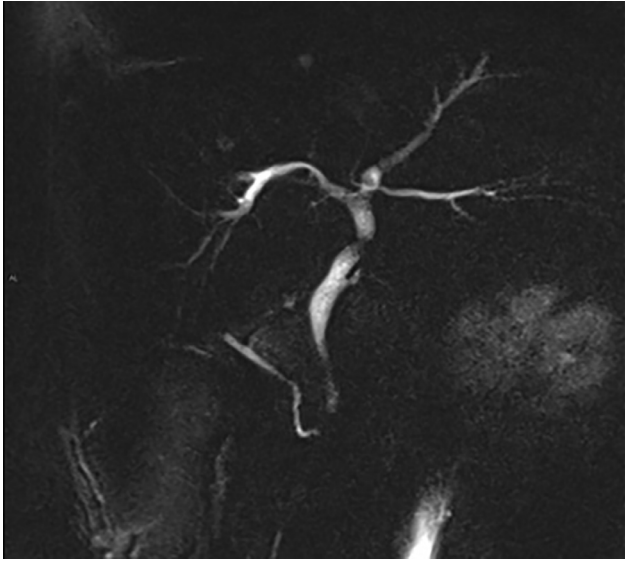
**Fig. 5 – The cholangiographic control performed 3 weeks after surgery, documented the presence of visible leakage in the main biliary duct (arrow: in the anatomical site of the preexisting surgical clips).**

On the other hand, the correct treatment of biliary leakage depends on the type of injury. Management, indeed, may include endoscopic, percutaneous (percutaneous biliary drainage: PTC), and open surgical interventions [5].

The successful management depends on injury type, timing of its diagnosis [6], patient clinical condition and availability of an experienced interventional radiologist, as well as an hepatobiliary surgeon.



**Fig. 6 – (A and B) Sixty days after surgery, the interventional radiologist together with the surgeon, decided to position a fully-covered stent-graft (asterisk: 10 x 80 mm Wallflex Boston Scientific).**



**Fig. 7 – In the given magnetic resonance imaging, there was no evidence of biliary leak and the complete resolution of radiological panel.**

Radiologists play a key role in diagnosis and treatment because biliary injuries could often become evident only in the postsurgery days [7]. Signs and symptoms of biliary leakage or strictures are often nonspecific (abdominal pain, nausea, and anorexia) and can cause delays in diagnosis and treatment.

Different imaging modalities could help the surgeon and interventional radiologist in treatment planning. MRI is the gold standard imaging modality for diagnosis of biliary injuries, because it can provide an excellent delineation of the biliary anatomy and pathology. Moreover, dynamic-MRCP with a hepatocyte-selective contrast agent could detect small biliary leakage, accuracy is close to 100%, exact location of leakage can be determined in 79%-85% of cases [8].

On the other hand, computed tomography and US are able to detect fluid collections or biliary duct dilatations, these are the most common imaging examinations for patients affected by jaundice and abdominal pain.

Endoscopic retrograde cholangiopancreatography has a limited utility because it does not allow evaluation of the proximal biliary tree.

Initial clinical management of patients affected by bile duct injuries is focused on stabilizing the patient and obtaining a complete imaging examination with cholangiographic characterization. Magnetic resonance cholangiography is the gold standard for complete characterization (type and extent) of biliary strictures or leakage [9].

The absence of stenosis or obstruction avoid surgery and permits an endoscopic therapy. In case of complete ductal ligation or biliary transection, PTC with external biliary drainage placement is the first step to obtain biliary decompression. After a technically successful treatment, if patient remains asymptomatic and laboratory test results are not suggestive of pathology, the biliary drainage could be removed. Biliary stent placement is the first-line nonsurgical treatment in patients affected by common duct lesion. Long-term outcomes after

sole percutaneous treatment have been reported in 33%-90% of cases [10].

In literature there are no definitive guidelines detailing technical aspects of percutaneous biliary procedures (such as: duration of biliary drainage, frequency of balloon dilations in case of strictures, type of balloon or use of biliary stent) and, as a consequence, success rates vary a lot among authors (27%-89%) [10].

In conclusion, interventional radiology is an effective alternative treatment strategy to surgical reconstruction in selected patients; however in case of injuries not suitable for percutaneous techniques, surgical approach is required [11]. Finally, Roux-en-Y hepatic – jejunostomy is the preferred procedure for major bile duct injuries. In literature, many authors reported excellent long-term outcomes with long-term patency in more than 90% of patients [7].

## Conclusion

Iatrogenic bile duct injuries are relevant technical and clinical issues requiring a multidisciplinary approach for their optimal management.

Imaging is the key for characterizing the injury and planning the proper percutaneous and surgical treatments. At the beginning, percutaneous drainage of fluid collections and re-establishment of normal biliary drainage is crucial to achieve a successful outcome. Percutaneous and endoscopic procedures allow definitive treatment in selected patients and may represent a valuable alternative to conventional surgery.

## Compliance with ethical standards

*Research involving human participants:* All procedures performed in studies involving human participants were in accordance with the ethical standards of the institutional and national research committee and with the 1964 Helsinki declaration and its later amendments or comparable ethical standards.

*Informed consent:* Informed consent was obtained from all individual participants included in the study.

## REFERENCES

- [1] Stampfl U, Hackert T, Radeleff B, Sommer CM, Stampfl S, Werner J. Percutaneous management of postoperative bile leaks after upper gastrointestinal surgery. *Cardiovasc Interventional Radiol* 2011;34:808–15.
- [2] Misra S, Melton GB, Geschwind JF, Venbrux AC, Cameron JL, Lillemoe KD. Percutaneous management of bile duct strictures and injuries associated with laparoscopic cholecystectomy: a decade of experience. *J Am Coll Surg* 2003;198(2) February 2004.
- [3] Popat B, Thakkar D, Deshmukh H, Rathod K. “Percutaneous transhepatic biliary drainage in the management of post-surgical biliary leaks”; *Indian J Surg* doi:10.1007/s12262-015-1418-1.

- 
- [4] Saad WEA. Percutaneous management of postoperative anastomotic biliary strictures. *Tech Vasc Interventional Rad* 2008;11(2):143–53.
- [5] de Jong EA, Moelker A, Leertouwer T, Spronk S, Van Dijk M, van Eijck CHJ. Percutaneous transhepatic biliary drainage in patients with postsurgical bile leakage and nondilated intrahepatic bile ducts. *Dig Surg* 2013;30:444–50.
- [6] Kapoor V.K. “Bile duct injury repair: earlier is not better”; *Front Med*. doi:10.1007/s11684-015-0418-7.
- [7] Thomson CM, Saad NE, Quazi RR, Darcy MD, Picus DD, Menias CO. Management of iatrogenic bile duct injuries: role of the interventional radiologist. *RadioGraphics* 2013;33:117–34.
- [8] Nikpour AM, Knebel R, Cheng D. Diagnosis and management of postoperative biliary leaks. *Semin Interventional Radiol* 2016;33:307–12.
- [9] Ibrarullah M, Sankar S, Sreenivasan K, Gavini S.R.K. “Management of bile duct injury at various stages of presentation: experience from a tertiary care centre”; *Indian J Surg* doi:10.1007/s12262-012-0722-2.
- [10] May K, Hunold P. Leakage of hepaticojejunal anastomosis: radiological interventional therapy. *Visc Med* 2017;33:192–6.
- [11] Corvino F, Centore L, Soreca E, Corvino A, Farbo V, Bencivenga A. Percutaneous “Y” biliary stent placement in palliative treatment of type 4 malignant biliar stricture. *J Gastrointestin Oncol* 2015;7(2):255–61.