

Case Report

A case of acute subdural hematoma due to bleeding from metastatic chondrosarcoma of the skull

Kenzo Kosugi, Satoshi Takahashi, Hikaru Sasaki, Ryota Tamura, Kentaro Ohara¹, Kazunari YoshidaDepartments of Neurosurgery, ¹Pathology, Keio University School of Medicine, Shinjuku, Tokyo, JapanE-mail: *Kenzo Kosugi - kensan03977@yahoo.co.jp; Satoshi Takahashi - satoshi710@mac.com; Hikaru Sasaki - hsasaki@a5.keio.jp;
Ryota Tamura - moltobello-r-610@hotmail.co.jp; Kentaro Ohara - k-ohara@a5.keio.jp; Kazunari Yoshida - kazrmky@z3.keio.jp

*Corresponding author

Received: 31 October 16 Accepted: 15 December 16 Published: 20 February 17

Abstract

Background: Intra or peritumoral hemorrhage of brain and skull tumors sometimes presents as stroke. Skull metastasis of chondrosarcoma is relatively rare, and furthermore, a case of intratumoural hemorrhage of skull metastasis of chondrosarcoma has not been reported.

Case Description: A 73-year-old man underwent right lower leg amputation in the past because of chondrosarcoma and was operated for a skull metastasis. He presented with a sudden headache, and head computed tomography revealed a right acute subdural hematoma (SDH) adjacent to the recurrent skull metastatic tumor. The removal of the SDH and tumor resection were performed emergently. The intraoperative findings included metastatic invasion beyond the dura mater to as deep as the subdural space, and the histological diagnosis was metastatic chondrosarcoma. His postoperative course was uneventful.

Conclusion: In the event of subdural invasion of a metastatic lesion, intratumoral hemorrhage may induce acute SDH, as in the present case. Similar to our case, most previous reports of intracranial chondrosarcoma hemorrhage have had an unclear etiology. Despite the rarity of this event, a patient with a history of malignancy presenting with nontraumatic acute SDH should be examined for the intratumoral hemorrhage of skull metastasis in the differential diagnosis.

Key Words: Acute subdural hematoma, chondrosarcoma, intratumoral hemorrhage, skull metastasis

Access this article online

Website:www.surgicalneurologyint.com**DOI:**

10.4103/2152-7806.200582

Quick Response Code:

INTRODUCTION

Cases of skull metastases of chondrosarcoma and of subdural hematomas (SDHs) caused by the intratumoral hemorrhage of skull metastases of malignant tumors are relatively rare. Because intracerebral hemorrhage in meningioma is also rare, with a frequency of 1.3%,^[8] there have been 6 reported cases of primary intracranial chondrosarcoma presenting with cranial hemorrhage.^[1-4,10,11] However, chondrosarcoma of the skull itself is rare.

This is an open access article distributed under the terms of the Creative Commons Attribution-NonCommercial-ShareAlike 3.0 License, which allows others to remix, tweak, and build upon the work non-commercially, as long as the author is credited and the new creations are licensed under the identical terms.

For reprints contact: reprints@medknow.com

How to cite this article: Kosugi K, Takahashi S, Sasaki H, Tamura R, Ohara K, Yoshida K. A case of acute subdural hematoma due to bleeding from metastatic chondrosarcoma of the skull. *Surg Neurol Int* 2017;8:23.

<http://surgicalneurologyint.com/A-case-of-acute-subdural-hematoma-due-to-bleeding-from-metastatic-chondrosarcoma-of-the-skull/>

CASE DESCRIPTION

A 73-year-old man underwent right lower leg amputation 16 years earlier because of chondrosarcoma. He previously had surgeries for lung and liver metastases of the lesion. One year ago, he underwent extended resection and subsequent cranioplasty for a skull metastasis. Because of the recurrence of the skull metastasis, another surgical resection was planned [Figure 1a]. However, he came to our outpatient clinic 1 day before his planned admission with a sudden headache. He had no history of head trauma and did not take any antiplatelet agents. Head computed tomography (CT) revealed a right acute SDH adjacent to the tumor [Figure 1b]. He underwent conservative initial management because he had no motor weakness and was neurologically intact other than a headache on admission. However, his headache suddenly worsened the next day, with associated left-sided weakness. Head CT showed an increase in hematoma size and exacerbation of the midline shift [Figure 1c]. Therefore, the removal of the SDH and tumor resection were performed emergently, with subsequent improvement of headache and motor weakness [Figure 1d]. The intraoperative findings included metastatic invasion beyond the dura mater to as deep as the subdural space, and intratumoral hemorrhage that appeared to rupture in the direction of the subdural space. There was no apparent adhesion of the lesion to normal brain tissue [Figure 2a]. The histological diagnosis was metastatic chondrosarcoma [Figure 2b]. His postoperative course was uneventful, and he was discharged from our hospital 10 days after surgery. One

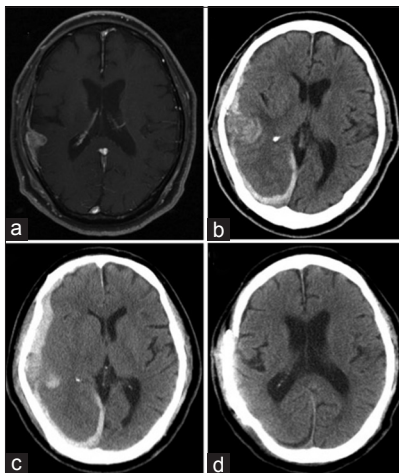


Figure 1: (a) A gadolinium-enhanced T1-weighted magnetic resonance (Gd-T1WI MR) image taken before scheduled surgery revealed the contrasted mass lesion on the left calvarium adjacent to normal brain with subdural invasion. (b) Head computed tomography (CT) taken on the day of admission revealed right-sided acute subdural hematoma (SDH). (c) Head CT performed before the urgent surgery revealed acute SDH with midline shift that indicated intratumoral hemorrhage of the calvarial metastasis. (d) Postoperative head CT showed the resected calvarial tumor and improvement of the midline shift

month later, the resection of his residual tumor and cranioplasty were performed.

DISCUSSION

According to the brain tumor registry of Japan, the frequency of malignant calvarial metastasis is approximately 2% among the 14000 recorded metastatic brain tumors.^[12] Furthermore, brain tumor metastasis from primary soft tissue malignancy has reportedly occurred in only 0.6% of 14000 cases.^[11] Only one case of calvarial metastasis of chondrosarcoma has ever been reported.^[6]

To date, there have been 6 reported cases of primary intracranial chondrosarcoma presenting with cranial hemorrhage.^[1-4,10,11] However, this is the first ever case report of a patient in whom a skull metastasis of chondrosarcoma presented as acute SDH. Acute SDH has reportedly developed from several other types of malignant lesions.^[7] In the event of subdural invasion of a metastatic lesion, intratumoral hemorrhage may induce acute SDH, as in the present case. Hemorrhagic events are commonly observed in malignant brain tumors, such as high-grade gliomas and metastatic tumors. The etiology of hemorrhages has been attributed to factors including hypervascularity, abundant neovascular proliferation, and necrosis.^[13] Chondrosarcomas vary widely in their vascularity, and there is a close association between vascularity and the grade of malignancy.^[9] Histopathologic analysis of this case revealed a grade 2 malignancy with normal vascularity. Other than normal vascularity, no other potential causes of intratumoral hemorrhage such as vascular proliferation or degenerative blood vessel changes were noted. Similar to our case, most previous reports of intracranial chondrosarcoma hemorrhage have had an unclear etiology. On the other hand, Jason reported an extracranial bleeding event in which of a patient with

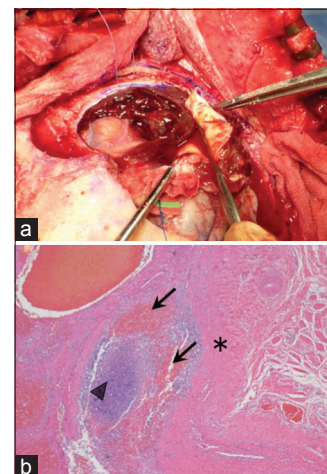


Figure 2: (a) Intraoperative findings included subdural tumor progression and SDH adjacent to the tumor. (b) Low-power magnification of a hematoxylin and eosin-stained section. Tumor (arrow head) invasion to the dura mater (*) and hemorrhage (arrow) were observed

a chest wall chondrosarcoma suffered a hemothorax.^[5] Intratumoral hemorrhage of chondrosarcomas may not be rare. However, in the uncommon situation where chondrosarcoma development occurs in sites with enough space for hemorrhagic to spread expansion, such as the chest wall or calvarium, the symptoms of intratumoral hemorrhage may be more readily apparent.

Here, we report the first case of the calvarial metastasis of chondrosarcoma presenting with acute subdural hematoma. Despite the rarity of this event, a patient with a history of malignancy presenting with nontraumatic acute SDH should be examined for the intratumoral hemorrhage of skull metastasis in the differential diagnosis.

Financial support and sponsorship

Nil.

Conflicts of interest

There are no conflicts of interest.

REFERENCES

1. Fukuchi M, Fushimi S, Yoneya M, Hirayama A, Mineura K, Kowada M, *et al.* Chondrosarcoma of the skull base associated with fatal intratumoral hemorrhage: Report of an autopsy case and review of the literature. *No Shinkei Geka* 1996;24:175-80.
2. Gallia GL, Binder ZA, Schwarz J, Moriarity JL, Weingart JD. Skull base chondrosarcoma presenting with hemorrhage. *Can J Neurol Sci* 2009;36:774-5.
3. Harada K, Nakahara I, Hayashi J, Tanaka M, Akiyama Y, Iwamuro Y, *et al.* Chondrosarcoma of the clivus presenting with intratumoral hemorrhage: Case report. *J Neurooncol* 2006;77:221-3.
4. Jumani MI, Channa R, Zafar SN, Enam SA. Pontine haemorrhage due to chondrosarcoma of the skull base. *J Coll Physicians Surg Pak* 2010;20:692-4.
5. Karlawish JH, Smith GW, Gabrielson EW, Liu MC. Spontaneous hemothorax caused by a chest wall chondrosarcoma. *Ann Thorac Surg* 1995;59:231-3.
6. Kawano T, Hamada J, Morioka M, Mihara Y, Ishimaru Y, Kaku M, *et al.* Skull metastasis from clear cell chondrosarcoma, case report. *Neurol Med Chir* 2005;45:367-70.
7. Kumar PM, Manisha M. Epidural hematoma secondary to solitary skull metastasis from an ovarian cancer. *Asian J Neurosurg* 2014;9:112-4.
8. Kuzeyli K, Cakir E, Usul H, Karaarslan G, Yazar U, Baykal S, *et al.* Intratumoral haemorrhage: A clinical study. *J Clin Neurosci* 2004;11:490-2.
9. Lagergren C, Lindbom A, Soderberg G. The blood vessels of chondrosarcoma. *Acta radiol* 1961;55:321-8.
10. Little A, Chung C, Perez-Ordóñez B, Mikulis D, Valiante TA. High-grade intracranial chondrosarcoma presenting with haemorrhage. *J Clin Neurosci* 2013;20:1457-60.
11. Ohshige H, Kasai H, Imahori T, Ryu T, Azuma K, Yoshimura K, *et al.* A case of petrous bone myxoid chondrosarcoma associated with cerebellar hemorrhage. *Brain Tumor Pathol* 2005;22:41-4.
12. Report of brain tumor registry of japan (1984-2000) 12th edition. *Neurol Med Chir* 2009;49:22-5.
13. Shibusaki S, Kimura T, Sasaki H, Fujiwara H, Akiyama T, Ueno M, *et al.* Hemorrhagic onset of cerebellar pilocytic astrocytoma in an adult: A case report and review of the literature implying a possible relation of degenerative vascular changes to the massive intratumoral hemorrhage. *Brain Tumor Pathol* 2012;29:96-102.