

Retinal nerve fiber layer characteristics in patients with spontaneous intracranial hypotension: a retrospective case series

Li-Guo Feng¹, Ying Chen¹, Fei-Fang He² and Yu-Feng Yao¹ 

Abstract

Objective: To evaluate changes in retinal nerve fiber layer (RNFL) and macular thicknesses, included ganglion cell-inner plexiform layer (GCIPL) thickness, in patients with spontaneous intracranial hypotension (SIH).

Methods: This was a retrospective, nonrandom, observational case series study. Comprehensive ophthalmic examinations and systemic examinations were performed. Spectral domain optical coherence tomography angiography scanning was used to measure peripapillary RNFL thickness and macular volume.

Results: In total, 108 eyes in 54 patients with SIH were evaluated; these were compared with 108 eyes in 54 healthy controls. The mean ages were 38.2 ± 9.4 years (patients with SIH) and 38.9 ± 9.4 years (healthy controls). In both groups, 33 patients were women (61.1%). The peripapillary RNFL and GCIPL were thinner in patients with SIH than in healthy controls ($100.08 \pm 9.94 \mu\text{m}$ vs $104.83 \pm 8.35 \mu\text{m}$ and $81.46 \pm 5.67 \mu\text{m}$ vs $85.67 \pm 4.57 \mu\text{m}$, respectively). Among patients with SIH, the GCIPL was thinner in patients with visual field defects ($79.81 \pm 5.62 \mu\text{m}$ vs $82.39 \pm 5.12 \mu\text{m}$).

Conclusions: The RNFL and GCIPL were thinner in patients with SIH than in healthy controls. The GCIPL was thinner in eyes with visual field defects among patients with SIH.

¹Department of Ophthalmology, Sir Run Run Shaw Hospital, Zhejiang University School of Medicine, Hangzhou, China

²Department of Pain Management, Center for Intracranial Hypotension Management, Sir Run Run Shaw Hospital, Zhejiang University School of Medicine, Hangzhou, China

Corresponding author:

Yu-Feng Yao, Department of Ophthalmology, Sir Run Run Shaw Hospital, Zhejiang University School of Medicine, 3 Qingchun Road East, Hangzhou, Zhejiang 310016, China. Email: yaoyf@zju.edu.cn



Keywords

Spontaneous intracranial hypotension, retinal nerve fiber layer, ganglion cell-inner plexiform layer, optical coherence tomography angiography, visual field defect, retinal thickness, macular volume

Date received: 17 March 2021; accepted: 15 September 2021

Introduction

Spontaneous intracranial hypotension (SIH) is an increasingly common public health problem in the past three decades; it primarily involves a spontaneous spinal cerebrospinal fluid leak.¹ Affected patients have various ocular symptoms, such as diplopia, transient visual obscurations, blurred vision, nystagmus, photophobia, and peripheral visual field depression.^{2,3} However, the mechanisms of these visual disturbances are unclear. Multiple studies have demonstrated that lower intracranial pressure is associated with the development of open-angle glaucoma, which is characterized by retinal nerve fiber layer (RNFL) thinning and visual field loss.⁴⁻⁷ Pressure differences across the lamina cribrosa in patients with SIH have been extensively investigated.⁸ Furthermore, optical coherence tomography (OCT) has been used to examine the relationships between eye changes and central nervous system diseases; these include RNFL features in patients with multiple sclerosis, neuromyelitis optica, Alzheimer's disease, and stiff-person syndrome.⁹⁻¹² Because the lamina cribrosa mediates the communication of pressure between intraocular and intracranial sites, it is important to investigate potential RNFL alterations in patients with SIH. Accordingly, we performed this study to observe RNFL characteristics in patients with SIH.

Materials and methods

Participants

This retrospective, nonrandom, single-center, observational case series included patients

who underwent ocular evaluations between January 2019 and December 2020 at the Sir Run Shaw Hospital of Zhejiang University. Patients with the diagnosis of SIH were included, based on the diagnostic criteria in the International Classification of Headache Disorders (reviewed by Schievink).¹ These criteria included worsened diffuse or dull headache within 15 minutes after sitting or standing; pachymeningeal enhancement on magnetic resonance imaging, cerebrospinal fluid leakage on conventional myelography, or opening pressure <60 mmH₂O in sitting position; and no history of dural puncture. Patients were excluded if they had other ocular diseases (e.g., idiopathic optic neuritis, ischemic optic neuropathy, uveitis, retinal vessel diseases, macular pucker, macular hole, and macular degeneration) or other central nervous system diseases. Given that intracranial pressure might affect both eyes, and based on observation methods in previous published papers,^{12,13} both eyes of each patient were included. Healthy controls were recruited from among normal healthy hospital examinees (i.e., healthy people who visited our hospital for routine examinations); no healthy controls had other ocular or central nervous diseases. The study protocol was approved by the Ethics Committee of Sir Run Run Shaw hospital (approval no. 20200716265). This study complied with the tenets of the Declaration of Helsinki. Written informed consent for inclusion in the study was obtained from all participants.

Examinations

Participants underwent spectral domain OCT angiography (Model 5000, Carl Zeiss Meditec, Dublin, CA, USA) scanning

without pupillary dilation, as previously described.¹⁴ For patients with SIH, OCT examinations were performed within 24 hours after SIH diagnosis. No participants received any ocular or systemic medications before their OCT examinations. All OCT examinations were performed by a trained operator blinded to the participants' diagnoses; images (i.e., cross-sectional tomograms of the retina) were acquired during those examinations. The scanning protocol comprised a circular 3.4-mm scan centered on the optic nerve head for 3.5 s; the scan density was 512×128 pixels. Each eye was scanned at least two times. Only images with signal strength of 6 to 10 were retained; images with extensive eye movements, large retinal vessel truncation, and blinking-related artifacts were also discarded. RNFL thickness measurements were recorded using a circular 3.4-mm peripapillary map. For all eyes in the study, the mean RNFL thickness was recorded for 360° around the optic disc, as well as for superior, inferior, nasal, and temporal quadrants around the optic nerve head; additionally, the vertical cup-to-disc ratio was recorded. The macular cube mode was used to scan the macula over a 6-mm^2 area centered on the fovea; data were acquired from a three-dimensional scan of 512×128 pixels. The fovea, cube mean; and ganglion cell-inner plexiform layer (GCIPL) thicknesses were recorded for all eyes in the study. To ensure OCT data accuracy, each scan was individually reviewed by two recorders who were blinded to the participants' diagnoses. OCT parameters were calculated automatically by software within the scanning equipment.

Automated perimetry examinations were performed in patients who could tolerate the 10-minute duration in sitting position; perimetry was not performed in patients who could not tolerate this duration of sitting. A reliable standard automated perimetry test per eye was performed using a Humphrey Field analyzer (Zeiss Humphrey

Systems, Dublin, CA, USA) with the SITA Standard 30–2 strategy, if patients could tolerate the full examination. If fixation losses were $>15\%$ and false-positive or false-negative rates were $>30\%$, the corresponding visual field test results were discarded. A visual field defect was defined as a glaucoma hemifield test outside normal limits or a pattern standard deviation <0.05 . The pattern of visual field defects was classified in accordance with the Ocular Hypertension Treatment Study protocol, which included peripheral circumferential depression, partial peripheral depression, central scotoma, and arcuate defect.¹⁵ Best corrected visual acuity was evaluated by the standard logarithmic visual acuity chart. Intraocular pressures in all eyes were measured via non-contact tonometry during each visit; the mean value of three measurements was recorded for each eye.

Statistical analyses

Statistical analyses were performed using SPSS (SPSS for Windows, version 22.0; IBM Corp., Armonk, NY, USA). Continuous data are presented as means and standard deviations; categorical data are presented as frequencies (percentages). Demographic characteristics were compared using Student's *t*-test (age and blood pressure) or the chi-squared test (sex). Generalized estimating equation analysis, with adjustments for within-patient inter-eye correlations, was performed to assess linear correlations between continuous variables (i.e., peripapillary RNFL and macular thicknesses). Univariable generalized linear models were adjusted for age and sex. Statistical significance was defined as $P < 0.05$.

Results

In total, 108 eyes in 54 patients with SIH were evaluated; 108 eyes in 54 healthy

controls were also evaluated. The demographic and clinical characteristics of patients with SIH and healthy controls are shown in Table 1. The measurement of intracranial pressure was recorded in 23 patients with SIH (37.26 ± 28.76 mmH₂O) (normal range: 80–180 mmH₂O); data were not available for other patients. Ocular symptoms are described in Table 1. The mean intraocular pressure was 15.06 ± 2.16 mmHg in 49 patients; data were not available for five patients with SIH. This mean intraocular pressure did not significantly differ from the value in healthy controls

(15.84 ± 2.52 mmHg), there was no significant statistical difference. Automatic static visual field examinations were completed in 88 eyes of 44 patients; a visual field defect was observed in 32 eyes (36.4%). These visual field defects mainly comprised peripheral circumferential depression (21 eyes, 23.7%), quadrant depression (seven eyes, 8.0%), central scotoma (two eyes, 2.3%) and arcuate defect (two eyes, 2.3%). One patient (1.9%) was diagnosed with normal-tension glaucoma, in accordance with European Glaucoma Society Terminology and guidelines for glaucoma.¹⁶

Table 1. Demographic and clinical characteristics of patients with spontaneous intracranial hypotension and healthy controls.

	Patients with SIH (n = 54)	HCS (n = 54)	P-value
Age (years)	38.2 ± 9.4	38.9 ± 9.4	0.6*
Sex (female)	33 (61.1)	33 (61.1)	0.58 [‡]
Duration (median, months)	1.95 ± 3.41	–	–
Ocular symptoms		–	–
Occasional blurred vision	7 (12.9)		
Transient visual obscurations	1 (1.9)		
Ocular soreness	15 (27.8)		
Occasional diplopia	2 (3.7)		
IOP (mmHg)	15.06 ± 2.16 (n = 49)	15.84 ± 2.52	0.08 [‡]
Spherical equivalent (D)	-1.89 ± 2.35	-1.52 ± 1.87	0.33 [‡]
Completed VF examination (eyes)	88 (81.5)	–	–
Abnormal VF (eyes)	32 (36.4)		
Normal VF (eyes)	65 (63.6)		
ICP (mmH ₂ O)	37.26 ± 28.76 (n = 23)	–	–
Arterial blood pressure (mmHg)			
Systolic	116.1 ± 14.8	121.0 ± 13.5	0.69*
Diastolic	72.4 ± 13.8	76.4 ± 9.7	0.06*
Systemic diseases		–	–
Hypertension	6 (11.1)		
Diabetes	2 (3.7)		
Leukopenia	1 (1.9)		
Hypercholesterolemia	1 (1.9)		
Chronic kidney disease	1 (1.9)		
Ventricular septal defect	1 (1.9)		
Hepatitis B	3 (5.6)		
CFLR	5 (9.3)		

Data are shown as mean \pm standard deviation or number of patients (%), except where indicated. *: Student's *t*-test; [‡]: chi-square test; [†]: generalized estimating equation.

Abbreviations: SIH, spontaneous intracranial hypotension; HCS, healthy controls; IOP, intraocular pressure; VF, visual field; ICP, intracranial pressure; CFLR, cerebrospinal fluid leak repair.

The mean peripapillary RNFL thicknesses were significantly different between patients with SIH and healthy controls ($P=0.004$, Table 2). The superior quadrant thicknesses also significantly differed between groups ($P=0.004$). The fovea, cube mean, and GCIPL were thinner in patients with SIH than in healthy controls ($P=0.015$, $P < 0.001$, and $P < 0.001$, respectively).

Patients with SIH were then grouped according to the presence or absence of visual field defects. Multivariable linear models revealed that the peripapillary RNFL and three sectors (inferior,

temporal, and nasal) were significantly thinner in patients with SIH who had visual field defects (Table 3); the GCIPL was also significantly thinner in these patients ($P=0.02$; Figure 1).

Discussion

This study revealed the clinical characteristics and RNFL changes in patients with SIH. The proportion of female patients and the mean age of patients with SIH were consistent with previous findings. Epidemiological investigations have revealed

Table 2. Comparison of retinal nerve fiber layer and macular thicknesses between patients with spontaneous intracranial hypotension and healthy controls.

	Patients with SIH	HCs	P-value [†]
Vertical cup-to-disc ratio	0.44 ± 0.19	0.44 ± 0.18	0.98
Peripapillary RNFL (μm)	100.08 ± 9.94	104.83 ± 8.35	0.004*
Superior (μm)	121.21 ± 18.37	129.31 ± 14.37	0.004*
Inferior (μm)	128.40 ± 20.53	134.31 ± 16.8	0.08
Temporal (μm)	80.11 ± 16.82	82.84 ± 15.91	0.88
Nasal (μm)	70.70 ± 12.07	72.90 ± 10.89	0.28
Fovea (μm)	244.53 ± 20.78	253.98 ± 20.44	0.015*
Cube mean (μm)	277.15 ± 12.15	286.38 ± 11.03	<0.001*
GCIPL (μm)	81.46 ± 5.67	85.67 ± 4.57	<0.001*

Data are shown as mean ± standard deviation. †: generalized estimating equation.

Abbreviations: SIH, spontaneous intracranial hypotension; HCs, healthy controls; RNFL, retinal nerve fiber layer; GCIPL, ganglion cell-inner plexiform layer.

Table 3. Comparisons of retinal nerve fiber layer and macular thicknesses between patients with and without visual field defects among patients who had spontaneous intracranial hypotension.

	Patients with VF defects	Patients without VF defects	P-value [§]
Vertical cup-to-disc ratio	0.47 ± 0.17	0.42 ± 0.17	0.53
Peripapillary RNFL (μm)	97.78 ± 10.6	101.66 ± 8.76	0.04*
Superior (μm)	119.81 ± 18.74	123.32 ± 15.75	0.19
Inferior (μm)	122.94 ± 20.42	132.23 ± 19.05	0.02*
Temporal (μm)	74.44 ± 17.82	81.84 ± 15.13	0.03*
Nasal (μm)	74.03 ± 16.26	69.29 ± 9.29	0.05*
Fovea (μm)	243.72 ± 22.29	242.86 ± 21.10	0.86
Cube mean (μm)	276.06 ± 13.92	278.04 ± 11.56	0.24
GCIPL (μm)	79.81 ± 5.62	82.39 ± 5.12	0.02*

Data are shown as mean ± standard deviation. §: Generalized linear model.

Abbreviations: VF, visual field; RNFL, retinal nerve fiber layer; GCIPL, ganglion cell-inner plexiform layer.

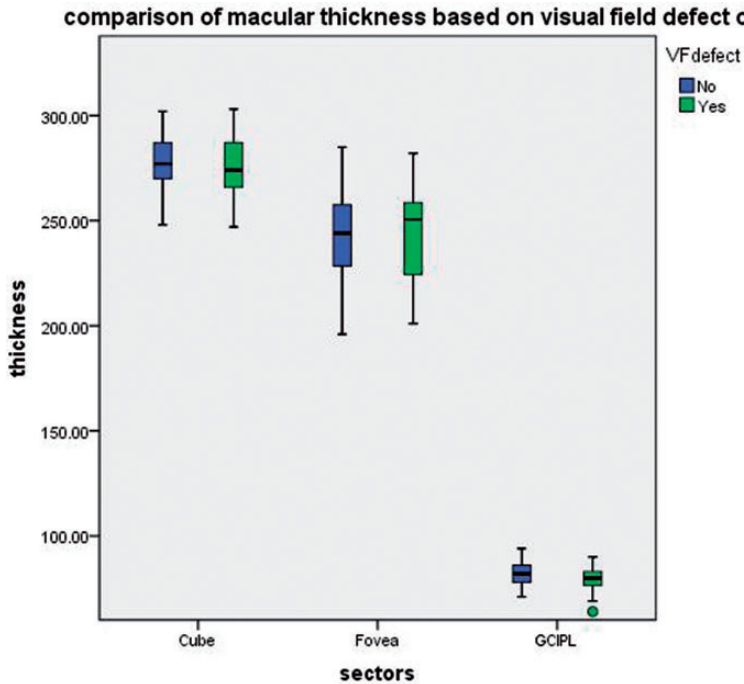


Figure 1. Comparisons of macular thicknesses between patients with and without VF defects among patients who had spontaneous intracranial hypotension. Although there were no significant differences in cube mean and fovea areas ($P = 0.24$ and $P = 0.86$, respectively), the GCIPL was thinner in patients with VF defects ($P = 0.02$), which suggested that the GCIPL layer might be involved in spontaneous intracranial hypotension. Note that the lone green circle represents the GCIPL value in the patient with normal-tension glaucoma. Blue bars, patients without VF defects; green bars/green circle, patients with VF defects. Abbreviations: GCIPL, ganglion cell-inner plexiform layer; VF, visual field.

that women are more susceptible to SIH, compared with men. The female-male ratio is approximately to 2:1; the onset of symptoms occurs around 40 years of age.^{17,18} In the present study, ocular symptoms in patients with SIH were similar to symptoms reported in previous studies. Two decades ago, Horton and Fishman first described neurovisual findings in patients with SIH; these findings included abducens nerve-related diplopia, blurred vision, and transient visual obscurations.² Groth and colleagues also described a patient with SIH who experienced slow progressive vision loss.¹⁹ Kurbanyan and Lessell described a patient with intracranial hypotension who developed binocular diplopia

because of abducens paresis.²⁰ Various visual field defects have also been reported. Groth et al described quadrant constriction and temporal defects,¹⁹ while Horton and Fishman reported binasal visual field defects and peripheral visual field depression.² In our study, visual field defects were present in more than one-third of patients; the most common visual field defect was peripheral circumferential depression. As mentioned above, the visual field findings in patients with SIH suggest that the retina or optic nerve structures might be affected. Therefore, we investigated RNFL changes via spectral domain OCT angiography.

The spectral domain OCT angiography findings in our study indicated thinning of

the peripapillary RNFL in patients with SIH. Previously, thinning of the temporal RNFL (determined via OCT) was described in a case report.¹⁹ Moreover, Yang et al identified bilateral progressive RNFL thinning in an experimental animal model involving monkeys with induced intracranial hypotension;²¹ this finding was consistent with our clinical results. The current and previous findings imply that lower intracranial pressure influences RNFL structures. In a population-based clinical study, Jonas et al observed that subfoveal choroid became thicker with increasing cerebrospinal fluid pressure; this indicated that changes in cerebrospinal fluid pressure influence eye physiology.²² Furthermore, Lee et al used swept-source OCT to observe dynamic changes in the lamina cribrosa among patients with intracranial pressure fluctuation; the lamina cribrosa showed posterior movement with decreasing intracranial pressure.²³ These findings illustrate the persistent need to clarify the effects of intracranial pressure on the lamina cribrosa or choroid in patients with SIH.

In the present study, normal-tension glaucoma was diagnosed in only one patient; this indicates a higher prevalence than in a previous report (1.0%) involving Chinese patients.²⁴ Multiple studies have focused on the relationship between open-angle glaucoma and intracranial pressure. For example, in a case-control clinical study, patients with primary open-angle glaucoma and normal-tension glaucoma exhibited lower intracranial pressure, compared with healthy controls.²⁵ Similarly, Ren et al reported that intracranial pressure was particularly low in patients with normal-tension glaucoma.⁵ Localized RNFL loss in patients with normal-tension glaucoma was observed nearly three decades ago.²⁶ Other studies have shown that optic disc rim loss usually occurs in superior and inferior areas among patients with early glaucoma.²⁷⁻²⁹

In the present study, we observed that the superior RNFL was thinner in patients with SIH than in healthy controls. The inferior RNFL was not significantly thinner in patients with SIH, although it tended to be thinner than in healthy controls. The characteristics of macular structures have extensively investigated using OCT in various glaucomatous and neuro-ophthalmological diseases; notably, significantly thinner GCIPL was observed in patients with glaucoma.^{27,30} Recently, Kim et al reported that assessment of sectoral macular superficial microvessel density combined with macular GCIPL thickness provides the greatest accuracy in the diagnosis of early stage normal-tension glaucoma.³¹ In stiff-person syndrome, Lambe and colleagues showed that GCIPL thickness was correlated with the number of body regions affected by the disease.¹² GCIPL thickness has also been analyzed in patients with optic neuritis; Xu et al found that GCIPL was highly sensitive for detecting prior instances of optic neuritis.³² Similar to the findings in previous studies, we showed that GCIPL thickness was lower in patients with SIH. Our results suggest that ganglion cells might be stressed in SIH. Further investigations are needed to fully elucidate the underlying pathogenesis; it might involve pressure-related mechanotransduction.³³

We compared RNFL thickness between patients with and without visual field defects. In contrast to the findings in patients with glaucomatous optic nerve lesions,³⁴ the peripapillary RNFL and three sectors (inferior, temporal, and nasal) were thinner among patients with visual field defects in the present study. Previously, Cheng and colleagues found that overall RNFL thickness was related to visual field loss in patients with multiple sclerosis-related optic neuritis.³⁵ We also found that GCIPL was thinner in patients with visual field defects, which suggests that the degree of ganglion cell involvement

might be related to visual field loss. Further research is needed to verify the retinal structure and function relationships in patients with SIH.

There were a few limitations in this study. First, the duration of SIH was short in affected patients, although the findings provide some useful insights. Long-term RNFL changes require investigation in future studies. Second, the pathogenesis underlying RNFL and GCIPL thinning in patients with SIH was not investigated in this study; it should receive greater attention in future research.

Conclusions

The RNFL and GCIPL were thinner in patients with SIH than in healthy controls. The GCIPL was thinner in eyes with visual field defects among patients with SIH.

Declaration of conflicting interest

The authors declare that there is no conflict of interest.

Funding

The authors disclosed receipt of the following financial support for the research, authorship and/or publication of this article: This study was supported by Foundation of Zhejiang Educational Committee (2016).

Author contributions

LGF and FFH collected data. LGF extracted and analyzed data. LGF drafted the manuscript. YFY and YC contributed to interpretation of data and critical revision of the manuscript.

ORCID iD

Yu-Feng Yao  <https://orcid.org/0000-0001-5699-3388>

References

1. Schievink WI. Spontaneous spinal cerebrospinal fluid leaks and intracranial hypotension. *JAMA* 2006; 295: 2286–2296.
2. Horton JC and Fishman RA. Neurovisual findings in the syndrome of spontaneous intracranial hypotension from dural cerebrospinal fluid leak. *Ophthalmology* 1994; 101: 244–251.
3. Ferrante E, Savino A, Brioschi A, et al. Transient oculomotor cranial nerves palsy in spontaneous intracranial hypotension. *J Neurosurg Sci* 1998; 42: 177–179.
4. Wang N, Xie X, Yang D, et al. Orbital cerebrospinal fluid space in glaucoma: the Beijing Intracranial and Intraocular Pressure (iCOP) Study. *Ophthalmology* 2012; 119: 2065–2073.e1.
5. Ren R, Jonas JB, Tian G, et al. Cerebrospinal fluid pressure in glaucoma: a prospective study. *Ophthalmology* 2010; 117: 259–266.
6. Berdahl JP, Allingham R and Johnson DH. Cerebrospinal fluid pressure is decreased in primary open-angle glaucoma. *Ophthalmology* 2008; 115: 763–768.
7. Pircher A, Montali M, Berberat J, et al. Relationship between the optic nerve sheath diameter and lumbar cerebrospinal fluid pressure in patients with normal tension glaucoma. *Eye (Lond)* 2017; 31: 1365–1372.
8. Jonas JB, Berenshtein E and Holbach L. Anatomic relationship between lamina cribrosa, intraocular space, and cerebrospinal fluid space. *Invest Ophthalmol Vis Sci* 2003; 44: 5189–5195.
9. Bock M, Brandt AU, Kuchenbecker J, et al. Impairment of contrast visual acuity as a functional correlate of retinal nerve fibre layer thinning and total macular volume reduction in multiple sclerosis. *Br J Ophthalmol* 2012; 96: 62–67.
10. Toosy AT, Mason DF and Miller DH. Optic neuritis. *Lancet Neurol* 2014; 13: 83–99.
11. Petzold A, De Boer JF, Schippling S, et al. Optical coherence tomography in multiple sclerosis: a systematic review and meta-analysis. *Lancet Neurol* 2010; 9: 921–932.
12. Lambe J, Rothman A, Prince J, et al. Retinal pathology occurs in stiff-person syndrome. *Neurology* 2020; 94: e2126–e2131.
13. Kirbas S, Turkyilmaz K, Anlar O, et al. Retinal nerve fiber layer thickness in patients with Alzheimer disease. *J Neuroophthalmol* 2013; 33: 58–61.

14. Garcia-Martin E, Pueyo V, Pinilla I, et al. Fourier-domain OCT in multiple sclerosis patients: reproducibility and ability to detect retinal nerve fiber layer atrophy. *Invest Ophthalmol Vis Sci* 2011; 52: 4124–4131.
15. Keltner JL, Johnson CA, Cello KE, et al. Classification of visual field abnormalities in the Ocular Hypertension Treatment Study. *Arch Ophthalmol* 2003; 121: 643–650.
16. European Glaucoma Society. *Terminology and guidelines for glaucoma*. Savona: Dogma Srl, 2008. <https://www.eugs.org/eng/guidelines.asp>
17. Schievink WI. Misdiagnosis of spontaneous intracranial hypotension. *Arch Neurol* 2003; 60: 1713–1718.
18. Chung SJ, Kim JS and Lee MC. Syndrome of cerebral spinal fluid hypovolemia: clinical and imaging features and outcome. *Neurology* 2000; 55: 1321–1327.
19. Groth SL, Lee MS, McKinney AM, et al. Optic neuropathy secondary to spontaneous intracranial hypotension (SIH) as related to experimental primate model. *Invest Ophthalmol Vis Sci* 2014; 55: 6175–6176.
20. Kurbanyan K and Lessell S. Intracranial hypotension and abducens palsy following upper spinal manipulation. *Br J Ophthalmol* 2007; 92: 153–155.
21. Yang D, Fu J, Hou R, et al. Optic neuropathy induced by experimentally reduced cerebrospinal fluid pressure in monkeys. *Invest Ophthalmol Vis Sci* 2014; 55: 3067–3073.
22. Jonas JB, Wang N, Wang YX, et al. Subfoveal choroidal thickness and cerebrospinal fluid pressure: the Beijing Eye Study 2011. *Invest Ophthalmol Vis Sci* 2014; 55: 1292–1298.
23. Lee WJ, Kim HJ, Park KH, et al. Dynamic change in optic nerve after intracranial pressure reduction in children. *Ophthalmology* 2017; 124: 1713–1715.
24. Zhao J, Solano MM, Oldenburg CE, et al. Prevalence of normal tension glaucoma in the Chinese population: a systematic review and meta-analysis. *Am J Ophthalmol* 2019; 199: 101–110.
25. Berdahl JP, Fautsch MP, Stinnett SS, et al. Intracranial pressure in primary open angle glaucoma, normal tension glaucoma, and ocular hypertension: a case-control study. *Invest Ophthalmol Vis Sci* 2008; 49: 5412–5418.
26. Yamazaki Y, Koide C, Miyazawa T, et al. Comparison of retinal nerve-fiber layer in high- and normal-tension glaucoma. *Graefe's Arch Clin Exp Ophthalmol* 1991; 229: 517–520.
27. Mwanza JC, Durbin MK, Budenz DL, et al. Glaucoma diagnostic accuracy of ganglion cell-inner plexiform layer thickness: comparison with nerve fiber layer and optic nerve head. *Ophthalmology* 2012; 119: 1151–1158.
28. Jonas JB, Fernandez MC and Naumann GO. Glaucomatous optic nerve atrophy in small discs with low cup-to-disc ratios. *Ophthalmology* 1990; 97: 1211–1215.
29. Zeyen TG and Caprioli J. Progression of disc and field damage in early glaucoma. *Arch Ophthalmol* 1993; 111: 62–65.
30. Tan O, Li G, Lu AT, et al. Mapping of macular substructures with optical coherence tomography for glaucoma diagnosis. *Ophthalmology* 2008; 115: 949–956.
31. Kim JS, Kim YK, Baek SU, et al. Topographic correlation between macular superficial microvessel density and ganglion cell-inner plexiform layer thickness in glaucoma-suspect and early normal-tension glaucoma. *Br J Ophthalmol* 2020; 104: 104–109.
32. Xu SC, Kardon RH, Leavitt JA, et al. Optical coherence tomography is highly sensitive in detecting prior optic neuritis. *Neurology* 2019; 92: e527–e535.
33. Agara A, Lia S, Agarwal N, et al. Retinal ganglion cell line apoptosis induced by hydrostatic pressure. *Brain Res* 2006; 1086: 191–200.
34. Prum BE Jr, Lim MC, Mansberger SL, et al. Primary open-angle glaucoma suspect preferred practice pattern[®] guidelines. *Ophthalmology* 2016; 123: P112–P151.
35. Cheng H, Laron M, Schiffman JS, et al. The relationship between visual field and retinal nerve fiber layer measurements in patients with multiple sclerosis. *Invest Ophthalmol Vis Sci* 2007; 48: 5798–5805.