


# Effectiveness and safety of a new clip for delivery using a duodenoscope for bleeding after endoscopic sphincterotomy



## Authors

Atsushi Yamaguchi<sup>1</sup>  Hiroki Kamada<sup>2</sup>, Shigeaki Semba<sup>2</sup>, Naohiro Kato<sup>2</sup>, Yasuhiro Okuda<sup>1,3</sup>, Yuji Teraoka<sup>1</sup>, Takeshi Mizumoto<sup>2</sup>, Yuzuru Tamaru<sup>2</sup>, Tsuyoshi Hatakeyama<sup>2</sup>, Hirotaka Kouno<sup>1</sup>, Shigeto Yoshida<sup>2</sup>

## Institutions

- 1 Gastroenterology, Kure Medical Center and Chugoku Cancer Center, Kure, Japan
- 2 Endoscopy, Kure Medical Center and Chugoku Cancer Center, Kure, Japan
- 3 Gastroenterology, Hiroshima University Hospital, Hiroshima, Japan

## Key words

Pancreatobiliary (ERCP/PTCD), Stones, ERC topics, Strictures

received 3.7.2024

accepted after revision 6.9.2024

accepted manuscript online 23.09.2024

## Bibliography

Endosc Int Open 2024; 12: E1190–E1195

DOI 10.1055/a-2420-2419

ISSN 2364-3722


© 2024. The Author(s).

This is an open access article published by Thieme under the terms of the Creative Commons Attribution-NonDerivative-NonCommercial License, permitting copying and reproduction so long as the original work is given appropriate credit. Contents may not be used for commercial purposes, or adapted, remixed, transformed or built upon. (<https://creativecommons.org/licenses/by-nc-nd/4.0/>)

Georg Thieme Verlag KG, Rüdigerstraße 14,  
70469 Stuttgart, Germany

## Corresponding author

M.D., Ph.D. Atsushi Yamaguchi, Kure Medical Center and Chugoku Cancer Center, Gastroenterology, Kure, Japan  
yamaguchiaueo1@gmail.com

 Supplementary Material is available at  
<https://doi.org/10.1055/a-2420-2419>

## ABSTRACT

**Background and study aims** Hemostasis for post-endoscopic sphincterotomy (post-EST) bleeding involves no standard strategy. New clips designed for delivery using the duodenoscope (SureClip, Micro-Tech, Nanjing, China) have been utilized for gastrointestinal bleeding hemostasis and bleeding prevention after polypectomy and papillectomy. We retrospectively analyzed the effectiveness and safety of SureClip for post-EST bleeding.

**Patients and methods** Of 608 patients with endoscopic sphincterotomy (EST), 41 cases (6.7%) experienced post-EST bleeding from 2019 to 2023. Of these patients, 24 underwent hemostasis by SureClip, and the success rate of complete hemostasis and complication by hemostasis by SureClip was analyzed.

**Results** In 12 and 12 patients with urgent and delayed bleeding, 11 (91.7%) and 11 (91.7%) had successful hemostasis, respectively. In addition, missed patients achieved complete hemostasis with additional transcatheter arterial embolization and balloon compression, respectively. No complications were observed, including perforation, pancreatitis, and clipping bile duct and pancreatic duct by mistake.

**Conclusions** Hemostasis with SureClip is safe, effective, and not expensive for post-EST bleeding. It could be the first choice for hemostasis in patients with post-EST bleeding refractory to balloon compression.

## Introduction

Bleeding incidence after endoscopic sphincterotomy (EST) was 0.3% to 2%, with 0.07% to 0.5% in severe cases [1]. With recent changes in administration of anticoagulants and antiplatelet agents for the procedure, it is important to now prioritize prevention of thromboembolism for post-endoscopic sphincterotomy

(post-EST) bleeding. Thus, a reliable and safe hemostatic method is warranted.

Unfortunately, the standard hemostatic method for post-EST bleeding remains unestablished despite some guidelines [2, 3]. One of the hemostatic methods is clipping for the bleeding site, but traditional hemostatic clips are difficult to correct-

ly release using a duodenoscope. Thus, some physicians have performed clipping hemostasis using a forward-viewing endoscope and reported the effectiveness of a cap-fitted forward-viewing endoscope for hemostasis of post-EST bleeding [4,5]. Achieving good visualization of the bleeding site with a forward-viewing endoscope and correct clipping is usually challenging. Recently, new clips designed for delivery using a duodenoscope (Sure Clip, Micro-Tech, Nanjing, China) have been utilized for gastrointestinal bleeding hemostasis and bleeding prevention after polypectomy for gastrointestinal neoplasms and papillectomy for ampullary neoplasm [6]. We retrospectively analyzed the effectiveness and safety of SureClip for post-EST bleeding hemostasis.

## Patients and methods

This retrospective, single-center, observational study included patients who underwent EST for biliary disease from January 2019 to December 2023 at the National Hospital Organization Kure Medical Center and Chugoku Cancer Center. We analyzed characteristics of patients with post-EST bleeding, hemostatic methods, success rates of hemostasis by SureClip, and safety of SureClip.

This study complied with the principles of the Declaration of Helsinki, and the ethics committees of our institution (National Hospital Organization Kure Medical Center and Chugoku Cancer Center) approved the study protocol (Approval No.2022–73). This trial was registered on February 13, 2024, in the University Hospital Medical Network Clinical Trials Registry as UMIN R000061171.

## Endoscopic procedure

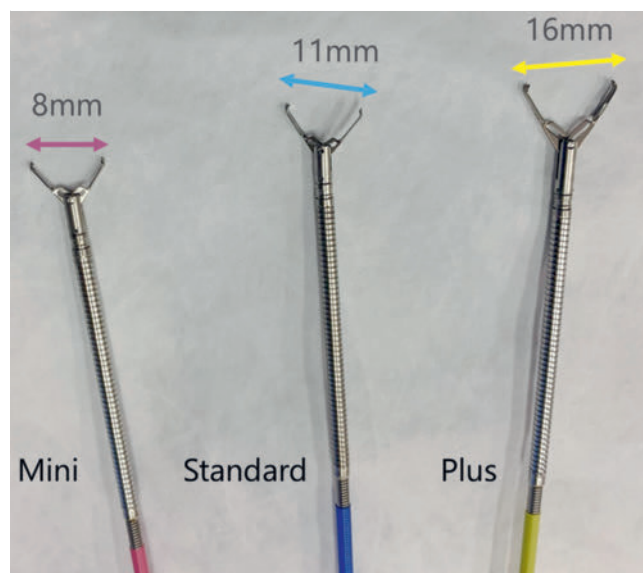
One expert endoscopist, who was board-certified by the Japan Gastroenterological Endoscopy Society and had vast experience in performing endoscopic retrograde cholangiopancreatography (ERCP) of at least 300 cases annually, performed all hemostasis procedures. All procedures were performed with a standard side-viewing endoscope (JF260, TJF260, and TJF290; Olympus, Tokyo, Japan). EST was performed at 11 to 12 o'clock using a standard pull-type papillotomy (CleverCut 3V, 20 mm, monofilament cutting wire, Olympus). Electronic units used during the operation included the ICC 200 or VIO 300 D (ERBE, Tubingen, Germany).

## Definition of post-EST bleeding

We defined patients with post-EST bleeding as having two patterns. Continuous bleeding that required any hemostatic procedure just after EST was defined as urgent bleeding. In addition, abnormal melena or vomiting of blood after an endoscopic procedure and bleeding in the next evaluation was defined as delayed bleeding.

## Strategy for hemostasis in post-EST bleeding

For bleeding, we first used compression hemostasis with a balloon catheter for a Vater papilla. Using an 8- to 10-mm balloon, we applied pressure to the back wall twice for 5 minutes per application. We used SureClips if hemostasis was not achieved.



► **Fig. 1** Three types of clips based on opening length (Mini, Standard, and Plus).

## SureClip

SureClip is a new clip designed for delivery using a duodenoscope. It is a disposable hemoclip with an easy regrasping function, a controlled rotation orientation, and possible complete release using an elevator function to some degree. It involves three clip types—Mini, Standard, and Plus—with opening lengths of 8 mm, 11 mm, and 16 mm, respectively (► **Fig. 1**). We frequently used Standard clips. A Mini clip was used when the working space was small, whereas a Plus clip was utilized when the bleeding site was a deep site.

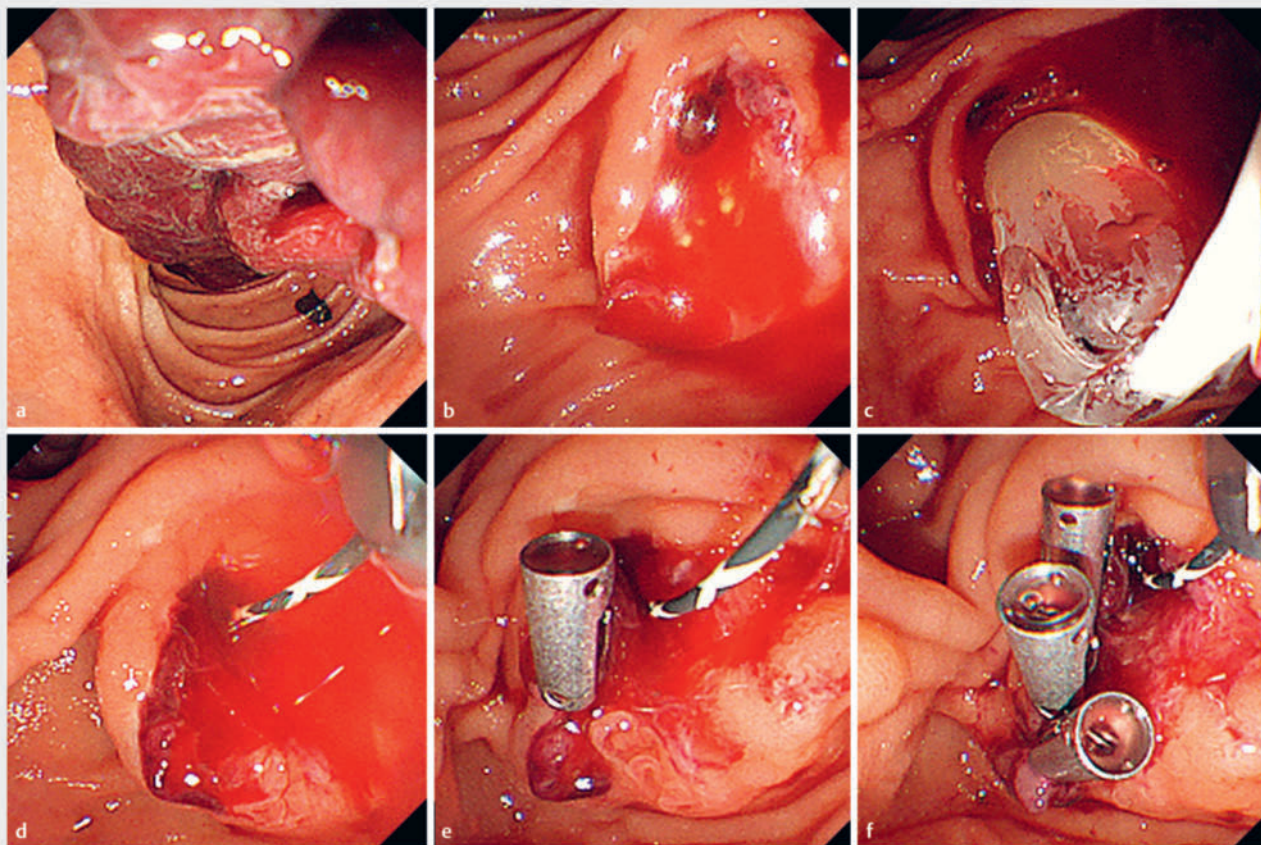
## Hemostasis with SureClip

The operative steps for releasing hemostatic clip were as follows (► **Fig. 2** and ► **Video 1**). First, we quickly delivered the clip using the scope and confirm its placement with the elevator. We opened the clip, insert the right arm into the excision site, and closed the clip. We added one or two clips around the first clip if hemostasis had been achieved.

An elevator could be used to lift the SureClip, but complete elevation was impossible. Thus, we sometimes needed to use an up-angle of the scope in clipping. In addition, we needed to reduce the degree of elevation when releasing the clip. The semi-long position of the duodenoscope was used when the positioning of the scope was not good.

## Outcomes

The primary outcome was successful hemostasis by SureClip. Successful hemostasis was defined as hemostasis during the procedure with no rebleeding a day after the procedure. Secondary outcomes included incidence of adverse events (AEs) (closing the bile duct or pancreatic duct by mistake, pancreatitis, perforation, and other). Rebleeding was defined as hematemesis and melena after a hemostatic procedure and confirmation of bleeding during the reexamination. Post-ERCP pan-



► **Fig. 2** Hemostasis by SureClip for delayed bleeding 3 days after Endoscopic sphincterotomy. **c, d** We tried to achieve hemostasis by balloon compression (balloon size: 10 mm, 5 min, twice) but failed. **e, f** We achieved complete hemostasis with SureClip.

creatitis was diagnosed with diagnostic criteria from the Japan Ministry of Health, Labour and Welfare.

## Results

### Patient characteristics

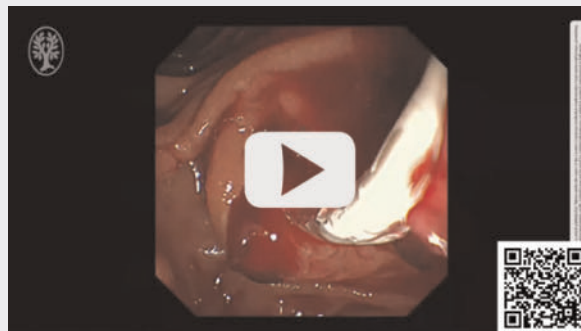We performed EST on 608 patients from 2019 to 2023. Post-EST bleeding was reported in 41 cases (6.7%), including 21 patients (51.2%) and 20 with urgent and delayed bleeding, respectively.

► **Table 1** presents patient characteristics. The median age of the patients was 76 years (range, 40–93), and 21 (51.2%) were male. Choledocholithiasis extraction was the main indication for therapeutic endoscopic retrograde cholangiopancreatography (ERCP). Antiplatelet agents, anticoagulants, and both were administered to eight patients (19.5%), seven patients (17.1%), and one patient, respectively. The range of EST did not exceed the major duodenal horizontal fold in 37 patients (90.2%) and endoscopic papillary balloon dilation was added in nine (22.6%).

### Patient flow

In all 21 patients with urgent bleeding, hemostasis was achieved hemostasis using the procedure. In one patient, however, rebleeding occurred after a few days and complete hemo-

### ► VIDEO



► **Video 1** Endoscopic hemostasis with SureClip. First, we attempted hemostasis with balloon compression and failed. Second, we achieved successful hemostasis with SureClip.

stasis was achieved with SureClip. Of the 20 patients with delayed bleeding, two had rebleeding after a few days of first hemostasis and had hemostasis with SureClip and transcatheter arterial embolization (TAE), respectively. The first hemostasis attempt was successful in 37 patients (90.2%). No AEs occurred in any patients (► **Fig. 3, Table 2**).



► **Table 1** Patient characteristics.

Instances of post-EST bleeding	41
Urgent bleeding: Delayed bleeding	21:20
Male, n (%)	21:20
Age, years, median (range)	76 (40–93)
Comorbidities, n (%)	
▪ Hypertension	23 (56.1)
▪ Hyperlipidemia	18 (43.9)
Diabetes mellitus	15 (36.6)
▪ Malignancy	6 (14.6)
▪ Heart failure	11 (26.8)
▪ Cerebrovascular disease	5 (12.2)
▪ Liver cirrhosis	1 (2.4)
▪ Dialysis	1 (2.4)
Medications, n (%)	
▪ Antiplatelet drugs	8 (19.5)
Anticoagulants	7 (17.1)
▪ Both of above	1 (2.4)
Laboratory data, median (range)	
▪ Total bilirubin, mg/dL	1.4 (0.48–12.3)
▪ Creatinine, mg/dL,	0.82 (0.42–6.5)
▪ Albumin, g/dL	3.5 (1.8–4.9)

► **Table 1** (Continuation)

Instances of post-EST bleeding	41
▪ C-reactive protein, mg/dL	2.8 (0.04–43.9)
▪ White blood cell count, ×10 <sup>2</sup> /μL	67 (25–300)
▪ Platelet count, ×10 <sup>4</sup> /μL	20.7 (4.8–51.3)
▪ PT-INR*	1
Objective for EST, n (%)	
▪ Extraction of choledocholithiasis	21 (51.2)
▪ Biliary drainage for acute cholangitis	8 (19.5)
▪ Biliary drainage for obstructive jaundice	5 (12.2)
Stenting for obstructive jaundice	4 (9.8)
▪ Examination for biliary tract	3 (7.3)
Vater papilla	
▪ Previous EST, n (%)	5 (12.2)
▪ Periampullary diverticulum, n (%)	15 (36.6)
Procedure of EST	
▪ EST (vs. EST + EPBD)	32 (78.4)
▪ Excision not exceeding the major duodenal horizontal fold	37 (90.2)

Post-EST, post endoscopic sphincterotomy; urgent bleeding, bleeding in the procedure; delayed bleeding, bleeding after procedure; PT-INR, prothrombin time-international normalized ratio; EST, endoscopic sphincterotomy; EPBD, endoscopic papillary balloon dilation.  
\*There were data deficiencies in 5 patients.

## Hemostasis by SureClip

Hemostasis was achieved in 24 patients with SureClip. Results are shown in ► **Table 2** and **Supplementary Table 1**. Urgent and delayed bleeding were reported in 12 and 12 patients, respectively. All patients achieved hemostasis in the first procedure but two experienced rebleeding after a few days. The success rate for hemostasis with SureClip was 91.7%. One patient was referred for TAE. No AEs were reported, such as perforation, pancreatitis, or clipping the bile and pancreatic duct by mistake.

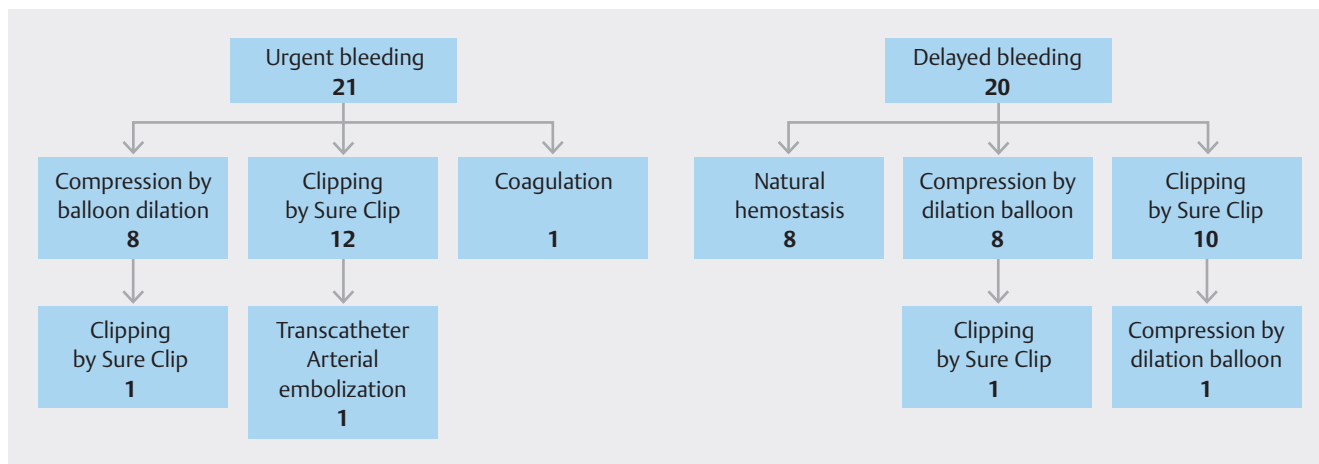
## Discussion

This study is the first case series to analyze the effectiveness and safety of SureClip for post-EST bleeding.

Post-EST bleeding is one of the complications that occur in ERCP-associated procedures. Fortunately, in most cases it is self-limited and stops spontaneously, but some patients experience severe bleeding and death. The recent tendency to prioritize thromboembolism prevention in endoscopic procedures is increasing the incidence of severe bleeding, a trend that is likely to continue in the future. Thus, it is necessary to have reliable hemostatic methods.

In general, endoscopic hemostatic methods for post-EST bleeding include balloon compression, epinephrine injection, thermocoagulation, and hemostatic clip placement. TAE and open surgery may be a salvage treatment option in cases in which uncontrolled bleeding cannot be remedied with an endoscopic technique. Recently, some reports have shown the efficacy of placement of a covered self-expandable metal stents (SEMS) [7] for uncontrolled bleeding before TAE and surgery. In addition, the efficacy of a novel self-assembling peptide matrix (PuraStat; 3-D Matrix Europe SAS, France) has been reported for hemostasis in gastrointestinal endoscopic procedures, including post-EST bleeding [8].

These methods have limitations. Balloon compression is easy and safe, but can only control mild bleeding. An injection of diluted epinephrine (1:10,000) at the bleeding site resulted in a 4% to 16% rebleeding rate, which is a potential risk for patients with heart disease [1]. Thermocoagulation therapy includes argon plasma coagulation, bipolar probe, and heat probe, which are effective but may have a potential risk of perforation because of the power used can cause tissue damage. SEMS placement is reported to be effective for massive post-EST bleeding, but the technique cannot be adapted and is very expensive. Moreover, the potential risk of AEs, including pancreatitis and cholecystitis, is a major concern. PuraStat is not recommended for spurting bleeding and is not appropriate for massive bleed-



► **Fig. 3** Patient flow. Urgent and delayed bleeding were reported in 21 and 20 patients, retrospectively. One patient with urgent bleeding after compression hemostasis had delayed bleeding and required hemostasis with SureClip. Two patients with delayed bleeding had rebleeding after the first hemostatic procedure. One patient had complete hemostasis with SureClip and the other with TAE.

ing. TAE is an effective and safe therapy compared with endoscopic hemostasis because of the few negative effects of the technique on the respiratory and circulatory systems. The weak points of TAE are the high cost, long procedure time, and need for apparatus and familiarity with angiographical therapy.

A technical problem common to epinephrine injection, thermocoagulation therapy, and traditional hemostatic clips is difficulty in achieving hemostasis using a duodenoscope because the elevator is not fully elevated when using each device. Thus, these hemostatic techniques are often attempted using a forward-viewing endoscope. Achieving hemostasis with this technique also is difficult because placement of the ampulla of Vater cannot be easily confirmed from the front. Reports have revealed the efficacy of hemostasis with a forward-viewing endoscope and a front-end transparent cap [4,5]; however, the technique is difficult technique for the average endoscopist.

We have started hemostasis for post-EST bleeding using SureClip, which makes clipping with the elevator function of the duodenoscope easy and results in a good success rate for hemostasis. There are some advantages to hemostasis with SureClip compared with other techniques. First, a hemostatic procedure is performed in a duodenoscope (no need to change the scope to a forward-viewing scope, easy confirmation of the location of the ampulla of Vater from the front). Second, SureClip is easy to regrasp, rotation orientation can be controlled, and it is possible complete release using an elevator function to some degree. Thus, in cases in which the device is not grasped properly, it can be regrasped and the correct clipping then achieved. Some other clips (e.g. the Resolution 360 clip, Boston Scientific, Massachusetts, United States) have the same function as SureClip and they may demonstrate hemostatic ability similar to the SureClip. A comparison of each clip's ability has been performed in vitro [9], but we have no data on clips other than SureClip.

We used a median of three hemoclips (range, 1–6), and we typically added one or two clips near the clip that induced hemostasis. This was because we suspected that an additional clip

near the first clip might prevent delayed bleeding. When we could not confirm a bleeding point, we first performed one clipping in any direction from 9 o'clock to 12 o'clock and continued clipping while searching for the bleeding site until hemostasis was achieved. The blood supply in the papillary region of the duodenum is most prevalent from 9 o'clock to 12 o'clock. Hence, Dong, et al. revealed the effectiveness of prophylactic clipping in the 12 o'clock direction of ampulla Vater for post-EST bleeding[1].

The most welcome result in our study was the absence of complications associated with clipping using SureClip. In particular, no perforations or pancreatitis associated with epinephrine injection, thermocoagulation, or SEMS placement occurred. SureClip is disposable and more expensive than a traditional reusable clip. It is approximately \$22 US dollars per clip in Japan and the cost for hemostasis is equivalent or lower compared with PuraStat, thermocoagulation therapy, and SEMS placement even if several clips are used. The weak point of clipping hemostasis is that it may cause image distortion around the clip, including the pancreatic head, although 3T magnetic resonance imaging can be performed before the clip falls off. Initially, we feared occurrence of pancreatitis associated with mis-clipping of the pancreatic duct. In practice, our experience with 24 patients indicated that there was little possibility of mis-clipping of the pancreatic duct because the bile duct and pancreatic duct are separated after EST. Thus, we think there is little need to place a pancreatic stent for prevention of pancreatitis.

This study has some limitations. First, it was retrospective, single-center, and had a small sample size. Second, the effectiveness of SureClip could not be compared with other hemostatic methods, particularly, thermal therapy. Third, the population of patients with delayed bleeding included patients with no decrease in hemoglobin level, so some cases were not consistent with Cotton's diagnosis criteria for post-EST bleeding [10].

► **Table 2** Results.

All patients, n	41
Urgent bleeding:delayed bleeding	21:20
Time to bleeding in patients with delayed bleeding, day, median (range)	4 (1–11)
Amount of decreased hemoglobin level in patients with delayed bleeding, g/dL, median (range)	2.8 (-1.3–8.3)
Success of hemostasis, n (%)	41 (100)
Use of TAE	1 (2.4)
No. patients needing several procedures for hemostasis	4 (9.8)
Death associated with post-ES bleeding	0
Adverse events associated with hemostatic procedure	0
Patients with hemostatic procedure by Sure Clip, n	24
Urgent bleeding:delayed bleeding	12: 12
Success of hemostasis by SureClip, n/N	
▪ Urgent bleeding	11/12 (91.7)
▪ Delayed bleeding	11/12 (91.7)
Additional therapy for patients with failed hemostasis	
Compression by balloon catheter	1
TAE	1
Number of clips used, n, median (range)	3 (1 – 6)
Clipping site, o'clock direction, n	
8–12	13
12	3
12–16	3
8–15	5
Adverse events associated with hemostatic procedure by SureClip	0
Clipping bile duct by mistake	0
▪ Clipping pancreatic duct by mistake	0
▪ Pancreatitis	0
▪ Perforation	0
▪ Others	0
urgent bleeding, bleeding during procedure; delayed bleeding, bleeding after procedure; TAE, transcatheter arterial embolization.	

## Conclusions

Hemostasis with SureClip using a duodenoscope is a relatively easy hemostatic method. In addition, it is safe and inexpensive; thus, it could be a first choice for hemostasis in patients with post-EST bleeding refractory to balloon compression hemostasis.

## Conflict of Interest

The authors declare that they have no conflict of interest.

## References

- [1] Dong J, Feng Q, Teng G et al. Application of a new hemostatic clip to prevent delayed bleeding after endoscopic sphincterotomy: a propensity score-matched analysis. *J Clin Gastroenterol* 2024; 58: 614–618 doi:10.1097/MCG.0000000000001906
- [2] Dumonceau JM, Kapral C, Aabakken L et al. ERCP-related adverse events: European Society of Gastrointestinal Endoscopy (ESGE) Guideline. *Endoscopy* 2020; 52: 127–149 doi:10.1055/a-1075-4080
- [3] Mullady DK, Wang AY, Waschke KA. AGA Clinical Practice Update on Endoscopic Therapies for Non-Variceal Upper Gastrointestinal Bleeding: Expert Review. *Gastroenterology* 2020; 159: 1120–1128 doi:10.1053/j.gastro.2020.05.095
- [4] Liu F, Wang GY, Li ZS. Cap-assisted hemoclip application with forward-viewing endoscope for hemorrhage induced by endoscopic sphincterotomy: a prospective case series study. *BMC Gastroenterol* 2015; 15: 135
- [5] Chon HK, Kim TH. Endoclip therapy of post-sphincterotomy bleeding using a transparent cap-fitted forward-viewing gastroscope. *Surg Endosc* 2017; 31: 2783–2788 doi:10.1007/s00464-016-5287-x
- [6] Park SW, Song TJ, Park JS et al. Effect of prophylactic endoscopic clipping for prevention of delayed bleeding after endoscopic papillectomy for ampullary neoplasm: a multicenter randomized trial. *Endoscopy* 2022; 54: 787–794 doi:10.1055/a-1737-3843
- [7] Yoshida M, Inoue T, Naitoh I et al. Practical experiences of unsuccessful hemostasis with covered self-expandable metal stent placement for post-endoscopic sphincterotomy bleeding. *Clin Endosc* 2022; 55: 150–155
- [8] Choi JH, Cho IR, Lee SH et al. Efficacy and safety of novel hemostatic gel in endoscopic sphincterotomy or endoscopic papillectomy: A multicenter, randomized controlled clinical trial. *Dig Liver Dis* 2023; 55: 527–533 doi:10.1016/j.dld.2023.01.157
- [9] Wang TJ, Aihara H, Thompson AC et al. Choosing the right through-the-scope clip: a rigorous comparison of rotatability, whip, open/close precision, and closure strength (with videos). *Gastrointest Endosc* 2019; 89: 77–86.e1
- [10] Cotton PB, Lehman G, Vennes J et al. Endoscopic sphincterotomy complications and their management: an attempt at consensus. *Gastrointest Endosc* 1991; 37: 383–393