



# Urinary Bladder Stone Passing Using a Persian Herbal Recipe

Ayda Hosseinkhani, PharmD, PhD<sup>1</sup>, Fatemeh Tabatabaei, MD, PhD<sup>1</sup>,  
 Maryam Mosaffa-Jahromi, PharmD, PhD<sup>1</sup>, and Mehdi Pasalar, MD, MPH, PhD<sup>1,2</sup>

## Abstract

**Objective.** The intrauterine device (IUD) is a popular contraceptive instrument with reported complications. IUD migration to the urinary bladder, a rare genitourinary tricky situation, may cause stone formation and result in urinary system sequels such as a stone formation and a recurrent infection. **Case Report.** This is a case report of IUD migration to the urinary bladder, mineralization, and subsequent complications. We report the case of a 35-year-old woman with a copper IUD nidus stone in her urinary bladder. She received a Persian medicine formulation including goat's head, cornflower, silk corn, field horsetail, cumin, black Spanish radish, and common dandelion. She passed an oxalate stone 3 days later. **Conclusion.** Inexpensive common traditional recommendations might be helpful in current obstetrics and gynecology practice in our region.

## Keywords

intrauterine device, complication, Persian medicine, urinary bladder

Received November 21, 2017. Received revised January 16, 2018. Accepted for publication February 13, 2018.

Use of medicinal plants and herbal products is very prevalent and favorable in Iran. People consume these natural products for different ailments—ranging from simple to complicated ones.<sup>1</sup> One of the most widespread diseases in urinary field is stone formation in the route of voiding. It may be a small nonobstructing calculus without obvious symptoms or a large stone with renal colic, restlessness, bloody urine, incontinency, and vomiting.<sup>2</sup> There are various options for stone removal like ureteroscopy, which is invasive.<sup>3</sup> Traditional and integrative medicine suggested more gentle choices for stone disease treatment. Some of these remedies are focused on herbal formulas with known or unidentified mechanisms of actions—helping stone ejection, stone dissolution, or slowing down stone formation down.<sup>4,5</sup>

Persian medicine textbooks have assigned a notable part to nephrolithiasis reviewing the genitourinary system. This starts from basic topics of calculus formation and ends with different therapeutic recommendations. Some of these remedies are medicinal plants that are prescribed in differing traditional dosage forms such as decoction or beverage.<sup>4,6</sup> Affirmative response to these therapies could bring more comfort, satisfaction and quality of life while applying a natural noninvasive method of treatment.<sup>7</sup>

Intrauterine device (IUD) is a safe prevalent reversible means of long-term contraception globally—it is ranked second among contraceptive methods.<sup>8</sup> There are various post-

IUD insertion side effects ranging from common complications like vaginal bleeding to serious ones like uterine perforation and malignancy.<sup>9</sup> Several cases of intravesical translocation of IUD have been reported in the recent decade.<sup>9-12</sup> However, applying a traditional herbal formula as a therapeutic option is quite novel. We report a case of IUD migration to the urinary bladder, its mineralization, and subsequent problems.

## Case Report

A 35-year-old woman parity 2 living 2 came to our Persian medicine clinic with complaints of recurrent vaginal infection, urinary tract infection, hesitancy, and suprapubic discomfort for 13 years. Speculum examination showed normal cervix and moderate signs of vaginal infection. Urine culture was

<sup>1</sup> Research Center for Traditional Medicine and History of Medicine, Shiraz University of Medical Sciences, Shiraz, Iran

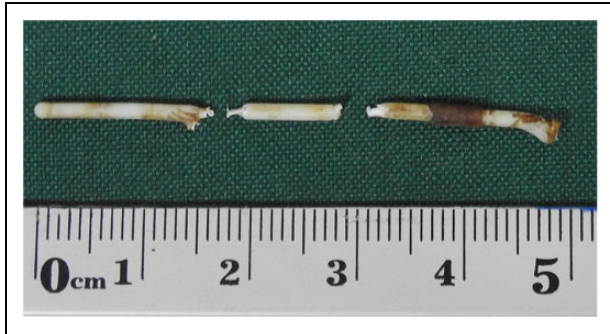
<sup>2</sup> Essence of Parsiyan Wisdom Institute, Traditional Medicine and Medicinal Plant Incubator, Shiraz University of Medical Sciences, Shiraz, Iran

## Corresponding Author:

Mehdi Pasalar, MD, MPH, PhD, Research Center for Traditional Medicine and History of Medicine, Shiraz University of Medical Sciences, Zand Street, 7134845794, Shiraz, Iran.

Email: [pasalar@sums.ac.ir](mailto:pasalar@sums.ac.ir)





**Figure 1.** Fragments of copper intrauterine device retracted from the uterovesical junction by laparoscopy.

requested and found positive for the infection. So, antibiotic therapy was started according to the antibiogram results. Two months later, the patient came back with the same symptoms. A pelvic ultrasonography was recommended. It was normal, but it was found that simple pelvic radiograph missed the IUD and the presence of a stone opacity with dimensions of  $1.8 \times 1.1$  cm around the IUD on the site of the urinary bladder.

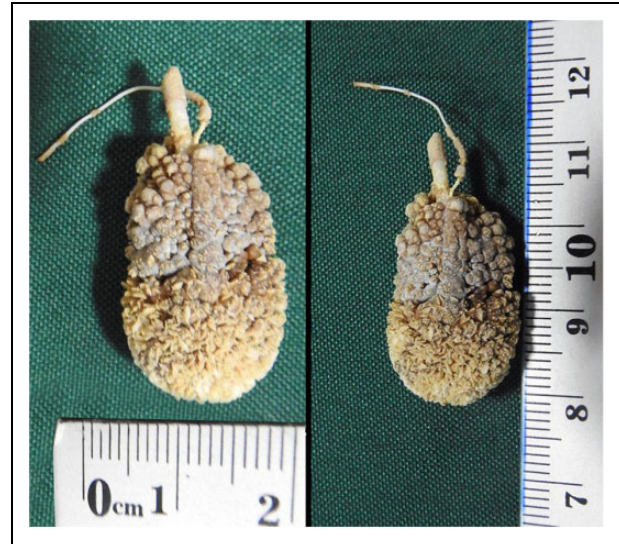
In her past medical history, the patient reported that 5 weeks after her first delivery (14 years ago) a copper IUD was placed in by a gynecologist. She noticed that her abdomen growing bigger 5 months or so later; she went to the hospital and an ultrasonography of the lower abdomen revealed a single live intrauterine gestation of 17 weeks without any sign of IUD. She passed the second normal vaginal delivery and forgot the IUD completely. In fact, she thought that it had fallen out. Thereafter, she developed the recurrent aforementioned symptoms.

She was referred to a gynecologist and a laparoscopic surgery was performed to take out the broken parts of the IUD from the vesicouterine junction after the removal of the adhesions (Figure 1). However, she refused laparotomy for stone removal. She returned to the Persian medicine clinic to receive herbal therapy to aid stone passage.

## Results

After signing an informed consent, she received a combination of 2 spoonsful from each of the following herbal medicines: goat's head (*Hasak*), cornflower (*jauz-e jandom*), silk corn (*Kakol-e zorat*), field horsetail (*Amsūkh*), and common dandelion (*Hendobay-e barri*).

The preparation of the infusion was done by boiling the herbs in 2 glasses of water and reducing it to 1 glass after evaporation. It was taken 1 hour after each main meal (thrice a day). Half an hour after taking the infusion, the patient took a cumin (*karīya*) decoction (2 teaspoons in 1 glass of boiled water). She also took two glasses of black Spanish radish (*Fojl*) juice daily. All of the aforementioned herbal medicines were available in the Persian medicine clinic drugstore and approved by a Persian medicine pharmacologist in the School of Pharmacology, Shiraz. After 3 days, the patient passed a hard, rough gray-colored stone measuring about  $23 \times 13 \times 7$  mm through the urethra (Figure 2). As seen in Table 1, the laboratory



**Figure 2.** Stone formed in urinary bladder with its intrauterine device nidus.

**Table 1.** Urinary Bladder Calculi Analysis.

Ingredient	Percent
Calcium	40
Oxalate	40
Phosphate	5
Ammonium	1
Nonminerals	14

analysis demonstrated a calcium oxalate stone structure. The patient was relieved of the symptoms bothering her after the restoration phase and she had no complaint during her follow-up visit after 3 months.

## Discussion

Stone formation may occur eventually in those women in whom the IUDs translocate into the urinary bladder. It may cause a wide range of symptoms based on the unusual position of the migrated IUD. However, it might be completely asymptomatic.<sup>8</sup> The symptoms could be reported very shortly after the IUD insertion or delayed for a long period.<sup>13</sup> Despite recurrent appropriate antibiotic therapies for the past 13 years, the patient presented with genitourinary system infection that did not disappear fully after the IUD insertion. Such a long history of infection reveals the importance of genital and/or urinary system imaging in women with a history of IUD insertion—a neglected procedure in the current case.

Different etiologies and predisposing factors are responsible for IUD migration and resulting complications, even though urinary bladder is an infrequent place for translocation.<sup>8</sup> We cannot determine the main cause of IUD translocation in this case, even though the patient had a history of IUD insertion in the puerperal period as an accepted factor that increased the

chance of uterine damage. On the other hand, she had a history of painless IUD insertion by trained personnel (gynecologist) as well as 2 normal vaginal deliveries.

Considering the World Health Organization's protocol for the management of displaced IUDs, which emphasizes the urgent removal of the device despite the IUD position and type,<sup>13</sup> the patient should have been scheduled for laparoscopic surgery. Based on the calculus size estimation, open surgery seemed to be the right choice.<sup>13</sup> The patient refused the surgery and opted for traditional medicine or complementary and alternative medicine remedies. There is no established medical therapy for IUD-linked urinary stone formation in the current literature, even though there are some herbal remedies in traditional Persian medicine textbooks that help in diuresis and consequential calculus passage.<sup>6</sup> We prescribed a compound herbal preparation—a Persian medicine choice of treatment—to assist the normal excretion of the stone out of the body.

Goat's head (*Tribulus terrestris* L), cornflower (*Cyanus segetum* Hill), silk corn (*Zea mays* L), field horsetail (*Equisetum arvense* L), common dandelion (*Taraxacum campylodes* G.E. Haglund), cumin (*Cuminum cyminum* L), and Spanish radish (*Raphanus sativus* var *sativus*) are among the most popular and available herbal plants in our traditional practice. There are multiple quotations in traditional Persian medicine masterpieces supporting the use of the aforementioned herbal medicines for urinary system ailments.<sup>6</sup> There is some evidence in favor of the effect of herbal use in experimental or clinical trials for urinary system problems. Common dandelion leaf hydro-ethanolic extracts showed an amplified urinary frequency and volume as a diuretic agent in humans.<sup>14</sup> The aqueous extract of the leaves and fruits of goat's head in an oral dose of 0.5 g/kg demonstrated a positive diuresis effect, which was somewhat more than that of furosemide in the Wistar male rat group.<sup>15</sup> In contrast, cornflower (*Cyanus segetum* Hill) diuretic activity was lower than hydrochlorothiazide in a similar experimental group.<sup>16</sup> With the increasing glomerular filtration rate in guinea pigs, a safe and strong diuretic activity was also proved by the consumption of field horsetail aqueous extract.<sup>17</sup> It is important to find different positive effects for the Spanish radish aqueous extract—significant stone weight loss in rats and inhibition of calcium hydrogen phosphate dehydrate crystals formation.<sup>18,19</sup> Considering the nature of the excreted stone, *Zea mays* L and *Tribulus terrestris* L extracts recently confirmed an encouraging inhibiting role of the growth of calcium oxalate dehydrate crystals in vitro.<sup>20</sup>

Although delicate surgical procedures are available nowadays, traditional noninvasive options for patients living in developing areas of our region or those preferring traditional solutions seem to be ethical, practical, and economical. On the other hand, an evidence-based practice should be kept in mind for practitioners all around the world.

### Acknowledgments

The authors are thankful to the patient for kind contribution of her time to the research.

### Author Contributions

AH and MP conceived of the presented idea. MM and FT gathered the data and followed the patient. AH and MP wrote the draft and supervised the findings of this work. All authors discussed the results and contributed to the final draft. All authors gave approval for the final version of the article.

### Declaration of Conflicting Interests

The authors declared no potential conflicts of interest with respect to the research, authorship, and/or publication of this article.

### Funding

The authors received no financial support for the research, authorship, and/or publication of this article.

### Ethical Approval

Written informed consent was signed by the participants and approved by SUMS ethics committee.

### References

- Hosseinkhani A, Lankarani KB, Mohagheghzadeh A, Long C, Pasalar M. An evidence-based review of medicinal herbs for the treatment of gastroesophageal reflux disease (GERD) [published online October 10, 2017]. *Curr Drug Discov Technol*. doi:10.2174/1570163814666171010113517.
- Mohammadjafari H, Barzin M, Salehifar E, Kord KM, Aalae A, Mohammadjafari R. Etiologic and epidemiologic pattern of urolithiasis in north Iran; review of 10-year findings. *Iran J Pediatr*. 2014;24:69-74.
- Shirvan MK, Mahboub MRD, Rahimi HR, Seyedi A. The evaluation of ureteroscopy and pneumatic lithotripsy results in pregnant women with urethral calculi. *Nephrourol Mon*. 2013;5:874-878. doi:10.5812/numonthly.10726.
- Jorjani E. *Zakhireye Kharazm Shahi* (Treasure of Kharazm Shah). Tehran, Iran: Iranian Medical Academy; 2001.
- Kasote DM, Jagtap SD, Thapa D, Khyade MS, Russell WR. Herbal remedies for urinary stones used in India and China: a review. *J Ethnopharmacol*. 2001;203:55-68. doi:10.1016/j.jep.2017.03.038.
- Sina HA. *Al-Qanun fi al-Tibb* [The Canon of Medicine]. Beirut, Lebanon: Alaalami Library; 2005.
- Naja F, Fadel RA, Alameddine M, Aridi Y, Zarif A, Hariri D, Tfayli A. Complementary and alternative medicine use and its association with quality of life among Lebanese breast cancer patients: a cross-sectional study. *BMC Complement Altern Med*. 2015;15:444. doi:10.1186/s12906-015-0969-9.
- Agacayak E, Tunc SY, Icen MS, et al. Evaluation of predisposing factors, diagnostic and treatment methods in patients with translocation of intrauterine devices. *J Obstet Gynaecol Res*. 2015;41:735-741. doi:10.1111/jog.12620.
- Gokce MI, Suer E, Tangal S, Beduk Y. Squamous cell carcinoma of the bladder associated with chronic irritation related to a migrated intrauterine device. *Scand J Urol Nephrol*. 2010;44:183-185. doi:10.3109/00365591003639210.
- Guner B, Arikan O, Atis G, Canat L, Caskurlu T. Intravesical migration of an intrauterine device. *Urol J*. 2013;10:818-820.

11. Gyasi-Sarpong CK, Maison PO, Morhe E, et al. Intravesical migration of an intrauterine device. *BMC Res Notes*. 2016;9:4. doi:10.1186/s13104-015-1792-6.
12. Istanbuluoglu MO, Ozcimen EE, Ozturk B, Uckuyu A, Cicek T, Gonen M. Bladder perforation related to intrauterine device. *J Chin Med Assoc*. 2008;71:207-209. doi:10.1016/s1726-4901(08)70105-9.
13. Shin DG, Kim TN, Lee W. Intrauterine device embedded into the bladder wall with stone formation: laparoscopic removal is a minimally invasive alternative to open surgery. *Int Urogynecol J*. 2012;23:1129-1131. doi:10.1007/s00192-011-1632-8.
14. Clare BA, Conroy RS, Spelman K. The diuretic effect in human subjects of an extract of *Taraxacum officinale* folium over a single day. *J Altern Complement Med*. 2009;15:929-934. doi:10.1089/acm.2008.0152.
15. Al-Ali M, Wahbi S, Twajj H, Al-Badr A. *Tribulus terrestris*: preliminary study of its diuretic and contractile effects and comparison with *Zea mays*. *J Ethnopharmacol*. 2003;85:257-260.
16. Klimas R, Rabiskovi M, Civinskiene G, Bernatoniene J. The diuretic effect of cornflower water extract [in Lithuanian]. *Medicina (Kaunas)*. 2007;43:221-225.
17. Turker H, Turkay M. Effects of *Equisetum arvense* plant extracts on the kidney stones and its diuretic action. *Cell Mol Biol*. 2016;1:1-8.
18. Natarajan S, Rmachandran E, Suja DB. Growth of some urinary crystals and studies on inhibitors and promoters. II. X-ray studies and inhibitory or promoteory role of some substances. *Crystal Res Technol*. 1997;32:553-559.
19. Vargas R, Perez RM, Perez S, Zavala MA, Perez C. Antirolithiatic activity of *Raphanus sativus* aqueous extract on rats. *J Ethnopharmacol*. 1999;68:335-338.
20. Ahmed S, Hasan MM, Mahmood ZA. In vitro urolithiasis models: an evaluation of prophylactic management against kidney stones. *J Pharmacogn Phytochem*. 2016;5:28.