

Failed Radiation Synovectomy in Diseased Knee Joint with Missed Tuberculous Synovitis

Ashwani Sood, Aman Sharma¹, Devendra Kumar Chouhan², Kirti Gupta³, Rahul Parghane, Jaya Shukla, Bhagwant Rai Mittal

Departments of Nuclear Medicine, ¹Internal Medicine, ²Orthopedics and ³Histopathology, Postgraduate Institute of Medical Education and Research, Chandigarh, Punjab and Haryana, India

Abstract

The authors in this case report highlight the poor outcome of radiation synovectomy (RSV) for repeated knee joint effusion in a patient with histopathologically proven nonspecific arthritis. There was partial response initially following RSV but later follow-up showed recurrence in joint effusion with limited and painful mobility of the knee joint. Subsequent surgical synovectomy and histopathological examination showed it to be tubercular in origin. Thus in a country endemic for tuberculosis, an alternative infective etiology should also be kept in mind before subjecting the patient to RSV.

Keywords: Radiation synovectomy, Rhenium-188 (Re-188) tin colloid, tuberculous synovitis

Introduction

Radiation synovectomy (RSV) or radiosynoviorthesis involves an intra-articular injection of various beta (β)-emitting radiopharmaceuticals in colloidal form to irradiate the inflamed joint synovium resulting in diminished inflammatory activity and subsequent fibrosis in different stages of arthritis. The RSV is a well-established treatment modality for inflammatory joint diseases but not indicated in infective arthritis including tuberculosis.^[1]

Tuberculosis of the appendicular skeleton is relatively rare. It constitutes about 1–3% of all tuberculosis and 7–15% of all extrapulmonary cases.^[2] Spine is the most common site followed by joints and knee joint being the third commonest site. Tuberculosis involvement is predominantly monoarticular and it commonly occurs in the weight-bearing joints such as hip and knee.^[2] Tubercular synovitis when presenting as a solitary

manifestation is often missed in absence of a pulmonary involvement. Here, we present a case of tuberculous synovitis of the knee joint where the initial diagnosis was different resulting in delay of the appropriate treatment.

Case Report

A 27-year-old male patient having recurrent left knee joint swelling, pain, and limited mobility was diagnosed to have nonspecific synovitis on synovial biopsy. Repeated aspiration and systemic therapy failed to give relief and the patient was referred for RSV. The baseline three-phase bone scan demonstrated increased blood pool and osteoblastic activity in the affected knee joint [Figure 1a and b]. RSV was performed using in-house prepared Re-188-tin colloid particles. Around 35 mL of slightly thick yellow colored fluid was aspirated followed by the administration of well-shaken 444 MBq of radiotracer (6 mL volume) through the same route and subsequent flushing with saline. The affected knee was repeatedly flexed and extended for homogenous tracer distribution in the synovial cavity. The treated joint was immobilized for 48 h to prevent any tracer leakage from the joint space. Postinjection static image at 1 h showed homogenous intra-articular tracer distribution within the affected joint space only. The patient had partial relief at 3-month follow-up, but effusion and pain reappeared at

Access this article online

Quick Response Code:



Website:
www.wjnm.org

DOI:
10.4103/1450-1147.167606

Address for correspondence:

Dr. Bhagwant Rai Mittal, Department of Nuclear Medicine, Postgraduate Institute of Medical Education and Research, Chandigarh - 160 012, Punjab and Haryana, India. E-mail: brmittal@yahoo.com

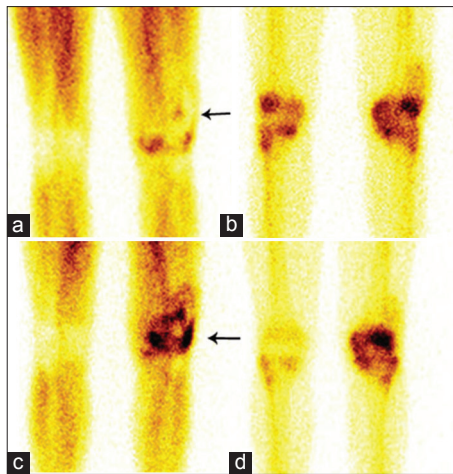


Figure 1: Three-phase bone scan showing increased tracer uptake in left knee region in blood pool phase (arrow) (a) and increased osteoblastic activity (b) in left knee joint. The follow-up three-phase bone scan with almost similar findings in blood pool (arrow) (c) and delayed phase (d)

6-month follow-up. Repeated bone scan showed findings almost similar to baseline bone scan [Figure 1c and d]. The histopathological examination of the patient who underwent partial surgical synovectomy revealed many compact epithelioid granulomas present beneath the subepithelium. Some multinucleated and Langerhans type giant cells, bordered by reactive lymphoid cells, were also identified without any necrosis [Figure 2a-d]. Stain for acid-fast bacilli (AFB) was negative. The polymerase chain reaction (PCR) report of the patient for mycobacterium tuberculosis (MTB) was positive. The patient was put on antitubercular treatment in view of the abovementioned findings and is asymptomatic presently.

Discussion

RSV has been used since early 1950 in the treatment of resistant synovitis for individual joints where other form of therapy has failed.^[3] It has been shown to be very efficacious in relieving the symptoms in 60–80% of cases.^[4] A wide variety of radiopharmaceuticals in colloidal form have been used for different joints depending upon their size. Rhenium-188 (Re-188) has both β and gamma (γ) radiations, suitable for therapeutic purpose and imaging. Round-the-clock availability of W-188/Re-188 generator and in-house preparation of tin colloid particles makes RSV with Re-188-labeled tin colloid a very cost-effective treatment modality^[5] and we also used the same. The tuberculosis synovitis is rare and has atypical presentation. There is marked joint effusion and thickening of synovial membrane, once the mycobacteria lodge in the joint synovium. The usual presentation is chronic pain, swelling, local tenderness, warmth, and progressive loss of function.^[6,7] The triad of joint space

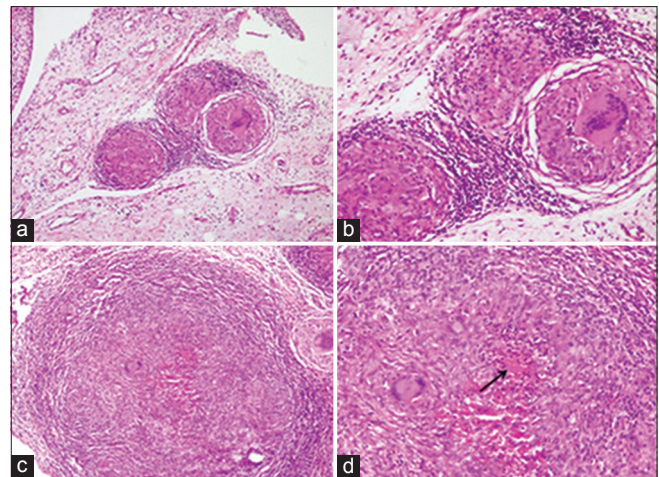


Figure 2: (a and b) Multiple epithelioid cell granulomas within the fibrofatty tissue constituting the synovial subepithelium [hematoxylin and eosin (H and E) stain, original magnification $\times 40$ (a), $\times 100$ (b)] (c) High magnification of epithelioid cell granuloma with Langhans giant cell H and E stain, original magnification $\times 200$ (d) Central necrosis (arrow) was identified in some of the granulomas H and E stain, original magnification $\times 200$

reduction, juxta-articular osteoporosis, and peripheral osseous erosion is seen in the late stages. Tuberculous synovitis is diagnosed by the culture of the synovial fluid, microscopic examination for AFB, and histopathological examination, though culture appears to be most sensitive among them and AFB positivity is observed in only around 16% cases.^[2,6-8] The noncaseating epithelioid cell granulomas, as identified in the present case, can also develop secondary to other pathologies including rheumatoid arthritis and sarcoidosis.^[9] Pulmonary changes are usually absent in half of the cases,^[7] as was also noted in the index case. The concurrent human immunodeficiency virus (HIV) infection is shown to be a risk factor for developing skeletal tuberculosis;^[9] however, our patient was immune-competent. Shen *et al.* showed the usefulness of arthroscopy for the management of synovial tuberculosis of the knee joint by performing the synovectomy and synovial membrane biopsy. It was followed by intra-articular isoniazid injection and systemic antitubercular drugs. All the patients had improved outcome.^[10] Similarly, our patient had partial synovectomy and synovial membrane biopsy in follow-up period of initial treatment. The positivity for tubercular bacillus on PCR and the favorable response to ATT confirmed the etiology of tuberculous synovitis. The institution of appropriate therapy in the index patient resulted in complete recovery.

The possibility of tuberculosis synovitis is often overlooked till the disease gets worsened or fails to show response to the treatment. The RSV did not yield the desired result in the index case due to the absence of proper diagnosis. In order to treat the patient

appropriately, possibility of tuberculosis synovitis should also be kept in mind and ruled out before RSV. This case emphasized that failure of favorable response to the initial treatment offered in the form of RSV necessitated a second look to rule out other etiopathogenesis.

References

1. Uğur O, Gedik GK, Atilla B, Rubello D. Radiosynovectomy: Current status in the management of arthritic conditions. *Nucl Med Commun* 2008;29:755-8.
2. Spiegel DA, Singh GK, Banskota AK. Tuberculosis of the musculoskeletal system. *Tech Orthop* 2005;20:167-78.
3. Fellingner K, Schmid J. Local therapy of rheumatic diseases. *Wien Z Inn Med* 1952;33:351-63.
4. Deutsch E, Brodack JW, Deutsch KF. Radiation synovectomy revisited. *Eur J Nucl Med* 1993;20:1113-27.
5. Shamim SA, Kumar R, Halanaik D, Kumar A, Shandal V, Shukla J, *et al.* Role of rhenium-188 tin colloid radiosynovectomy in patients with inflammatory knee joint conditions refractory to conventional therapy. *Nucl Med Commun* 2010;31:814-20.
6. Al-Saleh S, Al-Arfaj A, Naddaf H, Memish Z. Tuberculous arthritis: A Review of 27 cases. *Ann Saudi Med* 1998;18:368-9.
7. Erdem H, Baylan O, Simsek I, Dinc A, Pay S, Kocaoglu M. Delayed diagnosis of tuberculous arthritis. *Jpn J Infect Dis* 2005;58:373-5.
8. Lakhanpal VP, Tuli SM, Singh H, Sen PC. The value of histology, culture and guinea pig examination in osteo-articular tuberculosis. *Acta Orthop Scand* 1974;45:36-42.
9. Wanjari K, Baradkar VP, Mathur M, Kumar S. Tuberculosis synovitis in a HIV positive patient. *Indian J Med Microbiol* 2009;27:72-5.
10. Shen HL, Xia Y, Li P, Wang J, Han H. Arthroscopic operations in knee joint with early-stage tuberculosis. *Arch Orthop Trauma Surg* 2009;130:357-61.

How to cite this article: Sood A, Sharma A, Chouhan DK, Gupta K, Parghane R, Shukla J, *et al.* Failed radiation synovectomy in diseased knee joint with missed tuberculous synovitis. *World J Nucl Med* 2016;15:206-8.

Source of Support: Nil, **Conflict of Interest:** None declared.