



Contents lists available at ScienceDirect

## International Journal of Surgery Case Reports

journal homepage: [www.casereports.com](http://www.casereports.com)

# Medical Infrared Thermography assistance in the surgical treatment of axillary Hidradenitis Suppurativa: A case report

G. Polidori<sup>a</sup>, Y. Renard<sup>b,1</sup>, S. Lorimier<sup>a,c</sup>, H. Pron<sup>a</sup>, S. Derruau<sup>c,d</sup>, R. Taiar<sup>a,\*</sup><sup>a</sup> GRESPI, EA 4694, Research Group in Engineering Sciences, University of Reims, Reims, France<sup>b</sup> Department of General, Digestive and Endocrine Surgery, Reims University Hospital, Reims, France<sup>c</sup> Faculty of Dentistry, Department of Dendistry, Reims University Hospital, Reims, France<sup>d</sup> MEDYC, UMR CNRS 7369, Biophotonic and Technologies for Health Team, Reims, France

## ARTICLE INFO

## Article history:

Received 24 January 2017

Accepted 10 March 2017

Available online 16 March 2017

## Keywords:

Infrared thermography  
Hidradenitis Suppurativa  
Assisted surgical therapy

## ABSTRACT

**BACKGROUND:** The purpose of this case report is to highlight for the first time the way Medical Infrared Thermography can be a helpful tool to assist the surgeon in the surgical treatment of Hidradenitis Suppurativa inflammatory disease.

**METHODS:** A 36-year-old man with a 7-year history of Hidradenitis Suppurativa presented inflammatory nodules in the left axilla area corresponding to Hurley stage II. Choice is made to surgically treat this patient using a wide excision protocol combined with a postoperative second intention healing. For the study purpose, an IR FLIR SC620 camera (FLIR Systems, Wilsonville, OR), having a high resolution pixel detector of 640 × 480 pixels for greater accuracy and higher resolution, has been used.

**RESULTS:** For the first time in the literature, this case report on HS disease supports the idea that real-time medical infrared thermography may be helpful in establishing the true extent of disease preoperatively in the surgical room and in a similar manner, that this technique allows the surgeon to ensure all diseased lesions are removed during surgery.

**CONCLUSIONS:** At least, medical infrared thermography seems to be a powerful tool to control the final wide surgical wound, in order to minimize recurrence risk of such a disease.

© 2017 The Author(s). Published by Elsevier Ltd on behalf of IJS Publishing Group Ltd. This is an open access article under the CC BY-NC-ND license (<http://creativecommons.org/licenses/by-nc-nd/4.0/>).

## 1. Introduction

Hidradenitis suppurativa (HS) also known as Verneuil's disease is a chronic inflammatory cutaneous disorder that involves the infundibular terminal follicles in areas rich of apocrine glands. It can be associated with recurrent, painful and inflammatory fistulous tracts within the skin, scarring and nodules and abscesses formation [1–3]. HS is a complex disease of difficult management whose aetiology remains unknown and controversial [4]. Hidradenitis Suppurativa (HS) is considered as a life-altering skin disease that affects 1–4 per cent of the world's population, and that is more likely to occur in females in the rate 3–1. Most commonly affected locations are the armpits, groin, buttocks and breasts. The treatments are most appropriately chosen on the basis of disease severity. The Hurley severity classification for HS is useful even if it presents limitations [5].

There are three levels in the management of hidradenitis suppurativa: topical options, systemic options and surgical methods.

\* Corresponding author at: GRESPI EA 4694, Faculty of Sport Sciences, University of Reims Champagne-Ardenne, 51687 Reims Cedex 2, France.

E-mail address: [Redha.taiar@univ-reims.fr](mailto:Redha.taiar@univ-reims.fr) (R. Taiar).

<sup>1</sup> Co-first author.

<http://dx.doi.org/10.1016/j.ijscr.2017.03.015>

2210-2612/© 2017 The Author(s). Published by Elsevier Ltd on behalf of IJS Publishing Group Ltd. This is an open access article under the CC BY-NC-ND license (<http://creativecommons.org/licenses/by-nc-nd/4.0/>).

At each stage, each treatment has shown to be efficient, and may therefore be used either alone or in combination [6]. Operative excision of the involved follicles seems to be the only curative treatment for prevention of recurrence [7]. Guidelines recommend the wide radical excision technique, whenever possible, mainly for Hurley stage II and III lesions [8]. This extensive removal of the affected skin leads to the lowest recurrence rate estimated in the range 0–15% [5,7–9]. One of the major technical points concerns the margin of the excision: an excision not performed in healthy margin may lead to an important recurrence rate up to 79.9% [6,8,10,11].

## 2. Case report

A 36-year-old man with a 7-year history of HS presented inflammatory abscesses in the left armpit area corresponding to Hurley stage II. In December 2012, this patient had ever undergone a surgical treatment for the right axilla area with wide excision surgery and secondary intention healing. He also presented nodules and abscesses in intergluteal and inguinal regions, not surgically treated. The patient exhibited good clinical postoperative evolution and has not had any recurrence for 4 years after surgery. Surgery has been scheduled for left axilla lesions under general anesthesia. He was lying on the supine position the operating table, left arm

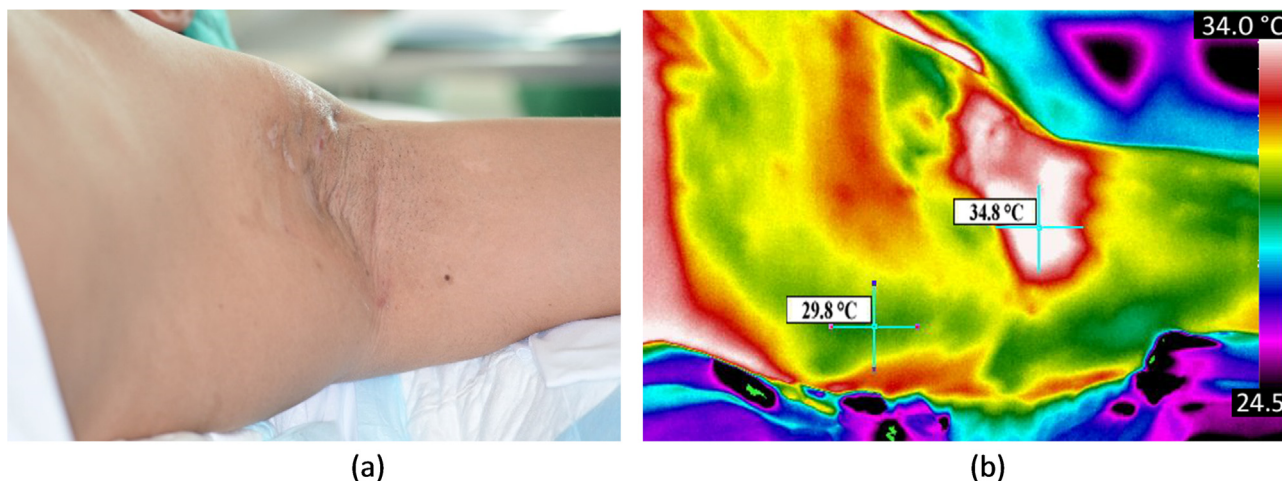


Fig. 1. HS of axillary area, planned for surgical treatment (a); inflammatory area evidenced by IR Thermography after alcohol-based antiseptic solution (b).

extended so that this exposure provided access to the whole zone to be surgically treated (Fig. 1(a)). The secondary intention healing [12] has been the chosen option to close the surgical wound, the wound being left open. Despite a long healing time, this method seems to be satisfactory in wounds up to 20 cm with a high level of acceptance by patients [13] and preferred to others such as skin graft [14] for example in order to minimize the risk of infection occurring when wound is sutured. Although widely used in axillary HS surgical treatments, this secondary intention technique may sometimes induce a contracted scar which disadvantageously causes the arm movements to be reduced. Patient gave his informed consent according to Helsinki Declaration to participate to this research study.

### 3. Discussion

Even though the diagnosis of HS is mainly based on visual inspection and palpation, the role of complementary imaging could be to provide objective and precise information [15] especially in the preoperative step to determine the width of the lateral margins of the surgical excision. However, radiological or nuclear imaging in the diagnosis and management of HS are not so frequently mentioned in the literature and used in clinical practice. Moreover, ultrasound imaging can be a helpful technique in establishing the true extend of disease making more visible clinically identified borders of the lesions compared to clinical examination [16]. Nevertheless this technique is usually not used in the immediate preoperative period and depends on the radiologist analysis. The efficiency of magnetic resonance imaging (MRI) has also been reported in literature in order to not only help define disease extend but also assess coexisting fistulae due to its high contrast resolution [17,18]. Moreover, because HS condition can clinically mimic cutaneous Crohn's disease, MRI can be used to distinguish between these two diseases even if sometimes they can co-exist [19]. First documentation of the appearance of HS on Positron Emission Tomography (PET) scan may also be mentioned [20].

The purpose of this case report is to highlight for the first time the way real-time Medical Infrared Thermography can be a helpful tool to assist the surgeon in the surgical treatment of Hidradenitis Suppurativa inflammatory disease. The advantage of using medical infrared thermography, which is a reliable and noninvasive method to access the skin temperature maps [21,22], is twofold. Firstly it allows to clearly optimize the per-operative mapping of lesion with adequate free margins and secondly it can be used to control after excision surgery if all the affected tissues are removed. To the best

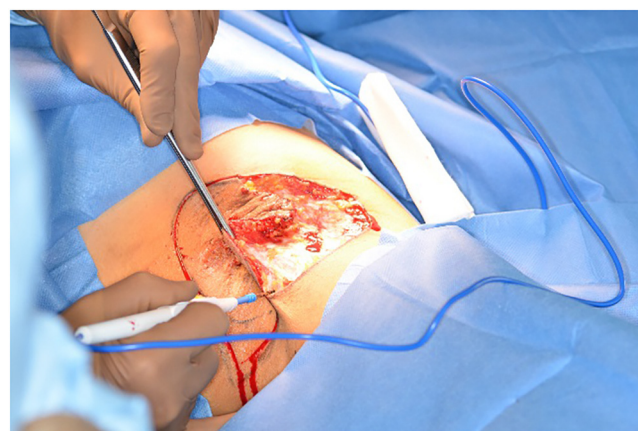


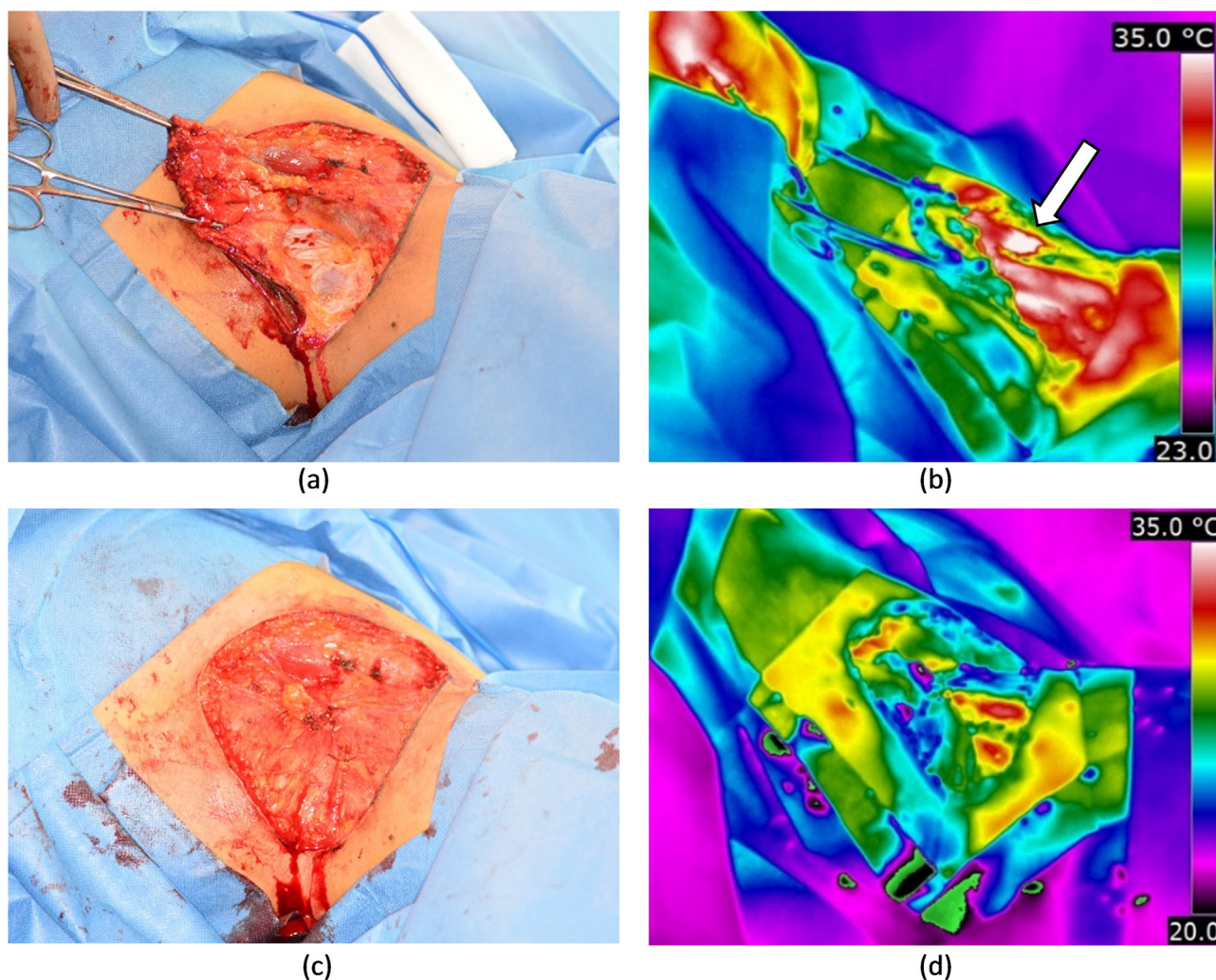
Fig. 2. Skin incision with electric scalpel (Erbe VIO.300 D).

of the authors knowledge, it is the first time such complementary imaging method is used in HS surgical procedure.

For this purpose, an IR FLIR SC620 camera (FLIR Systems, Wilsonville, OR), having a high resolution pixel detector of  $640 \times 480$  pixels for greater accuracy and higher resolution, has been used. Before draping the surgical incision site, the preoperative skin area is prepared with an alcohol-based antiseptic solution. Presence of alcohol on the skin in the preoperative step has a major incidence of the perfect identification of the incision area evidenced by infrared thermography. Indeed, alcohol is a volatile liquid which, due to the process of phase change by evaporating, is going to store the heat latent of the surrounding air and consequently to cool it. The skin being in direct contact of this colder air is going to cool also in an important way by increasing artificially temperature gaps and making more visible differences between inflammatory subcutaneous diseased tissues and healthy surrounding ones. This phenomenon is clearly evidenced in Fig. 1(b).

The identification by Infrared Thermography of the thermal area can then allow the surgeon to optimize its intervention and the compromise which he has to face, namely by considering a too small incision area and deduced risk to not radically remove all HS tissues and on the other hand by considering a too large incision area which will increase in an important way the healing time. Once drawn the skin incision lines with a margin of safety of 1 cm beyond the clinical border of activity, the incision is deepened through the skin and subcutaneous tissues till the fascia, as seen in Fig. 2.





**Fig. 3.** Excision process (a); corresponding IR thermography showing residual diseased lesion evidenced with the white arrow (b); end of the surgery (c); thermal verification of the final wide wound (d).

Medical Infrared Thermography also enables to efficiently evidence diseased tissues which would not have been completely removed during surgical excision process (Fig. 3(a) and (b)). Even if these tissues are stripped and visible, the metabolism process responsible to inflammation continues to act and consequently to thermally distinguish between healthy tissues and affected ones. The real-time thermography in Fig. 3(b) clearly highlights a white colored spot (evidenced by a white arrow on the thermal photography) corresponding to the presence of residual diseased tissue which was not curatively removed. The surgeon can then surgically treat this lesion.

Moreover, after the completion of surgery (Fig. 3(c) and (d)), the infrared thermography can also act like a control tool to verify if diseased inflammatory lesions still remain inside the wound. Fig. 3(d) reveals that no residual diseased lesion still remain after surgery. It should be specified in Fig. 3(d) that the two red spots do not correspond especially to lesions but to both axillary artery and vein.

#### 4. Conclusion

For the first time in the literature, this case report on HS disease supports the idea that real-time medical infrared thermography may be helpful in establishing the true extent of disease preoperatively in the surgical room and in a similar manner, that this

technique allows the surgeon to ensure all diseased lesions are removed during surgery. At least, medical infrared thermography seems to be a powerful tool to control the final wide surgical wound, in order to minimize recurrence risk of such a disease. In such a way, medical infrared thermography could be a convenient and easy alternative way to usual anatomopathology analyses of excised tissues, one of the objectives being to verify the lack of diseased tissues crossing the excision margins.

#### Conflicts of interest

The authors declare that there is no conflict of interests regarding the publication of this paper.

#### Funding

No source of funding.

#### Ethical approval

Ethics committee approval was not required for this case report.

## Consent

Informed consent was obtained from the patient in written and verbal form.

## Authors contribution

Guillaume Polidori, Hervé Pron: realizing the IR thermography experiments and contributed to drafting and critical review.

Yohann Renard: participating in the surgery treatment and management, interpretation and critical revision.

Sandrine Lorimier and Stéphane Derruau. Participating in the research conception and design.

Redha Taiar. Contributing to analysis and interpretation and drafting.

## Registration of research studies

No registry.

## Guarantor

Redha Taiar.

## Disclosure

The authors report no proprietary or commercial interest in any product mentioned or concept discussed in this article.

## Acknowledgments

The authors wish to thank the Director of the Reims University Hospital, the Head of the Department of General, Digestive and Endocrine Surgery as well as the medical staff of the operating room who have facilitated the implementation of the IR Thermography experiments.

## References

- [1] Z. Alharbi, J. Kauczok, N. Pallua, A review of wide surgical excision of hidradenitis suppurativa, *BMC Dermatol.* (2012) 12–19.
- [2] B.B. Dhaou, F. Boussema, Z. Aydi, L. Baili, L. Rokbani, Hidradenitis suppurativa (Verneuil's disease), *J. Saudi Soc. Dermatol. Surg.* 17 (2013) 1–5.
- [3] N. Mukai, L.V. Pinheiro, M. de Lourdes Setsuko Ayrizono, G.C. Barreiro, P. Kharmandayan, M.H. Akinaga, A.M. Bento, C.A.R. Martinez, R.B. de Carvalho, M. Ward, C.S.R. Coy, R.F. Leal, Mucinous adenocarcinoma associated with chronic suppurative hidradenitis: report of a case and review of the literature, *Int. J. Surg. Case Rep.* 26 (2016) 12–16.
- [4] S. Ather, D.S.Y. Chan, D.J. Leaper, K.G. Harding, Surgical treatment of hidradenitis suppurativa: case series and review of the literature, *Int. Wound J.* 3 (2006) 159–169.
- [5] H.H. Van der Zee, G.B.E. Jemec, New insights into the diagnosis of hidradenitis suppurativa: clinical presentations and phenotypes, *J. Am. Acad. Dermatol.* 73 (2015) S23–S26.
- [6] S. Yazdanyar, G.B. Jemec, Hidradenitis suppurativa: a review of cause and treatment, *Curr. Opin. Infect. Dis.* 24 (2) (2011) 118–123.
- [7] R.J. Kagan, K.P. Yakuboff, P. Warner, G.D. Warden, Surgical treatment of hidradenitis suppurativa: a 10-year experience, *Surgery* 138 (2005) 734–740.
- [8] C.C. Zouboulis, N. Desai, L. Emtestam, et al., European S1 guideline for the treatment of hidradenitis suppurativa/acne inversa, *J. Eur. Acad. Dermatol. Venereol.* 29 (2015) 619–644.
- [9] A. Mehdizadeh, P.G. Hazen, F.G. Bechara, N. Zwingerman, M. Moazenzadeh, M. Bashash, R.G. Sibbald, A. Alavi, Recurrence of hidradenitis suppurativa after surgical management: a systematic review and meta-analysis, *J. Am. Acad. Dermatol.* 73 (5) (2015) S70–S77.
- [10] L.Z. Ellis, Hidradenitis suppurativa: surgical and other management techniques, *Dermatol. Surg.* 38 (4) (2012) 517–536.
- [11] D.C. van Rappard, J.E. Mooij, J.R. Mekkes, Mild to moderate hidradenitis suppurativa treated with local excision and primary closure, *J. Eur. Acad. Dermatol. Venereol.* 26 (7) (2012) 898–902.
- [12] L.S. Humphries, E. Kueberuwa, M. Beederman, L.J. Gottlieb, Wide excision and healing by secondary intent for the surgical treatment of hidradenitis suppurativa: a single-center experience, *J. Plast. Reconstr. Aesthet. Surg.* 69 (2016) 554–566.
- [13] A. Bienek, Y. Matusiak, D. Okulewicz-Gojlik, J.C. Szepietowski, Surgical treatment of hidradenitis suppurativa: experiences and recommendations, *Dermatol. Surg.* 36 (2010) 1998–2004.
- [14] J.C.R. Wormald, A. Balzano, J.J. Clibbon, A. Figus, Surgical treatment of severe hidradenitis suppurativa of the axilla: thoracodorsal artery perforator (TDAP) flap versus split skin graft, *J. Plast. Reconstr. Aesthet. Surg.* 67 (2014) 1118–1124.
- [15] X. Wortsman, Imaging of hidradenitis suppurativa, *Dermatol. Clin.* 34 (2016) 59–68.
- [16] X. Wortsman, G.B.E. Jemec, Real-time compound imaging ultrasound of hidradenitis suppurativa, *Dermatol. Surg.* 33 (11) (2007) 1340–1342.
- [17] F. Poe, S.K. Wong, Imaging of hidradenitis suppurativa and its complications, *Case Rep. Radiol.* (2014), ID 294753.
- [18] H. Takiyama, S. Kazama, Y. Tanoue, K. Yasuda, K. Otani, T. Nishikawa, T. Tanaka, J. Tanaka, T. Kiyomatsu, K. Hata, K. Kawai, H. Nozawa, T. Miyagawa, D. Yamada, H. Yamaguchi, S. Ishihara, E. Sunami, T. Watanabe, Efficacy of magnetic resonance imaging in the diagnosis of perianal hidradenitis suppurativa, complicated by anal fistulae: a report of two cases and review of the literature, *Int. J. Surg. Case Rep.* 15 (2015) 107–111.
- [19] N. Griffin, K.M. Taylor, A.B. Williams, S.H. Anderson, P.M. Irving, J.D. Sanderson, N. Desai, V. Goh, PWE-067 MRI to distinguish hidradenitis suppurativa from perianal Crohn's disease, *Gut* 61 (2012) 1324–1325.
- [20] R.C. Simpson, M.J.S. Dyer, J. Entwisle, K.E. Harman, Positron emission tomography features of hidradenitis suppurativa, *Br. J. Radiol.* 84 (1004) (2011) e164–e165.
- [21] B.B. Lahiri, S. Bagavathiappan, T. Jayakumar, J. Philip, Medical applications of infrared thermography: a review, *Infrared Phys. Technol.* 55 (2012) 221–235.
- [22] D. Alexandre, M. Prieto, F. Beaumont, R. Taiar, G. Polidori, Wearing lead aprons in surgical operating rooms: ergonomic injuries evidenced by infrared Thermography, *J. Surg. Res.* 209 (2017) 227–233.

## Open Access

This article is published Open Access at [sciencedirect.com](https://www.sciencedirect.com). It is distributed under the [IJSCR Supplemental terms and conditions](#), which permits unrestricted non commercial use, distribution, and reproduction in any medium, provided the original authors and source are credited.