

A rare case of primary urachal actinomycosis mimicking malignancy

T Ayesha Sithika, Hemalatha Ganapathy, AR Subashree

Department of Pathology, Sree Balaji Medical College, Chennai, Tamil Nadu, India

ABSTRACT

Primary actinomycosis occurring in urachal remnants is rarely documented in literature and may mislead the clinicians to diagnose urachal carcinoma. A 50-year-old man came with complaints of lower abdominal pain, dysuria, and dribbling of urine for 2 months. A vague mass of 7 cm was palpable in the suprapubic region. Imaging of the abdomen revealed an irregular mass seen superior to fundus of the urinary bladder appearing adherent to mesentery and bowel loops, suggesting an urachal remnant associated lesion with infiltration. Provisional diagnosis of urachal carcinoma was considered. Excision of the mass with partial cystectomy and resection of involved ileal segments were done. Microscopic examination revealed actinomycotic colonies surrounded by microabscesses and dense inflammatory fibrotic lesion. Small intestinal segments showed a similar lesion in the serosa.

Key words: Actinomycosis, urachal remnants, urachal tumor

Submission: 13-12-2015 **Accepted:** 12-10-2016

INTRODUCTION

Actinomycosis is an infrequent invasive chronic inflammatory disease caused mainly by *Actinomyces israelii*, Gram-positive, filamentous, anaerobic bacteria. It occurs more commonly in the oral cavity, followed by gastrointestinal tract.^[1] Actinomycosis occurring primarily in urachal remnants is rare and may mislead the clinicians to diagnose urachal carcinoma.^[2] We report one such case of urachal actinomycosis in a 50-year-old male with lower abdominal pain and mass palpable mimicking a urachal tumor.

CASE REPORT

A 50-year-old man, hailing from South India, came to the Urology outpatient department with complaints of lower

abdominal pain, dysuria, and dribbling of urine for 2 months duration. He had no history of fever or discoloration of urine. He had a history of appendectomy done 10 years back. Clinically, he was afebrile and per-abdomen examination revealed a vague mass of 7 cm palpable at the suprapubic region.

Umbilicus was normal with no discharging sinuses. Complete blood count showed a notable white blood cell count of 22,100/cumm. Other blood and urine investigations were within normal limits. Computed tomography scan of the abdomen revealed an irregular mass seen superior to fundus of urinary bladder appearing adherent to mesentery and bowel loops and suggested an urachal remnant associated lesion with infiltration [Figure 1]. Provisional diagnosis of urachal carcinoma was made. Excision of the mass with partial cystectomy and resection of involved ileal segments was done [Figure 2]. The specimen was sent for histopathological examination.

Address for correspondence: Dr. T Ayesha Sithika,
No. 7, CLC Works Road, Chrompet, Chennai - 600 044,
Tamil Nadu, India.
E-mail: dr.ayeesha1@gmail.com

Access this article online	
Quick Response Code:	Website: www.ijabmr.org
	DOI: 10.4103/2229-516X.198538

This is an open access article distributed under the terms of the Creative Commons Attribution-NonCommercial-ShareAlike 3.0 License, which allows others to remix, tweak, and build upon the work non-commercially, as long as the author is credited and the new creations are licensed under the identical terms.

For reprints contact: reprints@medknow.com

How to cite this article: Sithika TA, Ganapathy H, Subashree A. A rare case of primary urachal actinomycosis mimicking malignancy. Int J App Basic Med Res 2017;7:77-9.

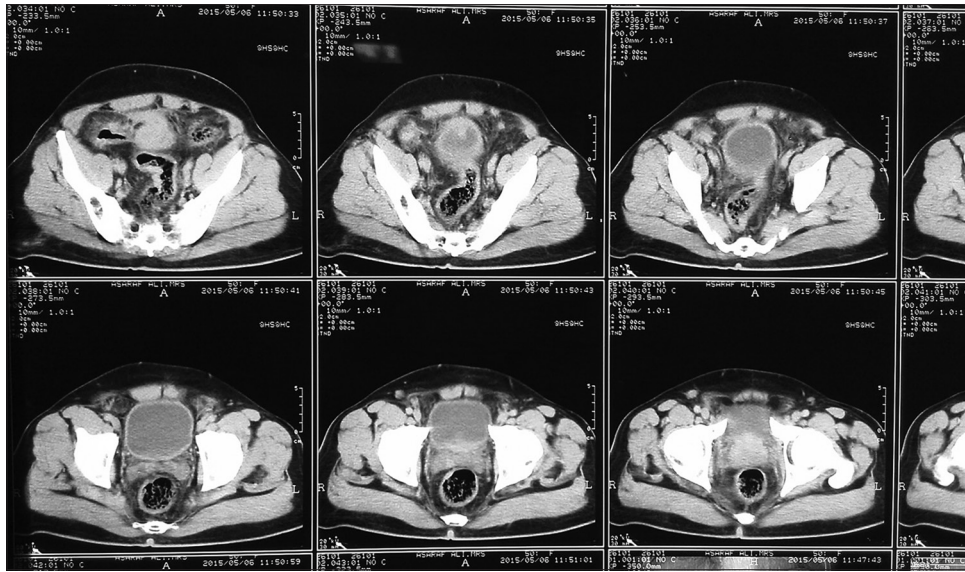


Figure 1: Computed tomography of the abdomen showing an irregular mass seen superior to fundus of urinary bladder appearing adherent to mesentery and bowel loops

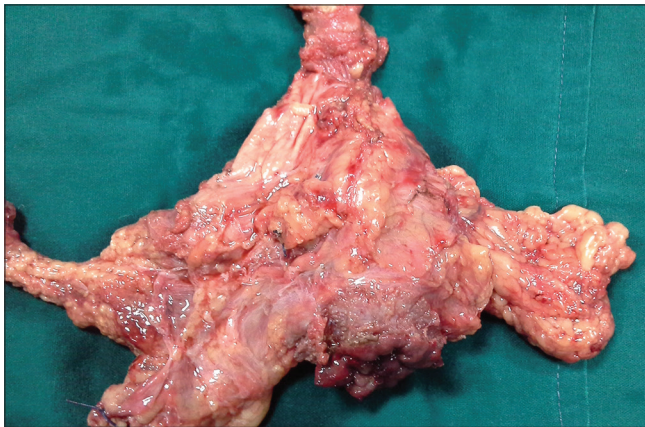


Figure 2: Excised mass

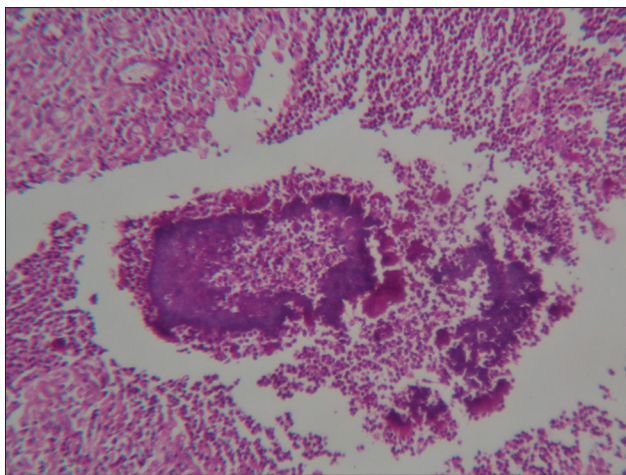


Figure 3: Photomicrograph showing high power view of H and E section of actinomycotic colonies surrounded by microabscesses

Grossly, we received an irregular soft tissue mass measuring 12 cm × 15 cm × 4 cm with umbilicus on the one side and dome

of the bladder on the other side. Cut surface of it showed a yellowish necrotic and sinus like openings. We also received two loops of intestine with attached serosal mass measuring 4 cm × 3 cm × 2 cm. After adequate sampling, sections from the urachal remnant revealed actinomycotic colonies surrounded by microabscesses and dense inflammatory fibrotic lesion [Figure 3]. Small intestinal segments showed a similar lesion in the serosa but not in the mucosa, confirming it to be a primary urachal actinomycosis. They stained positively with periodic acid-Schiff stain.

The patient was started on intravenous penicillin and recovered without complications.

DISCUSSION

Abdominal-pelvic actinomycosis accounts for 3% of all actinomycotic infections. The most common risk factor includes use of intrauterine contraceptive devices in female, and others include history of bowel surgery such as perforated acute appendicitis, perforated colonic diverticulitis, penetrating trauma to the abdomen, and persistent urachal remnant.^[3] Our patient showed two of the risk factors of persistent urachal remnant and an earlier appendectomy. It spreads by direct extension where the mucosal barrier is breached.

Patients usually have symptoms of lower abdominal pain, palpable hard mass with induration. The infiltrative nature of the bacteria into the surrounding organs can be explained by production of proteolytic enzyme. There are no specific radiological signs to distinguish actinomycotic lesions from malignancy due to its infiltrative nature.^[4] Its varied

clinical and radiological features mislead the clinicians to the diagnosis of malignancy. Definite diagnosis before surgery is difficult unless patient had discharging sinuses in the lower abdomen. Our patient had no discharging sinuses. Demonstration of the colonies of actinomycosis by histopathological examination is the definitive diagnosis, and hence, adequate sampling and extensive scanning must be done.^[5]

In a study of 33 patients with pelvic actinomycosis by Marella *et al.*, 19 patients had intrauterine contraceptive devices and only four of them had urachal remnants. Cystoscopy was done in 12 of them which predominantly showed extrinsic mass effect. Exploratory laparotomy was done in most of them, and definite diagnosis was made by histopathological examination after excision of the mass. Penicillin therapy was given.^[6]

CONCLUSION

One should be aware of this infectious disease mimicking malignancy in its clinical presentation. It has a good prognosis and is curable with antibiotics such as penicillin and amoxicillin. It is important to consider it in the differential diagnosis of patients presenting with lower abdominal pain and hard suprapubic mass with or without discharging sinuses. To the best of our knowledge, very few cases of

primary urachal actinomycosis are reported in International literature.

Acknowledgment

We thank Dr. Jeyaraman and Dr. Praveen Kumar for their support.

Financial support and sponsorship

Nil.

Conflicts of interest

There are no conflicts of interest.

REFERENCES

1. Cintron JR, Del Pino A, Duarte B, Wood D. Abdominal actinomycosis. *Dis Colon Rectum* 1996;39:105-8.
2. Maddah G, Feizzdeh Kerigh B, Mohamadian N, Bagheri V. Primary urachal actinomycosis: Case report and literature review. *Nephrourol Mon* 2013;5:997-1000.
3. Awe J, Soliman AM. Abdomino-pelvic actinomycosis of urachal remnant mimicking lower abdominal tumour. *Glob Adv Res J Med Med Sci* 2013;2:247-51.
4. Li MF, Yang TL, Huang JS. Imaging findings of primary urachal actinomycosis. *J Chin Med Assoc* 2011;74:44-7.
5. Chaitra V, Rajalakshmi T, Mohanty S, Lahoti NK, George A, Idiculla J. Actinomycosis in urachal remnants: A rare cause of pseudotumor. *Indian J Urol* 2011;27:545-6.
6. Marella VK, Hakimian O, Wise GJ, Silver DA. Pelvic actinomycosis: Urologic perspective. *Int Braz J Urol* 2004;30:367-76.