

# Clinical profile and follow-up of 51 pediatric neurocysticercosis cases: A study from Eastern India

Shakya Bhattacharjee, Prativa Biswas<sup>1</sup>, Tanushree Mondal<sup>2</sup>

Departments of Neurology, Mater Misericordiae University Hospital, Dublin - 7, Ireland, <sup>1</sup>Pediatrics, R.G. Kar Medical College and Hospital, Kolkata, <sup>2</sup>Community Medicine, N.R. Sarkar Medical College and Hospital, Kolkata, West Bengal, India

## Abstract

**Introduction:** Our present observational study attempted to evaluate the clinical profiles, diagnosis, treatment and follow-up results of 51 pediatric neurocysticercosis patients over a mean duration of five years (from January 2006 to December 2010). **Materials and Methods:** Diagnosis was mainly based on clinical features, computed tomography (CT)/magnetic resonance imaging scan and exclusion of other causes. Patients with active, transitional cysts and seizure were treated with albendazole for 28 days, steroids and anticonvulsants. **Results:** A total of 38 patients completed this study. Mean age of the presentation was  $8.47 \pm 3.19$  years 52.6% of the patients were female. Overall patients presented with generalized seizure in 55.3%, focal in 31.6%, headache  $\pm$  vomiting in 63.2%, focal neurodeficit in 10.5% and combination of symptoms in 60.5% cases. Contrast CT brain showed a solitary lesion in 27 (71.1%) and multiple in the rest. At presentation lesions were transitional in 58.2%, inactive in 20% and mixed in 14.6%. After a mean of 2 years, seizure persisted in 9 (23.7%) and headache in 8 (21.1%) of whom six had normal electroencephalography (EEG) while one each showed focal slowing, generalized slowing and epileptiform discharges. During the follow-up, CT scan brain 44.7% lesions calcified, 31.6% disappeared, 10.5% regressed and the rest persisted. **Conclusion:** Solitary ring enhancing lesions (transitional stage) involving the parietal lobe was the commonest CT picture at presentation. Generalized tonic-clonic seizure was the most common type of seizure. Number of lesions, persistence of lesion, number of seizures, EEG abnormality at presentation were not found to be prognostically significant ( $P > 0.05$ ).

## Key Words

Brain, epilepsy, lesion, neurocysticercosis, parenchyma, solitary

## For correspondence:

Dr. Shakya Bhattacharjee, Beaumont Hospital, Dublin - 18, Ireland.  
E-mail: bubai.shakya@gmail.com

*Ann Indian Acad Neurol 2013;16:549-55*

## Introduction

Human cysticercosis, an infection by the larval stage (cysticercus) of the pork tapeworm *Taenia solium*, is the most common parasitic central nervous infection world-wide.<sup>[1,2]</sup> Though, it affects adults commonly, pediatric infection is also well-recognized. Most of the cases have been reported from South East Asia, Central and Latin American nations.<sup>[2-6]</sup> Our present study attempts to assess the clinical features, diagnostic modalities available with special emphasis on imaging modalities, treatment outcome and follow-up of pediatric neurocysticercosis cases over a mean duration of 2 years from January 2006 to December 2010.

## Materials and Methods

The study was carried out in the Department of Neurology OPD, R.G. Kar Medical College and Hospital, Kolkata, India and in the pediatrics indoor (same college). Seizure patients with computed tomography (CT) scan brain showing active or ring enhancing lesions or mixed lesions (any combination of active, ring enhancing, calcified) were included. Newly diagnosed childhood seizure patients with only calcified lesion on CT scan brain during the presentation were excluded from the study. The study period was from January 2006 to December 2010.

The children (where possible), their parents and witnesses were interviewed separately with the help of a predesigned questionnaire. Every patient's parents and legal guardians confirmed participation in the study freely and voluntarily.

Initially, 51 children were found eligible for the study, but ultimately after a mean duration of 2 years only 38 children could be followed-up as the rest 13 dropped out at various stages of the study. Statistical analysis was performed only on those 38 cases.

### Access this article online

#### Quick Response Code:



#### Website:

www.annalsofian.org

#### DOI:

10.4103/0972-2327.120463

No separate diagnostic criteria have been laid down for pediatric neurocysticercosis so the adult criteria of Del Brutto *et al.*, were followed in our study.<sup>[7]</sup> According to those criteria, either one absolute criteria or a combination of 2 major, 2 minor and 1 epidemiologic criterion are necessary for the definitive diagnosis [Table 1]. Probable diagnosis is made by 1 major plus 2 minor or 1 major plus 1 minor plus 1 epidemiologic criterion or 3 minor plus 1 epidemiologic criterion. Among those who finished the study 25 definite cases were diagnosed by the combination criteria, 4 definite cases were diagnosed with major criterion. Nine cases were diagnosed as probable. Eight of those who defaulted at various stages were diagnosed as definite cases with combination criteria, five cases were diagnosed as probable.

Serum immunoglobulin M and immunoglobulin G enzyme-linked immunosorbent assay against cysticercus study were done only in six cases as it is not an integral part of diagnosis in Del Brutto criteria.<sup>[7]</sup> Serological result (antibody titer against cysticercus) was considered as diagnostic when the serum titer was  $\sim 1:160$ .<sup>[4]</sup> It was supported by other investigations like magnetic resonance imaging (MRI) of brain, electroencephalography (EEG), stool microscopy for ova, cysts and parasites, absolute eosinophil count. Chest X-ray, Mantoux test, sputum and gastric lavage for acid fast bacilli were also performed to rule out tuberculosis, tuberculous meningitis or tuberculoma, a very common differential diagnosis in India.

MRI brain was done only in multiple lesion cases (11 in number) already detected by CT scan brain. Number of lesions were counted in CT scan and the disease activity was classified as active (appearance on CT as hypodense cyst without enhancement), transitional (appearance of a ring or nodular shadow with contrast enhancement) and inactive (calcified lesions) based on the viability of the parasite as proposed by Carpio *et al.* [Figure 1].<sup>[8,9]</sup>

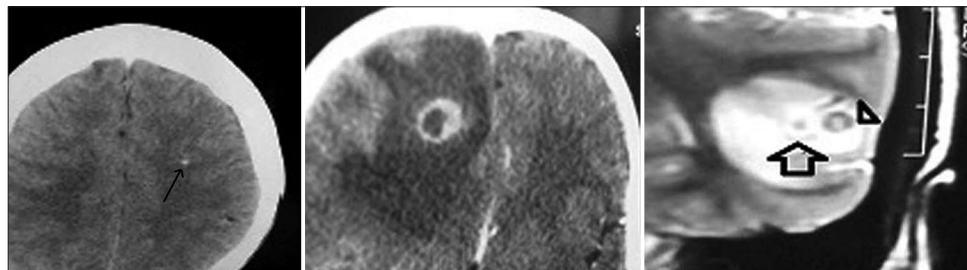
Patients with active, transitional or mixed cysts and seizure, i.e., all 38 patients were treated with oral albendazole (15 mg/kg/day in two divided doses with the maximum dose 800 mg/day) for total duration of 28 days as definitive therapy for active and transitional cysts.<sup>[1,10]</sup> All patients who were begun albendazole therapy, irrespective of any features of raised intracranial tension (ICT) were given oral prednisolone (1 mg/kg/dose with the maximum dose of 50 mg/day) 48 h before starting albendazole therapy as seizure may be precipitated by the

introduction of albendazole because of inflammatory reaction by the breakdown of cysts.<sup>[1]</sup> Prednisolone was continued for a total period of 30 days, i.e., until the albendazole therapy was continued. After 18 days of 1 mg/kg/day Prednisolone therapy the dose was reduced by 10 mg every 4<sup>th</sup> day and withdrawn in next 10 days. The drugs used for control of immediate seizure were diazepam and phenytoin.

After discharge, patients were advised oral phenytoin. Phenytoin was started @ 5 mg/kg/day in two or three divided doses with maximum dosage of 300 mg/day. All patients presenting with seizure were continued phenytoin for at least 2 years unless some unacceptable side effects were observed. However, in recurrent seizure cases, persistent lesions and in seizure-free patients with calcification of cysts, phenytoin was continued for a longer period.

**Table 1: Diagnostic criteria for human cysticercosis**

<b>Absolute criteria</b>	
Demonstration of cysticerci by histologic or microscopic examination of biopsy material	
Visualization of the parasite in the eye by fundoscopy	
Neuroradiologic demonstration of cystic lesions containing a characteristic scolex	
<b>Major criteria</b>	
Neuroradiologic lesions suggestive of neurocysticercosis	
Demonstration of antibodies to cysticerci in serum by enzyme-linked immunoelectrotransfer blot	
Resolution of intracranial cystic lesions spontaneously or after therapy with albendazole or praziquantel alone	
<b>Minor criteria</b>	
Lesions compatible with neurocysticercosis detected by neuroimaging studies	
Clinical manifestations suggestive of neurocysticercosis	
Demonstration of antibodies to cysticerci or cysticercal antigen in cerebrospinal fluid by ELISA	
Evidence of cysticercosis outside the central nervous system (e.g., cigar-shaped soft tissue calcifications)	
<b>Epidemiologic criteria</b>	
Residence in a cysticercosis-endemic area	
Frequent travel to a cysticercosis-endemic area	
Household contact with an individual infected with <i>Taenia solium</i>	
Definite diagnosis: 1 absolute criterion or two major criteria+minor criterion,+one epidemiologic criterion	
Probable diagnosis: 1 major+2 minor or 1 major+1 minor+1 epidemiologic criterion or 3 minor+1 epidemiologic criterion	



**Figure 1:** Left hand figure: Plain computed tomography scan brain showing calcified cyst of the left parietal cortex (narrow single line arrow) middle figure: CT scan brain showing ring enhancing lesion (transitional cyst) of the right frontal lobe with perilesional edema with doubles from 1 to 6 O' clock position right hand figure: Magnetic resonance imaging brain (T2-weighted) showing an active cyst (double line black arrow) and transitional cyst demonstrating a scolex as white dot (triangular black arrow head)

Follow-up protocol included regular clinical evaluation, repeat CT scan at intervals of 6 weeks, 6 months and 24 months, EEG during first diagnosis and after 24 months. Repeat CT scans were compared with the first one. The above treatment and follow-up is the protocol followed in our institution. It was just an observational study with no use of identifiable patient data or drug trial, but still institutional ethical committee clearance was obtained.

Regression of lesion in CT scan was defined as a reduction in number or size 50% of the original lesion. Persistence of lesions was defined as no reduction in number and reduction if size <50% of the original.<sup>[9]</sup> The size/diameter of the lesions was measured by the inbuilt ruler provided by the CT scan software and was compared with the old data of the same patient stored in the computer. The data were evaluated in terms of clinical presentation, investigation findings, response to therapy and follow-up.

Microsoft office XL2010 and statistical SPSS 16 (IBM Corporation) software version 3.2.1 were used for statistical calculation. Categorical data were analyzed by Chi-square test with Yates's correction factor for small numbers. A *P* value less than 0.05 was considered as statistically significant.

## Results

Though initially, the cohort had 51 patients 13 dropped out at different stages of the study. The youngest child was 4 years old. Nine children belonged to 10-12 years old age group. Among the 13 children who dropped out 10 gave the history suggestive of focal seizure and three of generalized seizure at presentation. None showed any neurodeficit.

Among those 38 patients who completed the study the mean age of onset of symptoms was 8.47 years with a range of 1-13 years. 20 patients were female while 18 were male. 10-12 years age group was the commonest age group to be involved (36.8%) followed by 4-6 year age group (23.6%). Only one case of below 2 year age group could be found. 94.7% children belonged to lower socio-economic status. Seven were pure vegetarians and the rest were non-vegetarians, but most of them never took pork as this habit is not a socially prevalent custom in India.

Among these 38 patients seizures was overwhelmingly the most common initial presentation seen in 36 cases (94.7%). Simple partial seizure was seen in 31.6% of cases at presentation, complex partial seizure in 7.9% cases while generalized tonic-clonic seizures were observed in 21 (55.3%) cases at presentation [Table 2].

Interestingly generalized tonic-clonic seizure at presentation was higher among males. 11 out of 18 (61.1%) boys presented with generalized tonic-clonic seizure, whereas 10 out of 20 (50%) girls had generalized seizure at presentation. Complex partial seizure was higher among females (10% in girls and 5.6% in boys). Simple partial seizure was also more common among female. 7 of 20 (35%) girls had simple partial seizure at presentation while 27.7% male children had simple partial seizure as initial presenting symptoms.

**Table 2: Number, type, parenchymal site of lesions, EEG and eosinophil count at presentation of the 38 patients completing the study**

Symptoms at presentation	N (%) of total (n=38) (male 18, female 20)
Seizures	36 (94.7)
Male	16 (42)
Female	20 (58)
Simple partial (total)	12 (31.6)
Simple partial (male)	5 (13.2)
Simple partial (female)	7 (18.4)
Complex partial (total)	3 (7.9)
Complex partial (male)	1 (2.6)
Complex partial (female)	2 (5.3)
Generalized tonic-clonic seizure (total)	21 (55.3)
Generalized seizure (male)	11 (29)
Generalized seizure (female)	10 (26.3)
Headache with or without vomiting	24 (63.2)
Neuropsychiatric manifestations	2 (5.3)
Cranial nerve palsy/focal neurodeficit	4 (10.5)
Combination of symptoms	23 (60.5)

EEG=Electroencephalography

Generalized tonic-clonic seizure was probably due to secondary generalization of the focal seizure given the focal nature of the lesion. In 17 out of the 36 cases, seizures initially appeared in a cluster of 2-4 episodes and in two cases as status epilepticus. Symptoms of raised intracranial tension like headache with or without vomiting were there in 63.2% cases at initial presentation. Two children showed neuropsychiatric disturbances in the form of violent behavior, irrelevant talking.

Amidst the drop outs CT scan brain at presentation revealed active lesion in two patients, transitional lesion in 10 cases and mixed in one patient. Total 15 lesions were detected from CT scan at the presentation nine of which were noted in the parietal lobe, five in the frontal lobe and one in the occipital lobe. Eight never turned up at the 6<sup>th</sup> week of follow-up, five attended after the mean duration of 6<sup>th</sup> week, but only one came at 6<sup>th</sup> month and none after a mean duration of 2 years. Out of the five patients who attended after 6 weeks three had calcification, one had persistence of lesion and one had regression in the cyst size.

Out of the 38 patients who completed the study 71% patients showed solitary lesion while the rest revealed multiple (>2) lesions at different stages of development [Table 3] in the CT scan brain. Amongst the solitary lesions parietal lobe was the most common site of involvement (74.1%) followed by frontal lobe involvement around 15% cases. Eleven children had multiple lesions in the CT brain. Amid the multiple lesions three were found in the frontal lobe, 17 in the parietal lobe and three in the occipital lobe. Combining solitary and mixed, 55 lesions were noted in total of which 37 showed either parietal lobe involvement [Table 3]. Overall transitional stage lesion was the most common CT finding comprising almost 67% cases presenting as ring enhancing lesions, inactive lesion in 25% cases. None of the cases revealed ventricular involvement or "starry sky" appearance. 9 (23.7%) cases revealed the presence of scolex in the form of eccentric nodules, 23 (60.5%) cases

revealed perilesional edema on CT/MRI at presentation. Only in 2 out of the 11 multiple NCC patients who underwent both imaging modalities, MRI picked up more lesions than CT scan.

All EEG data were interpreted in conjunction with clinical presentation. In the 38 patients participating until the end epileptic discharge was noted in eight cases and non-specific abnormality in 13 cases [Table 3]. Widespread high frequency interictal epileptiform activity was noted in each of two patients with solitary frontal lobe lesion, three patients with solitary parietal lobe lesion lesions and one patient with more than one lesion. Two patients with parietal lobe lesion showed site specific focal spike wave discharges. Among the non-specific abnormalities focal slow wave activity was observed in three children, focal attenuation in two cases, generalized attenuation in two cases, generalized slowness in four children, triphasic wave in one case and small spike in one patient. Among

the eight epileptic discharges only two parietal lobe lesions corresponded to the site of spikes. However, non-specific abnormalities did not correspond to the location of the lesion in the brain parenchyma [Table 3a].

Stool microscopy revealed the presence of ova in 44.7% cases. Peripheral blood eosinophilia was observed in around 33% cases [Table 3].

If the initial cohort of 51 patients were considered together rather than the 38 patients completing the study still then more than 70% of the lesions were solitary and parietal lobe was the location of almost 70% of the solitary cysts. Transitional type was found in more than 71% of the cysts on CT scan brain [Table 4].

At the mean of 6<sup>th</sup> week of follow-up seizure disappeared in 16 cases while at the end of 24 months only nine cases had persistent seizure. Initially, 24 cases presented with headache with or without vomiting, but at the 6<sup>th</sup> month of follow-up those symptoms could only be found in 11 cases. 8 (21.1%) cases complained of headache with or without vomiting after 2 years. At presentation four cases showed focal neurodeficit (right 6<sup>th</sup> cranial nerve palsy in one case and three cases of the upper arm paresis), but none showed any residual neurodeficit from the 6<sup>th</sup> week onward. Only two children at presentation had abnormal behavior in the form of violent attitude, irrelevant talking and forgetfulness and poor performance at school, but at the end of mean of 2 year they recovered completely.

Out of the eight cases of headache after 2 years five had calcification of lesions while three had complete disappearance of the cyst. No EEG abnormality was found in five out of these eight patients while focal slowing, generalized slowing and epileptiform discharges were found in one each.

Those 38 patients were examined clinically and radiologically with contrast CT brain at a mean duration of 6<sup>th</sup> week, 6<sup>th</sup> month and 24<sup>th</sup> month of follow-up with EEG at the beginning and after 24 months. After a mean of 2 years calcification was noted in 44.7% cases and lesions disappeared in 31.6% cases.

Mean age of onset of seizure for patients who had persistent seizure after a mean of 2 years was  $8.44 \pm 3.004$  years. Patients who were seizure free after a mean of 2 years had mean age of onset of seizure of  $8.71 \pm 3.29$  years. Only one child with persistent seizure showed epileptiform discharge (widespread fast waves) and three showed non-epileptiform

**Table 3: Number, type, parenchymal site of lesions, EEG and eosinophil count at presentation**

Lesion (number, location, type) and EEG changes	Absolute Number and percentage in each group
Type of lesions (n=38)	Number of children (%)
Single	27 (71.1)
Multiple (frontal+both parietal+temporal+occipital)	11 (8+17+0 + 3) (28.9)
Site of solitary lesion (n=27)	Number of lesions (%)
Frontal	4 (14.8)
Parietal	20 (74.1)
Temporal	0
Occipital	3 (11.1)
Number of total lesions	55
Nature of lesions (n=55)	Number of lesions (%)
Active	4 (7.2)
Inactive	14 (25.5)
Transitional	37 (67.3)
Abnormal electroencephalography	
Type of abnormality (n=21)	Number of children (%)
Non-specific background abnormalities	13 (61.9)
Epileptic discharges (for details)	8 (38.1)
Other investigations	Number of children (%)
Absolute eosinophil count (>500/mm <sup>3</sup> )	13 (34.2)
Stool microscopy showing <i>Taenia</i> sp	17 (44.7)

**Table 3a: Type of epileptic discharges with type, site and number of lesions**

Epileptiform EEG abnormalities	Type of lesion	Anatomical location (lobe)	Number of lesion
Widespread high frequency	Transitional	Frontal	2
Widespread high frequency	Calcified	Parietal	1
Widespread high frequency	Transitional	Parietal	2
Widespread high frequency	Mixed	Multiple	1
Focal parietal spike wave	Calcified	Parietal	1
Focal parietal wave spike	Transitional	Parietal	1

EEG=Electroencephalography



discharges (two generalized slowing and one focal slowing) after a mean follow-up of 2 years. No particular parameter like EEG abnormality at presentation or after 2 years of follow-up, mean age at onset, type and number of seizures were found to be statistically significant ( $P < 0.05$ ) [Table 5].

## Discussion

Patients from endemic areas with ring enhancing brain CT lesion of less than 2 cm size presenting with seizure with no

clinical neurodeficit and no evidences of systemic diseases almost always suffer from neurocysticercosis.<sup>[11]</sup>

Though classically human cysticercosis is said to be acquired through ingestion of undercooked pork but infection in vegetarian children can happen by consumption of food and water contaminated with eggs, autoinfection by eggs refluxing from intestine into the stomach by reverse peristalsis. Persons infected with adult worm may also self-infect with eggs by feco-oral route.<sup>[1]</sup>

**Table 4: Number, type and parenchymal site of neurocysticercosis lesions, EEG, eosinophil count at presentation of the 51 patients who participated initially in the study**

Lesion (Number, site, activity) and EEG changes	Absolute number and percentage in each group
Type of lesion (n=51)	Number of patients
Single (solitary)	39 (76.5)
Multiple	12 (23.5)
Site of solitary lesion (n=39)	Number of lesion
Frontal	9 (23.1)
Parietal	27 (69.2)
Temporal	0
Occipital	3 (7.7)
Total lesions	70
Nature of cysts (n=70)	Number of lesion
Active	6 (8.6)
Inactive	14 (20)
Transitional	50 (71.4)
Abnormal electroencephalography (n=24)	Number of patients
Type of abnormality	N (%)
Non-specific background abnormalities	14 (58.3)
Epileptic discharges	10 (41.7)
Other investigations	Number of patients
Absolute eosinophil count (>500/mm <sup>3</sup> )	16 (31.3)
Stool microscopy showing <i>Taenia</i> sp	19 (37.26)

EEG=Electroencephalography

Special precaution were taken to rule out the closest differential diagnosis in this part of the globe i.e. tuberculoma. Tuberculoma were excluded by the following features in CT brain-ring enhancing tuberculoma are more than 20 mm diameter, wall thickness more than 2 mm, presence of midline shift, lack of white dot like scolices, lack of spontaneous disappearance of the tuberculoma.<sup>[10-12]</sup> Moreover, the absence of permanent focal neurodeficit strongly supports the diagnosis of neurocysticercosis.

Generalized seizure was the commonest presentation in our cases unlike most other literatures worldwide.<sup>[3,13-16]</sup> However, one study from Western Nepal recorded almost 30% incidence of partial seizures at presentation.<sup>[9]</sup> Interestingly two large case series published very recently from Nepal and India cited incidences of generalized seizure at presentation 52% and 65% respectively.<sup>[17,18]</sup> Incidences of status epilepticus or convulsive crisis were less than 6% in our observation, but Cuéllar *et al.* and Terraza *et al.*, reported high incidences of convulsive crisis.<sup>[5,19]</sup> Headache and vomiting were observed in 63% of ours. Singhi *et al.*, recorded almost 33% incidences of headache and vomiting.<sup>[3]</sup> Kalra and Sethi cited 44% incidences of headache because of raised intracranial tensions.<sup>[20]</sup>

Persistence of headache after a mean of 2 years was found in more than 20% of our cases, but the cause of such headache was not known. Persistent headache occurred more commonly in patients with calcification of cyst. Persistent calcification was seen after a mean duration of 2 years in 5 out of 8 headache patients in our cohort. However, any definite correlation cannot be drawn from such a small study though an association between secondary migraine like headache and neurocysticercosis was proposed by Mishra in a study.<sup>[21]</sup> Cruz *et al.*, found 19 cases of neurocysticercosis amongst 57

**Table 5: Statistical analysis of various parameters of pediatric neurocysticercosis cases**

Parameters	Number of patients with seizure after a mean of 2 years of follow up showing the parameters (n=9) (%)	Number of patients without any seizure after a mean of 2 years of follow up showing the parameter (n=29) (%)	Significance as predictor for prognosis
More than 1 CT lesion at presentation	4 (44.4)	7 (24.13)	Insignificant
Persistent calcified lesion in CT after a mean of 2 years	4 (44.4)	13 (44.8)	Insignificant
Patients with EEG abnormality at presentation	5 (55.6)	16 (55.1)	Insignificant
Multiple seizures	5 (55.6)	14 (48.3)	Insignificant
Patients with EEG abnormality at 2 years (mean duration)	4 (44.4) epileptic waves in 1 only (widespread high frequency)	7 (24.14)	Insignificant
Generalized seizure	6 (66.7)	15 (51.2)	Insignificant

CT=Computed tomography, EEG=Electroencephalography

adult cases of migraine in Ecuador.<sup>[22]</sup> Similar to a study by Basu *et al.*, the highest numbers of cases were found among 10-12 year age group in ours.

Since many of our patients had multitude of symptoms at the beginning and in many patients multiple stages of the cysts coexisted it was not possible to find any particular stage specific symptoms except the fact that seizure is the most common presentation during transitional stages of the cyst and persistent headache was common in children with calcified cyst.

We found slight female preponderance with female:male ratio of 1.1:1. Higher female predominance was observed from one article in Chicago and also from a small observation by Morgado *et al.*<sup>[3,23]</sup> Youngest patient in our series was 1 year old. Cuéllar *et al.*, found a large number of cases of below 4 year age. The infant in our series presented with non-febrile focal seizure and poor feeding. According to the mother, the infant was exclusively breast fed until 6 months of age. Henceforth, the infant was breast fed until 1 year along with boiled, smashed vegetables and cereals. The parents denied giving any raw vegetables to their child. The parents also denied any history of seizures in their family and next-door neighbors. Similar to the majority of less than 4-year-old children described by Cuéllar *et al.*, this infant was an urban slum dweller with poor socioeconomic status, improper access to good sanitation facilities. However, there are growing evidences that infections acquired mostly via person to person and environmental factor play little role in the transmission. The child presented with partial seizure and had excellent symptomatic response to treatment with no fresh episode of seizure after beginning anticonvulsant. However, there was no history suggestive of convulsive crisis unlike described by Cuéllar *et al.* The infant's other family members, especially the children could not be screened for taeniasis or neurocysticercosis as they did not turn up for screening at our outdoor despite counseling. The heterogeneity in the susceptible age groups among pediatric population reflects the wide variation of the incubation period of this infection.

Incidence of a single ring enhancing lesion on imaging was almost 71% in our study consistent with most of the other major studies (50-80%).<sup>[11,14,21]</sup> However, a study from Western Nepal recorded only 41% solitary lesions.<sup>[9]</sup> Cyst morphology/stage and number did not correlate with different patterns of clinical presentations.

Parietal lobe was the overwhelmingly common site in our series (74% involvement), like the western Nepalese study. Probably cysticercus larva have a tendency to involve middle cerebral artery and its branches so parietal lobe involvement is common.<sup>[24]</sup>

None of our cases showed extra-parenchymal or extracranial (muscles, ocular tissue etc.) involvement. One possible reason for no extraparenchymal involvement in our study is the over-reliance on CT and limitation of CT in identifying intraventricular, cisternal or soft-tissue involvement. Antoniuk *et al.* and Singhi and Singhi also observed that extraparenchymal neurocysticercosis was rare in paediatric

age group.<sup>[6,14]</sup> However, Basu *et al.*, showed more than 20% extraparenchymal involvement.

Transitional stage cyst was the most common finding in CT in ours (prevalence > 70%). Almost similar prevalence was noted in Western Nepal. Antoniuk *et al.*, in a Brazilian study found only 36% transitional stage cysts. We found 25% cases of calcified (inactive) cysts at diagnosis; Brazilian report found 39% cases of inactive stage lesions. One report from Western Nepal observed less than 3% calcified lesions at diagnosis.

In this study, 8 (22.2%) out of 36 patients with seizure showed epileptiform EEG discharges at presentation in our cohort of 38 children and only 2 EEGs (5.6% of the total seizure patients) corresponded to the site of lesion (parietal lobe). A major review showed that EEG demonstrated little relation to symptoms and CT lesions in patients with neurocysticercosis.<sup>[25]</sup> A positive correlation between CT lesions and localizing or lateralizing EEG abnormalities was reported in only 15-30% cases of neurocysticercosis. Correlation between seizure type and EEG abnormalities was reported in 7-20% of patients only.<sup>[25]</sup>

After 2 years, nearly 32% of the lesions disappeared and 45% lesion healed by calcification in our study. Basu *et al.*, who recorded almost 70% disappearance and 7% calcification of the lesions after 12 months.<sup>[9]</sup> Another large series from India noted complete disappearance in more than 90% of solitary lesions.<sup>[3]</sup> The strikingly lower rate of disappearance of lesion in our study is most probably due to the poor compliance of patients either due to poor financial status or ignorance. Both are relatively common in this part of the world due to a higher rate of illiteracy though it was rigorously tried to follow a uniform diagnosis, management or treatment protocol in all patients. Whether reliance on CT as primary imaging modality instead of MRI and selecting treatment regimen containing prednisolone, phenytoin and albendazole resulted in such a low disappearance of the lesion is not clear. Randomized control trials between various imaging modalities and treatment modalities are necessary to ascertain the exact cause.

After a mean of 2 years no permanent neurodeficit or behavioral abnormality were noted and seizure persisted in less than 25% cases in our patients. Similar excellent outcome was echoed by other large studies on pediatric neurocysticercosis.<sup>[3,5,9]</sup> Though Singhi *et al.*, found multiple lesions, persistence of lesions, calcification and extra-parenchymal forms of cysts to be associated with recurrence of the seizures but we found no specific factor like type morphology, location in brain parenchyma or number of cysts to be prognostically significant probably due to a smaller number of cases unlike Singhi.<sup>[13]</sup> There is growing evidence that so-called "inactive" form i.e., calcification can cause many symptoms like headache or seizure.<sup>[26]</sup>

The indications and exact duration of anticonvulsant therapy in neurocysticercosis patients are not clear. Indian Academy of Pediatrics recommends at least 12-18 months of therapy for convulsion.<sup>[10]</sup> Some authors also advocate continuation of anticonvulsants until the resolution of lesions.<sup>[12]</sup> However, if seizures are recurrent or associated with calcified lesions treatment should be continued for 2-3 years before any attempt

to wean from anticonvulsants. Carbamazepine and phenytoin are the commonly used anticonvulsants.

Albendazole in the treatment of pediatric neurocysticercosis in the context of resolution of active or transitional cysts and better clinical progress is a controversial subject. There are proponents of no albendazole therapy, short course therapy (7 days) and 28 days course of full dose albendazole therapy.<sup>[1,5,10,12,14,27]</sup> However, Albendazole or other anticysticercal drugs are contraindicated for spinal and ocular involvement as drug induced inflammation may result in irreversible damage to the respective organs.

## Conclusion

From 10 to 12 year age group children are the most common victims of pediatric neurocysticercosis. Generalized tonic clonic seizure is the most common variety of seizure at presentation followed by simple partial type. Transitional type is the most common variety of the cyst to be discovered at CT scan. Parietal lobe is the most common location of cyst on CT scan. Transitional cyst commonly appears as ring enhancing lesion with or without perilesional edema. Solitary cyst is much more common than multiple cysts with not a single case of extraparenchymal type of lesion found in our study. Calcification of the cyst is the commonest mode of healing followed by spontaneous resolution after a mean duration of 2 years of follow-up. Prognosis is excellent as almost 80% had complete disappearance of seizure after 2 years of follow-up. None of the children had any features of neurodeficit at the end of 2 years. However, almost 20% reported persistence of headache after 2 years.

## Acknowledgment

The authors are highly indebted to Professor S.P. Saha, Head, Department of Neuromedicine, N.R.S. Medical College for his continuous support at all stages. The authors are also indebted to Professor Malay Dasgupta, Consultant Pediatrician, R.G. Kar Medical College and Hospital, Dr. Samar Biswas, Assistant Professor, Department of Neurology, R.G. Kar Medical College, Professor Dr. Arup Dutta, Head of the Department of Neuromedicine, R.G. Kar Medical College and Hospital, Kolkata. The authors are also grateful to Dr. Mrinal Acharya and Dr. Dwaipayan Bhattacharya (both SHOs in the Neuromedicine Department) for their help in counseling the guardians.

## References

- Blanton R. Cysticercosis. In: Kliegman RM, Jenson HB, Behrman RE, Stanton BF, editors. Nelson Textbook of Paediatrics. Philadelphia: Saunders Elsevier; 2007. p. 1514-6.
- Bhattacharjee S, Biswas P. Childhood seizure – A case of neurocysticercosis involving left parietal lobe. Turk Noroloji Dergisi 2011;17:167-70.
- Singhi P, Ray M, Singhi S, Khandelwal N. Clinical spectrum of 500 children with neurocysticercosis and response to albendazole therapy. J Child Neurol 2000;15:207-13.
- Rosenfeld EA, Byrd SE, Shulman ST. Neurocysticercosis among children in Chicago. Clin Infect Dis 1996;23:262-8.
- Cuéllar R, Molinero M, Ramirez F, Vallejo V. Clinical findings in active cerebral neurocysticercosis in pediatrics. Rev Neurol 1999;29:334-7.
- Antoniuk S, Bruck I, Santos LH, Souza LP, Fugimura S.

- Neurocysticercosis in children: Clinical study and follow-up of 112 patients. Rev Neurol 2006;42 Suppl 3:S97-101.
- Del Brutto OH, Rajshekhar V, White AC Jr, Tsang VC, Nash TE, Takayanagui OM, *et al.* Proposed diagnostic criteria for neurocysticercosis. Neurology 2001;57:177-83.
- Carpio A, Placencia M, Santillán F, Escobar A. A proposal for classification of neurocysticercosis. Can J Neurol Sci 1994;21:43-7.
- Basu S, Ramchandran U, Thapliyal A. Clinical profile and outcome of paediatric neuro-cysticercosis: A study from Western Nepal. J Pediatr Neurol 2007;5:45-52.
- Kalra V. Neurocysticercosis. In: Parthasarathy A, Menon PS, Agarwal RK, Choudhury P, Thacker CN, Ugra D, *et al.*, editors. IAP Textbook of Paediatrics. New Delhi: Jaypee Brothers Medical Publishers; 2009. p. 469-70.
- White AC Jr, Weller PF. Cestodes. In: Kasper DL, Fauci AS, Longo DL, Braunwald E, Hauser SL, Jameson JL, *et al.*, editors. Harrison's Principles of Internal Medicine. New York: McGraw Hill; 2008. p. 1337-8.
- Kalra V. Central nervous system. In: Ghai OP, editor. Ghai Essential Paediatrics. New Delhi: CBS Publishers; 2009. p. 546-7.
- Singhi P. Neurocysticercosis. Ther Adv Neurol Disord 2011;4:67-81.
- Singhi P, Singhi S. Neurocysticercosis in children. J Child Neurol 2004;19:482-92.
- Morales NM, Agapejev S, Morales RR, Padula NA, Lima MM. Clinical aspects of neurocysticercosis in children. Pediatr Neurol 2000;22:287-91.
- Talukdar B, Saxena A, Popli VK, Choudhury V. Neurocysticercosis in children: Clinical characteristics and outcome. Ann Trop Paediatr 2002;22:333-9.
- Gauchan E, Malla T, Basnet S, Rao KS. Variability of presentations and CT-scan findings in children with neurocysticercosis. Kathmandu Univ Med J (KUMJ) 2011;9:17-21.
- Prasad R, Anil, Mishra OP, Mishra SP, Upadhyay RS, Singh TB. Oxidative stress in children with neurocysticercosis. Pediatr Infect Dis J 2012;31:1012-5.
- Terraza S, Pujol T, Gascón J, Corachán M. Neurocysticercosis: An imported disease?. Med Clin (Barc) 2001;116:261-3.
- Kalra V, Sethi A. Childhood neurocysticercosis – Epidemiology, diagnosis and course. Acta Paediatr Jpn 1992;34:365-70.
- Mishra D. Cysticercosis headache: An important differential of childhood headache disorder in endemic countries. Headache 2007;47:301-2.
- Cruz ME, Cruz I, Preux PM, Schantz P, Dumas M. Headache and cysticercosis in Ecuador, South America. Headache 1995;35:93-7.
- Morgado C, Gomes LB, de Campos JG. Neurocysticercosis. An imaging analysis of 35 cases. Acta Med Port 1994;7:269-75.
- Roos KL, Tyler KL. Meningitis, encephalitis, brain abscess and empyema. In: Kasper DL, Braunwald E, Jameson JL, Hauser S, Fauci AS, Longo DL, *et al.*, editors. Harrison's Principles of Internal Medicine. New York: McGraw Hill; 2005. p. 2485.
- Carpio A. Neurocysticercosis: An update. Lancet Infect Dis 2002;2:751-62.
- Del Brutto OH. Neurocysticercosis: New thoughts on controversial issues. Curr Opin Neurol 2013;26:289-94.
- Kaur P, Dhiman P, Dhawan N, Nijhawan R, Pandit S. Comparison of 1 week versus 4 weeks of albendazole therapy in single small enhancing computed tomography lesion. Neurol India 2010;58:560-4.

**How to cite this article:** Bhattacharjee S, Biswas P, Mondal T. Clinical profile and follow-up of 51 pediatric neurocysticercosis cases: A study from Eastern India. Ann Indian Acad Neurol 2013;16:549-55.

**Received:** 27-04-13, **Revised:** 23-06-13, **Accepted:** 29-08-13

**Source of Support:** Nil, **Conflict of Interest:** Nil