











Original Article

Development of a Novel Endovascular Brachytherapy Stent: A Proof-of-concept Study

Nan Du^{1,2#} , Jingqin Ma^{1,2#} , Zihan Zhang^{1,2} , Yongjie Zhou^{1,2} , Minjie Yang^{1,2} , Wen Zhang^{1,2} ,
Jianjun Luo^{1,2*}  and Zhiping Yan^{1,2*} 

¹Department of Interventional Radiology, Zhongshan Hospital, Fudan University, Shanghai, China; ²Shanghai Institution of Medical Imaging, Shanghai, China

Received: 24 November 2020 | Revised: 20 March 2021 | Accepted: 7 April 2021 | Published: 7 July 2021

Abstract

Background and Aims: Endovascular implantation of iodine-125 (¹²⁵I) seeds strand combined with stent is an effective method of treatment for portal vein tumor thrombosis. The aim of this study was to develop a novel endovascular brachytherapy stent (EVB-Stent) and to evaluate its feasibility of use. **Methods:** An EVB-Stent was implanted into the main portal vein (MPV) in a live porcine model via the percutaneous transhepatic route. Blood samples were collected and tested before and after operation, as well as before euthanasia. Single-photon emission computed tomography (SPECT) combined with CT (SPECT/CT) scan were performed directly after operation and CT scan was performed 2 months after implantation. After the CT scan was performed, all animals were euthanized and histologically examined. **Results:** The novel stent was successfully positioned in all six pigs. No deterioration of liver function was observed during the 2-month follow-up period. SPECT/CT revealed the uniform distribution of radiation around the seeds strand, and the hottest spot was near the center of the MPV. The patency of the stented MPV was confirmed using CT scans. The tissue-accumulated absorbed dose was 31,822.11 mGy at 10 mm transversely away from the midpoint of the ¹²⁵I seeds strand, with a half-life of 59.4 days. Pathological examination results showed no significant atrophy or inflammation of adjunct liver tissue, and no obvious intima thickening or thrombosis were detected in the stented MPV. **Conclusions:** A liver porcine model was used to demonstrate that the transhepatic placement of a novel endovascular brachytherapy stent, EVB-Stent, is both technically feasible and safe.

Citation of this article: Du N, Ma J, Zhang Z, Zhou Y, Yang M,

Zhang W, et al. Development of a novel endovascular brachytherapy stent: A proof-of-concept study. *J Clin Transl Hepatol* 2021;9(5):711–718. doi: 10.14218/JCTH.2020.00128.

Introduction

Hepatocellular carcinoma (HCC) is the 7th most common malignancy and the fourth leading cause of cancer-related death worldwide.^{1,2} Approximately 10–40% of HCC patients suffer portal vein tumor thrombus (PVTT) complication at the time of diagnosis.³ Based on Barcelona Clinic Liver Cancer staging, sorafenib is the only evidence-based and recommended treatment option for patients with vascular invasion (stage C). However, several studies have shown only modest clinical efficiency when sorafenib monotherapy has been provided for HCC patients with PVTT.^{4–6} In recent studies, transarterial chemoembolization (TACE) combined with sorafenib or radiotherapy has shown survival benefits for HCC patients with PVTT.^{7–9} Although survival benefits have been provided through the adoption of these combinations, the survival duration of HCC patients with PVTT remains poor, which may be attributed to the obstructed blood flow in the PV. Owing to compromised PV blood supply, the interruption of hepatic arterial flow may result in severe ischemic liver damage.¹⁰ Therefore, HCC patients with PVTT are generally considered as contraindicated for TACE.

In China, HCC patients with PVTT often receive treatment through multiple methods, such as surgery, external beam radiotherapy (EBRT), chemotherapy, and iodine-125 (¹²⁵I) seeds strand and stent implantation.¹¹ A recent multicenter study proved that patients with limited PVTT could benefit from liver resection.¹² However, patients with main PV tumor thrombus (MPVTT), can barely meet the requirements for liver resection. A systematic review and meta-analysis compared TACE plus EBRT with TACE alone for unresectable HCC.¹³ The results of the study indicated that the pooled median survival for TACE plus EBRT-treated patients was significantly better than of TACE alone-treated patients. However, the pooled analysis also showed that compared with TACE alone, TACE plus EBRT significantly increased the occurrence of gastroduodenal ulcers, as well as elevated levels of alanine aminotransferase and total bilirubin. Since normal hepatic tissues show poor tolerance to radiation, it is also impos-

Keywords: Portal vein tumor; Tumor thrombus; Brachytherapy; Stent; Iodine-125 seeds strand.

Abbreviations: ¹²⁵I, iodine-125; EBRT, external beam radiotherapy; EVB, endovascular brachytherapy; HCC, hepatocellular carcinoma; MPV, main portal vein; MPVTT, main portal vein tumor thrombus; NBCA, n-butyl-2-cyanoacrylate; PVSI, portal vein stent implantation; PVTT, portal vein tumor thrombus; SPECT, single-photon emission computed tomography; TACE, transarterial chemoembolization.

*These two authors contributed equally to this study.

Correspondence to: Zhiping Yan and Jianjun Luo, Department of Interventional Radiology, Zhongshan Hospital, Fudan University, No. 180 Fenglin Road, Shanghai 200032, China. ORCID: <https://orcid.org/0000-0001-7907-435X> (ZY), <https://orcid.org/0000-0003-4942-0439> (JL). Tel: +86-13681971205, E-mail: yan.zhiping@zs-hospital.sh.cn (ZY); Tel: +86-13801924777, E-mail: luojianjun@zs-hospital.sh.cn (JL)

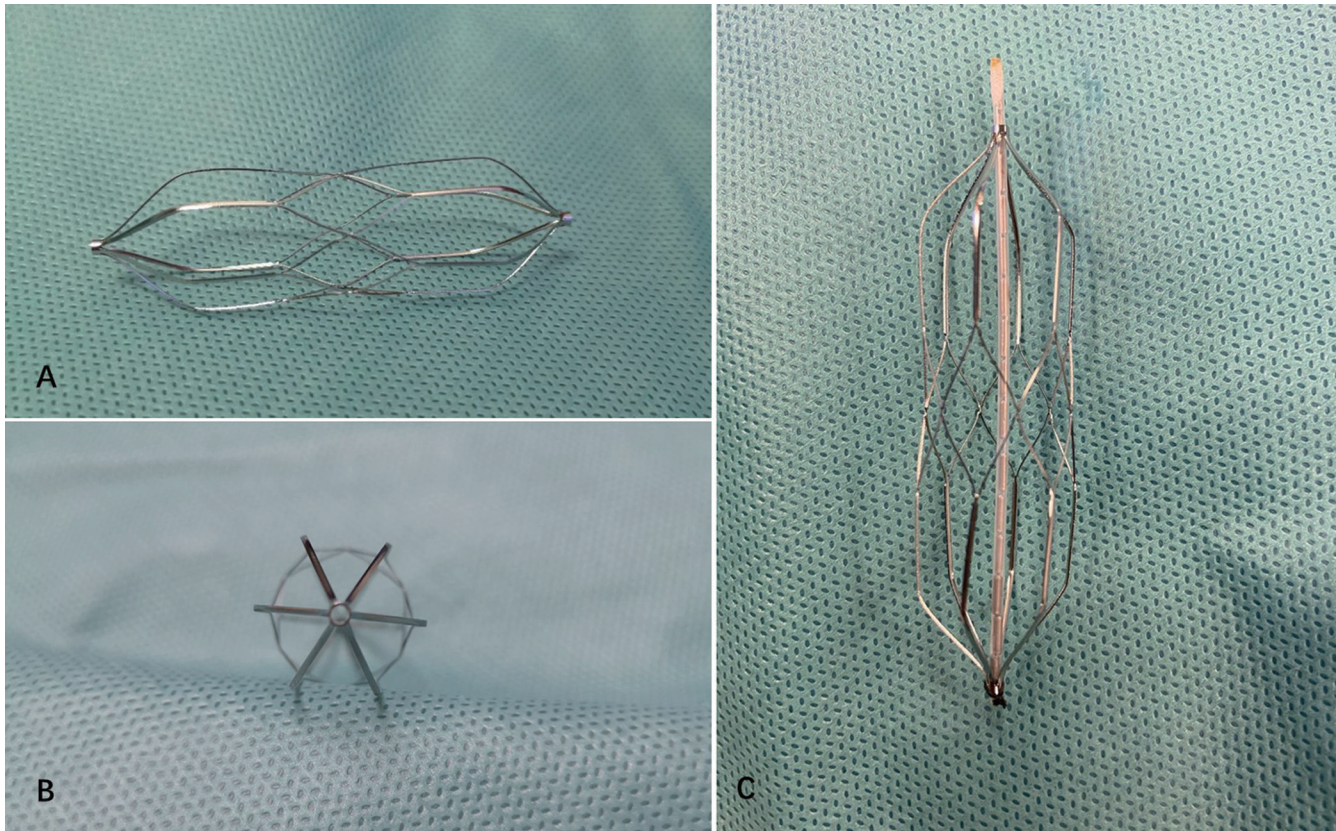


Fig. 1. Configuration and structure of the EVB-Stent system. (A) The EVB-Stent was made using a nickel titanium alloy and consisted of a cylindrical mesh structure with two rings at its two ends. Its length of its axis was 60 mm, with a diameter of 18 mm. (B) At the two tapered ends of stent, an ^{125}I seeds strand, which was a 4-Fr sterile plastic tube containing ^{125}I seeds, was inserted through the two rings and fixed to the stent using sterile sutures. (C) After assembly was completed, the novel stent equipped with an ^{125}I seeds stand was known as an EVB-Stent.

sible to increase the external irradiation dose provided for the treatment of PVTT. Endovascular brachytherapy (EVB) using ^{125}I seeds strand implantation could offer an adequate dose of radiation to exert a tumor killing effect with subtle damage during irradiation, leading to the relative protection of healthy tissues.¹⁴ Animal models with vascular tumor thrombus have been established and employed to demonstrate the safety and efficacy of ^{125}I seeds strand in exerting an antitumor effect.^{15,16} For patients with MPVTT, estimated overall survival was only 2 to 4 months.¹⁷ Our previous studies have also established that TACE combined with ^{125}I seeds strand and portal vein stent implantation (PVSII) can prolong the overall survival of HCC patients with MPVTT.^{18–21} Moreover, this method has been widely used for HCC patients with MPVTT in many tertiary hospitals in China.

Due to the eccentric location of ^{125}I seed strands in MPV, the uneven distribution of radiation in the PV was a potential deficiency that could compromise the efficacy of endovascular radiotherapy. Moreover, the usage of a higher dosage of ^{125}I seeds strand was restricted due to the close association to the vascular wall. Hence, even after undergoing ^{125}I seeds strand combined with stent MPV implantation, some patients may still suffer from re-occlusion of the PV owing to tumor thrombus progression. To further improve the antitumor effect of EVB using PV stent and ^{125}I seeds strand insertion, we introduced an innovative EVB-Stent, which is a biconical stent with an ^{125}I seed strand attached coaxially at the center of the stent. The aim of this study was to develop and evaluate the technical feasibility

and safety of the EVB-Stent.

Methods

Assembling of the EVB-Stent

A self-expanding Nitinol stent (Hongpu Medical Device Corporation, Shanghai, China) with a mesh-like structure, was tapered into two rings at the proximal and distal ends. The stent used in this study was 18 mm × 60 mm in size. A 4-Fr sterile plastic tube (Boston Scientific Co., Marlborough, MA, USA) containing ^{125}I seeds was inserted through the rings at both ends and the seeds strand was fixed to the stent using sterile sutures (Fig. 1). The stent, once equipped with the ^{125}I seeds stand, was known as an EVB-Stent.

As described in our previous study,¹⁹ Model 6711 ^{125}I seeds (XinKe, Shanghai, China) were encapsulated in a 4-Fr sterile plastic tube (Boston Scientific Co.) to assemble the seeds strand. The radioactivity of each ^{125}I seed was 25.9 MBq, with a half-life of 59.4 days. The principal photon emissions were 27.4–31.4 keV X-ray and 35.5 keV γ -ray. The half-value thickness of tissue for ^{125}I seeds was 17 mm, and the initial dose rate was 7 cGy/h. The effective irradiating range was 20 mm. The number of ^{125}I seeds was determined by the length of the plastic tube (L mm; $N = L/4.5$). In this study, the number of ^{125}I seeds used in each strand was 14.

Table 1. Comparison of laboratory test results pre-procedure and post-procedure

	Preoperative	One-week post-intervention	Two-month post-intervention	<i>p</i>
RBC as $\times 10^{12}/L$	7.2 \pm 0.3	6.7 \pm 0.6	7.0 \pm 0.5	0.261
HB as $\times 10^9/L$	116.8 \pm 9.4	107.8 \pm 13.9	111.3 \pm 10.3	0.352
WBC as $\times 10^9/L$	11.7 \pm 2.2	13.9 \pm 2.2	11.0 \pm 1.6	0.074
PLT as $\times 10^9/L$	514.2 \pm 82.8	507.1 \pm 77.4	513.8 \pm 67.3	0.984
TB in $\mu\text{mol}/L$	9.7 \pm 0.4	10.4 \pm 0.6	10.2 \pm 0.5	0.079
DB in $\mu\text{mol}/L$	6.5 \pm 0.4	7.2 \pm 0.5	7.0 \pm 0.5	0.053
AST in U/L	37.2 \pm 1.9	38.0 \pm 1.9	38.2 \pm 2.3	0.655
ALT in U/L	44.0 \pm 2.4	45.2 \pm 2.1	46.5 \pm 2.8	0.240
ALB in g/L	23.6 \pm 1.6	22.9 \pm 1.4	22.8 \pm 0.8	0.508

ALB, albumin; ALT, alanine aminotransferase; AST, aspartate aminotransferase; DB, direct bilirubin; HB, hemoglobin; PLT, platelet; RBC, red blood cell; TB, total bilirubin; WBC, white blood cell.

Animals

The animals selected for the experiment were six ordinary white pigs (weight 35–40 kg) provided by the Experimental Animal Center of our hospital. This study was approved by the institutional Animal Ethics Committee of our hospital. The animals were fasted for 12 h before operation. Intramuscular injection of xylazine hydrochloride (2–4 mg/kg) and diazepam (2 mg/kg) were used for sedation and anesthesia, respectively. Blood pressure, heart rate, and respiration rate were monitored during the procedure.

Interventional procedures

Under fluoroscopic and ultrasound guidance, the right intrahepatic PV was punctured using a 21G Chiba needle (Cook Medical Inc., Bloomington, IN, USA) and a 0.018-inch wire (Cook Medical Inc.) was inserted into the PV. A 6-F Neff Percutaneous Access set (Cook Medical Inc.) was introduced into the PV over the wire. Through the outer cannula of the Neff Percutaneous Access set, a 0.035-inch, 150 cm-long wire (Terumo, Tokyo, Japan) was manipulated across the MPV into the superior mesenteric vein, followed by the insertion of a 4-F pigtail catheter (Cook Medical Inc.). PV venography was performed via the pigtail catheter. After venography, the catheter was removed, and the outer cannula of the Neff Percutaneous Access set was replaced by a 7-Fr, 23 cm-long sheath (Cordis, Hialeah, FL, USA) over the wire. After 100 U/kg heparin (XinYi, Shanghai, China) was administered through the sheath, and the novel EVB-Stent was loaded into the sheath and pushed into the target main PV. The stent was deployed from the distal MPV into the proximal patent intrahepatic PV under fluoroscopic guidance. PV venography was repeated through the pigtail catheter to confirm the appropriate location and patency of the EVB-Stent. Finally, the transhepatic puncture track was occluded using n-butyl-2-cyanoacrylate (NBCA) (Compont, Beijing, China).

Radiation safety protection measures were followed by physicians during the ^{125}I seed preparation and PV implantation. Lead protective gloves were provided to animal house workers during the follow-up period. At the end of the study, the ^{125}I seeds were restored and processed properly.

Post-procedure management

After implantation, 100 U/kg heparin was subcutaneously administered once a day for 2 months. The animals were

raised by conventional methods and monitored for the loss of appetite, vomiting, diarrhea, and weight loss after implantation. Blood samples were collected before implantation and at 1 week and 2 months after implantation, to determine liver function and blood toxicity. Single photon emission computed tomography (SPECT) combined with CT (SPECT/CT) scan was performed to evaluate the radiation distribution emitted by the ^{125}I seeds strand immediately after implantation.²¹ Tissue accumulated absorbed doses 10 mm from the midpoint of the ^{125}I seeds strand were theoretically calculated using ^{125}I Radiation Field Distribution Calculation Software.¹⁶ CT scan was performed at 2 months post operation, and three-dimensional (3D) reconstructions were made to evaluate the patency of the stented PV. The contrast agent used was Ultravist Injection (300 mgI/mL). Intravenous access was through the femoral vein, and the dose of the contrast agent was 80 mL (2.0 mL/kg) on average, at an injection rate of 4 mL/s, delay time of arterial phase enhancement of 15 s, and a portal venous phase enhancement delay time of 50 s. After CT scans were performed, the animals were sacrificed through intravenous injection of potassium chloride and necropsied, immediately. The stented MPV and adjacent organ tissue were harvested and fixed in 10% formalin for pathological examination. Hematoxylin and eosin staining were performed, to evaluate adjunct liver tissue change and to evaluate thrombus organization within the stented PV and neointima coverage of the PV.

Statistical analysis

Statistical analysis was performed using SPSS 22.0 (IBM Corp., Armonk, NY, USA) software. One-way analysis of variance was used to compare differences in hematological indices between the different time points. Measurement data are presented as mean \pm standard deviation. A two-sided *p*-value of <0.05 was considered statistically significant.

Results

The EVB-Stent was successfully implanted into the MPV of all six pigs without major complications. After stent placement, venography of the PV confirmed the proper location of the EVB-Stent in the MPV. All animals were in good condition without a loss of appetite, bleeding, weight loss, or death. Hematological indices taken throughout the examination period were summarized, and showed that no significant liver function deterioration or blood toxicity were detected (Table 1).

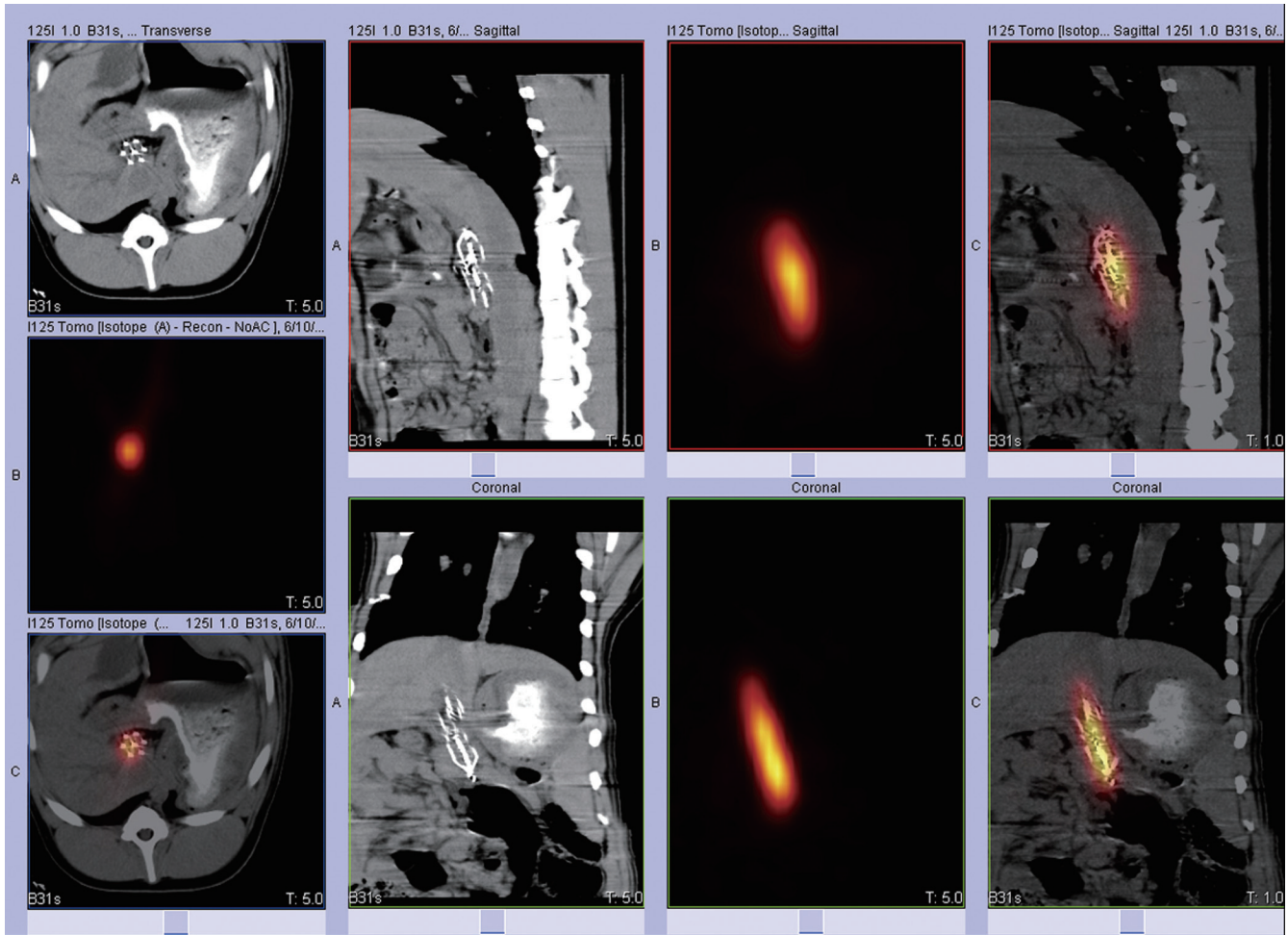


Fig. 2. Images obtained by performing a SPECT/CT scan 1 day after the procedure was performed. The EVB-Stent was implanted correctly in the MPV without displacement. The radiation emitted by the ¹²⁵I seeds was homogeneously distributed and completely covered the target lesion.

The SPECT/CT scan showed that the EVB-Stent had been correctly placed in the MPV without collapse, occlusion, or over-expansion. Radiation emitted by the ¹²⁵I seeds strand was distributed symmetrically in the MPV, and presented as a cylindrical shape that completely covered the targeted MPV (Fig. 2). Based on the ¹²⁵I Radiation Field Distribution Calculation software, the tissue accumulated absorbed dose was 31,822.11 mGy 10 mm transverse from the midpoint of the ¹²⁵I seeds strand, with a half-life of 59.4 days (Fig. 3). The three-dimensional reconstruction CT image showed that the stented vessel remained in position and that the ¹²⁵I seeds strand was tightly fixed to the center of the stent (Fig. 4). Additionally, no malposition, collapse, thrombosis, or stenosis occurred in the stented vessels, when observed using CT scans.

Necropsy and pathological examination results showed that none of the stents were covered or occluded at the two tapered ends by neointimal overgrowth in all six pigs (Fig. 5A). However, slight intimal hyperplasia and incomplete neointimal growth covered the tapered end near the hilar side of the stent in one pig (Fig. 5B). Hematoxylin-eosin staining revealed that the central grid of the EVB-Stent and even the densest part of the stent mesh were almost completely covered by neointimal growth, which resulted in the proper incorporation of the EVB-Stent, and its surface was smooth and free from tears, peelings, or injuries (Fig. 5C-D). No

obvious abnormalities were found in nearby organs, including the liver parenchyma, duodenal wall, and pancreas, as examined through gross observations and pathological analysis (Supplementary Fig. 1).

Discussion

In this study, we demonstrated the technical feasibility of the percutaneous transhepatic placement of a novel radioactive stent, the EVB-Stent, in the MPV of a live porcine model. Furthermore, during the 2-month follow-up period, the stented PV remained in position in all cases, with minimal neointimal growth covering it. All these results present evidence that the EVB-Stent has the potential to be used for further clinical exploration.

PVTT is a prognostic factor for poorer overall survival among patients with HCC. Stent implantation promptly restores blood flow in the obstructed MPV and provides an opportunity for TACE to be applied for tumor lesions. However, in-stent stenosis can occur due to tumor growth and/or tumor thrombosis.²² EVB along with ¹²⁵I seeds implantation, which can inhibit and prevent the progression of tumor thrombosis, has been provided an option to prolong stent patency.^{21,23} In a previous study, better overall response rate as well as a significantly favorable level of survival

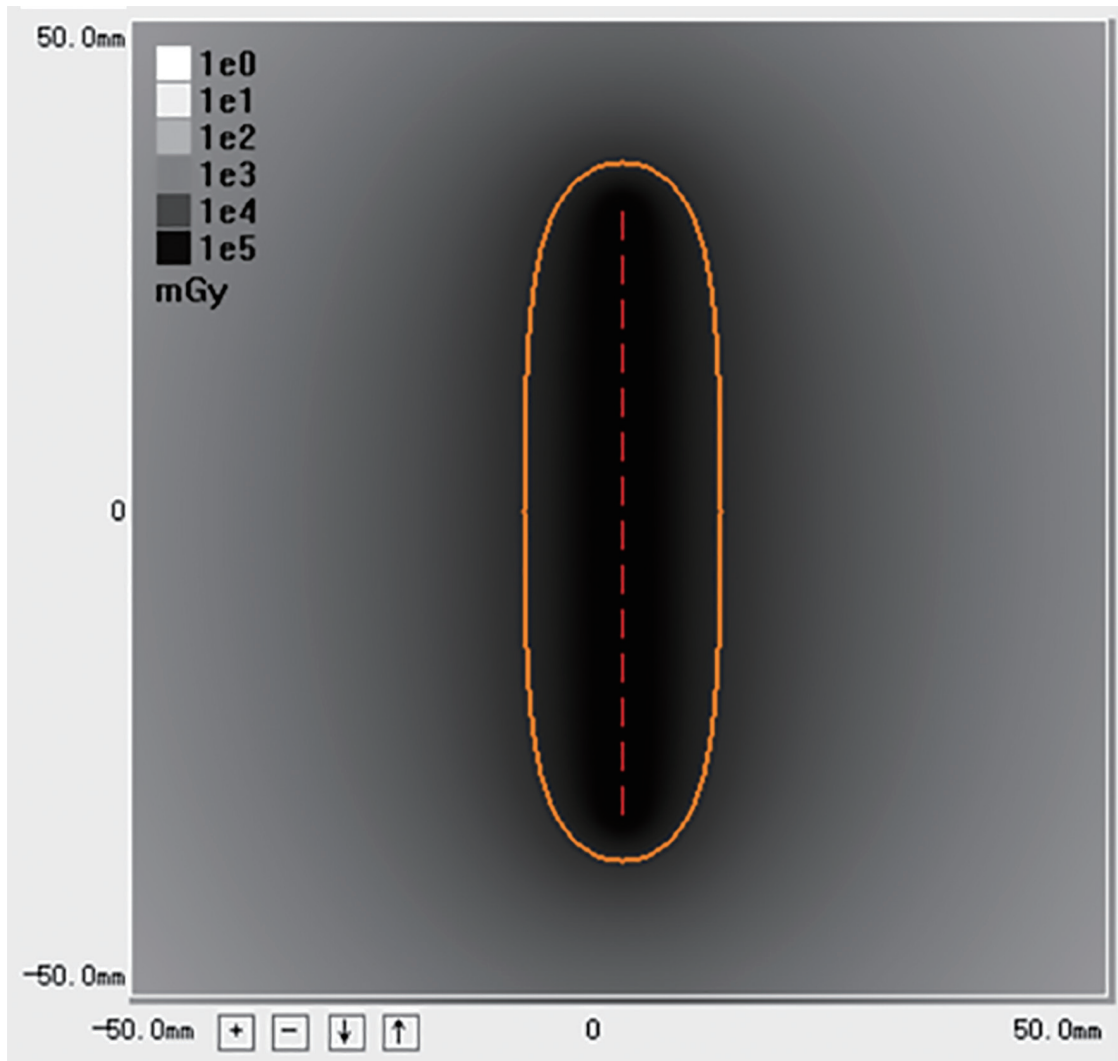


Fig. 3. Calculation of the accumulated absorbed dose presented by the ^{125}I seeds strand. The ^{125}I Radiation Field Distribution Calculation software showed the tissue accumulated absorbed dose 10 mm transversely away from the midpoint of the ^{125}I seeds strand. The yellow ellipses show the 31,822.11 mGy isodose curve.

were observed in patients who received TACE combined with EVB with ^{125}I seeds strand and stent placement.^{24–26} Numerous studies have demonstrated that stent devices that are combined with EVB exert therapeutic efficacy in PVTT, unresectable malignant esophageal and biliary obstruction.^{21,27,28} The eccentric distribution of the ^{125}I seeds strand may cause the delivery of an insufficient radiation dose to the contralateral blood vessel wall, thus compromising the therapeutic efficacy. Moreover, the eccentric distribution of the ^{125}I seeds in the MPV may limit the maximum dose of radiation delivered. Hence, we constructed a novel EVB-Stent to further improve the therapeutic efficacy of brachytherapy using ^{125}I seeds for MPVTT by improving the radiation dosage delivered. The ^{125}I seeds were presented as a sequential string coaxially at the center of the EVB-Stent, and the radiation emitted by the ^{125}I seeds was homogeneously distributed and covered the entire stent canal. To examine the safety and feasibility of the novel radioactive stent, we conducted an animal study through the percutaneous transhepatic PV deployment of the EVB-Stent in a live porcine model.

Previous experimental studies have proven that transhe-

patic puncture and catheterization in a porcine model can be technically feasible without bleeding complications.²⁹ In our study, ultrasound was used to assess intrahepatic vascular dissection and provided clear guidance for PV puncture. Moreover, owing to fine needle puncture, no bleeding or hematoma was observed after operation. A 7-Fr long sheath was used to create a transhepatic track and the EVB-Stent was released through the long sheath. The EVB-Stent could be easily introduced into the PV without any technical difficulties or challenges. Our previous experience showed us that the procedure used for the implantation of the ^{125}I seeds strand combined stent was complicated to some extent.²¹ The outer cannula of the Neff set can be difficult to be delivered to the obstructed MPV and the release of the ^{125}I seeds strand can be complicated if the stent has already been inserted. In this study, the ^{125}I seeds were arranged linearly and continuously sealed into a 4-Fr sterile catheter to construct an ^{125}I seeds strand. Then, the strand was fixed at the center of the stent. Compared with previously used techniques, the transhepatic MPV deployment of the EVB-Stent performed in this study was relatively simple. Hence, we demonstrated the techni-

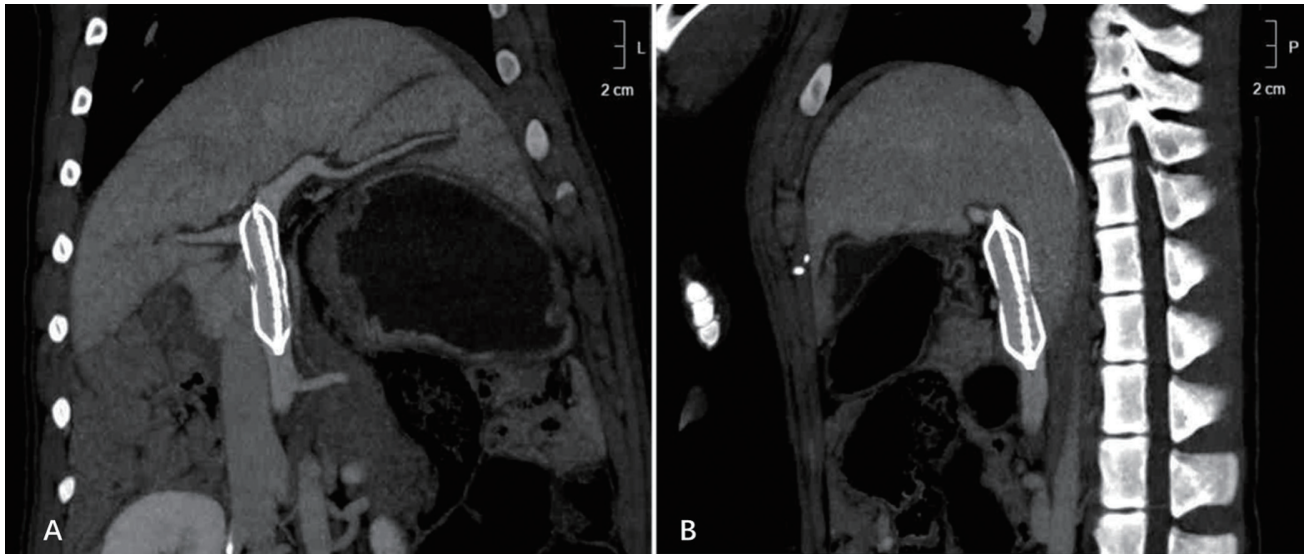


Fig. 4. CT images obtained 2 months after the operation was performed. Reconstruction of the CT image showed that the EVB-Stent expanded completely in the MPV, the ¹²⁵I seeds strand was fixed tightly at the center of the stent, and no thrombus was found in the entire PV.

cal feasibility of the transhepatic PV placement of an EVB-Stent into a pig model. However, its manipulative feasibility for HCC patients with MPVTT remains to be elucidated through clinical trials.

In this study, 14 ¹²⁵I seeds were encapsulated in a 4-Fr sterile plastic tube to create a seeds strand and then fixed

at the center of the stent. SPECT/CT showed that the radiation emitted by the ¹²⁵I seeds was uniformly distributed in the PV. The overall isodose of radiation can exert an elongating tumor killing effect and minimize the irradiation of the surrounding normal tissue. Moreover, the potentially irregular and asymmetric radiation emitted by the ¹²⁵I seeds

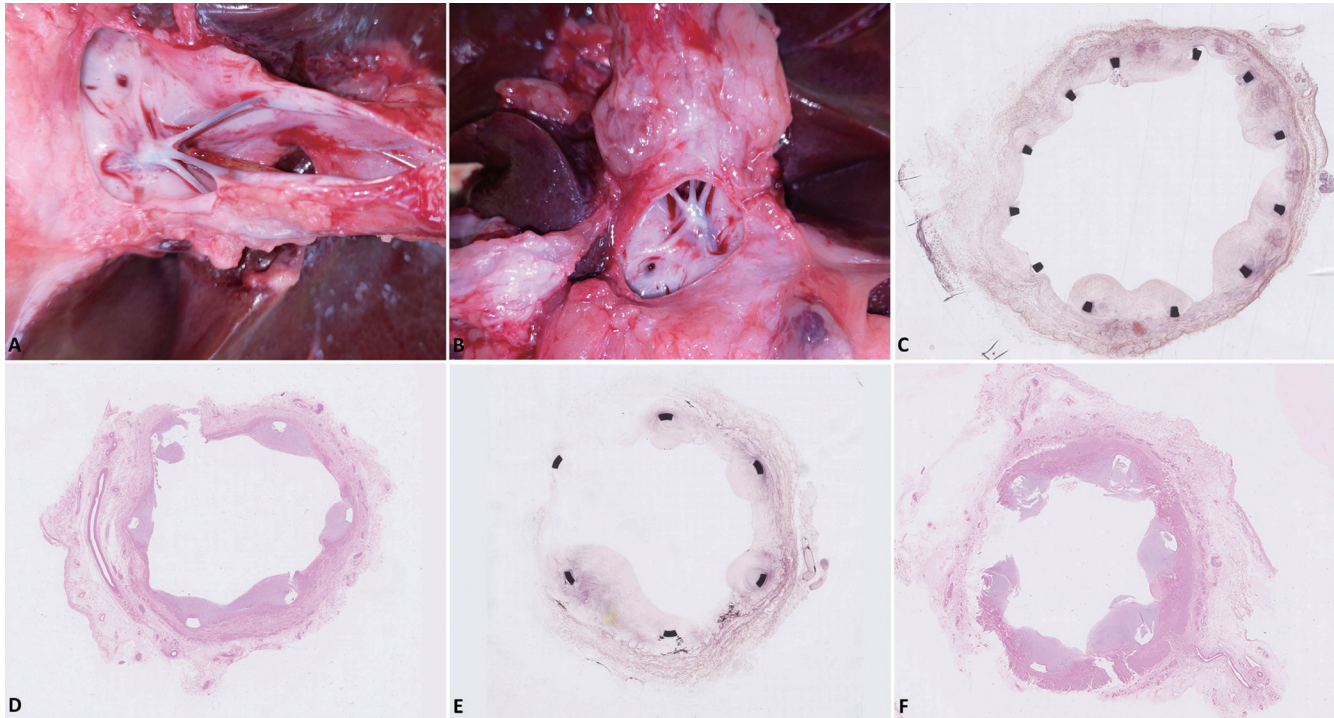


Fig. 5. Necropsy and pathological examination results obtained 2 months after the procedure. (A) There was no evidence of thrombosis in the stented portal vein and on both sides of the stent. The ¹²⁵I seeds strand was completely covered by neointima, without narrowing or occlusion. (B) In one pig, slight intimal hyperplasia and incomplete neointimal cover was observed at the tapered end of the YZP-Stent near the hilar end. (C, D) Hematoxylin and eosin staining showing the central grid section of the YZP-Stent and the densest section of the stent mesh was also almost completely covered by neointimal growth, which shows the proper incorporation of the YZP-Stent. Its surface was smooth and free from tears, peelings, or injuries. (E, F) At the tapered end of stent near the hilar end, necropsy and pathological imaging showed that there was a slight intimal hyperplasia but intimal overgrowth or neointimal growth that completely covered the stent was not observed.

strand for the eccentric location in the PV can be avoided and the potential heterotopia of implanted ¹²⁵I seeds strand can also be avoided. None of the animals were found to show signs of PV thrombosis after EVB-Stent placement during the 2-month follow-up period. On one hand, proper anticoagulant therapy with heparin is of great importance in preventing thrombosis. On the other hand, the anti-neointimal hyperplasia effect provided by the implantation of the ¹²⁵I seeds strand³⁰ allowed for a longer patency period to be achieved by the MPV stent. Moreover, the central location of the ¹²⁵I seeds strand in the stented PV contributed to full conformal radiotherapy implementation on the MPV. Hence, incomplete neointimal hyperplasia coverage of the stent was observed but without thickening or resulting in PV stenosis after 2 months of deployment of the EVB-Stent.

Studies have established that persistent low-energy ¹²⁵I irradiation therapy may keep tumor cells in the sensitive resting period, resulting in tumor cell apoptosis, which can induce epigenetic changes that reactivate silenced tumor suppressor genes, and damage to the DNA to kill cancer cells.^{14,31} For end-stage patients, the combination of EVB and PV stent implantation may not only provide a long period in which symptoms of portal hypertension are relieved, but may also suppress the progression of tumor thrombus. Furthermore, compared with external radiotherapy, brachytherapy using ¹²⁵I seeds provides a high local dose close to the seeds and a steep fall in the dose provided to the surrounding tissues, which exerts an adequate tumor suppression effect with limited damage exerted onto the surrounding normal tissue.¹⁵ Since ¹²⁵I seeds have a long half-life (59.4 days), a sustained level of radiation can be exerted to inhibit the replication of tumor cells and induce tumor cell apoptosis.³² In this study, the EVB-Stent, which was used as a novel endovascular brachytherapy stent kit, provided three obvious advantages compared with its current usage. First, it may induce tumor cell apoptosis more effectively and inhibit the progression of tumor thrombus, since the gamma rays are evenly distributed at the center of the obstructed PV. Second, the support provided by the stent resulted in the ¹²⁵I seeds strand being firmly fixed at the center of the stent without displacement. Third, the central deployment of the radiative strand provided an opportunity to further improve the antitumor effect by increasing the dosage provided by the ¹²⁵I seeds without obvious damage to the PV wall.

There are several limitations in our study. First and foremost, only six pigs were used, which may introduce a case-by-case bias. Second, the use of healthy animals without tumor thrombus or portal hypertension can barely reproduce the complex environment in a real human diseased vessel in which a stent must be implanted. Finally, long-term results of the efficacy and safety of the EVB-Stent transhepatic PV implantation, as well as its impact on the vessel wall over longer periods of time, are still pending. The creation of an ideal animal model with PVTT remains a daunting challenge but is urgently required to demonstrate the antitumor efficacy and safety of the transhepatic PV placement of the EVB-Stent.

Conclusions

Mid-term preclinical results demonstrated the feasibility and safety of the percutaneous transhepatic MPV implantation of a novel EVB-Stent into a live porcine model. The implantation of the stent did not produce thrombosis or stenosis. Further studies using large samples of animals with or without PVTT are needed to further assess the efficacy and safety of this innovative stent before it can be considered suitable for clinical application.

Acknowledgments

We give our thanks to Hongpu Medical Device Corporation for their help in building the self-expanding Nitinol stent. The authors are very grateful to Dr. Xianglin Hu of Fudan University Shanghai Cancer Center for his professional suggestions for the English writing.

Funding

This study has received funding by the Shanghai Science Committee (16411968600), Clinical Research Special Fund from Zhongshan Hospital, Fudan University (2013SY060) and National Clinical Research Center for International Medicine.

Conflict of interest

The authors have no conflict of interests related to this publication.

Author contributions

Study concept and design (JL, ZY), acquisition of data (ND, JM, YZ), analysis and interpretation of data (MY, WZ, ZZ), obtained funding (ZY), drafting of the manuscript (ND, JM), critical revision of the manuscript for important intellectual content (MY, WZ), administrative, technical, or material support, study supervision (JL).

Data sharing statement

All data are available upon reasonable request.

References

- [1] Bray F, Ferlay J, Soerjomataram I, Siegel RL, Torre LA, Jemal A. Global cancer statistics 2018: GLOBOCAN estimates of incidence and mortality worldwide for 36 cancers in 185 countries. *CA Cancer J Clin* 2018;68(6):394–424. doi:10.3322/caac.21492.
- [2] Akinyemiju T, Abera S, Ahmed M, Alam N, Alemayohu MA, Allen C, *et al*. The burden of primary liver cancer and underlying etiologies from 1990 to 2015 at the global, regional, and national level: Results from the Global Burden of Disease study 2015. *JAMA Oncol* 2017;3(12):1683–1691. doi:10.1001/jamaoncol.2017.3055.
- [3] Cheung TK, Lai CL, Wong BC, Fung J, Yuen MF. Clinical features, biochemical parameters, and virological profiles of patients with hepatocellular carcinoma in Hong Kong. *Aliment Pharmacol Ther* 2006;24(4):573–583. doi:10.1111/j.1365-2036.2006.03029.x.
- [4] Bruix J, Raoul JL, Sherman M, Mazzaferro V, Bolondi L, Craxi A, *et al*. Efficacy and safety of sorafenib in patients with advanced hepatocellular carcinoma: subanalyses of a phase III trial. *J Hepatol* 2012;57(4):821–829. doi:10.1016/j.jhep.2012.06.014.
- [5] Cheng AL, Kang YK, Chen Z, Tsao CJ, Qin S, Kim JS, *et al*. Efficacy and safety of sorafenib in patients in the Asia-Pacific region with advanced hepatocellular carcinoma: a phase III randomised, double-blind, placebo-controlled trial. *Lancet Oncol* 2009;10(1):25–34. doi:10.1016/S1470-2045(08)70285-7.
- [6] Llovet JM, Ricci S, Mazzaferro V, Hilgard P, Gane E, Blanc JF, *et al*. Sorafenib in advanced hepatocellular carcinoma. *N Engl J Med* 2008;359(4):378–390. doi:10.1056/NEJMoa0708857.
- [7] Lee DS, Seong J. Radiotherapeutic options for hepatocellular carcinoma with portal vein tumor thrombosis. *Liver Cancer* 2014;3(1):18–30. doi:10.1159/000343855.
- [8] Shen L, Xi M, Zhao L, Zhang X, Wang X, Huang Z, *et al*. Combination therapy after TACE for hepatocellular carcinoma with macroscopic vascular invasion: Stereotactic body radiotherapy versus sorafenib. *Cancers (Basel)* 2018;10(12):516. doi:10.3390/cancers10120516.
- [9] Choi GH, Shim JH, Kim MJ, Ryu MH, Ryoo BY, Kang YK, *et al*. Sorafenib alone versus sorafenib combined with transarterial chemoembolization for advanced-stage hepatocellular carcinoma: results of propensity score

- analyses. *Radiology* 2013;269(2):603–611. doi:10.1148/radiol.13130150.
- [10] Jelic S, Sotiropoulos GC. Hepatocellular carcinoma: ESMO Clinical Practice Guidelines for diagnosis, treatment and follow-up. *Ann Oncol* 2010;21(Suppl 5):v59–v64. doi:10.1093/annonc/mdq166.
- [11] Yuan D, Gao Z, Zhao J, Zhang H, Wang J. ¹²⁵I seed implantation for hepatocellular carcinoma with portal vein tumor thrombus: A systematic review and meta-analysis. *Brachytherapy* 2019;18(4):521–529. doi:10.1016/j.brachy.2019.01.014.
- [12] Zhang XP, Gao YZ, Chen ZH, Chen MS, Li LQ, Wen TF, *et al*. An eastern hepatobiliary surgery hospital/portal vein tumor thrombus scoring system as an aid to decision making on hepatectomy for hepatocellular carcinoma patients with portal vein tumor thrombus: A multicenter study. *Hepatology* 2019;69(5):2076–2090. doi:10.1002/hep.30490.
- [13] Huo YR, Eslick GD. Transcatheter arterial chemoembolization plus radiotherapy compared with chemoembolization alone for hepatocellular carcinoma: A systematic review and meta-analysis. *JAMA Oncol* 2015;1(6):756–765. doi:10.1001/jamaoncol.2015.2189.
- [14] Gao B, Shen L, He KW, Xiao WH. GNRs@SiO₂-FA in combination with radiotherapy induces the apoptosis of HepG2 cells by modulating the expression of apoptosis-related proteins. *Int J Mol Med* 2015;36(5):1282–1290. doi:10.3892/ijmm.2015.2358.
- [15] Zhang W, Luo J, Liu Q, Ma J, Qu X, Yang M, *et al*. Brachytherapy with Iodine-125 seeds strand for treatment of main portal vein tumor thrombi: an experimental study in a rabbit model. *Am J Cancer Res* 2016;6(3):587–599.
- [16] Zhang W, Yan Z, Luo J, Fang Z, Wu L, Liu Q, *et al*. Iodine-125 seeds strand for treatment of tumor thrombus in inferior vena cava: an experimental study in a rabbit model. *Cardiovasc Intervent Radiol* 2013;36(5):1371–1382. doi:10.1007/s00270-013-0628-9.
- [17] Liu PH, Huo TI, Miksad RA. Hepatocellular carcinoma with portal vein tumor involvement: Best management strategies. *Semin Liver Dis* 2018;38(3):242–251. doi:10.1055/s-0038-1666805.
- [18] Luo J, Yan Z, Liu Q, Qu X, Wang J. Endovascular placement of iodine-125 seed strand and stent combined with chemoembolization for treatment of hepatocellular carcinoma with tumor thrombus in main portal vein. *J Vasc Interv Radiol* 2011;22(4):479–489. doi:10.1016/j.jvir.2010.11.029.
- [19] Yang M, Fang Z, Yan Z, Luo J, Liu L, Zhang W, *et al*. Transarterial chemoembolization (TACE) combined with endovascular implantation of an iodine-125 seed strand for the treatment of hepatocellular carcinoma with portal vein tumour thrombosis versus TACE alone: a two-arm, randomised clinical trial. *J Cancer Res Clin Oncol* 2014;140(2):211–219. doi:10.1007/s00432-013-1568-0.
- [20] Zhang ZH, Liu QX, Zhang W, Ma JQ, Wang JH, Luo JJ, *et al*. Combined endovascular brachytherapy, sorafenib, and transarterial chemobolization therapy for hepatocellular carcinoma patients with portal vein tumor thrombus. *World J Gastroenterol* 2017;23(43):7735–7745. doi:10.3748/wjg.v23.i43.7735.
- [21] Luo JJ, Zhang ZH, Liu QX, Zhang W, Wang JH, Yan ZP. Endovascular brachytherapy combined with stent placement and TACE for treatment of HCC with main portal vein tumor thrombus. *Hepatol Int* 2016;10(1):185–195. doi:10.1007/s12072-015-9663-8.
- [22] Yamakado K, Nakatsuka A, Tanaka N, Fujii A, Terada N, Takeda K. Malignant portal venous obstructions treated by stent placement: significant factors affecting patency. *J Vasc Interv Radiol* 2001;12(12):1407–1415. doi:10.1016/s1051-0443(07)61699-6.
- [23] Zhu HD, Guo JH, Mao AW, Lv WF, Ji JS, Wang WH, *et al*. Conventional stents versus stents loaded with (125)iodine seeds for the treatment of unresectable oesophageal cancer: a multicentre, randomised phase 3 trial. *Lancet Oncol* 2014;15(6):612–619. doi:10.1016/S1470-2045(14)70131-7.
- [24] Wu YF, Wang T, Yue ZD, Zhao HW, Wang L, Fan ZH, *et al*. Stents combined with iodine-125 implantation to treat main portal vein tumor thrombus. *World J Gastrointest Oncol* 2018;10(12):496–504. doi:10.4251/wjgo.v10.i12.496.
- [25] Lin J, Jiang H, Yang W, Jiang N, Zheng Q, Huang N, *et al*. Predictive factors of benefit from iodine-125 brachytherapy for hepatocellular carcinoma with portal vein tumor thrombosis. *Brachytherapy* 2019;18(2):233–239. doi:10.1016/j.brachy.2018.10.002.
- [26] Sun H, Zhang M, Liu R, Liu Y, Hou Y, Wu C. Endovascular implantation of ¹²⁵I seed combined with transcatheter arterial chemoembolization for unresectable hepatocellular carcinoma. *Future Oncol* 2018;14(12):1165–1176. doi:10.2217/fon-2017-0354.
- [27] Zhu HD, Guo JH, Zhu GY, He SC, Fang W, Deng G, *et al*. A novel biliary stent loaded with (125)I seeds in patients with malignant biliary obstruction: preliminary results versus a conventional biliary stent. *J Hepatol* 2012;56(5):1104–1111. doi:10.1016/j.jhep.2011.12.018.
- [28] Lu J, Guo JH, Zhu HD, Zhu GY, Chen L, Teng GJ. Safety and efficacy of irradiation stent placement for malignant portal vein thrombus combined with transarterial chemoembolization for hepatocellular carcinoma: A single-center experience. *J Vasc Interv Radiol* 2017;28(6):786–794.e3. doi:10.1016/j.jvir.2017.02.014.
- [29] Pesce A, Boncoraglio A, Basile A, Puleo S. Percutaneous transhepatic Y-shaped stent placement in portal-superior mesenteric vein tumor thrombosis before right colectomy. *Surg Laparosc Endosc Percutan Tech* 2018;28(1):e30–e32. doi:10.1097/SLE.0000000000000496.
- [30] Giday SA, Clarke JO, Buscaglia JM, Shin EJ, Ko CW, Magno P, *et al*. EUS-guided portal vein catheterization: a promising novel approach for portal angiography and portal vein pressure measurements. *Gastrointest Endosc* 2008;67(2):338–342. doi:10.1016/j.gie.2007.08.037.
- [31] Sidawy AN, Weiswasser JM, Waksman R. Peripheral vascular brachytherapy. *J Vasc Surg* 2002;35(5):1041–1047. doi:10.1067/mva.2002.123751.
- [32] Ma JX, Jin ZD, Si PR, Liu Y, Lu Z, Wu HY, *et al*. Continuous and low-energy ¹²⁵I seed irradiation changes DNA methyltransferases expression patterns and inhibits pancreatic cancer tumor growth. *J Exp Clin Cancer Res* 2011;30(1):35. doi:10.1186/1756-9966-30-35.