








# Useful Ultrasound Findings of Pediatric Patients with Equivocal Results of Appendicitis: Analysis Based on a Structured Report Form

애매한 초음파 결과를 보인 소아 환자에서  
충수돌기염을 감별하는데 유용한 초음파 소견:  
구조화 판독문에 기초한 분석

Jiyoung Choi, MD , Hyuk Jung Kim, MD\* , Suk Ki Jang, MD ,  
Hyun Jin Kim, MD , Jae Woo Yeon, MD 

Department of Radiology, Daejin Medical Center Bundang Jesaeng General Hospital,  
Seongnam, Korea

**Purpose** To identify the features that can be used for differentiating appendicitis from non-appendicitis in pediatric patients with equivocal ultrasound (US) results.

**Materials and Methods** A total of 53 pediatric patients ( $\leq 18$  years old) with equivocal results on US examination for suspected appendicitis between November 2012 and October 2017 were included. US evaluation was conducted based on information retrieved from a predefined structured report form. Then, the likelihood of appendicitis was prospectively classified into five categories. The equivocal results were considered as grade 3 (indeterminate) and grade 4 (probably appendicitis).

**Results** Of the 53 patients, 25 (47.2%) and 28 (52.8%) were classified into grade 3 and 4 groups, respectively. Among the individual US findings, increased vascularity of the appendiceal wall and peri-appendiceal fat infiltration were independent findings associated with the diagnosis of appendicitis ( $p = 0.005$ ,  $p = 0.045$ , respectively) in the multivariate logistic regression analysis and showed the highest diagnostic accuracy (69.8% and 62.3%, respectively).

**Conclusion** Increased vascularity within the appendiceal wall and peri-appendiceal fat infiltration were significant predictors of appendicitis in patients with equivocal US findings.

**Index terms** Appendicitis; Appendix; Children; Ultrasound; Diagnosis

Received December 11, 2019

Revised March 25, 2020

Accepted May 7, 2020

\*Corresponding author

Hyuk Jung Kim, MD  
Department of Radiology,  
Daejin Medical Center Bundang  
Jesaeng General Hospital,  
20 Seohyeon-ro 180beon-gil,  
Bundang-gu, Seongnam 13590,  
Korea.

Tel 82-31-779-0051

Fax 82-31-779-0062


E-mail hyukjungk@naver.com

This is an Open Access article distributed under the terms of the Creative Commons Attribution Non-Commercial License (<https://creativecommons.org/licenses/by-nc/4.0/>) which permits unrestricted non-commercial use, distribution, and reproduction in any medium, provided the original work is properly cited.

## ORCID iDs

Jiyoung Choi 


[https://  
orcid.org/0000-0002-0170-171X](https://orcid.org/0000-0002-0170-171X)

Hyuk Jung Kim 


[https://  
orcid.org/0000-0002-4629-4142](https://orcid.org/0000-0002-4629-4142)

Suk Ki Jang 

[https://  
orcid.org/0000-0002-8625-7573](https://orcid.org/0000-0002-8625-7573)

Hyun Jin Kim 

[https://  
orcid.org/0000-0002-3411-3690](https://orcid.org/0000-0002-3411-3690)

Jae Woo Yeon 

[https://  
orcid.org/0000-0002-0516-1220](https://orcid.org/0000-0002-0516-1220)

## INTRODUCTION

Acute appendicitis is one of the most common acute diseases requiring emergency surgery in pediatric patients. Ultrasound (US) is the preferred primary imaging modality for diagnosing acute appendicitis in children because of lack of ionizing radiation or need for patient preparation (1). US is highly specific for the diagnosis of appendicitis in children without significant difference in the specificity as compared to that of CT (2); however, US has significantly lower sensitivity than CT (2), and the rates of identification of the appendix and sensitivity for diagnosis of appendicitis vary across sites (3).

Non-visualization of the appendix is the most common factor of interpretive uncertainty; whereas, clear visualization of the appendix on US with ambiguous findings of normalcy or presence of appendicitis is another common subset of equivocal cases (4). Previous reports indicated that the incidence of equivocal results from US evaluation of appendicitis varies from 4% to 14% (5-8). The variable incidence may reflect inconsistent and ambiguous definition of “equivocal” in those studies.

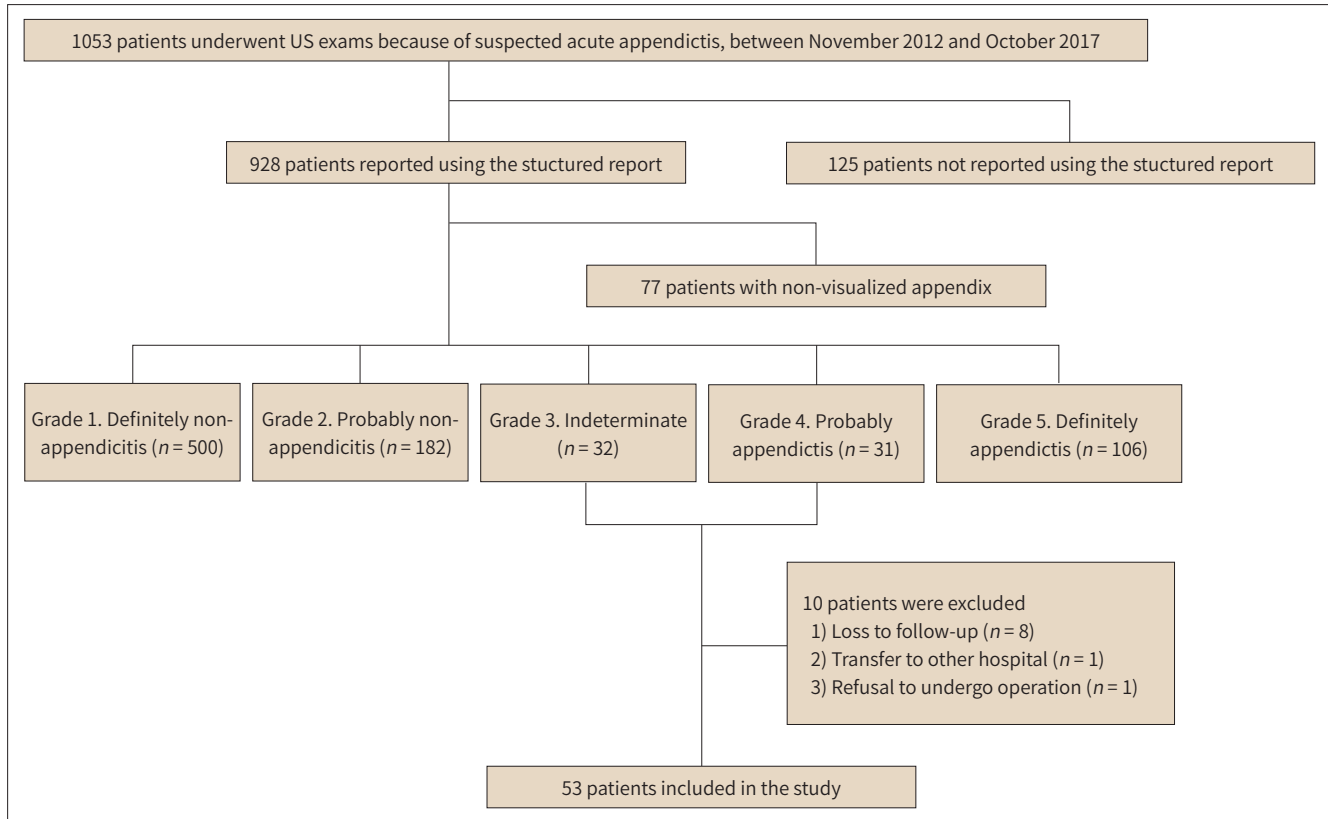
Equivocal US exams can increase the time to diagnosis, which can lead to delays before appendectomy, higher rate of postoperative complications (8, 9), and unnecessary surgery such as negative appendectomy (10). Therefore, it is important to decrease the rate of equivocal US exam results, although their complete elimination is not possible. Our institution developed a standardized structured report (SR) for appendix US to improve communication with referring physicians (11), in which, the radiologists are asked to describe or check predefined US findings suggestive of appendicitis and conclude the likelihood of appendicitis using a 5-point scoring system that includes equivocal US exam results. The purpose of this study was to identify those features that are useful to differentiate appendicitis from non-appendicitis in pediatric patients with equivocal US results.

## MATERIALS AND METHODS

### STUDY POPULATION

Our Institutional Review Board approved this study and waived the requirement for informed consent (IRB No. 2018-11-007-001). We included 1053 pediatric patients of age 1–18 years who underwent US for suspected acute appendicitis between November 2012 and October 2017. Of these patients, US exams not reported using SR ( $n = 125$ ) were excluded. US results of indicated non-visualized appendix ( $n = 77$ ) also be excluded because US findings of them cannot be evaluated. Among the remaining 851 patients, 245 patients had equivocal US exam results based on initial reports as follows: probably non-appendicitis (grade 2,  $n = 182$ ), indeterminate (grade 3,  $n = 32$ ), and probably appendicitis (grade 4,  $n = 31$ ); of these, we excluded grade 2 group because they did not cause clinical ambiguity in the diagnosis of appendicitis. There was no false positive or negative result in the grade 2 group. Of remaining 63 patients, 10 were also excluded for the following reasons: 1) lost to follow-up ( $n = 8$ ); 2) transfer to another hospital ( $n = 1$ ); 3) refusal to undergo operation ( $n = 1$ ). Finally, 53 pediatric patients with equivocal US exam results for suspected appendicitis were included in the study (Fig. 1). Medical records of the patients were reviewed for demographic and clinical variables.

Fig. 1. Flow diagram of the patients.



## US EXAMINATION AND INTERPRETATION

All US examinations were performed with an iU22 gray-scale US system (Philips Healthcare, Eindhoven, Netherlands) using 5–8-MHz curved or 5–12-MHz linear probes, followed by color Doppler US at low-flow settings of the lowest available pulse repetition frequency, highest possible gain without background noise, and 100-Hz low-wall filter. All US examinations were performed during daytime business-hours by residents (with 1–4 years' training) under the supervision of two experienced abdominal radiologists (with 16 and 9 years' experience), or by the same attending abdominal radiologists, using a graded-compression technique. If the residents initially performed the US examinations, the attending abdominal radiologist immediately reviewed and confirmed the results. As routine protocol, the appendix US examinations were not conducted by the radiologists during off-hours at our hospital.

Appendix US results were interpreted using our institutions' predefined SR form (Appendix Table 1) based on literature review (12–15) and the likelihood of appendicitis was prospectively scored using five grades: grade 1, definitely non-appendicitis; grade 2, probably non-appendicitis; grade 3, indeterminate; grade 4, probably appendicitis; grade 5, definitely appendicitis. The SR form provided information on the degree of visibility of the appendix (entirely, partly, and not identified), and presence or absence of the following US exam findings: 1) non-compressible enlarged appendix (> 6 mm); 2) appendiceal wall thickening compared with the adjacent normal bowel wall; 3) US-guided tenderness; 4) peri-appendiceal fat infiltration as indicated by increased peri-appendiceal echogenicity; 5) increased vascularity of the

appendiceal wall compared with that of adjacent bowel. In addition, it allowed textual description of additional findings that were indirectly suggestive of appendicitis, such as the wall thickening at the cecal base, fluid in the right lower quadrant (RLQ) of the abdomen, or presence of appendicolith, etc. But, they were excluded from the following analysis because there were variability and inconsistency in interpreting and reporting them among the performing radiologists. The maximum appendiceal diameter and wall thickness were measured and recorded in real time. We did not define specific criteria for diagnosing appendicitis and instead relied on the subjective decision of the performing radiologist. The SR form was implemented by our institution in November, 2012 and is since routinely used in daily practice.

## REFERENCE STANDARD

The diagnosis of appendicitis was based on the surgical and pathological findings. If the pathological diagnosis differed from the operative diagnosis, the pathological diagnosis of acute appendicitis based on the presence of neutrophil infiltration of the submucosa or muscularis propria was considered as the final diagnosis. The absence of appendicitis was confirmed through pathologic analysis (negative appendectomy) or assumed based on information retrieved from the medical records.

## STATISTICAL ANALYSES

Chi-square test or Fisher exact test was used to compare the frequencies of categorical variables. The *t* test was performed for continuous variables. To assess the independent variables for discrimination of appendicitis, multivariable logistic regression analyses were conducted with backward selection of significant variables in univariable analysis for the patients with equivocal US exam results. Sensitivity, specificity, positive predictive value, negative predictive value, and accuracy of each significant imaging finding were also calculated. A *p*-value of less than 0.05 was considered as statistically significant difference. All analyses were performed using PASW Statistics for Windows (version 18.0; SPSS Inc., Chicago, IL, USA) and MedCalc (version 12.1.4; MedCalc Software, Mariakerke, Belgium).

## RESULTS

### PATIENT CHARACTERISTICS & US FINDINGS

Of the 53 pediatric patients (28 male and 25 female patients; mean age,  $11.1 \pm 3.9$  years) with equivocal US exam findings, 22 had acute appendicitis and 31 did not. In all 22 patients (11 male and 11 female patients; mean age,  $10.1 \pm 3.5$  years) with acute appendicitis, the diagnosis was confirmed using operative and pathologic evaluation. Among the 31 patients (17 male and 14 female patients; mean age  $11.8 \pm 4.1$  years) without acute appendicitis, the diagnosis was confirmed at surgery in nine patients, additional examination such as CT or follow-up US exam in 20 patients, and clinical follow-up in 2 patients. The final pathologic diagnosis of nine patients who underwent negative appendectomy was serosal congestion ( $n = 6$ ) and fecalith impaction ( $n = 3$ ). The final diagnosis of the remaining 22 patients was as follows; non-specific abdominal pain ( $n = 9$ ), enteritis or enterocolitis ( $n = 7$ ), rupture of the right ovarian cyst ( $n = 2$ ), mesenteric lymphadenitis ( $n = 2$ ), acute pyelonephritis in the right kidney ( $n = 1$ ), and paralytic

ileus ( $n = 1$ ). All patients were successfully treated by conservative therapy or showed improvement of symptom at follow-up. The most common finding of equivocal US exam results was US-guided tenderness (94.3%), followed by the non-compressible enlarged appendix (88.7%), appendiceal wall thickening (79.2%), peri-appendiceal fat infiltration (60.4%) and increased vascularity of the appendiceal wall (52.8%) (Table 1).

## INDEPENDENT US FINDINGS

In the univariate logistic regression analyses, peri-appendiceal fat infiltration [odds ratio (OR) = 3.6, 95% confidence interval (CI) = 1.0–12.3,  $p = 0.039$ ] and increased vascularity of the

**Table 1.** Patient Characteristics and US Findings of the Equivocal Groups

	All ( $n = 53$ )	Grade 3, Indeterminate ( $n = 25, 47.2\%$ )	Grade 4, Probably Appendicitis ( $n = 28, 52.8\%$ )	<i>p</i> -Value
Age, years	11.1 ± 3.9	11.1 ± 4.3	11.1 ± 3.7	0.276
Sex				0.662
Female, $n$ (%)	25 (47.2)	11 (44.0)	14 (50.0)	
Male, $n$ (%)	28 (52.8)	14 (56.0)	14 (50.0)	
Visualization of appendix				0.563
Partial	17 (32.1)	9 (36.0)	8 (28.6)	
Entire	36 (67.9)	16 (64.0)	20 (71.4)	
Appendix maximal diameter (mm)	7.0 ± 1.7	6.2 ± 1.3	7.7 ± 1.7	0.555
Appendiceal wall thickness (mm)	2.2 ± 0.6	2.0 ± 0.6	2.4 ± 0.5	0.795
Non-compressible enlarged appendix				0.06
Absent	6 (11.3)	5 (20.0)	1 (3.6)	
Present	47 (88.7)	20 (80.0)	27 (96.4)	
Appendiceal wall thickening				0.01
Absent	11 (20.8)	9 (36.0)	2 (7.1)	
Present	42 (79.2)	16 (64.0)	26 (92.9)	
US-guided tenderness				0.486
Absent	3 (5.7)	2 (8.0)	1 (3.6)	
Present	50 (94.3)	23 (92.0)	27 (96.4)	
Peri-appendiceal fat infiltration				0.021
Absent	21 (39.6)	14 (56.0)	7 (25.0)	
Present	32 (60.4)	11 (44.0)	21 (75.0)	
Increased vascularity of the appendiceal wall				0.004
Absent	25 (47.2)	17 (68.0)	8 (28.6)	
Present	28 (52.8)	8 (32.0)	20 (71.4)	
Added exam (CT or F.U US)	31 (58.5)	22 (88.0)	9 (32.1)	< 0.001
Appendectomy	31 (58.5)	7 (28.0)	24 (85.7)	< 0.001
Appendicitis	22 (41.5)	2 (8.0)	20 (83.3)	< 0.001
Negative appendectomy rate, %	29.0 (9/31)	71.4 (5/7)	16.7 (4/24)	< 0.001

F.U = follow-up, US = ultrasound

appendiceal wall (OR = 6.2, 95% CI = 1.8–21.3,  $p = 0.004$ ) were significant US findings associated with the surgical diagnosis of appendicitis; those US findings were independent factors associated with the surgical diagnosis of appendicitis (OR = 3.9, 95% CI = 1.0–15.0,  $p = 0.045$ ; OR = 6.5, 95% CI = 1.8–24.1,  $p = 0.005$ ) in backward-elimination logistic regression analysis (Table 2).

## DIAGNOSTIC PERFORMANCE OF INDIVIDUAL US FINDINGS

The performance of individual US findings to diagnose appendicitis is shown in Table 3. Increased vascularity of the appendiceal wall showed the highest accuracy of 69.81% (95% CI: 55.66, 81.66%) with sensitivity of 77.27% (95% CI: 54.63, 92.18%), and specificity of 64.52%

**Table 2.** Univariate and Multivariate Logistic Regression Analysis Results for Predicting Appendicitis of the Equivocal Appendix

Variable	Acute Appendicitis No. of Patients (%)	Univariate Analysis		Multivariate Analysis	
		OR (95% CI)	<i>p</i> -Value	OR (95% CI)	<i>p</i> -Value
Non-compressible enlarged appendix					
Absent	1 (4.5)	Reference			
Present	21 (95.5)	4.0 (0.4–37.3)	0.218		
Appendiceal wall thickening					
Absent	0 (0.0)	Reference			
Present	22 (100.0)			0.999	
US-guided tenderness					
Absent	1 (4.5)	Reference			
Present	21 (95.5)	1.4 (0.1–17.0)	0.768		
Peri-appendiceal fat infiltration					
Absent	5 (22.7)	Reference		Reference	
Present	17 (77.3)	3.6 (1.0–12.3)	0.039	3.9 (1.0–15.0)	0.045
Increased vascularity of the appendiceal wall					
Absent	5 (22.7)	Reference		Reference	
Present	17 (77.3)	6.2 (1.8–21.3)	0.004	6.5 (1.8–24.1)	0.005

CI = confidence interval, OR = odds ratio, US = ultrasound

**Table 3.** Diagnostic Performance of the Individual US Findings for Appendicitis

	Sensitivity (%)	Specificity (%)	PPV (%)	NPV (%)	Accuracy (%)
Non-compressible appendix	95.45 (77.16–99.88)	16.13 (5.45–33.73)	44.68 (40.30–49.14)	83.33 (38.53–97.55)	49.06 (35.06–63.16)
Appendiceal wall thickening	100 (84.56–100.00)	35.48 (19.23–54.63)	52.38 (45.87–58.82)	100	62.26 (47.89–75.21)
US-guided tenderness	95.45 (77.16–99.88)	6.45 (0.79–21.42)	42.00 (38.87–45.19)	66.67 (16.19–95.39)	43.40 (29.84–57.72)
Peri-appendiceal fat infiltration	77.27 (54.63–92.18)	51.61 (33.06–69.85)	53.12 (42.48–63.50)	76.19 (57.95–88.14)	62.26 (47.89–75.21)
Increased vascularity of the appendiceal wall	77.27 (54.63–92.18)	64.52 (45.37–80.77)	60.71 (47.73–72.34)	80.00 (63.94–90.02)	69.81 (55.66–81.66)
Peri-appendiceal fat infiltration + increased vascularity of the appendiceal wall	59.09 (36.35–79.29)	83.87 (66.27–94.55)	72.22 (52.02–86.18)	74.29 (63.08–83.01)	73.58 (59.67–84.74)

Data in parentheses are the 95% confidence interval.

NPV = negative predictive value, PPV = positive predictive value, US = ultrasound

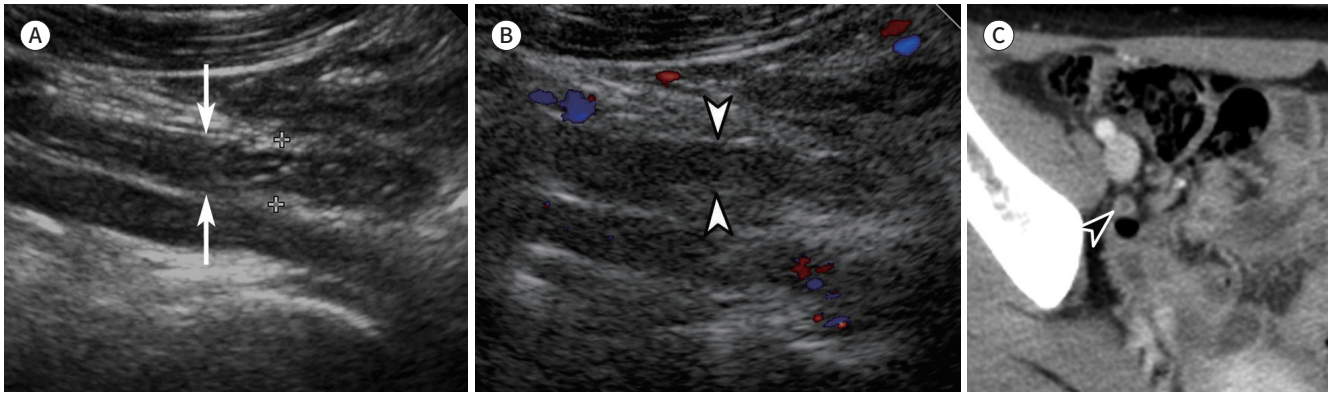
**Fig. 2.** An 11-year-old boy with right lower quadrant pain.

**A.** Gray-scale US shows a mildly dilated appendix (6.8 mm, arrows) and appendiceal wall thickening. US-guided tenderness and peri-appendiceal fat infiltration were positive on the structured report.

**B.** No mural hyperemia can be seen on the color Doppler US image (appendix, arrowheads). The findings were interpreted as probably appendicitis (grade 4).

**C.** Contrast-enhanced CT acquired on the same day showing a normal appendix (arrowhead).

US = ultrasound

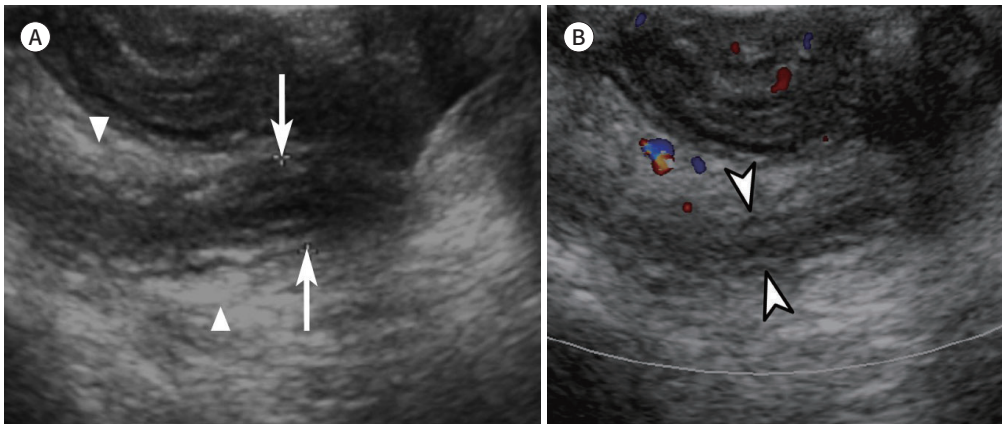


**Fig. 3.** A 13-year-old boy with acute appendicitis.

**A.** Gray-scale US image shows typical features of appendicitis, including a non-compressible enlarged appendix (8.8 mm, arrows), appendiceal wall thickening, and peri-appendiceal fat infiltration (arrowheads). US-guided tenderness was positive on the structured report.

**B.** No mural hyperemia can be seen on the color Doppler US image (appendix, arrowheads). The findings were interpreted as probably appendicitis (grade 4). Laparoscopic appendectomy was performed, and acute appendicitis was confirmed through pathology.

US = ultrasound



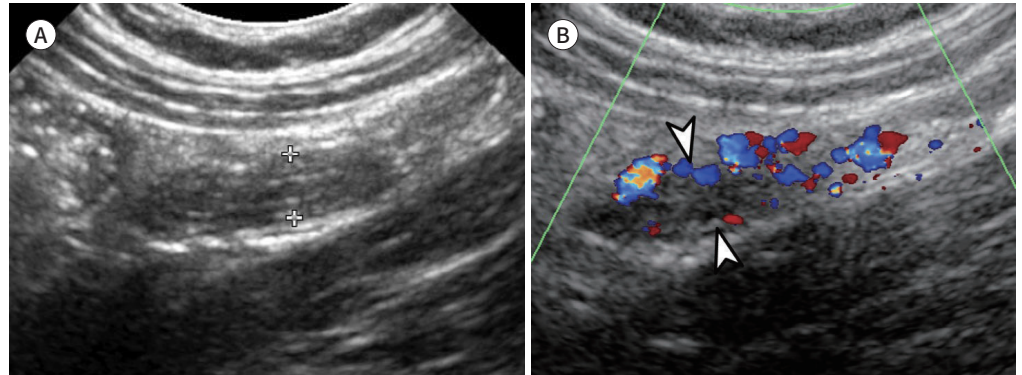
(95% CI: 45.37, 80.77%) to discriminate appendicitis from non-appendicitis (Fig. 2), followed by peri-appendiceal fat infiltration (accuracy 62.26%, sensitivity 77.27%, and specificity 51.61%) (Fig. 3). When these two findings are combined, the specificity improves to 83.87% (95% CI: 66.27, 94.55%) and the overall accuracy increases to 73.58% (95% CI: 59.67, 84.74%) (Fig. 4). Non-compressible enlarged appendix, appendiceal wall thickening and US-guided tenderness showed favorable sensitivity (95.45%, 100%, and 95.45%, respectively) and poor specificity (16.13%, 35.48%, and 6.45%, respectively).

**Fig. 4.** A 5-year-old boy with acute suppurative appendicitis.

**A.** Gray-scale US reveals an appendiceal diameter of 4.8 mm (crisscrosses), which does not meet the criteria of appendicitis. However, other findings of appendicitis, such as appendiceal wall thickening, US-guided tenderness, and peri-appendiceal fat infiltration, were positive on the structured report.

**B.** Color Doppler US image shows the presence of mural hyperemia (appendix, arrowheads). This was interpreted as probably appendicitis (grade 4). Laparoscopic appendectomy was performed, and acute suppurative appendicitis was confirmed through pathology.

US = ultrasound



## DISCUSSION

In our study, increased vascularity of the appendiceal wall (OR = 6.5;  $p = 0.005$ ) and peri-appendiceal fat infiltration (OR = 3.9;  $p = 0.045$ ) were significant US features associated with histologically confirmed appendicitis after surgery. Several previous studies reported similar results to those of our study for the diagnosis of appendicitis in patients with equivocal US exam findings (5, 8, 16, 17). Lim et al. (16) and Xu et al. (17) reported that the presence of hyperemia in the appendiceal wall through color Doppler US was helpful to diagnose appendicitis in patients with an appendix of equivocal size. Telesmanich et al. (8) reported that the loss of mural stratification, peri-appendiceal fat inflammation, and appendicolith were significant predictors of appendicitis in children with equivocal US exam results using a risk-stratified scoring system and SR form. However, our study had some difference as compared to those studies. We included patients with equivocal US exam results using a predefined SR. This design reflects the real-time characteristic of US exam compared with retrospective review studies focusing on US images and enables analysis of variable US exam findings suggesting appendicitis such as the appendiceal wall thickness, US-guided tenderness, peri-appendiceal fat infiltration, and increased vascularity of the appendiceal wall.

The reported incidence of equivocal US exam results in the diagnosis of appendicitis varies from 4% to 14% (5-8), which could be due to the operator-dependent characteristic of US examination and definition of the equivocal group. In our study, the incidence was much higher than reported results when including the grade 2 (probably non-appendicitis) group (28.8%, 245/851), but similar to that reported with the exception of grade 2 group (7.4%, 63/851).

In our study, peri-appendiceal fat infiltration and increased vascularity of the appendiceal wall showed lower specificity (51.6% and 64.5%, respectively). Patients with peri-appendiceal fat infiltration had considerable false-positive rate (46.9%, 15/32); of these, five patients were with alternative diagnosis of fat infiltration in the RLQ of the abdomen on additional CT images



that was interpreted as peri-appendiceal fat infiltration on the US image, such as enterocolitis ( $n = 2$ ), mesenteric lymphadenitis ( $n = 1$ ), or rupture of the right ovarian cyst ( $n = 2$ ). The remaining nine patients underwent additional CT or surgery but the cause of peri-appendiceal fat infiltration was not determined. The patients with increased vascularity of the appendiceal wall had slightly lower false-positives rate (39.3%, 11/28) than those with peri-appendiceal fat infiltration; of these 11 patients, five were considered to have secondary appendicitis due to inflammation of the adjacent organs including enterocolitis ( $n = 4$ ) and right acute pyelonephritis ( $n = 1$ ). This is explained by a previous report indicating that mural hyperemia is effective to distinguish between appendicitis and the normal appendix, but not between primary and secondary appendicitis (18). The remaining six patients had no specific diagnosis and some of them may have true appendicitis since spontaneous resolution of simple appendicitis can occur (19). There were false negatives in five of the patients with appendicitis (22.7%, 5/22); of these, two patients were diagnosed with acute suppurative appendicitis, two with acute gangrenous appendicitis, and one with peri-appendiceal abscess formation. A previous report indicated that there were few or no signals in case of appendicitis with necrosis or perforation (20), which may account for the false negatives in the latter three cases but in the former two cases. As previous studies (5, 17), it is still unclear why this inconsistency exists within the same pathological category of acute appendicitis. The specificity can be improved by the combination of two findings. In our study, the combined two findings showed an increased specificity of 83.87% and overall diagnostic accuracy of 73.58%, which may be due to the complementary roles of the two findings to reflect different pathologies.

Our study has several limitations. First, there is potential selection bias due to exclusion of 11.9% (125/1053) of cases that did not follow the SR. However, this effect may be limited because the incidence of appendicitis in the excluded cases (15.2%, 19/125) was not significantly different from that in the included cases (14.2%, 132/928). We also excluded the cases of non-visualization of the appendix with or without secondary findings of appendicitis, such as the wall thickening at the cecal base, fluid in the RLQ of the abdomen, enlarged mesenteric lymph nodes, or presence of appendicolith, because the secondary US findings were provided as descriptive text and there was variability and inconsistency in interpretation among the radiologists who performed the US exam; the prevalence of appendicitis in this group was 5.2% (4/77). Second, we did not retrospectively review the US imaging findings because we considered that since US is a real-time imaging modality, the SR by the attending radiologists provided more relevant information than retrospective review of the captured US images that does not allow adjustment of observation and description errors. Finally, the present study was performed at a single institution with a relatively small population. Additional multi-center study including larger population is required to validate our results.

In conclusion, increased vascularity of the appendiceal wall and peri-appendiceal fat infiltration were significant predictors of appendicitis in the equivocal appendix [grade 3 (indeterminate) and grade 4 (probably appendicitis)] group.

#### Author Contributions

Conceptualization, K.H.J.; data curation, C.J., K.H.J.; formal analysis, K.H.J., C.J.; funding acquisition, K.H.J.; investigation, all authors; methodology, K.H.J., C.J.; project administration, K.H.J.; resources, K.H.J., C.J.; software, C.J.; supervision, K.H.J.; validation, K.H.J.; visualization, C.J.; writing—

original draft, C.J.; and writing—review & editing, K.H.J.

### Conflicts of Interest

The authors have no potential conflicts of interest to disclose.

### Acknowledgments

This research was supported by grants from the Central Medical Service. Co., Ltd. (DMC 2018-11-007-001).

### REFERENCES

1. Puylaert JB, Van der Zant FM, Rijke AM. Sonography and the acute abdomen: practical considerations. *AJR Am J Roentgenol* 1997;168:179-186
2. Doria AS, Moineddin R, Kellenberger CJ, Epelman M, Beyene J, Schuh S, et al. US or CT for diagnosis of appendicitis in children and adults? A meta-analysis. *Radiology* 2006;241:83-94
3. Mittal MK, Dayan PS, Macias CG, Bachur RG, Bennett J, Dudley NC, et al. Performance of ultrasound in the diagnosis of appendicitis in children in a multicenter cohort. *Acad Emerg Med* 2013;20:697-702
4. Larson DB, Trout AT, Fierke SR, Towbin AJ. Improvement in diagnostic accuracy of ultrasound of the pediatric appendix through the use of equivocal interpretive categories. *AJR Am J Roentgenol* 2015;204:849-856
5. Kim MS, Kwon HJ, Kang KA, Do IG, Park HJ, Kim EY, et al. Diagnostic performance and useful findings of ultrasound re-evaluation for patients with equivocal CT features of acute appendicitis. *Br J Radiol* 2018;91:20170529
6. Athans BS, Depinet HE, Towbin AJ, Zhang Y, Zhang B, Trout AT. Use of clinical data to predict appendicitis in patients with equivocal US findings. *Radiology* 2016;280:557-567
7. Ang A, Chong NK, Daneman A. Pediatric appendicitis in “real-time”: the value of sonography in diagnosis and treatment. *Pediatr Emerg Care* 2001;17:334-340
8. Telesmanich ME, Orth RC, Zhang W, Lopez ME, Carpenter JL, Mahmood N, et al. Searching for certainty: findings predictive of appendicitis in equivocal ultrasound exams. *Pediatr Radiol* 2016;46:1539-1545
9. Kaiser S, Jorulf H, Söderman E, Frenckner B. Impact of radiologic imaging on the surgical decision-making process in suspected appendicitis in children. *Acad Radiol* 2004;11:971-979
10. Trout AT, Sanchez R, Ladino-Torres MF, Pai DR, Strouse PJ. A critical evaluation of US for the diagnosis of pediatric acute appendicitis in a real-life setting: how can we improve the diagnostic value of sonography? *Pediatr Radiol* 2012;42:813-823
11. Fallon SC, Orth RC, Guillerman RP, Munden MM, Zhang W, Elder SC, et al. Development and validation of an ultrasound scoring system for children with suspected acute appendicitis. *Pediatr Radiol* 2015;45:1945-1952
12. Trout AT, Sanchez R, Ladino-Torres MF. Reevaluating the sonographic criteria for acute appendicitis in children: a review of the literature and a retrospective analysis of 246 cases. *Acad Radiol* 2012;19:1382-1394
13. Jeffrey RB Jr, Laing FC, Townsend RR. Acute appendicitis: sonographic criteria based on 250 cases. *Radiology* 1988;167:327-329
14. Worrell JA, Drolshagen LF, Kelly TC, Hunton DW, Durmon GR, Fleischer AC. Graded compression ultrasound in the diagnosis of appendicitis. A comparison of diagnostic criteria. *J Ultrasound Med* 1990;9:145-150
15. Abu-Yousef MM, Bleicher JJ, Maher JW, Urdaneta LF, Franken EA Jr, Metcalf AM. High-resolution sonography of acute appendicitis. *AJR Am J Roentgenol* 1987;149:53-58
16. Lim HK, Lee WJ, Kim TH, Namgung S, Lee SJ, Lim JH. Appendicitis: usefulness of color Doppler US. *Radiology* 1996;201:221-225
17. Xu Y, Jeffrey RB, Shin LK, DiMaio MA, Olcott EW. Color Doppler imaging of the appendix: criteria to improve specificity for appendicitis in the borderline-size appendix. *J Ultrasound Med* 2016;35:2129-2138
18. Kwon LM, Lee K, Min SK, Ahn SM, Ha HI, Kim MJ. Ultrasound features of secondary appendicitis in pediatric patients. *Ultrasonography* 2018;37:233-243
19. Bhangu A, Søreide K, Di Saverio S, Assarsson JH, Drake FT. Acute appendicitis: modern understanding of pathogenesis, diagnosis, and management. *Lancet* 2015;386:1278-1287

20. Patriquin HB, Garcier JM, Lafortune M, Yazbeck S, Russo P, Jequier S, et al. Appendicitis in children and young adults: Doppler sonographic-pathologic correlation. *AJR Am J Roentgenol* 1996;166:629-633

## 애매한 초음파 결과를 보인 소아 환자에서 충수돌기염을 감별하는데 유용한 초음파 소견: 구조화 판독문에 기초한 분석

최지영 · 김혁중\* · 장석기 · 김현진 · 연재우

**목적** 애매한 초음파 결과를 보인 소아 환자들에서 충수돌기염을 감별하는 데 도움이 되는 초음파 소견들을 알아보고자 한다.

**대상과 방법** 2012년 11월부터 2017년 10월 사이에 충수돌기염이 의심되어 초음파를 시행한 소아 환자 중 애매한 결과를 보인 53명의 환자를 대상으로 하였다. 초음파 검사는 정해진 구조화 판독문을 사용했으며 충수돌기염의 가능성은 5가지로 분류되었다. 그중 3등급과 4등급을 애매한 결과로 간주하였다.

**결과** 53명의 환자 중 각각 25명(47.2%)과 28명(52.8%)이 3등급과 4등급으로 분류되었다. 각 초음파 소견 중 충수돌기 벽의 혈류 증가와 충수돌기 주변의 지방 침윤이 충수돌기염을 진단하는 데 다변량 로지스틱 회귀분석에서 의미 있는 소견이었고( $p = 0.005$ ,  $p = 0.045$ ), 진단적 정확도도 높았다(69.8%, 62.3%).

**결론** 충수돌기 벽의 혈류 증가와 충수돌기 주변의 지방 침윤은 애매한 초음파 결과를 보인 소아 환자들에서 의미 있는 충수돌기염의 예견 인자이다.

분당제생병원 영상의학과

**Appendix Table 1.** Structured Report for Appendicitis

	Option	
Visualization of appendix	Grade 0. Not identified Grade 1. Unsure or partially visualized Grade 2. Clearly and entirely visualized	
Appendix maximal diameter (mm)		
Appendiceal wall thickness (mm)		
Non-compressible appendix	<input type="checkbox"/> Absent	<input type="checkbox"/> Present
Appendiceal wall thickening	<input type="checkbox"/> Absent	<input type="checkbox"/> Present
US-guided tenderness	<input type="checkbox"/> Absent	<input type="checkbox"/> Present
Peri-appendiceal fat infiltration	<input type="checkbox"/> Absent	<input type="checkbox"/> Present
Increased vascularity of the appendiceal wall	<input type="checkbox"/> Absent	<input type="checkbox"/> Present
Alternative diagnosis		
Likelihood of appendicitis	Grade 1. Definitely absent. Clinical observation is recommended Grade 2. Probably absent. Clinical observation is recommended Grade 3. Indeterminate. Clinical observation or CT is recommended Grade 4. Probably present. Surgical exploration is recommended Grade 5. Definitely present. Surgical exploration is recommended	

US = ultrasound