













Cerebrovascular Reservoir and Arterial Transit Time Changes Assessed by Acetazolamide-Challenged Multi-Phase Arterial Spin Labeling Perfusion MRI in Chronic Cerebrovascular Steno-Occlusive Disease

만성 뇌혈관 협착폐색증에서 아세타졸아미드 부하 다상 동맥스핀표지 자기공명관류영상으로 평가한 뇌혈류 예비능과 동맥 통과 시간의 변화

Inpyeong Hwang, MD¹ , Chul-Ho Sohn, MD^{1*} , Keun-Hwa Jung, MD² ,
Eung Koo Yeon, MD¹ , Ji Ye Lee, MD¹ , Roh-Eul Yoo, MD¹ ,
Koung Mi Kang, MD¹ , Tae Jin Yun, MD¹ ,
Seung Hong Choi, MD¹ , Ji-hoon Kim, MD¹ 

Departments of ¹Radiology and ²Neurology, Seoul National University Hospital, Seoul, Korea

Purpose To explore cerebrovascular reservoir (CVR) and arterial transit time (ATT) changes using acetazolamide-challenged multi-phase arterial spin labeling (MP-ASL) perfusion-weighted MRI in chronic cerebrovascular steno-occlusive disease.

Materials and Methods This retrospective study enrolled patients with chronic steno-occlusion who underwent acetazolamide-challenged MP-ASL between June 2019 and October 2020. Cerebral blood flow, CVR, basal ATT, and ATT changes associated with severe stenosis, total occlusion, and chronic infarction lesions were compared.

Results There were 32 patients (5 with bilateral steno-occlusion) in our study sample. The CVR was significantly reduced during total occlusion compared with severe stenosis (26.2% ± 28.8% vs. 41.4% ± 34.1%, respectively, $p = 0.004$). The ATT changes were not significantly different ($p = 0.717$). The CVR was marginally lower in patients with chronic infarction (29.6% ± 39.1% vs. 38.9% ± 28.7%, respectively, $p = 0.076$). However, the ATT was less shortened in pa-

Received December 8, 2020
Revised December 23, 2020
Accepted December 31, 2020











***Corresponding author**

Chul-Ho Sohn, MD
Department of Radiology,
Seoul National University
Hospital, 101 Daehak-ro,
Jongno-gu, Seoul 03080, Korea.

Tel 82-2-2072-3617
Fax 82-2-747-7418
E-mail neurorad63@gmail.com

This is an Open Access article distributed under the terms of the Creative Commons Attribution Non-Commercial License (<https://creativecommons.org/licenses/by-nc/4.0>) which permits unrestricted non-commercial use, distribution, and reproduction in any medium, provided the original work is properly cited.

ORCID iDs

Inpyeong Hwang 
<https://orcid.org/0000-0002-1291-8973>
Chul-Ho Sohn 
<https://orcid.org/0000-0003-0039-5746>
Keun-Hwa Jung 
<https://orcid.org/0000-0003-1433-8005>
Eung Koo Yeon 
<https://orcid.org/0000-0001-7965-0118>
Ji Ye Lee 
<https://orcid.org/0000-0002-3929-6254>
Roh-Eul Yoo 
<https://orcid.org/0000-0002-5625-5921>
Koung Mi Kang 
<https://orcid.org/0000-0001-9643-2008>
Tae Jin Yun 
<https://orcid.org/0000-0001-8441-4574>
Seung Hong Choi 
<https://orcid.org/0000-0002-0412-2270>
Ji-hoon Kim 
<https://orcid.org/0000-0002-6349-6950>

tients with chronic infarction (-54 ± 135 vs. -117 ± 128 ms, respectively, $p = 0.013$).

Conclusion Acetazolamide-challenged MP-ASL provides an MRI-based CVR evaluation tool for chronic steno-occlusive disease.

Index terms Acetazolamide; Cerebrovascular Circulation; Cerebrovascular Disorders; Magnetic Resonance Angiography; Perfusion

INTRODUCTION

The treatment goal of cerebrovascular steno-occlusive disease is to prevent stroke. The current examination for stroke risk mostly depends on the degree of stenosis or poststenotic flow (1, 2). However, collateral flow assessment provides important hemodynamic information to select a treatment plan (3, 4). Cerebrovascular reservoir (or cerebrovascular reactivity; CVR) is defined as a flow response to a given vasoactive stressor (5), and it reflects the net effect of compensatory vasodilation and recruitment of collateral blood flow. It is believed to be a more desirable hemodynamic assessment for chronic steno-occlusive disease (6).

There are several methods to evaluate CVR using various imaging modalities and vasoactive stimuli (5). In particular, arterial spin labeling (ASL) perfusion-weighted MRI uses blood as an endogenous, diffusible tracer; therefore, it is a repeatable method without contrast media administration (7). Furthermore, ASL can provide absolute quantification of cerebral blood flow (CBF). There has been an attempt to use ASL in CVR evaluation with acetazolamide in moyamoya disease, demonstrating excellent diagnostic performance to detect impaired CVR (8). However, ASL has a particular limitation in the quantification of CBF when arterial transit time (ATT) is delayed in chronic steno-occlusive disease, causing underestimation of CBF and delayed ATT artifacts (9). Multiple post-labeling delay (PLD) acquisitions make it possible to improve the quantification of CBF by correction of the ATT. A Hadamard-encoded multi-phase ASL (MP-ASL) can provide transit-time-corrected CBF and ATT maps with reasonable time and signal-to-noise ratio (10). MP-ASL predicts the hypoperfusion area more accurately than standard ASL in moyamoya disease with ^{15}O -water PET as a reference standard (11). However, acetazolamide-challenged MP-ASL has not been rigorously investigated to evaluate CVR.

Therefore, the purpose of this study was to explore the cerebrovascular reservoir and ATT change by acetazolamide-challenged MP-ASL perfusion-weighted MRI in chronic cerebrovascular steno-occlusive disease.

MATERIALS AND METHODS

STUDY POPULATION

The Institutional Review Board approved this single-center, retrospective observational study, and informed consent was waived (IRB No. H-2012-121-1183). We searched a radiology database between June 2019 and October 2020 that included data for MP-ASL performed with acetazolamide challenge in our institution for chronic cerebrovascular steno-occlusive dis-

ease. The patients were referred from the Department of Neurology to evaluate newly diagnosed chronic cerebrovascular steno-occlusive disease. Our institution has performed acetazolamide-challenged ASL perfusion-weighted MRI for clinical purposes. The patients were diagnosed with severe stenosis or total occlusion of the internal carotid artery (ICA) or proximal middle cerebral arterial (MCA, M1, or proximal M2 segment) on digital subtracted angiography (DSA) or MR angiography (MRA). The stenosis degree was determined using the North American Symptomatic Carotid Endarterectomy Trial criteria for proximal ICA lesions and the Warfarin–Aspirin Symptomatic Intracranial Disease study criteria for intracranial lesions (1, 12).

MRI ACQUISITION

All patients underwent brain MRI using a 3.0-T MR scanner (Discovery MR 750w, GE Healthcare, Milwaukee, WI, USA) with a 32-channel phased-array head coil. Basal MP-ASL perfusion-weighted MRI was obtained using three-dimensional (3D) spiral fast spin-echo sequences with a Hadamard-encoded pseudo-continuous ASL. The imaging parameters were as follows: repetition time (TR), 7311 ms; echo time (TE), 11.0 ms; flip angle (FA), 111°; readout, 4 arms × 640 samples; field of view (FOV), 240 × 240 mm; section thickness, 6 mm; number of excitations (NEX), 1; reconstructed resolution, 1.88 × 1.88 mm²; and acquisition time, 4 min 33 s. We set Hadamard-encoded multiple PLDs using the following parameters: perfusion labeling time, 4 s; PLD, 1 s; number of delays, 7; and exponential delay spacing resulting in 7 PLDs of 1.00, 1.23, 1.50, 1.82, 2.21, 2.74, and 3.51 s with label durations of 0.23, 0.27, 0.32, 0.40, 0.52, 0.77, and 1.49 s, respectively. A proton density-weighted image with the same parameters was also obtained for CBF quantification.

Ten minutes after intravenous administration of acetazolamide (Zoladin injection, BC World Pharm, Seoul, Korea) at a dose of 14 mg/kg of body weight, acetazolamide challenge MP-ASL was obtained with the same acquisition parameters. T1-weighted 3D magnetization-prepared rapid acquisition gradient-echo sequences were obtained for structural imaging between the waiting times after intravenous administration of acetazolamide. The sequence parameters were as follows: TR = 7.5 ms; TE = 2.7 ms; FA = 12°; acquisition matrix = 256 × 256 × 256; FOV = 256 × 256 × 256 mm; reconstructed voxel size, 1 × 1 × 1 mm³; NEX, 1; and sagittal plane with multiplanar reconstruction.

The time-corrected CBF map was calculated by fitting the 7-delay ASL difference signals as a function of the PLD to the following equation:

$$\text{CBF (mL/100 g/min)} = 6000 \cdot \frac{e^{\delta/T_{1a}}}{2\epsilon T_{1a} [e^{-\max(\text{PLD}-\delta, 0)/T_{1t}} - e^{-\max(\text{PLD} + \text{LD} - \delta, 0)/T_{1t}}]} \cdot \lambda \cdot \frac{M}{M_0}$$

where M is the signal difference of ASL control and labeled images; M₀ is the signal of proton density-weighted images; T_{1a} and T_{1t} are the longitudinal relaxation times of blood and tissue, respectively (1.65 and 1.2 seconds, respectively); ε is the combined efficiency of the labeling sequence and background suppression (0.85 × 0.75), and λ is the tissue-to-blood partition coefficient of water (0.9). The ATT map (δ) was measured as described by Dai et al. (13).

IMAGE ANALYSIS

The basal/acetazolamide MP-ASL images were processed using the FMRIB Software Library (FSL version 6.0.1; <http://fsl.fmrib.ox.ac.uk/fsl>) by a single investigator (I.H., with 9 years of experience in neuroradiology). The skull-stripped T1-weighted images were generated using the BET tool (14) and used as a structural reference. The skull-removed proton-density weighted images for CBF quantification were coregistered to T1-weighted images by six degrees of freedom rigid transformation using the FLIRT tool (15). Then, the transformation matrix was applied to time-corrected CBF and ATT maps. The time-corrected CBF and ATT maps were smoothed with a Gaussian kernel with a standard deviation of 4 mm. All coregistration results were verified visually by the investigator.

Sixteen spherical volumes of interest (VOIs; 2 cm in diameter) were drawn into bilateral cerebral cortical areas regarding the anterior circulation territory in the Montreal Neurological Institute 152 standard space (MNI 152) (Fig. 1). The T1-weighted images were affinely transformed into MNI 152 space, and VOIs were reverse transformed to each patient's T1-weighted images. Systematic measurement of basal and acetazolamide time-corrected CBF and ATT was then performed. The CVR and ATT change (Δ ATT) were then calculated as follows:

$$\text{CVR} = (\text{CBF}_{\text{acetazolamide}} - \text{CBF}_{\text{basal}}) / \text{CBF}_{\text{basal}}$$

$$\Delta\text{ATT} = \text{ATT}_{\text{acetazolamide}} - \text{ATT}_{\text{basal}}$$

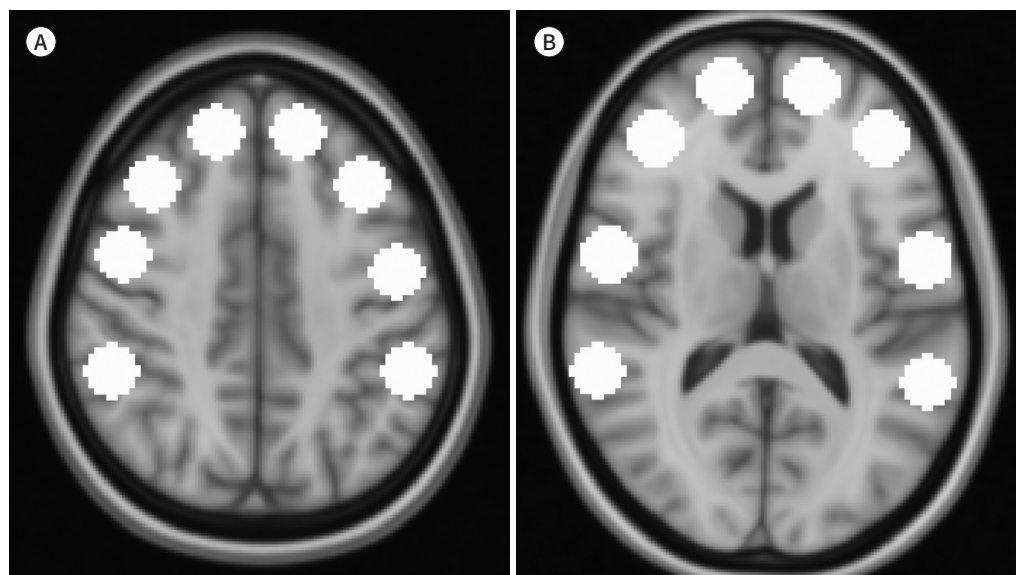
The measured basal CBF, acetazolamide CBF, CVR, basal ATT, and Δ ATT in each VOI from all patients were used for further statistical analysis.

STATISTICAL ANALYSIS

Descriptive statistics summarized demographic and clinical characteristics. For unilateral

Fig. 1. VOI templates for the Montreal Neurological Institute 152 standard space.

A, B. Sixteen VOIs are drawn around bilateral cerebral cortical areas within the anterior circulation territory. VOI = volume of interest



steno-occlusive disease, a pairwise comparison of perfusion metrics was performed between the steno-occlusion side and contralateral side by the signed-rank test for clustered data (16). Group comparison of perfusion metrics was then performed according to the degree of steno-occlusion (total occlusion vs. severe stenosis) on the steno-occlusion side. In bilateral cases, both hemispheres were regarded as a steno-occlusion side. Furthermore, we compared the perfusion metrics according to the presence of chronic territorial infarction or border-zone infarction lesions on T1-weighted images on the steno-occlusion side. The two-sample *t*-test for clustered data was performed with a subject as a cluster variable (17). Finally, correlation analysis between CVR and Δ ATT was performed using Pearson's correlation coefficient (*r*). All statistical analyses were performed using the open-source statistical language (R for Windows, version 3.6.3, R Foundation for Statistical Computing, Vienna, Austria). In all statistical tests, a *p* value of less than 0.05 was considered significant.

RESULTS

DEMOGRAPHIC AND CLINICAL CHARACTERISTICS

Finally, 32 patients were included in the study sample (25 male and 7 female). The mean and standard deviation of the age was 68.9 ± 10.6 years. Thirteen patients had right-sided stenosis, and 14 patients had left-sided stenosis. The stenosis sites and degree were as follows: proximal ICA severe stenosis ($n = 15$), proximal ICA occlusion ($n = 6$), proximal MCA severe stenosis ($n = 4$), and proximal MCA occlusion ($n = 7$). There were 5 patients with bilateral steno-occlusion as follows: 3 patients with proximal ICA occlusion and contralateral proximal ICA severe stenosis, one patient with bilateral proximal ICA severe stenosis, and one patient with bilateral proximal MCA occlusion. Twenty-one patients were diagnosed with DSA, and 11 patients were diagnosed with MRA. Fig. 2 illustrates a representative case.

All patients tolerated the acetazolamide-challenged MP-ASL studies well. There were no immediate adverse events or neurological deficits within the first day after acetazolamide challenge by medical record search.

PAIRWISE COMPARISON OF PERFUSION METRICS BETWEEN THE STENO-OCCLUSION SIDE AND CONTRALATERAL SIDE IN UNILATERAL STENO-OCCLUSIVE DISEASE

On the steno-occlusion side, the basal CBF and acetazolamide CBF were lower, and ATT was significantly prolonged (all $p < 0.001$) (Table 1). The CVR was significantly reduced on the steno-occlusion side ($38.5\% \pm 35.2\%$ vs. $50.7\% \pm 27.4\%$, respectively, $p = 0.016$). In addition, the ATT was significantly less shortened after acetazolamide challenge on the steno-occlusion side than on the contralateral side (-97 ± 140 ms vs. -169 ± 114 ms, respectively, $p < 0.001$).

COMPARISON OF PERFUSION METRICS ACCORDING TO THE DEGREE OF STENO-OCCLUSION

Interestingly, hemispheres with total occlusion showed significantly higher basal CBF than severe stenosis (56.4 ± 23.9 vs. 49.0 ± 17.0 mL/100 g/min, respectively, $p = 0.032$). The CVR was significantly reduced in total occlusion compared with severe stenosis ($26.2\% \pm 28.8\%$

vs. $41.4\% \pm 34.1\%$, respectively, $p = 0.004$). The basal ATT and Δ ATT were not significantly different in total occlusion and severe stenosis ($p = 0.989$ and $p = 0.717$, respectively, Table 2).

COMPARISON OF PERFUSION METRICS ACCORDING TO THE PRESENCE OF CHRONIC INFARCTION LESIONS

Six patients had chronic territorial infarction or borderzone infarction lesions on the steno-occlusion side. All patients with bilateral steno-occlusion had chronic infarction lesions on at least one side. In patients with chronic infarction, the basal CBF and acetazolamide CBF of the steno-occlusion side were significantly reduced, and the basal ATT was more delayed (all $p < 0.001$, Table 3). The CVR was lower in patients with chronic infarction but was marginally significant ($29.6 \pm 39.1\%$ vs. $38.9 \pm 28.7\%$, respectively, $p = 0.076$). Furthermore,

Fig. 2. Representative case.

A-G. A 74-year-old male was diagnosed with right proximal ICA occlusion (**A**) and left proximal ICA severe stenosis (**B**) based on digital subtraction angiography findings (lateral projection). The basal time-corrected CBF map (**C**) demonstrates decreased perfusion in the right ICA territory. The acetazolamide-challenged CBF map (**D**) reveals substantial augmentation of CBF in the left cerebral hemisphere and the right posterior circulation territory. In contrast, no substantial CBF augmentation is noted in the right ICA territory, suggesting an impaired cerebrovascular reservoir. The axial T1-weighted images (**E**) reveals chronic infarction in the right inferior frontal lobe and right basal ganglia (repetition time, 7.5 ms; echo time, 2.7 ms). The basal ATT map (**F**) shows delayed ATT in the right ICA territory. On the acetazolamide-challenged ATT map (**G**), the ATT is reduced in the left cerebral hemispheres (please note the color change), but the ATT change in the right ICA territory is minimal.

ATT = arterial transit time, CBF = cerebral blood flow, ICA = internal carotid arterial

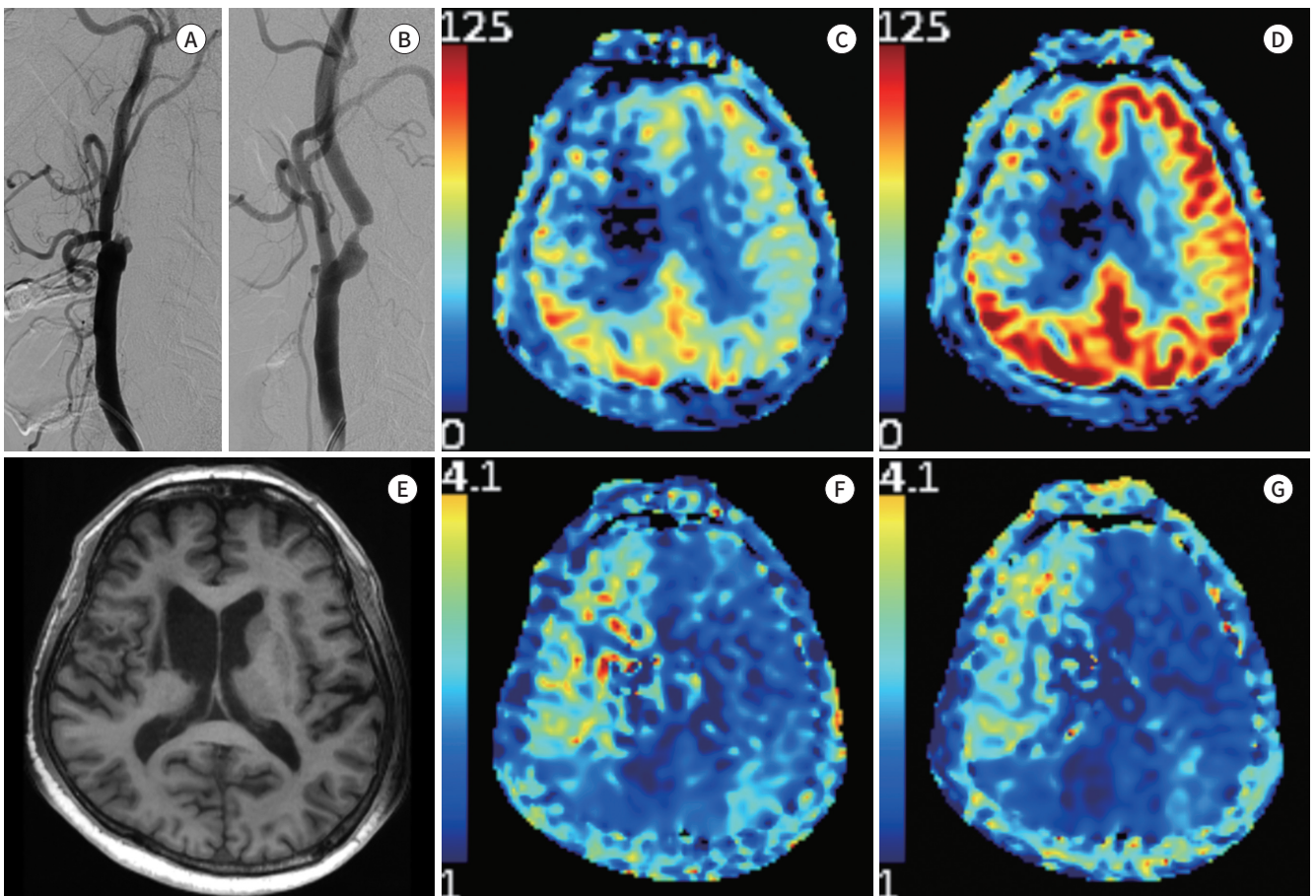


Table 1. Comparison of Ipsilateral and Contralateral Perfusion Metrics in Unilateral Steno-Occlusive Disease ($n = 27$)

	Steno-Occlusion Side	Contralateral Side	<i>p</i> -Value*
Basal CBF (mL/100 g/min)	53.1 ± 21.5	56.8 ± 18.9	< 0.001
Acetazolamide CBF (mL/100 g/min)	70.3 ± 24.7	82.9 ± 22.7	< 0.001
CVR (%)	38.5 ± 35.2	50.7 ± 27.4	0.016
Basal ATT (ms)	1624 ± 335	1435 ± 192	< 0.001
ΔATT (ms)	-97 ± 140	-169 ± 114	< 0.001

Data are presented as mean ± standard deviation.

*Pairwise comparison between the steno-occlusion side and the contralateral side.

ATT = arterial transit time, ΔATT = ATT change, CBF = cerebral blood flow, CVR = cerebrovascular reservoir

Table 2. Comparison of Perfusion Metrics in Severe Stenosis and Total Occlusion

	Severe Stenosis ($n = 23$)*	Total Occlusion ($n = 14$)*	<i>p</i> -Value
Basal CBF (mL/100 g/min)	49.0 ± 17.0	56.4 ± 23.9	0.032
Acetazolamide CBF (mL/100 g/min)	66.7 ± 21.5	69.7 ± 27.4	0.481
CVR (%)	41.4 ± 34.1	26.2 ± 28.8	0.004
Basal ATT (ms)	1762 ± 273	1761 ± 344	0.989
ΔATT (ms)	-98 ± 144	-89 ± 115	0.717

Data are presented as mean ± standard deviation.

*Number of steno-occlusion sides (including 5 bilateral steno-occlusions).

ATT = arterial transit time, ΔATT = ATT change, CBF = cerebral blood flow, CVR = cerebrovascular reservoir

Table 3. Comparison of Perfusion Metrics Associated with Chronic Infarction Lesions

	With Chronic Infarction ($n = 13$)*	Without Chronic Infarction ($n = 24$)*	<i>p</i> -Value
Basal CBF (mL/100 g/min)	41.3 ± 16.6	57.5 ± 19.7	< 0.001
Acetazolamide CBF (mL/100 g/min)	51.2 ± 20.3	76.8 ± 20.6	< 0.001
CVR (%)	29.6 ± 39.1	38.9 ± 28.7	0.076
Basal ATT (ms)	1933 ± 280	1668 ± 270	< 0.001
ΔATT (ms)	-54 ± 135	-117 ± 128	0.013

Data are presented as mean ± standard deviation.

*Number of steno-occlusion sides (including 5 bilateral steno-occlusions).

ATT = arterial transit time, ΔATT = ATT change, CBF = cerebral blood flow, CVR = cerebrovascular reservoir

the ATT was less shortened in patients with chronic infarction (-54 ± 135 vs. -117 ± 128 ms, respectively, $p = 0.013$).

CORRELATION OF CVR AND ATT CHANGE BY ACETAZOLAMIDE CHALLENGE

There was a negative linear correlation between CVR and ΔATT ($r = -0.250$, $p < 0.001$) in all VOIs pooled together. Scatterplots are presented in Fig. 3. However, ΔATT was less correlated with CVR on the steno-occlusive side ($r = -0.130$, $p = 0.025$). In the contralateral hemispheres, ΔATT was negatively correlated with CVR ($r = -0.327$, $p < 0.001$).

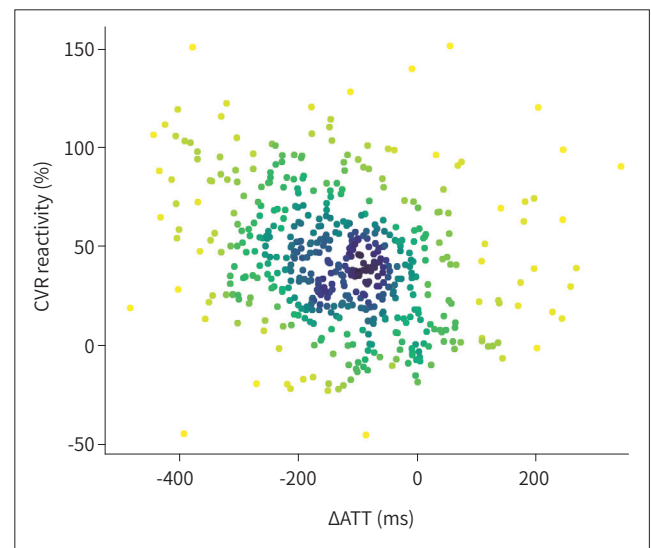


Fig. 3. A scatterplot of CVR and Δ ATT. Δ ATT is negatively correlated with the CVR.

Δ ATT = arterial transit time change, CVR = cerebrovascular reservoir

DISCUSSION

Our study demonstrated MP-ASL-based acetazolamide-induced perfusion changes in chronic steno-occlusive disease. In unilateral steno-occlusion cases, the steno-occlusion side showed a significantly reduced CVR (38.5% vs. 50.7% $p = 0.016$) and less shortening of ATT after acetazolamide challenge (-97 ms vs. -169 ms, $p < 0.001$). The CVR was significantly reduced in the total occlusion group compared with the severe stenosis group (26.2% vs. 41.4%, $p = 0.004$). The CVR was lower in the hemispheres with chronic infarction, but was not significant (29.6% vs. 38.9%, $p = 0.076$). However, the magnitude of Δ ATT was smaller in hemispheres with chronic infarction (-54 ms vs. -117 ms, $p = 0.013$).

In a previous study, the CVR was evaluated by acetazolamide-challenged MP-ASL in moyamoya disease (18), showing that the CVR gradually decreases with the stenosis degree. In this previous study, however, severe stenosis and occlusion were considered as a single category. Our study demonstrated that there was a certain difference in CVR between patients with severe stenosis and total occlusion in patients with carotid or intracranial steno-occlusion. Interestingly, the basal CBF was higher in the total occlusion group than in the severe stenosis group. A previous study also found a paradoxical increase in basal CBF by increasing stenosis severity. This may be partially explained by the fact that labeled protons in more severe stenosis spend more time in the arterial blood, where T1 relaxation time is longer than in brain tissue, and gives greater ASL perfusion signal after ATT correction (18).

There are several pieces of evidence that impaired CVR is associated with stroke in high-grade carotid stenosis or intracranial stenosis (6, 19). Furthermore, it is believed that preserved CVR may indicate a lower risk of stroke regardless of the degree of carotid artery stenosis (20). Basal CBF was significantly decreased in hemispheres with chronic infarction, which might be due to the reduced oxygen demand of infarcted tissue and might not necessarily indicate a higher risk of further stroke. Although our study did not evaluate new acute stroke, patients with chronic infarction showed marginally lower CVRs ($p = 0.076$).

The ATT can be obtained only by MP-ASL. It was negatively correlated with CVR; hence, it

has been proposed as a surrogate marker of CVR impairment without acetazolamide challenge (18, 21). However, little is known about the ATT changes caused by acetazolamide challenge. Previous CT and MR perfusion studies have reported a reduction in the mean transit time (MTT) after acetazolamide challenge (22, 23). Although ATT is known to be correlated with MTT (24), the ATT is the traveling time of labeled blood between the labeling plane and the imaging plane, while MTT is the average transit time of blood through a given brain region (25). In our study, ATT changes were significantly blunted in hemispheres with chronic infarction and negatively correlated with the CVR. The novel role of ATT changes in the assessment of CVR and stroke risk may be investigated in future research. Meanwhile, there was a concern in using ASL for acetazolamide challenge because it changes the ATT, which may affect absolute CBF quantification. However, MP-ASL can provide time-corrected CBF regardless of the ATT change. A recent study has shown that ATT and time-corrected CBF by MP-ASL are longitudinally stable, supporting their use in a vasoactive challenge study (26).

Although there is no standardization of published studies that have evaluated CVR, acetazolamide-challenged brain perfusion single-photon emission computed tomography (SPECT) is one of the most readily available nuclear medicine imaging techniques that provide cross-sectional images (27, 28). However, SPECT has disadvantages of radiation exposure and limited absolute quantification (29). In contrast, MP-ASL can provide absolute CBF measures without radiation exposure. Particularly, absolute CVR might be useful for identifying CVR impairment in significant bilateral steno-occlusive disease. Meanwhile, there are no widely accepted criteria for impaired CVR. The proposed criteria used to define an abnormal response to acetazolamide include less than a 10% increase in the absolute CBF or less than an absolute increase of 10 mL/100 g/min (28). A prior study demonstrated that acetazolamide-challenged standard ASL shows a 30–45% increase in CBF in healthy subjects (30). In our study, the mean CVR on the contralateral side was 50.7%, which was higher than that of the prior healthy subject study. It is possible that transit time correction may affect absolute CVR. Therefore, a comparative study with reference standards, such as SPECT or PET, is warranted to assess the diagnostic performance of acetazolamide-challenged MP-ASL and to obtain robust criteria for impaired CVR.

The present study had several limitations. First, the retrospective study design had a potential selection bias. Second, we did not consider the difference between proximal carotid stenosis and MCA stenosis. The anterior cerebral arterial territory may not be affected in cases of MCA stenosis. Finally, we used relatively small spherical VOIs in the anterior circulation territory for simplicity, which was motivated by the Alberta stroke program early CT score (9, 31). However, the VOI size was relatively small and not all-inclusive for the affected hemispheres. An exhaustive VOI template should be used for exact and extensive measurements.

In conclusion, the CVR evaluated with acetazolamide-challenged MP-ASL showed a significant difference according to the degree of steno-occlusion. Furthermore, acetazolamide-challenged MP-ASL could evaluate the ATT change that was significantly different according to the presence of chronic infarction, suggesting clinical relevance. Acetazolamide-challenged MP-ASL may provide an MRI-based CVR evaluation tool for chronic steno-occlusive disease.

Author Contributions

Conceptualization, H.I., S.C., J.K.; data curation, all authors; formal analysis, H.I.; funding acquisition, S.C.; investigation, H.I., S.C., Y.E.K., L.J.Y.; methodology, H.I.; project administration, H.I., S.C.; resources, S.C., Y.R., K.K.M., Y.T.J., C.S.H., K.J.; software, H.I.; supervision, S.C., J.K.; validation, Y.E.K., L.J.Y., Y.R., K.K.M., Y.T.J., C.S.H., K.J.; visualization, H.I., S.C.; writing—original draft, H.I., S.C.; and writing—review & editing, all authors.

Conflicts of Interest

The authors have no potential conflicts of interest to disclose.

Funding

None

Acknowledgments

This research was supported by the Bio & Medical Technology Development Program of the National Research Foundation (NRF) funded by the Korean government (MSIT) (No. 2018M3C7A1056884 and 2018M3C7A1056888).

REFERENCES

1. North American Symptomatic Carotid Endarterectomy Trial Collaborators, Barnett HJM, Taylor DW, Haynes RB, Sackett DL, Peerless SJ, et al. Beneficial effect of carotid endarterectomy in symptomatic patients with high-grade carotid stenosis. *N Engl J Med* 1991;325:445-453
2. Brott TG, Hobson RW 2nd, Howard G, Roubin GS, Clark WM, Brooks W, et al. Stenting versus endarterectomy for treatment of carotid-artery stenosis. *N Engl J Med* 2010;363:11-23
3. Derdeyn CP. Hemodynamics and oxygen extraction in chronic large artery steno-occlusive disease: clinical applications for predicting stroke risk. *J Cereb Blood Flow Metab* 2018;38:1584-1597
4. Bang OY, Goyal M, Liebeskind DS. Collateral circulation in ischemic stroke: assessment tools and therapeutic strategies. *Stroke* 2015;46:3302-3309
5. Fisher JA, Venkatraghavan L, Mikulis DJ. Magnetic resonance imaging-based cerebrovascular reactivity and hemodynamic reserve. *Stroke* 2018;49:2011-2018
6. Reinhard M, Schwarzer G, Briel M, Altamura C, Palazzo P, King A, et al. Cerebrovascular reactivity predicts stroke in high-grade carotid artery disease. *Neurology* 2014;83:1424-1431
7. Haller S, Zaharchuk G, Thomas DL, Lovblad KO, Barkhof F, Golay X. Arterial spin labeling perfusion of the brain: emerging clinical applications. *Radiology* 2016;281:337-356
8. Yun TJ, Paeng JC, Sohn CH, Kim JE, Kang HS, Yoon BW, et al. Monitoring cerebrovascular reactivity through the use of arterial spin labeling in patients with Moyamoya disease. *Radiology* 2016;278:205-213
9. Zaharchuk G, Do HM, Marks MP, Rosenberg J, Moseley ME, Steinberg GK. Arterial spin-labeling MRI can identify the presence and intensity of collateral perfusion in patients with moyamoya disease. *Stroke* 2011;42:2485-2491
10. Dai W, Shankaranarayanan A, Alsop DC. Volumetric measurement of perfusion and arterial transit delay using hadamard encoded continuous arterial spin labeling. *Magn Reson Med* 2013;69:1014-1022
11. Fan AP, Khalighi MM, Guo J, Ishii Y, Rosenberg J, Wardak M, et al. Identifying hypoperfusion in moyamoya disease with arterial spin labeling and an [¹⁵O]-water positron emission tomography/magnetic resonance imaging normative database. *Stroke* 2019;50:373-380
12. Samuels OB, Joseph GJ, Lynn MJ, Smith HA, Chimowitz MI. A standardized method for measuring intracranial arterial stenosis. *AJNR Am J Neuroradiol* 2000;21:643-646
13. Dai W, Robson PM, Shankaranarayanan A, Alsop DC. Reduced resolution transit delay prescan for quantitative continuous arterial spin labeling perfusion imaging. *Magn Reson Med* 2012;67:1252-1265
14. Smith SM. Fast robust automated brain extraction. *Hum Brain Mapp* 2002;17:143-155
15. Greve DN, Fischl B. Accurate and robust brain image alignment using boundary-based registration. *Neuroimage* 2009;48:63-72
16. Datta S, Satten GA. A signed-rank test for clustered data. *Biometrics* 2008;64:501-507

17. Donner A, Klar N. Statistical considerations in the design and analysis of community intervention trials. *J Clin Epidemiol* 1996;49:435-439
18. Federau C, Christensen S, Zun Z, Park SW, Ni W, Moseley M, et al. Cerebral blood flow, transit time, and apparent diffusion coefficient in moyamoya disease before and after acetazolamide. *Neuroradiology* 2017; 59:5-12
19. Gupta A, Chazen JL, Hartman M, Delgado D, Anumula N, Shao H, et al. Cerebrovascular reserve and stroke risk in patients with carotid stenosis or occlusion: a systematic review and meta-analysis. *Stroke* 2012; 43:2884-2891
20. Vernieri F, Pasqualetti P, Matteis M, Passarelli F, Troisi E, Rossini PM, et al. Effect of collateral blood flow and cerebral vasomotor reactivity on the outcome of carotid artery occlusion. *Stroke* 2001;32:1552-1558
21. Choi HJ, Sohn CH, You SH, Yoo RE, Kang KM, Yun TJ, et al. Can arterial spin-labeling with multiple postlabeling delays predict cerebrovascular reserve? *AJNR Am J Neuroradiol* 2018;39:84-90
22. Chen A, Shyr MH, Chen TY, Lai HY, Lin CC, Yen PS. Dynamic CT perfusion imaging with acetazolamide challenge for evaluation of patients with unilateral cerebrovascular steno-occlusive disease. *AJNR Am J Neuroradiol* 2006;27:1876-1881
23. Ma J, Mehrkens JH, Holtmannspoetter M, Linke R, Schmid-Elsaesser R, Steiger HJ, et al. Perfusion MRI before and after acetazolamide administration for assessment of cerebrovascular reserve capacity in patients with symptomatic internal carotid artery (ICA) occlusion: comparison with 99mTc-ECD SPECT. *Neuroradiology* 2007;49:317-326
24. Wang R, Yu S, Alger JR, Zuo Z, Chen J, Wang R, et al. Multi-delay arterial spin labeling perfusion MRI in moyamoya disease--comparison with CT perfusion imaging. *Eur Radiol* 2014;24:1135-1144
25. Konstas AA, Goldmakher GV, Lee TY, Lev MH. Theoretic basis and technical implementations of CT perfusion in acute ischemic stroke, part 1: theoretic basis. *AJNR Am J Neuroradiol* 2009;30:662-668
26. Cohen AD, Agarwal M, Jagra AS, Nencka AS, Meier TB, Lebel RM, et al. Longitudinal reproducibility of MR perfusion using 3D pseudocontinuous arterial spin labeling with Hadamard-encoded multiple postlabeling delays. *J Magn Reson Imaging* 2020;51:1846-1853
27. Burt RW, Witt RM, Cikrit DF, Reddy RV. Carotid artery disease: evaluation with acetazolamide-enhanced Tc-99m HMPAO SPECT. *Radiology* 1992;182:461-466
28. Vagal AS, Leach JL, Fernandez-Ulloa M, Zuccarello M. The acetazolamide challenge: techniques and applications in the evaluation of chronic cerebral ischemia. *AJNR Am J Neuroradiol* 2009;30:876-884
29. Kapucu OL, Nobili F, Varrone A, Booi J, Vander Borgh T, Nägren K, et al. EANM procedure guideline for brain perfusion SPECT using 99mTc-labelled radiopharmaceuticals, version 2. *Eur J Nucl Med Mol Imaging* 2009;36:2093-2102
30. Inoue Y, Tanaka Y, Hata H, Hara T. Arterial spin-labeling evaluation of cerebrovascular reactivity to acetazolamide in healthy subjects. *AJNR Am J Neuroradiol* 2014;35:1111-1116
31. Barber PA, Demchuk AM, Zhang J, Buchan AM. Validity and reliability of a quantitative computed tomography score in predicting outcome of hyperacute stroke before thrombolytic therapy. ASPECTS Study Group. Alberta Stroke Programme Early CT Score. *Lancet* 2000;355:1670-1674

만성 뇌혈관 협착폐색증에서 아세타졸아미드 부하 다상 동맥스핀표지 자기공명관류영상으로 평가한 뇌혈류 예비능과 동맥 통과 시간의 변화

황인평¹ · 손철호^{1*} · 정근화² · 연응구¹ · 이지예¹ · 유노을¹ · 강경미¹ · 윤태진¹ · 최승홍¹ · 김지훈¹

목적 만성 뇌동맥 협착-폐색증에서 아세타졸아미드 부하 다상 동맥 스핀 표지(multi-phase arterial spin labeling; 이하 MP-ASL) 자기공명관류영상을 이용하여 뇌혈류 예비능(cerebrovascular reservoir; 이하 CVR)과 동맥 통과 시간(arterial transit time; 이하 ATT)의 변화를 탐색하였다.

대상과 방법 2019년 6월부터 2020년 10월까지 새롭게 만성 협착-폐색증으로 진단되어 아세타졸아미드 부하 MP-ASL을 시행한 환자를 후향적으로 모집하였다. 부하 전후의 뇌혈류(cerebral blood flow), CVR, 부하전 ATT 및 부하 전후의 ATT 변화량을 중증 협착과 완전 폐색간, 만성 뇌경색 병변의 유무에 따라 비교하였다.

결과 5명의 양측성 협착-폐색을 포함하여 총 32명의 환자가 본 연구에 포함되었다. CVR은 완전 폐색에서 중증 협착보다 유의하게 낮았다($26.2\% \pm 28.8\%$ vs. $41.4\% \pm 34.1\%$, $p = 0.004$). ATT의 변화는 두 군간 유의한 차이는 없었다($p = 0.717$). 만성 뇌경색 병변의 유무에 따른 CVR의 통계적 차이는 미미하였다($29.6\% \pm 39.1\%$ vs. $38.9\% \pm 28.7\%$, $p = 0.076$). 하지만, 만성 뇌경색 병변이 있는 환자에서 ATT의 단축 정도는 유의하게 작았다(-54 ± 135 vs. -117 ± 128 ms, $p = 0.013$).

결론 만성 협착-폐색증에서 아세타졸아미드 부하 MP-ASL 검사는 MRI 기반의 CVR 평가 도구로 사용될 수 있다.

서울대학교병원 ¹영상의학과, ²신경과