

Meatal stenosis after surgical correction of short frenulum: Is the “pull-and-burn” method the way to go?

Kostis I. Gyftopoulos

Department of Anatomy, University of Patras Medical School and Olympion Hospital, Patras, Greece

Abstract

Background and Objectives: The surgical correction of a short frenulum includes several procedures that vary in complexity of the technique and the use of stitches, lasers, or skin grafts. However, little is known about the effect of these procedures on meatal stenosis. A possible association of frenular artery trauma during circumcision and subsequent meatal stenosis has raised concerns regarding the importance of frenulum preservation. We hereby report our experience over 15 years of applying the “pull-and-burn” method for short frenulum correction.

Patients and Methods: A total of 236 patients underwent the “pull-and-burn” procedure for short frenulum under local anesthesia on an outpatient basis between November 2002 and November 2017. The method is suture free and involves tearing the frenulum superficially and vertically by the aid of a low-power, high-frequency hyfrecator, avoiding the underlying frenular vessels. Patients were advised for a regular follow-up visit at 2–3 months postoperatively and were reviewed for symptoms and signs suggestive of meatal stenosis.

Results: Follow-up files were available for 228 patients (96.6%). No symptoms suggestive of meatal stenosis (dysuria and stream pattern abnormalities) were reported by any patient. Examination of the urethral meatus revealed normal appearance, with no signs of edema or scarring in all the 228 patients.

Conclusions: The “pull-and-burn” method is a simple and safe procedure for the correction of short frenulum that respects anatomically the delicate vasculature of the frenular area, resulting in the preservation of the integrity of the urethral meatus.

Keywords: Anatomy, frenuloplasty, frenulum, stenosis, urethra meatus

Address for correspondence: Prof. Kostis I. Gyftopoulos, Department of Anatomy, University of Patras Medical School and Olympion Hospital, Patras, Greece.

E-mail: kogyftop@yahoo.gr

Received: 20.02.2018, Accepted: 20.06.2018

INTRODUCTION

The penile frenulum is a mucosal fold attached between the ventral aspect of the foreskin and the glans penis, acting as a natural retractor of the foreskin over the glans.^[1] The short frenulum (or frenulum breve) is a common condition in urology practice that may cause dyspareunia,

premature ejaculation, or even predispose to traumatic rupture.^[2-4] Surgical procedures for the correction of a short frenulum vary from simple dissection and ligation to more sophisticated procedures including frenuloplasties and frenular grafting.^[2-7] However, concerns have been raised regarding the association of frenular artery trauma

This is an open access journal, and articles are distributed under the terms of the Creative Commons Attribution-NonCommercial-ShareAlike 4.0 License, which allows others to remix, tweak, and build upon the work non-commercially, as long as appropriate credit is given and the new creations are licensed under the identical terms.

For reprints contact: reprints@medknow.com

How to cite this article: Gyftopoulos KI. Meatal stenosis after surgical correction of short frenulum: Is the “pull-and-burn” method the way to go? *Urol Ann* 2018;10:354-7.

Access this article online	
Quick Response Code:	Website: www.urologyannals.com
	DOI: 10.4103/UA.UA_25_18

and subsequent meatal stenosis. Data from circumcision procedures have underlined the possibility of meatal stenosis due to frenular artery damage and, recently, circumcision techniques that spare the frenular vessels have been proposed.^[8,9] However, the effect of different types of surgical correction of the short frenulum on meatal stenosis remains unclear. In 2009, we described a suture-free “pull-and-burn” method for short frenulum correction that spares the frenular vessels.^[2] In the present study, we evaluated the 15 years’ experience with this method focusing on meatal stenosis.

PATIENTS AND METHODS

Between November 2002 and November 2017, a total of 236 patients underwent the “pull-and-burn” procedure for short frenulum in an outpatient basis. The indication was dyspareunia due to the short frenulum. Patients with lichen planus (balanitis xerotica obliterans) lesions were not offered this procedure. The files of these patients were reviewed in regard to symptoms and signs of meatal stenosis. The follow-up visit after the procedure was regularly planned at 2–3 months. The patients were interviewed about symptoms suggesting meatal stenosis (dysuria and stream pattern abnormalities), and the urethral meatus was inspected for signs of inflammation and stenotic appearance. The present study was conducted according to the principles of the Declaration of Helsinki and the Institutional Review Board approval was obtained. Informed consent was obtained, and specific consent for photograph publication was acquired from patients that agreed in being photographed for illustrative purposes.

The “pull-and-burn” method has been described in detail.^[2,3] All procedures were performed under local anesthesia by applying Eutectic mixture of local anesthetics (2.5% lidocaine and 2.5% prilocaine, Greece, Astra Zeneca, Inc.) on the ventral surface of the glans penis for 15–20 min. By bending the penis upward, the point of maximum tethering of the frenulum was incised using the scalpel of a Birtcher Hyfrecator Plus™, a high-frequency device used for monoterminial fulguration at low-power settings (7–10 W). Gentle but firm traction was then applied causing the initial cut to extend vertically along the midline. Further cuts were made as needed until complete resolution of the frenular tissue was obtained [Figure 1a-c]. Care was taken to retain the tear superficial at the mucosa level and not to sever the frenular artery (or arteries) that could often be seen lying at the frenular bed [Figure 2]. After completion of the procedure, a small quantity of povidone-iodine was applied, and the patients were advised

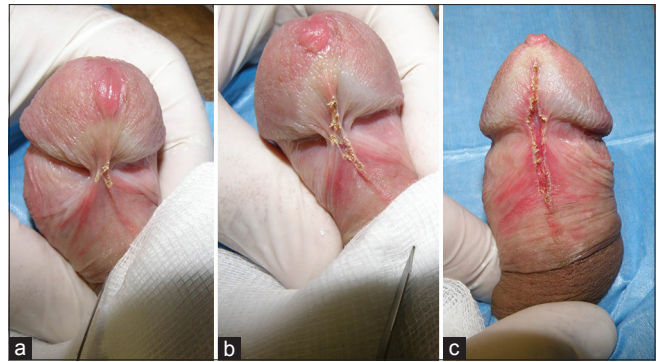


Figure 1: Initial incision of the frenulum (a) is followed by gentle but firm traction to extend the initial cut vertically (b). Further small cuts with the hyfrecator scalpel result in complete resolution of the tethering frenulum with practically no bleeding, leaving the frenular vessels intact (c)

to commence daily personal hygiene and retain sexual abstinence until complete healing was present.

RESULTS

Of the 236 patients that underwent the procedure, nine patients did not attend the follow-up visit after 2–3 months. One of these patients returned after 3 years for an unrelated reason. Thus, data were available for a total of 228 cases (96.6%). The median age of patients was 21.4 years (range: 17–36 years). Forty-three cases (19%) reported a history of previous frenular trauma during intercourse and scar tissue (usually minimal) was present at the time of surgery. The procedure was suture free in all but three cases (1.3%) where resection of a thick frenulum resulted in a rather wide gap; in these cases, one or two fine absorbable sutures (5-0 polyglycolic acid, Safil Quick™, B. Braun Melsungen AG) were used to approximate the mucosal edges to facilitate faster healing.

No symptoms related to meatal stenosis were reported by any patient during follow-up. Moreover, the meatus appearance was normal, with no signs of inflammation or scarring at follow-up visit for all the 228 patients. No difference was noted in patients with a history of prior frenular trauma.

DISCUSSION

Concerns about meatal stenosis after circumcision and frenular excision have been raised for both pediatric and adult patients. The incidence of meatal stenosis in circumcised boys varies from 7.29% to 15%–20% in neonates.^[10,11] Importantly, the latter group presented a 40% decrease in meatal caliber although they remained asymptomatic.^[11] The rationale behind these concerns implicates damage to the frenular vessels and especially the frenular artery as a possible causal factor for subsequent

meatal stenosis. According to this mechanism, ischemia to the meatal mucosa may lead to meatal stenosis, particularly at the ventral part of the meatus, as it is universally observed in postcircumcision cases.^[8]

The exact anatomy of the vasculature of the frenular and meatal area remains elusive. Typically, the skin and prepuce are supplied by dorsolateral and ventrolateral axial penile branches of the external pudendal arteries. Just behind the glans, perforating branches that arise from these axial arteries are brought through Buck's fascia to anastomose with the terminal branches of the dorsal arteries (branches of the internal pudendal arteries) before they end in the glans.^[12] The blood supply to the frenulum area however is complex. According to Hinman, arterial supply typically arises from the dorsal artery of the penis. Circumflex branches of the dorsal artery (from internal pudendal artery) curve around each side of the distal penile shaft to enter the glans and the frenulum from the ventral surface.^[13] Similarly, branches of the dorsal arteries called "terminal branches" are anastomosed with urethral branches of the penile arteries (from internal pudendal artery) in the corpus spongiosum, thus supplying the urethra and also giving perforating branches to the skin, i.e., the distal prepuce.^[12,14] When bleeding occurs, it is coming from the coronal end of the cut artery.^[15] It is unclear whether the frenular artery is single; in our experience, paired arteries were often evident, lying in the frenular bed [Figure 2]. As far as venous drainage is concerned, McGrath has proposed the term "frenular veins" to describe two paired venules that run in the frenular delta area, close to the midline along the frenulum before disappearing into its depths.^[16] He proposed that these veins are always present in intact (noncircumcised) males and actually drain the glans area supplied by the frenular artery, i.e., the ventral

area with the urethral cleft and meatus. The anatomical observations in our series concur with the remarks of McGrath; interestingly, these frenular veins were unharmed by the "pull-and-burn" procedure and could be seen intact in follow-up visits [Figure 3].

It appears that the frenular arteries and veins may be involved in supplying and draining, respectively, both the external urethral meatus and the frenulum area, justifying the incidence of meatal stenosis after nonfrenulum-sparing circumcision. The dual mechanism may involve both ischemia due to arterial severing and edema due to venous occlusion. The main advantage of the "pull-and-burn" method is that no extensive fulguration is necessary as the applied traction is gradually expanding the initial mucosal tear without disrupting the underlying vessels. In a sense, our technique is most closely related to the laser-CO₂ frenuloplasty proposed by Duarte *et al.*^[17] In our series, no symptoms or signs of meatal stenosis were present in any patient. Unfortunately, it is difficult to compare our results with other techniques due to lack of available data. All published series available do not specifically evaluate meatal stenosis or simply this is not commented upon.^[4-8,17] In fact, Gallo *et al.* clearly describe the use of a thick (2/0) suture to include the frenular artery and nerve to prevent bleeding! However, in their report, they only focus on the main outcomes, i.e., improvement in premature ejaculation.^[7]

A possible limitation of our study is that no proper calibration of the meatus using a sound or catheter was used to compare pre- and post-operation caliber of the urethral meatus. However, this was deemed unnecessary as voiding symptoms are usually sufficient in unveiling an underlying pathology.^[8] Moreover, thorough inspection of the meatus during the follow-up visit did not reveal the

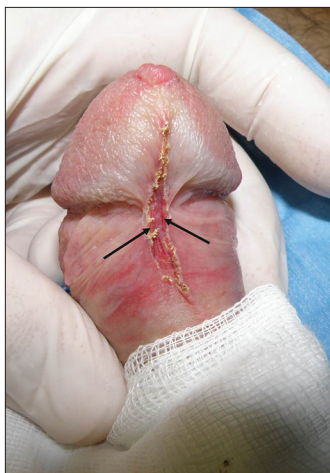

Figure 2: Paired frenular arteries (the left and right branches) are easily seen lying undamaged at the frenular bed (arrows)

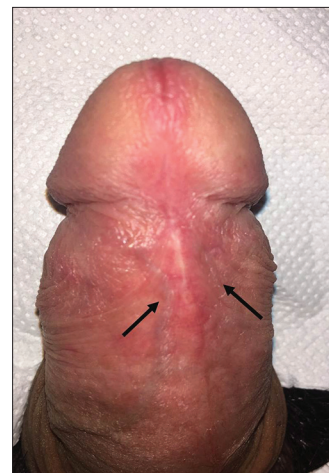

Figure 3: The named *frenular veins* are seen intact flanking each side of the midline (arrows) in a case at 2-month follow-up

signs of inflammation, edema, or scar tissue at the ventral aspect of the meatus as described in postcircumcision meatal stenosis. Another issue may lie in the fact that no comparison arm by another frenuloplasty method was used. However, since the functional and esthetic results of the “pull-and-burn” method have been excellent, we considered it unethical to use a different surgical approach on patients purely for control purposes.

CONCLUSIONS

The results of our series reveal that the “pull-and-burn” method is a simple and safe procedure for the correction of short frenulum that respects anatomically the delicate vasculature of the frenular area, resulting in the preservation of the integrity of the urethral meatus. Better understanding of the complex vasculature of the frenular delta may assist in preventing damage to these deeper structures that supply the meatus. It would be interesting for future studies utilizing other alternatives of frenuloplasty to focus and report on the potential hazard of (unnecessary) iatrogenic meatal stenosis.

Financial support and sponsorship

Nil.

Conflicts of interest

There are no conflicts of interest.

REFERENCES

- Rosenblatt A, de Campos Guidi HG, Belda W Jr. Embryology and functional anatomy of the male external genitalia. In: *Male Genital Lesions: The Urological Perspective*. Springer-Verlag Berlin Heidelberg; 2013. p. 3-22.
- Gyftopoulos K. Male dyspareunia due to short frenulum: The suture-free, “pull and burn” method. *J Sex Med* 2009;6:2611-4.
- Gyftopoulos KI. The efficacy and safety of topical EMLA cream application for minor surgery of the adult penis. *Urol Ann* 2012;4:145-9.
- Rajan P, McNeill SA, Turner KJ. Is frenuloplasty worthwhile? A 12-year experience. *Ann R Coll Surg Engl* 2006;88:583-4.
- Dockray J, Finlayson A, Muir GH. Penile frenuloplasty: A simple and effective treatment for frenular pain or scarring. *BJU Int* 2012;109:1546-50.
- Kayes O, Li CY, Spillings A, Ralph D. Frenular grafting: An alternative to circumcision in men with a combination of tight frenulum and phimosis. *J Sex Med* 2007;4:1070-3.
- Gallo L, Perdonà S, Gallo A. The role of short frenulum and the effects of frenulectomy on premature ejaculation. *J Sex Med* 2010;7:1269-76.
- Van Howe RS. Incidence of meatal stenosis following neonatal circumcision in a primary care setting. *Clin Pediatr (Phila)* 2006;45:49-54.
- Persad R, Sharma S, McTavish J, Imber C, Mouriquand PD. Clinical presentation and pathophysiology of meatal stenosis following circumcision. *Br J Urol* 1995;75:91-3.
- Joudi M, Fathi M, Hiradfar M. Incidence of asymptomatic meatal stenosis in children following neonatal circumcision. *J Pediatr Urol* 2011;7:526-8.
- Kajbafzadeh AM, Kajbafzadeh M, Arbab M, Heidari F, Arshadi H, Milani SM. Post circumcision meatal stenosis in the neonates due to meatal devascularisation: A comparison of frenular artery sparing, Plastibell and conventional technique. *J Urol* 2011;185 Suppl:e132.
- Quartey JK. Anatomy and blood supply of the urethra and penis. In: Schreiter F, Jordan GH, editors. *Reconstructive Urethral Surgery*. Springer-Verlag Berlin Heidelberg: Springer; 2006. p. 11-7.
- Hinman F Jr. The blood supply to preputial island flaps. *J Urol* 1991;145:1232-5.
- Dwyer ME, Salgado CJ, Lightner DJ. Normal penile, scrotal, and perineal anatomy with reconstructive considerations. *Semin Plast Surg* 2011;25:179-88.
- Fordham M. Surgery of the foreskin. In: Kingsnorth A, Majid AA, editors. *Principles of Surgical Practice*. Greenwich Medical Media Ltd.; UK; 2001. p. 85-98.
- McGrath K. The frenular delta. A new preputial structure. In: Denniston GC, Hodges FM, Milos MF, editors. *Understanding Circumcision: A Multi-Disciplinary Approach to a Multi-Dimensional Problem*. New York: Kluwer Academic/Plenum Publishers; 2001. p. 199-206.
- Duarte AF, Correia O. Laser CO2 frenuloplasty: A safe alternative treatment for a short frenulum. *J Cosmet Laser Ther* 2009;11:151-3.