

# Healed plaque erosion as a cause of recurrent vasospastic angina: a case report

Tetsuya Yamamoto \*, Ishii Toshimitsu, and Akihiko Ishida 

Department of Cardiology, Toyooka Public Hospital, Japan. 1094, Tobera, Toyooka, Hyogo 668-8501, Japan

Received 28 February 2021; first decision 9 April 2021; accepted 13 July 2021; online publish-ahead-of-print 4 September 2021

## Background

Recurrent vasospastic angina sometimes occurs. Fresh thrombi have been known to arise without plaque rupture at coronary spasm sites due to blood flow stagnation and intimal erosion caused by vasospasms. The relationship between recurrence of vasospastic angina and thrombus formation remains unclear.

## Case summary

A 67-year-old man presented with sudden chest pain at rest. Electrocardiography and coronary angiography indicated vasospastic angina. His chest pain persisted despite the administration of benidipine, isosorbide mononitrate, nicorandil, and nifedipine. Coronary angiography performed one month after initial presentation showed stenosis refractory to isosorbide administration. Optical coherence tomography revealed a healed plaque, and a stent was deployed. The patient remained symptom-free at 1-year follow-up.

## Discussion

Prolonged coronary vasospasm with limited coronary blood flow could induce total occlusion of the coronary artery, and acute thrombus formation, which resulted in healed plaque erosion. When vasospastic angina cannot be controlled, rapidly progressive stenosis caused by healed plaque erosion could be its underlying cause and mechanism. This report indicates that antiplatelet therapy may be a preventive option for future recurrent vasospastic angina, especially in those caused by healed plaques.

## Keywords

Case report • Vasospastic angina • Optical coherence tomography • Healed plaque • Acute coronary syndrome

## Learning points

- Optical coherence tomography may be useful to determine the cause of recurrence of vasospastic angina.
- When vasospastic angina cannot be controlled, rapidly progressive stenosis caused by healed plaque erosion might be the underlying cause and mechanism.
- Percutaneous coronary intervention could be considered as a potential therapy for refractory vasospastic angina if angiography and intravascular imaging are suggestive of an atherosclerotic aetiology.

## Introduction

Coronary artery spasm is implicated in the pathogenesis of variant angina and acute coronary syndrome (ACS).<sup>1,2</sup> Attacks of vasospastic angina can usually be relieved or suppressed using coronary vasodilators such as nitrates and calcium channel blockers. However, in some patients, vasospastic angina is intractable and resistant to drug treatment, and its attacks cannot be relieved or suppressed.<sup>3</sup>

The most common pathologic findings of ACS are plaque rupture, plaque erosion, and calcified nodules, which lead to occlusive thrombus formation in the coronary arteries.<sup>4</sup> This paradigm serves as the

\* Corresponding author. Tel: 81-796-22-6111, Fax: 81-796-22-0088, Email: [m07100ty@jichi.ac.jp](mailto:m07100ty@jichi.ac.jp)

Handling Editor: Marco De Carlo

Peer-reviewers: Konstantinos Stathogiannis; Rami Riziq Yousef Abumuaileq; Gareth Squire; Zaid Iskander and Derek Phan

Compliance Editor: Edwina McNaughton

Supplementary Material Editor: Ayse Djahit

© The Author(s) 2021. Published by Oxford University Press on behalf of the European Society of Cardiology.

This is an Open Access article distributed under the terms of the Creative Commons Attribution-NonCommercial License (<https://creativecommons.org/licenses/by-nc/4.0/>), which permits non-commercial re-use, distribution, and reproduction in any medium, provided the original work is properly cited. For commercial re-use, please contact [journals.permissions@oup.com](mailto:journals.permissions@oup.com)

theoretical basis of using antiplatelet therapy in ACS. However, fresh thrombi have been known to arise without plaque rupture at coronary spasm sites due to blood flow stagnation and intimal erosion caused by vasospasms.<sup>5</sup>

The relationship between recurrence of vasospastic angina and thrombus formation remains unclear. We present the case of a patient with recurrent vasospastic angina due to healed plaque erosion.

## Timeline

Emergency department (Day 1)	The patient presented with sudden chest pain at rest in the early morning. Electrocardiography showed an obvious ST-segment elevation in the leads I, aVL, and V1–5. Emergent coronary angiography (CAG) was performed due to acute ST-segment elevation myocardial infarction. CAG showed severe stenosis in the proximal portion of the left anterior descending coronary artery (LAD). Following administration of 5 mg isosorbide dinitrate, resolution of both LAD stenosis and ST-segment elevation were confirmed; thus, we established a diagnosis of vasospastic angina.
Day 5	The patient was discharged. He was administered benidipine (4 mg/day), isosorbide mononitrate (40 mg/day), and rosuvastatin (2.5 mg/day) and was free from any chest symptoms at the time of discharge.
Day 11	He had further chest pain and was taken to our hospital. His symptoms had already improved because of nitroglycerine administration before transport. Nicorandil (15 mg/day) and nifedipine (40 mg/day) were added to his medication regimen in the outpatient department. Following this, he had multiple recurrences of chest pain.
Day 32	He was hospitalized for titration of medication.
Day 36	Chest pain occurred and electrocardiography showed an obvious ST-segment elevation in the leads I, aVL, and V1–5. Emergent CAG showed severe organic stenosis; therefore, percutaneous coronary intervention was performed.
Day 39	He was discharged and dual antiplatelet therapy with prasugrel and aspirin was initiated.
1 year	He remained symptom-free.

## Case presentation

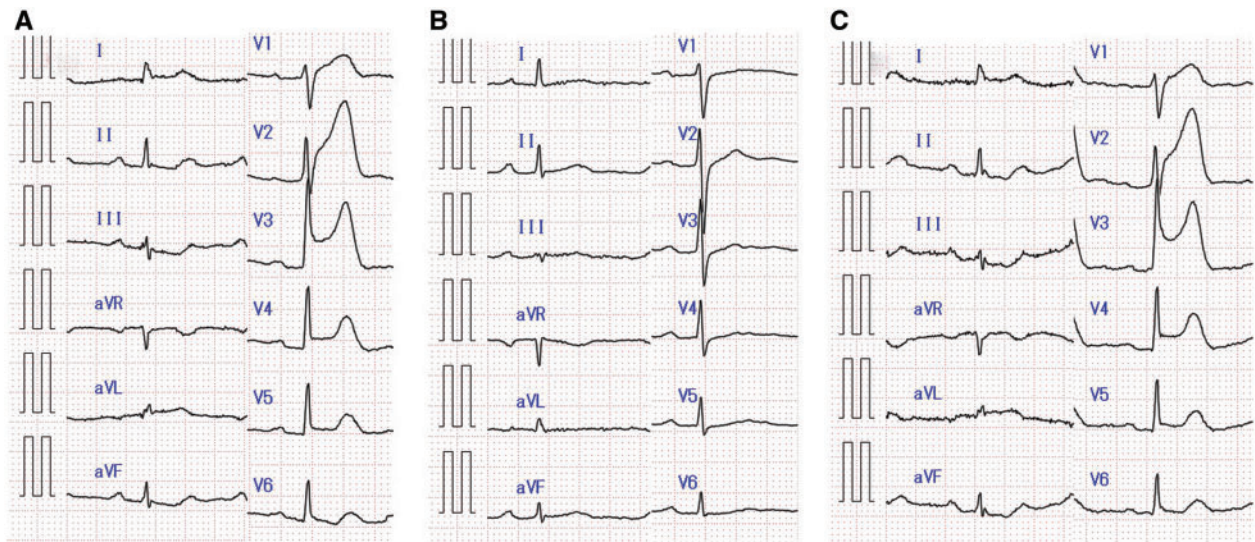
A 67-year-old Japanese man presented with sudden chest pain at rest. The chest pain persisted for 30 min and gradually decreased, and he was taken to our hospital. He was a former smoker, and his past medical history was significant for type 2 diabetes mellitus and hypertension, both of which were controlled by diet and exercise therapy.

His low-density lipoprotein level was 101 mg/dL (upper limit of normal: 140 mg/dL); high-density lipoprotein level, 66 mg/dL (lower limit of normal: 35 mg/dL); triglycerides level, 69 mg/dL (upper limit of normal: 150 mg/dL); and HbA1c level, 6.5% (upper limit of normal: 6.2%). He was not on any medications previously, including antiplatelet drugs.

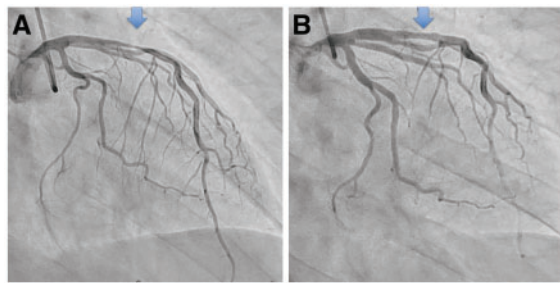
The patient's vital signs were stable. Physical examination showed significant facial and conjunctival pallor. There were no additional heart sounds on auscultation or pulmonary rales. Electrocardiography exhibited ST-segment elevation in leads I, aVL, and V1–5 (Figure 1A). Emergent coronary angiography (CAG) was performed due to acute ST-segment elevation myocardial infarction. CAG revealed severe stenosis in the proximal portion of the left anterior descending coronary artery (LAD) but no obvious atherosclerotic stenosis in any other lesions (Figure 2A and Supplementary material online, Video S1). Following an intracoronary infusion of 5 mg isosorbide dinitrate (ISDN), resolution of both LAD stenosis and ST-segment elevation were confirmed, leading to a diagnosis of vasospastic angina (Figures 1B and 2B and Video 1). Transthoracic echocardiogram showed normal left ventricular ejection fraction with no asynergy. On arrival, troponin I and creatinine kinase MB (CK-MB) levels were normal. Two hours later, the troponin I level had increased to 0.031 µg/mL (upper limit of normal: 0.026 µg/mL), and the CK-MB level was normal.

The patient was administered benidipine (4 mg/day), isosorbide mononitrate (40 mg/day), and rosuvastatin (2.5 mg/day). He was free from any chest symptoms at the time of discharge. However, 1 week later, he experienced chest pain and was taken to our hospital. His symptom had already improved because of nitroglycerine administration before transport. The efficacy of nitroglycerine indicated recurrent vasospastic angina. Nicorandil (15 mg/day) and nifedipine (40 mg/day) were added to his medication regimen. However, chest pain continued to occur frequently, only at rest, in the left chest region, with no radiation. There were no aggravating or relieving factors. The frequency of chest pain gradually increased. Therefore, he was hospitalized for titration of medication one month after the initial CAG.

Chest pain occurred in the early morning on Day 4 after hospitalization and electrocardiography revealed obvious ST-segment elevation in leads I, aVL, and V1–5 (Figure 1C). Emergent CAG was performed before nitroglycerine administration, which revealed the same site of severe stenosis in the LAD (Figure 3A and Supplementary material online, Video S2). This severe stenosis did not improve after intracoronary infusion of 5 mg ISDN (Figure 3B and Video 2). Optical coherence tomography (OCT) was performed to confirm the morphological features of the lesion. OCT showed multiple signal-rich layers with different optical densities and clear demarcation from underlying components: layered heterogeneous pattern (Figure 4 and Video 3). These findings were consistent with healed plaque, characterized by distinct layers of organized thrombus or collagen. The percutaneous coronary intervention was performed considering that rapidly progressive stenosis caused by healed plaque erosion might be the underlying cause and mechanism of recurrent vasospastic angina. A 3.0/13 mm Lacrosse NSE™ (Goodman Co., Ltd, Nagoya, Japan) was used for pre-dilatation. Thereafter, an everolimus-eluting



**Figure 1** Electrocardiography. (A) Electrocardiogram shows anterior ST-segment elevation myocardial infarction. (B) ST resolution is confirmed after the administration of isosorbide dinitrate. (C) Electrocardiogram reveals obvious ST-segment elevation for the second time.



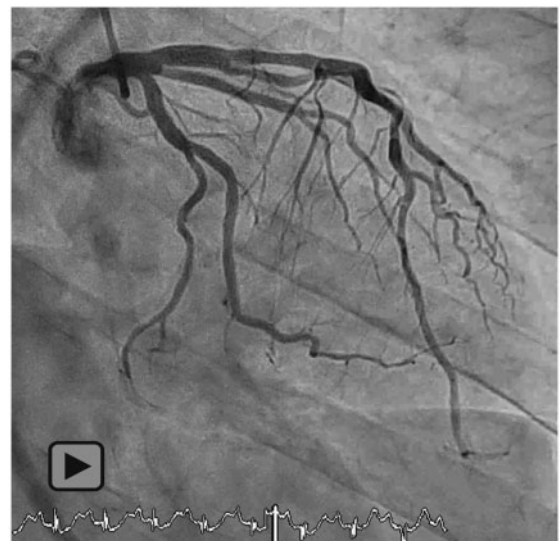
**Figure 2** The initial coronary angiogram. (A) Severe stenosis of the left anterior descending coronary artery (arrow) before the administration of isosorbide dinitrate. (B) Dilatation of a severe stenotic lesion in the left anterior descending coronary artery (arrow) after the administration of isosorbide dinitrate.

stent (3.0/15 mm) was successfully implanted ([Supplementary material online, Video S3](#)).

On the day of the second coronary angiography, troponin I and CK-MB levels were normal. Transthoracic echocardiogram showed normal left ventricular ejection fraction with no asynergy. The remainder of his hospital stay was uneventful. Dual antiplatelet therapy with prasugrel 3.75 mg and aspirin 100 mg was initiated. The patient remained symptom-free at the 1-year follow-up visit.

## Discussion

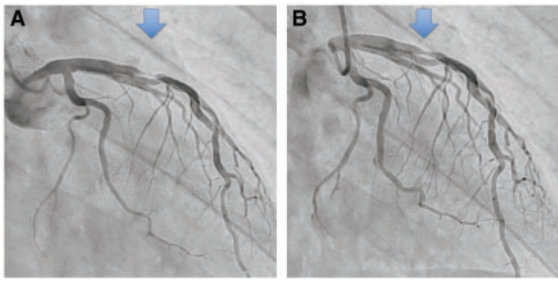
We report the case of a patient with recurrent vasospastic angina due to healed plaque. Acute disturbances in blood flow caused by acute vascular narrowing could induce endothelial damage and



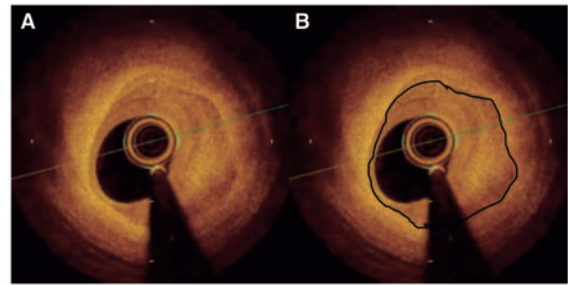
**Video 1** The initial coronary angiogram shows resolution of stenosis in the left anterior descending coronary artery after the administration of isosorbide dinitrate.

erosive injury to plaques with consequent thrombus formation.<sup>6</sup> Spasms are associated with more frequent thrombus formation and plaque erosion.<sup>7</sup> A previous intravascular imaging study using OCT showed that substantial proportions of spasm sites exhibited luminal irregularity,<sup>5,7</sup> which is pathologically consistent with a surface thrombus.<sup>8</sup> This suggests a close relationship between thrombus formation and persistent spasms.

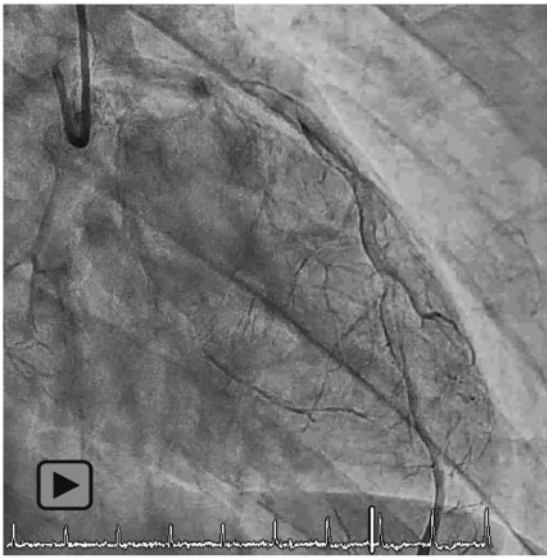
The thrombotic response is dynamic, including thrombosis and thrombolysis, and often associated with vasospasm. These responses



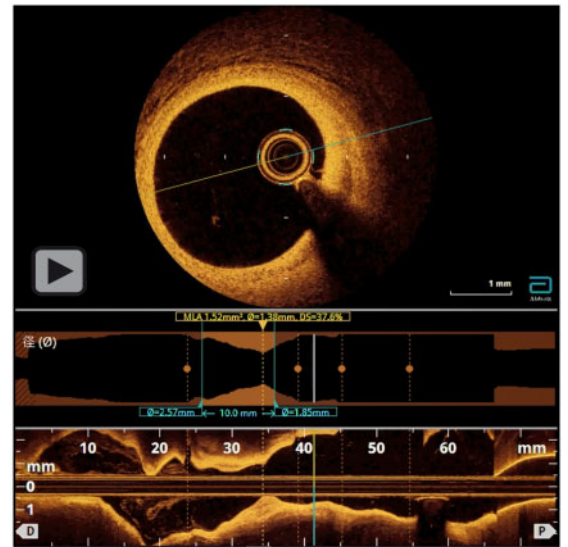
**Figure 3** The second coronary angiogram. (A) Severe stenosis in the left anterior descending coronary artery (arrow) before the administration of isosorbide dinitrate. (B) Severe organic stenosis in the left anterior descending coronary artery (arrow) remains after the administration of isosorbide dinitrate.



**Figure 4** Optical coherence tomography. (A) Imaging of the rapidly, progressive stenosis. (B) Black border indicates the layers of the vascular. There is healed plaque inside the border and fibrous plaque outside the border.



**Video 2** The second coronary angiogram shows severe organic stenosis in the left anterior descending coronary artery remains after the administration of isosorbide dinitrate.



**Video 3** Optical coherence tomography imaging of the rapidly, progressive stenosis.

tend to occur simultaneously, causing intermittent flow and the formation of a layered thrombus over several days.<sup>9</sup>

In this case, the patient experienced recurring chest pain, despite the administration of a vasodilator administration. During vasospastic angina, a thrombus gradually developed without causing myocardial infarction. The presence of a severe stenotic lesion with multiple layers at different optical densities and clear demarcation from underlying components exhibited hallmark features consistent with healed plaque erosion.<sup>10</sup> Based on these findings, rapid progression of severe stenosis due to healed plaques may be considered a cause of recurrent vasospastic angina.

Evidence regarding various pharmacotherapeutic options for vasospastic angina is limited. Table 1 shows medications for patients with vasospasm according to the 2019 European Society of Cardiology

guidelines,<sup>11</sup> 2013 Japanese Circulation Society guidelines,<sup>3</sup> and American Heart Association/American College of Cardiology guidelines.<sup>12</sup> It is unclear whether antiplatelet therapy suppresses future cardiovascular events in patients with coronary vasospastic angina. Patients with vasospastic angina without significant coronary artery stenosis who are administered low-dose aspirin have a higher risk of major adverse cardiac events, indicated primarily by a tendency towards rehospitalization.<sup>13</sup> Another study assessed clinical manifestations of ACS and all patients with vasospastic angina. The use of aspirin prevented myocardial infarction and chest pain recurrence in patients with vasospasm-induced with ACS, suggesting that it might be a useful therapy in certain patients.<sup>14</sup>

Prolonged coronary vasospasm with limited coronary blood flow may induce total occlusion of the coronary artery and formation of acute thrombus, which can result in healed plaque erosion. When

**Table 1 Medications of patients with vasospasm**

	Drug classes	Common drugs	Dosage
During an attack	Short-acting nitrates	Sub-lingual nitroglycerine	0.3–0.6 mg once
First line for prevention	Non-DHP CCB	Diltiazem IR	120–960 mg daily
	DHP CCB	Long-acting nifedipine	40–160 mg daily
Second line for prevention	Long-acting nitrates	ISDN	20–80 mg once daily
Alternative pharmacotherapy		Nicorandil	20 mg daily
	Steroid	Prednisolone	30 mg daily
	Rho-kinase inhibitor	Fasudil	300 µg/min for 15 min
	Statins	Fluvastatin	30 mg daily
	Alpha1-adrenergic receptor antagonists	Prazosin	8–30 mg daily
	Late sodium ion channel inhibitor	Ranolazine	1000 mg twice daily
	Endothelin receptor antagonist	Bosentan	125 mg twice daily
		Cilostazol	100 mg twice daily

CCB, calcium channel blocker; DHP, dihydropyridine; IR, immediate release; ISDN, isosorbide dinitrate.

vasospastic angina cannot be controlled, rapidly progressive stenosis caused by healed plaque erosion might be its underlying cause and mechanism. Therefore, this finding might indicate that antiplatelet therapy may be a preventive option for future recurrent vasospastic angina, especially in those caused by healed plaques. According to a previous study, this could have been the mechanism by which the use of antiplatelet therapy prevented myocardial infarction and chest pain recurrence in patients with vasospasm-induced with ACS.<sup>14</sup>

Stenting was an effective treatment in this patient with recurrent vasospastic angina with healed plaque. However, stenting is not advisable in patients with vasospastic angina for obvious reasons.<sup>15</sup> However, stenting could be considered as a potential therapy for refractory vasospastic angina if angiography and intravascular imaging were suggestive of an atherosclerotic aetiology.

## Conclusions

Optical coherence tomography may be useful to determine the cause of recurrence of vasospastic angina. When vasospastic angina cannot be controlled, rapidly progressive stenosis caused by healed plaque erosion might be its underlying cause and mechanism.

## Lead author biography



Tetsuya Yamamoto was born 1988 in Kobe, Japan. He received his medical training at Himeji Cardiovascular Center. Currently, he is a doctor in the Department of Cardiology of Toyooka Public Hospital.

## Supplementary data

Supplementary material is available at *European Heart Journal—Case Reports* online.

**Slide sets:** A fully edited slide set detailing these cases and suitable for local presentation is available online as [Supplementary data](#).

**Consent:** The authors confirm that written consent for submission and publication of this case report including images and associated text has been obtained from the patient in line with COPE guidance.

**Conflict of interest:** None declared.

**Funding:** None declared.

## References

- Pasupathy S, Air T, Dreyer RP, Tavella R, Beltrame JF. Systematic review of patients presenting with suspected myocardial infarction and nonobstructive coronary arteries. *Circulation* 2015;**131**:861–870.
- Yasue H, Omote S, Takizawa A, Nagao M. Coronary arterial spasm in ischemic heart disease and its pathogenesis. A review. *Circ Res* 1983;**52**:1147–1152.
- JCS Joint Working Group. Guidelines for diagnosis and treatment of patients with vasospastic angina (Coronary Spastic Angina) (JCS 2013). *Circ J* 2014;**78**: 2779–2801.
- Virmani R, Kolodgie FD, Burke AP, Farb A, Schwartz SM. Lessons from sudden coronary death: a comprehensive morphological classification scheme for atherosclerotic lesions. *Arterioscler Thromb Vasc Biol* 2000;**20**:1262–1275.
- Shin ES, Ann SH, Singh GB, Lim KH, Yoon HJ, Hur SH et al. OCT-defined morphological characteristics of coronary artery spasm sites in vasospastic angina. *JACC Cardiovasc Imaging* 2015;**8**:1059–1067.
- Sumi T, Yamashita A, Matsuda S, Goto S, Nishihira K, Furukoji E et al. Disturbed blood flow induces erosive injury to smooth muscle cell-rich neointima and promotes thrombus formation in rabbit femoral arteries. *J Thromb Haemost* 2010;**8**: 1394–1402.
- Shin E-S, Her A-Y, Ann SH, Balbir Singh G, Cho H, Jung EC et al. Thrombus and plaque erosion characterized by optical coherence tomography in patients with vasospastic angina. *Rev Esp Cardiol (Engl Ed)* 2017;**70**:459–466.
- Yahagi K, Zarpak R, Sakakura K, Otsuka F, Kutys R, Ladich E et al. Multiple simultaneous plaque erosion in 3 coronary arteries. *JACC Cardiovasc Imaging* 2014;**7**: 1172–1174.
- Bentzon JF, Otsuka F, Virmani R, Falk E. Mechanisms of plaque formation and rupture. *Circ Res* 2014;**114**:1852–1866.
- Okamoto H, Kume T, Yamada R, Koyama T, Tamada T, Imai K et al. Prevalence and clinical significance of layered plaque in patients with stable angina pectoris –

- evaluation with histopathology and optical coherence tomography. *Circ J* 2019;**83**:2452–2459.
11. Knuuti J, Wijns W, Saraste A, Capodanno D, Barbato E, Funck-Brentano C, et al.; ESC Scientific Document Group. 2019 ESC Guidelines for the diagnosis and management of chronic coronary syndromes. *Eur Heart J* 2020;**41**:407–477.
  12. Amsterdam EA, Wenger NK, Brindis RG, Casey DE Jr, Ganiats TG, Holmes DR, Jr et al. 2014 AHA/ACC Guideline for the Management of Patients with Non-ST-Elevation Acute Coronary Syndromes: a report of the American College of Cardiology/American Heart Association Task Force on Practice Guidelines. *J Am Coll Cardiol* 2014;**64**:e139–e228.
  13. Lim AY, Park TK, Cho SW, Oh MS, Lee DH, Seong CS et al. Clinical implications of low-dose aspirin on vasospastic angina patients without significant coronary artery stenosis; a propensity score-matched analysis. *Int J Cardiol* 2016;**221**:161–166.
  14. Lee Y, Park HC, Shin J. Clinical efficacy of aspirin with identification of intimal morphology by optical coherence tomography in preventing event recurrence in patients with vasospasm-induced acute coronary syndrome. *Int J Cardiovasc Imaging* 2018;**34**:1697–1706.
  15. Tanabe Y, Itoh E, Suzuki K, Ito M, Hosaka Y, Nakagawa I et al. Limited role of coronary angioplasty and stenting in coronary spastic angina with organic stenosis. *J Am Coll Cardiol* 2002;**39**:1120–1126.